

AperTO - Archivio Istituzionale Open Access dell'Università di Torino

**Unknown Primary Melanoma: Worldwide Survey on Clinical Management.**

**This is the author's manuscript**

*Original Citation:*

*Availability:*

This version is available <http://hdl.handle.net/2318/1640895> since 2017-06-05T09:13:12Z

*Published version:*

DOI:10.1159/000453592

*Terms of use:*

Open Access

Anyone can freely access the full text of works made available as "Open Access". Works made available under a Creative Commons license can be used according to the terms and conditions of said license. Use of all other works requires consent of the right holder (author or publisher) if not exempted from copyright protection by the applicable law.

(Article begins on next page)

# Unknown Primary Melanoma: Worldwide Survey on Clinical Management

Simone Ribero<sup>a</sup> Riccardo Pampena<sup>b,c</sup> Veronique Bataille<sup>d,h</sup> Elvira Moscarella<sup>b</sup>  
Luc Thomas<sup>e</sup> Pietro Quaglino<sup>a</sup> Concetta Potenza<sup>c</sup> Alexander C.J. Van Akkooij<sup>f</sup>  
Alessandro Testori<sup>g</sup> Paul Nathan<sup>h</sup> Susana Puig<sup>i,j</sup> Iris Zalaudek<sup>k</sup>  
Giuseppe Argenziano<sup>l</sup> Caterina Longo<sup>b,m</sup>

<sup>a</sup>Section of Dermatology, Medical Sciences Department, University of Turin, Turin, <sup>b</sup>Dermatology and Skin Cancer Unit, Arcispedale Santa Maria Nuova-IRCCS, Reggio Emilia, and <sup>c</sup>Dermatology Unit Daniele Innocenzi, Department of Medical and Surgical Sciences and Biotechnologies, Sapienza University of Rome, Terracina, Italy; <sup>d</sup>Department of Twin Research and Genetic Epidemiology, King's College London, London, UK; <sup>e</sup>Dermatology, Centre Hospitalier Lyon-Sud and Lyon 1 University and Lyon Cancer Research Center, Lyon, France; <sup>f</sup>Department of Surgical Oncology, The Netherlands Cancer Institute – Antoni van Leeuwenhoek Hospital, Amsterdam, The Netherlands; <sup>g</sup>European Institute of Oncology, Milan, Italy; <sup>h</sup>Mount Vernon Cancer Centre, East and North NHS Trust, Northwood, UK; <sup>i</sup>Melanoma Unit, Dermatology Department, Hospital Clinic de Barcelona, IDIBAPS, Universitat de Barcelona, Barcelona, and <sup>j</sup>Centro de Investigación Biomédica en Red en Enfermedades Raras (CIBERER), Valencia, Spain; <sup>k</sup>Department of Dermatology and Venereology, Medical University of Graz, Graz, Austria; <sup>l</sup>Dermatology Unit, Second University of Naples, Naples, <sup>m</sup>Dermatology Unit, University of Modena and Reggio Emilia, Modena, Italy

## Keywords

Unknown primary · Melanoma · Management · Survey

## Abstract

**Background:** How to deal with melanoma of unknown primary (MUP) origin is a debated topic in the literature. **Objective:** We performed a worldwide survey to inquire what clinical and investigational workup is performed as well as the physicians' perception of this disease. **Methods:** A questionnaire was sent via mail to clinicians involved in melanoma care from December 2015 to April 2016 using the International Dermoscopy Society website. **Results:** 119 physicians from 47 different countries answered the questionnaire. The most reported examination was skin examination followed by CT and/or PET scans. All the participants declared asking

about previous excisions of skin lesions with 81% of them asking for a histopathological slide review of previous biopsies. Half of the participants checked for a possible vitiligo phenomenon that may explain regression of the primary lesion. *BRAF*, *cKIT*, and *GNAQ* mutations were screened by 32% of participants. The majority of participants (76%) applied the same treatment protocols for MUP as patients with known primary melanomas of the same AJCC stage. **Conclusion:** Strong heterogeneity was found between physicians dealing with MUP. Thus, a consensus document should be strongly encouraged.

© 2017 S. Karger AG, Basel

Simone Ribero and Riccardo Pampena contributed equally to this work.

## Introduction

Melanoma of unknown primary (MUP) or occult primary melanoma represents only a minority of melanoma cases, occurring in almost 3% of patients with histologically confirmed metastatic melanoma in either lymph nodes, (sub)cutaneous tissue, or visceral sites [1]. The diagnosis of MUP is commonly based on the impossibility to identify a primary cutaneous, ocular or mucosal lesion throughout physical examination and revision of previous excisions [2].

In 1963, Das Gupta et al. [3] first described diagnostic criteria for MUP excluding from this category patients who did not receive complete physical examination, including anus/genitalia and ophthalmological visit, patients with evidence of previous orbital enucleation, patients who underwent surgical or nonsurgical procedures, without histological documentation, for a mole, birthmark, freckle, chronic paronychia, or skin blemish, in particular in cases of nodal involvement and presence of a scar in the skin area drained by the lymphatic basin.

The majority of MUP cases are nodal (60%), with the axilla, neck and groin representing the most frequent sites; the remaining cases involve the (sub)cutaneous tissue and various visceral sites [4].

Concerning the origin, MUP should probably be considered a heterogeneous entity, comprising cases with fully regressed primary lesions, cases of internal or nodal primary melanomas and cases where the primary tumor had been treated with nonsurgical procedures or excised without proper histological confirmation [5].

The management and prognosis of MUP is a debated topic in the literature. Despite evidence reporting a similar or more favorable prognosis compared to melanomas of known origin according to stage, physicians are usually more worried when dealing with MUPs, and different follow-up approaches are used [6]. Moreover, there is a lack of consensus regarding the investigations that should be performed in searching for a potential primary melanoma.

The current survey aimed to investigate which type of investigations is currently performed to search for the melanoma primary in MUP.

## Materials and Methods

For further details, see the supplementary materials (for all online suppl. material, see [www.karger.com/doi/10.1159/000453592](http://www.karger.com/doi/10.1159/000453592)) (Fig. 1).

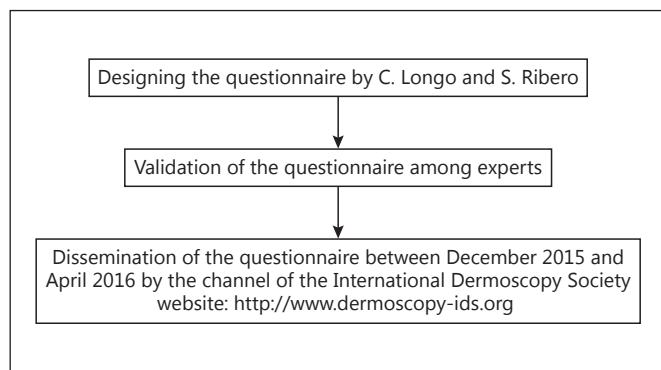


Fig. 1. Flowchart of Materials and Methods.

## Results

In all, 119 physicians from 47 different countries returned the questionnaire (men, 52%; mean age, 45.5 years; range, 26–72 years). Worldwide distribution of participants involved all 5 continents (75 Europe, 17 Asia, 16 America, 7 Oceania, and 4 Africa). Fifty-five (46%) of the participants worked in a university hospital, 24 (20%) in a district hospital, and 40 (34%) in private practice.

The majority of the participants (89%) were dermatologists, and the others were equally distributed between surgeons, oncologists, and general practitioners with special interest in dermatology.

The mean number of new melanomas treated yearly by each physician was  $37 \pm 6.8$ , with 88% of the participants reporting at least 1 stage III or IV melanoma patient treated in the previous year.

Half of the participants (51%) reported to have treated more than 1 patient with MUP in the last 5 years, while 21% had treated at least 1 in the previous year.

The great majority of patients with MUPs had skin metastases as first disease manifestation (51 cases), followed by nodal (41), visceral (32), and mucosal metastases (14).

The distribution of requested investigations is reported in Table 1. The most frequent was a skin examination followed by CT and/or PET scans. More invasive investigations such as colonoscopy and gastroscopy were not reported with high priority. In particular, there was a strong agreement (88%,  $\kappa = 0.76$ ) between the ones suggesting colonoscopy and the ones suggesting gastroscopy.

All the participants declared asking about previous excisions of skin lesions, with 81% of them asking for a histopathological slide review of previous biopsies. Half of the participants checked for a possible vitiligo phenom-

**Table 1.** List of clinical examinations and imaging used for MUP from participants in the survey ( $n = 107$ )

Examination	Yes	Percent
CT/PET	95	88.7
Gynecological examination	48	44.8
Ophthalmological examination	66	61.7
Rectoscopy	34	31.8
Colonoscopy	36	33.6
Gastroscopy	30	28.0
Skin examination	99	92.5
Ear-neck-throat examination	38	35.5
<i>BRAF/KIT/GNAQ</i> mutations	35	32.7
Documentation of previous skin biopsies	107	100
Review of histopathology for previous lesions	87	81
Check for vitiligo	53	49.5

enon that may indicate regression of the primary lesion. *BRAF*, *cKIT*, and *GNAQ* mutations were screened by 32% of the participants.

When asked for the more suitable explanations of MUP, 16 reported a possible amelanotic melanoma, 52 believed in regression of primary, 18 thought about a misdiagnosed nevus, 13 in melanoma in lymph nodes and 11 in an internal primary.

Regarding treatment, the majority of the participants (76%) declared to apply the same treatment protocols in MUP as compared to patients with known primary melanomas of the same AJCC stage [7], 4 (3%) answered that they would treat the patient in a more relaxed and 24 (21%) in a more worried fashion.

Fifty-four (47%) participants thought that the prognosis of patients with MUP is worse than of those with non-MUP, 19 (17%) that it is better and 41 (36%) that it is superimposable.

## Discussion

Treatment of metastatic melanoma is a challenging topic; despite the recent progress, the majority of the patients will die in a relatively short time [8]. MUP is by definition a metastatic melanoma [1]. After Das Gupta et al. [3] had first defined MUP criteria, many authors investigated the prognosis of this entity with conflicting results [1, 9–11].

The American Joint Committee on Cancer 2009 melanoma staging system stated to classify MUP with nodal or (sub)cutaneous involvement as stage III and cases with visceral metastasis as stage IV; however, the prog-

nostic significance of this entity was not properly specified [7].

Recently, a meta-analysis [6] of observational studies showed a better survival in patients with MUP compared to patients with known primary melanomas, according to stage; the authors hypothesized that the antitumor immune response to MUP may lead to a better survival, as they considered spontaneous regression as one of the probable causes of MUP. It was also suggested that the same therapeutic approach should be followed for both of these entities [12]. Furthermore, histological regression has been described as a potential favorable feature of melanoma as it probably reflects an activation of the immune system [13]. On the other hand, discordant data are reported regarding the survival of patients with complete regressed primary cutaneous melanoma [14].

In spite of this, the majority of responders in this survey considered survival of MUP worse than for known primaries, although only a minority would manage this entity with a more aggressive therapeutic approach.

Concerning finding a potential primary, very few studies assessed the usefulness of clinical examination and imaging for detecting the primary tumor.

In particular, Tos et al. [15] investigated the best screening for MUP, concluding that skin examination, medical history, histopathological review of previous excisions and CT/PET for staging should be performed.

Our results also highlight the primary role of careful skin examination and anamnesis for the identification and histopathological revision of previous skin excisions in MUP patients.

Two thirds of the participants estimated that the skin was the most likely primary site for MUP, in agreement with recent studies demonstrating a similar molecular profile between MUP and melanomas on nonchronically sun-damaged skin [16, 17].

One of the major concerns regarding screening for primary tumor in MUP patients is the need for a multidisciplinary approach. In our survey, almost half of the participants referred MUP patients for gynecology or ear-neck-throat examinations to look at possible melanoma localizations.

This could be explained not only by the lower concern of a primary mucosal origin of MUP, but also by a higher ability of dermatologists in diagnosing mucosal melanomas of the mouth and genital area, thanks to dermoscopy [18, 19].

Regarding instrumental examinations, CT and/or PET were largely preferred to endoscopy, probably as the former primarily have a staging role.

Our survey has 2 limitations: first, it is more based on physicians' perception than real data from different centers; second, respondents cannot be considered totally representative of the International Dermoscopy Society membership.

In conclusion, strong variability was found between physicians dealing with MUP, despite the high prevalence of doctors who manage treatment in stage III or IV. A consensus document is needed in order to assist clinicians in the clinical workup of a given patient with MUP and in defining the need for a multidisciplinary approach.

## References

- 1 Kamposioras K, Pentheroudakis G, Pectasides D, Pavlidis N: Malignant melanoma of unknown primary site: to make the long story short – a systematic review of the literature. *Crit Rev Oncol Hematol* 2011;78:112–126.
- 2 Pack GT, Gerber DM, Scharnagel IM: End results in the treatment of malignant melanoma: a report of 1,190 cases. *Ann Surg* 1952;136:905–911.
- 3 Das Gupta T, Bowden L, Berg JW: Malignant melanoma of unknown primary origin. *Surg Gynecol Obstet* 1963;117:341–345.
- 4 Anbari KK, Schuchter LM, Bucky LP, Mick R, Synnestvedt M, Guerry D 4th, Hamilton R, Halpern AC: Melanoma of unknown primary site: presentation, treatment, and prognosis – a single institution study. University of Pennsylvania Pigmented Lesion Study Group. *Cancer* 1997;79:1816–1821.
- 5 Chang P, Knapper WH: Metastatic melanoma of unknown primary. *Cancer* 1982;49:1106–1111.
- 6 Bae JM, Choi YY, Kim DS, Lee JH, Jang HS, Lee JH, Kim H, Oh BH, Roh MR, Nam KA, Chung KY: Metastatic melanomas of unknown primary show better prognosis than those of known primary: a systematic review and meta-analysis of observational studies. *J Am Acad Dermatol* 2015;72:59–70.
- 7 Balch CM, Gershenwald JE, Soong SJ, Thompson JF, Atkins MB, Byrd DR, Buzaid AC, Cochran AJ, Coit DG, Ding S, Eggermont AM, Flaherty KT, Gimotty PA, Kirkwood JM, McMasters KM, Mihm MC Jr, Morton DL, Ross MI, Sober AJ, Sondak VK: Final version of 2009 AJCC melanoma staging and classification. *J Clin Oncol* 2009;27:6199–6206.
- 8 Ribero S, Longo C, Glass D, Nathan P, Bataille V: What is new in melanoma genetics and treatment? *Dermatology* 2016;232:259–264.
- 9 Laveau F, Picot MC, Dereure O, Guillou JJ, Guillot B: Metastatic melanoma of unknown primary site. *Ann Dermatol Venereol* 2001;128:893–898.
- 10 Savoia P, Fava P, Osella-Abate S, Nardò T, Comessatti A, Quaglino P, Bernengo MG: Melanoma of unknown primary site: a 33-year experience at the Turin Melanoma Center. *Melanoma Res* 2010;20:227–232.
- 11 Clerico R, Bottoni U, Paolino G, Ambrifi M, Corsetti P, Devirgiliis V, Calvieri S: Melanoma with unknown primary: report and analysis of 24 patients. *Med Oncol* 2012;29:2978–2984.
- 12 Prens SP, van der Ploeg AP, van Akkooi AC, van Montfort CA, van Geel AN, de Wilt JH, Eggermont AM, Verhoef C: Outcome after therapeutic lymph node dissection in patients with unknown primary melanoma site. *Ann Surg Oncol* 2011;18:3586–3592.
- 13 Ribero S, Osella-Abate S, Sanlorenzo M, Savoia P, Astrua C, Cavaliere G, Tomasini C, Senetta R, Macripò G, Bernengo MG, Quaglino P: Favourable prognostic role of regression of primary melanoma in AJCC stage I–II patients. *Br J Dermatol* 2013;169:1240–1245.
- 14 Ribero S, Moscarella E, Ferrara G, Piana S, Argenziano G, Longo C: Regression in cutaneous melanoma: a comprehensive review from diagnosis to prognosis. *J Eur Acad Dermatol Venereol* 2016;30:2030–2037.
- 15 Tos T, Klyver H, Drzewiecki KT: Extensive screening for primary tumor is redundant in melanoma of unknown primary. *J Surg Oncol* 2011;104:724–727.
- 16 Gos A, Jurkowska M, van Akkooi A, Robert C, Kosela-Paterczyk H, Koljenović S, Kamsukom N, Michej W, Jeziorski A, Pluta P, Verhoef C, Siedlecki JA, Eggermont AM, Rutkowski P: Molecular characterization and patient outcome of melanoma nodal metastases and an unknown primary site. *Ann Surg Oncol* 2014;21:4317–4323.
- 17 Egberts F, Bergner I, Krüger S, Haag J, Behrens HM, Hauschild A, Röcken C: Metastatic melanoma of unknown primary resembles the genotype of cutaneous melanomas. *Ann Oncol* 2014;25:246–250.
- 18 Blum A, Simionescu O, Argenziano G, Braun R, Cabo H, Eichhorn A, Kirchesch H, Malvey J, Marghoob AA, Puig S, Ozdemir F, Stolz W, Tromme I, Weigert U, Wolf IH, Zalaudek I, Kittler H: Dermoscopy of pigmented lesions of the mucosa and the mucocutaneous junction: results of a multicenter study by the International Dermoscopy Society (IDS). *Arch Dermatol* 2011;147:1181–1187.
- 19 Hofmann-Wellenhof R: Special criteria for special locations. 2. Scalp, mucosal, and milk line. *Dermatol Clin* 2013;31:625–636, ix.

## Acknowledgments

The authors are thankful to all the clinicians who took part in this survey.

## Ethics Statement

IRB approval was waived.

## Disclosure Statement

The authors report no conflict of interest. There were no funding sources for this work.