

CLINICAL REPORT

Autoantibody Profile of a Cohort of 78 Italian Patients with Mucous Membrane Pemphigoid: Correlation Between Reactivity Profile and Clinical Involvement

Emanuele COZZANI¹, Giovanni DI ZENZO², Valentina CALABRESI², Marco CARROZZO³, Martina BURLANDO¹, Lora LONGANESI⁴, Amilcare CERRI⁵, Marzia CAPRONI⁶, Francesco SERA⁷, Emiliano ANTIGA⁶, Pietro QUAGLINO⁸, Angelo V. MARZANO⁹ and Aurora PARODI¹

¹IRCCS - AUO San Martino-IST, DISSAL- Section of Dermatology, Department of Health Sciences, University of Genoa, Genoa, ²Laboratory of Molecular and Cell Biology, Istituto Dermopatico dell'Immacolata-IRCCS, Rome, Italy, ³Centre for Oral Health Research, Oral Medicine Department, University of Newcastle upon Tyne, Newcastle upon Tyne, UK, ⁴Ophthalmology Section, Hospital of Lugo, Ravenna, ⁵Dermatologic Clinic, Department of Medicine Surgery and Dental Sciences S. Paolo, University of Milan, Milan, ⁶Department of Surgery and Translational Medicine, Section of Dermatology, University of Florence, Florence, Italy, ⁷Lifecourse Epidemiology and Biostatistics, Population, Policy and Practise, UCL Institute of Child Health, London, UK, ⁸Dermatologic Clinic, Department of Medical Sciences, University of Turin, Turin, ⁹Dipartimento di Fisiopatologia Medico-Chirurgica e dei Trapianti, Università degli Studi di Milano, Unita' Operativa di Dermatologia, IRCCS Fondazione Ca' Granda, Ospedale Maggiore Policlinico, Milano, Italy

Direct diagnosis of mucous membrane pemphigoid (MMP) is not easy. Circulating autoantibodies targeting bullous pemphigoid antigens of 180 kDa and 230 kDa (BP180 and BP230), $\alpha\beta4$ integrin, laminin 332 and type VII collagen (Col VII) are not always present. The aims of this study were to characterize the humoral immune response of a cohort of Italian patients with MMP, its association with clinical involvement and severity, and to design an algorithm for efficient serological diagnosis. Seventy-eight MMP sera were studied retrospectively by indirect immunofluorescence on salt-split skin, enzyme-linked immunosorbent assay (ELISA) and immunoblotting. Indirect immunofluorescence on salt-split skin resulted in the most sensitive approach for diagnosis of MMP. BP180 was the major autoantigen in MMP patients with oral and cutaneous involvement. Significant associations were found between BP180 reactivity and oral and cutaneous localization of the lesions ($p=0.006$), and between Col VII positivity and Setterfield severity score ($p=0.020$). Key words: autoantibody; mucous membrane pemphigoid; diagnosis.

Accepted Dec 2, 2015; Epub ahead of print Dec 3, 2015

Acta Derm Venereol 2016; 96: 768–773.

Emanuele Cozzani, IRCCS, AUO San Martino-IST, DISSAL- Section of Dermatology, University of Genoa, IT-16132 Genoa, Italy. E-mail: emanuele.cozzani@unige.it

Mucous membrane pemphigoid (MMP) comprises a heterogeneous group of autoimmune sub-epithelial bullous diseases, predominantly affecting mucous membranes with or without skin involvement, leading to scarring phenotype (1, 2). MMP also includes those blistering diseases, such as mucous membrane-dominant epidermolysis bullosa acquisita and linear IgA bullous dermatosis, with preferential mucous membrane involvement (1). MMP is characterized by deposits of immunoglobulin G (IgG) and/or IgA and/

or complement fragments at the dermal-epidermal and/or chorio-epithelial basement membrane zone (BMZ) and, at least in some patients, circulating IgG and/or IgA autoantibodies targeting several BMZ components, including the bullous pemphigoid antigens of 180 kDa (BP180) and 230 kDa (BP230) (3–7), $\alpha\beta4$ integrin (8, 9), laminin 332 (10, 11) and type VII collagen (Col VII) (1).

BP180 and BP230 are components of the junctional adhesion complex called hemidesmosome. BP230 is a cytoplasmic protein implicated in the organization of the keratin filament network and BP180 is a transmembrane protein that, by interaction with $\alpha\beta4$, contributes to the assembly and stabilization of hemidesmosomes (12, 13). In addition, $\alpha\beta4$ integrin mediates cell adhesion to extracellular matrix, and laminin 332 and Col VII play an important role in the maintenance of epithelial cell anchorage to the underlying connective tissue (14–16). In *ex vivo* and *in vivo* models it has been demonstrated that autoantibodies against laminin 332 and $\beta4$ integrin have a role in the pathogenesis of MMP (9, 17).

Diagnosis of MMP is made through clinical findings, assessment of sub-epithelial blister by histopathology, detection of linear deposition of autoantibodies at the BMZ by direct immunofluorescence (DIF) and binding to the roof and/or floor of the blister of salt-split skin by indirect immunofluorescence (IIF-SSS). Commercially available ELISAs, based on proteins involved in dermo-epidermal or chorio-epithelial adhesion, are also usually employed for serological diagnosis of MMP. In particular, the major targets of autoantibodies are BP180 (both NC16A and C-terminal domain) and laminin 332, and diagnoses of anti-BP180 and anti-laminin 332 type MMP, respectively, are frequently made.

The present retrospective study characterized the humoral immune response of 78 Italian patients with MMP using standard approaches, such as IIF-SSS and commercial ELISAs, to design an algorithm for efficient serological diagnosis.

METHODS

Patients

Seventy-eight sera, collected from 2013 to 2014, were studied retrospectively. The sera were collected from 54 women and 24 men (mean age 74 years) with MMP observed in different Italian clinical centres (Turin, Genoa, Ravenna, Milan and Florence). In accordance with the international consensus on MMP, patients with predominantly mucosal membrane disease were classified as MMP even though they only have autoantibodies to Col VII (1). From a clinical point of view, the 78 patients presented different clinical involvement: oral (OR), ocular (OC), skin Brunsting-Perry (BP) variant, naso-pharynx (NP) and genital (G). In particular, 39 patients (#1–39) were classified as OR-MMP, 10 (#40–49) as OC-MMP, 5 (#50–54) as BP-MMP variant, and 24 (#55–78) presented a mixed form with both cutaneous and mucous involvement. Out of these patients with mixed form, 5 (#55–59) had OR/OC-MMP, 3 (#60–62) OR/BP-MMP, 3 (#63–65) OR/OC/NP-MMP, 3 (#66–68) OC/BP-MMP, 2 (#69–70) OR/NP-MMP, 1 (#71) OR/G-MMP, 1 (#72) OC/NP-MMP, 1 (#73) OR/NP/BP-MMP, 1 (#74) OR/BP/G-MMP, 1 (#75) OR/OC/BP-MMP, 1 (#76) OR/NP/G-MMP, 1 (#77) OC/BP/NP-MMP and 1 (#78) OC/BP/G-MMP (Table S1¹). According to Setterfield score, a reproducible system for scoring clinical sites (skin, ocular, oral gingiva, oral non-gingival sites, naso/pharynx, larynx, oesophagus, and genital), which would minimize observer variability, and allow accurate assessment of both disease severity and response to therapeutic intervention (18), our patients were allocated an initial clinical score based on the sum of individual site severity scores at presentation. The disease severity of our patients was then classified into 4 classes: I (score 0–4), II (score 5–9), III (score 10–14) and IV (score ≥ 15). The clinical diagnosis was confirmed by histology and by the presence of IgG/IgA at the BMZ by DIF. The sera of 10 healthy individuals were used as controls for the laminin 332 detection assay.

Indirect immunofluorescence

IIF was performed on monkey oesophagus (MO), utilizing commercial slides (BioSystems S.A. Barcelona, Spain). IIF-SSS was performed utilizing a commercial kit (Immco Diagnostics, NY, USA). All sera were diluted to 1:20 in phosphate-buffered saline (PBS). The slides were incubated with the diluted sera for 30 min. After washing in PBS, the slides were covered with fluorescein isothiocyanate-conjugated goat anti-human IgG or IgA (Kallestad Diagnostic, Chaska, MN, USA) for 30 min. Following a further PBS washing, the slides were mounted in buffered glycerine and examined under a fluorescence microscope (Leitz, Wetzlar, Germany). IIF titre was considered positive when higher than 1:40.

Enzyme-linked immunosorbent assay

ELISA was performed using commercial kits (MBL, Naka-Ku Nagoya, Japan) consisting of microwells coated with recombinant proteins encompassing BP230, BP180 and Col VII. According to the manufacturer's recommendations, the cut-off value for both BP230 and BP180 was 9.0 (U/ml), and for Col VII the cut-off value was 6.0 (U/ml). To compare the results from different plates, the test sample optical densities (OD) were adjusted according to positive and negative control samples supplied in each kit. The final results were expressed as a percentage according to the following calculation:

$$\text{OD sample} - \text{OD negative control} / \text{OD positive control} - \text{OD negative control} \times 100.$$

Laminin 332 affinity purification

Squamous carcinoma cells (SCC) 25 (CCL 25; American Type Culture Collection) were grown in 50% Ham's F-12 (Life Technologies, Milan, Italy) and 50% Dulbecco's-modified Eagle's medium (Life Technologies), supplemented with 10% foetal bovine serum (FBS) (GE Healthcare Bio-Sciences, Pittsburgh, PA, USA), 4 mM glutamine (Life Technologies), hydrocortisone (0.4 $\mu\text{g/ml}$) (Merck, Milan, Italy), 50 U/ml penicillin, and 50 $\mu\text{g/ml}$ streptomycin (Life Technologies). The culture medium, harvested from confluent SCC25 culture after 24 h in medium without serum with 0.1% bovine serum albumin (BSA), was centrifuged to remove cells and filtered. The medium was concentrated 20-fold by centrifugation with Amicon Ultra (cut-off 10,000 Da) (Millipore, Billerica, MA, USA), dialysed against PBS, passed over bovine gelatin coupled to Sepharose™ 4B (GE Healthcare) to remove fibronectin, and stored at 4°C after addition of protease inhibitors (5 mM EDTA, complete) (Roche Diagnostics, Indianapolis, IN, USA). Subsequently, laminin 332 was purified by passage over K140 sepharose (mouse MoAb to the laminin 332 $\beta 3$ chain; gift from R. Burgeson, Cutaneous Biology Research Center, Charlestown, MA, USA) (19). Laminin 332 was eluted from K140 sepharose using 100 mM glycine pH 2.8. The fractions containing laminin 332 were neutralized by adding 1 M Tris-HCl, pH 9, pooled and dialysed against PBS.

Immunoblotting

SDS-polyacrylamide gel electrophoresis was performed using a 6% polyacrylamide gel loaded with 5 μg purified laminin 332 per lane, in reducing conditions. Immunoreactivity was detected, after transfer to polyvinylidene difluoride membrane (Immobilon-P; Millipore), by incubation with a 1:100 dilution of patient and control sera and monoclonal antibodies to laminin 332 K140 (anti- $\beta 3$), BM165 (anti- $\alpha 3$) (20), U46 (anti- $\gamma 2$ polyclonal antibody produced in our laboratory), followed by incubation with alkaline phosphatase-labelled secondary antibodies.

Statistical analysis

Associations between disease severity and IIF microscopy or antigen reactivity, expressed as dichotomous variable (absent/present) were assessed using Mann-Whitney (for category variables with 2 categories). Prevalence differences of IIF microscopy or antigen reactivity on patients with different disease localization (oral, ocular, skin, multiple site) were assessed with χ^2 test calculated on contingency tables. Fisher's exact test was used when expected counts were less than 5. All analyses were performed using Stata statistical package (2005. Stata Statistical Software: Release 9. College Station, TX, USA: StataCorp LP).

RESULTS

Patients

A total of 78 MMP sera from different Italian clinical centres were retrospectively studied, including 39 (50%) OR-MMP, 10 (12.8%) OC-MMP, 5 (6.4%) BP-MMP and 24 (30.8%), presenting a mixed form with both cutaneous and mucous involvement. Fifty-seven out of 78 (73%) patients with MMP presented oral

¹<http://www.medicaljournals.se/acta/content/?doi=10.2340/00015555-2311>

involvement (Table S1¹), which is the most affected mucosal site, as previously reported (21).

Indirect immunofluorescence results

When tested by IIF, only 2 sera of the 78 MMP patients (2.6%) were IgG-positive using MO (IgG) as a substrate. In contrast, when analysed by IIF-SSS, IgG and/or IgA positivity was found in 45 MMP sera out of 78 (58%), confirming the higher sensitivity of this technique in comparison with IIF on MO (Table S1¹). In particular, as for the 37 IgG-positive patients, 22 (59.5%) patients' sera had a double positivity pattern (roof and floor), 11 (29.7%) had positivity only at the roof and 4 (10.8%) only at the floor. As for the 23 IgA-positive patients, 8 (34.8%) patients' sera had a double positivity pattern (roof and floor), 8 (34.8%) had positivity only at the roof, and 7 (30.4%) patients' only at the floor (Table S1¹). As regards the relationship between clinical variant and the IIF-SSS reactivity pattern, no statistical significant result was found. In addition, no significant association was found between IIF-SSS reactivity and disease severity score.

IgG reactivity profile

The MMP sera reactivity profile was investigated using 3 commercially available ELISA kits for detection of autoantibodies targeting BP180, BP230 and Col VII and an immunoblotting (IB) analysis based on affinity purified laminin 332. BP180 ELISA was positive in 26 patients (33%), BP230 ELISA was positive in 9 patients (11.5%) and Col VII ELISA in 3 patients (3.8%) (Table S1¹) (Fig. 1a). IgG reactivity to laminin 332 on IB was found in 9 out of 78 patients' sera (11.5%) and in no control sera (Fig. 1b). All laminin 332-positive sera reacted against the α 3 chain, 3 out of 9 bound to γ 2 and 1 out of 9 to β 3 (Fig. 1b and data not shown). Of note, no relationship between laminin 332 positivity and associated internal cancer was found (data not shown). Even if bound by a relatively low number of sera, BP180 represents the most recognized antigen in the present cohort of patients with MMP.

Correlation between target antigen, clinical variant and disease severity

As regards the relationship between target antigen, clinical variant and Setterfield score, among the 26 BP180-positive patients, 17 had OR-MMP variant, 1 had an OC-MMP variant, 4 had BP-MMP type and 4 had a mixed variant (OR/BP-MMP; OR/NP-MMP; OR/G-MMP; OR/NP/BP-MMP), showing a significant association between BP180 reactivity and oral and cutaneous localization of the lesions ($p=0.006$) (Table S1¹ and Fig. 2). Of note, BP180 reactivity presented a significant inverse association with disease severity

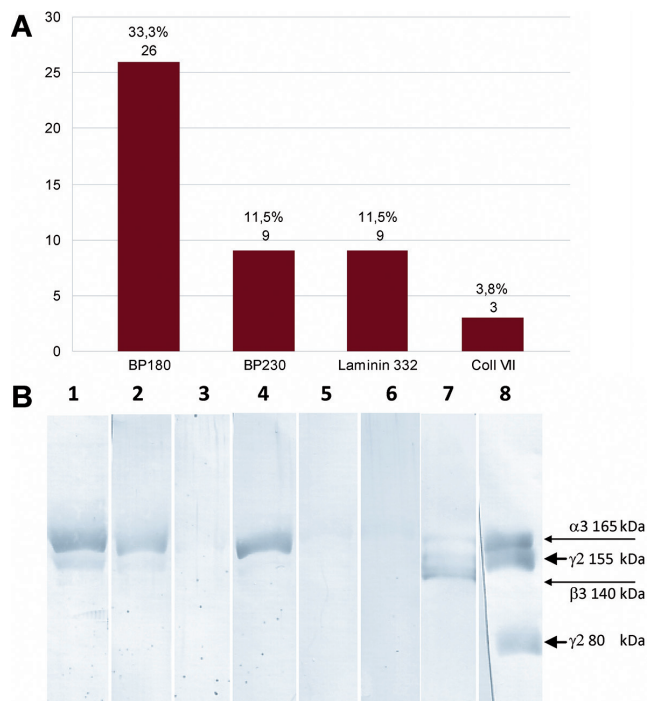


Fig. 1. Mucous membrane pemphigoid (MMP) sera reactivity profile. (A) BP180 enzyme-linked immunoassay (ELISA) was positive in 26 patients (33%); 9 patients (11.5%) were positive by BP230 ELISA and 3 (3.8%) by collagen VII ELISA. Immunoglobulin G (IgG) reactivity to purified laminin 332 by immunoblotting analysis was found in 9 out of 78 patients' sera (11.5%). (B) Immunoblotting of some representative positive (#40, #76, #24 in lanes 1, 2, 4, respectively), negative patient sera (#7 in lane 3) and normal sera (lanes 5, 6) against affinity purified laminin 332. Monoclonal antibodies K140 (lane 7), BM165 and U46 (lane 8) bind β 3 and α 3 and γ 2 chain, respectively.

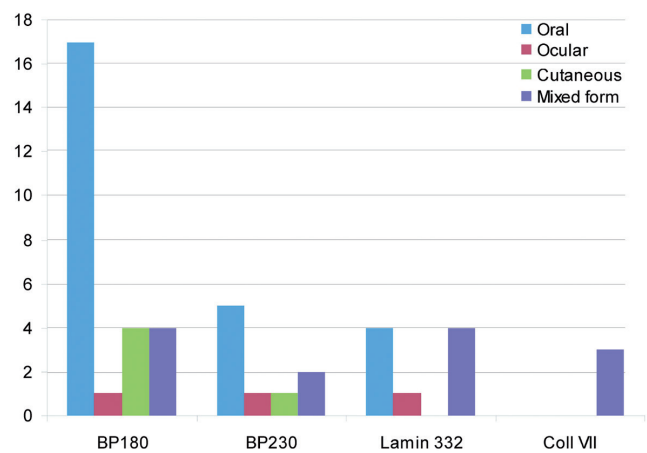


Fig. 2. Relationship between target antigen and mucous membrane pemphigoid (MMP) clinical variant. Out of 26 BP180-positive patients 17 had OR-MMP variant, 1 had an OC-MMP variant, 4 had BP-MMP type and 4 a mixed variant (OR/BP-MMP; OR/NP-MMP; OR/G-MMP; OR/NP/BP-MMP). Out of 9 BP230-positive patients, 5 had OR-MMP, 1 an OC-MMP, 1 had BP-MMP type and 2 a mixed form (OR/BP-MMP; OR/NP-MMP). Of 9 laminin-332-positive patients, 4 had an OR-MMP, 1 had an OC-MMP and 4 a mixed form (2 OR/OC-MMP; 1 OR/NP/G-MMP; 1 OC/BP/NP-MMP). All 3 collagen VII-positive patients presented a mixed form (OR/NP-MMP; OR/NP/BP-MMP; OC/BP/G-MMP).

score ($p=0.025$) (data not shown). On the other hand, all 3 Col VII-positive patients presented a mixed form (OR/NP; OR/NP/BP; OC/BP/G) with the involvement of multiple mucosal sites, also showing a significant association with severity score ($p=0.020$) (data not shown). Finally, no significant association was found between disease severity score, clinical variant and reactivity against BP230 or laminin 332.

DISCUSSION

In patients with a severe form of MMP, timely diagnosis and appropriate treatment are essential. The laboratory diagnosis of MMP relies mainly on the detection of tissue-bound autoantibodies by DIF and the demonstration of serum autoantibodies binding to the BMZ component using IIF-SSS and/or antigen-based ELISAs. Chan and co-workers (1), in the first international consensus on MMP, assert that MMP also includes mucous membrane-dominant epidermolysis bullosa acquisita and linear IgA bullous dermatosis with preferential mucous membrane involvement. The consensus underlines the supremacy of the clinical picture (predominant mucosal involvement) over the immunological features, also considering "the principle that MMP can no longer be defined by a specific target antigen because multiple antigens have been identified by the autoantibodies of this group of patients" (1).

The present study: (i) characterized the autoantibody profile of 78 Italian patients with MMP; (ii) confirmed that BP180 is the major autoantigen of MMP patients with oral and cutaneous involvement; (iii) and identified BP180 reactivity as an inverse marker of disease severity.

To our knowledge, this is the largest Italian cohort of MMP patients that has been investigated clinically and serologically. To assess disease severity, the Setterfield score was employed, as it was considered more suitable to our purposes than other existing MMP outcome methods, particularly considering the predominance of oral involvement in our cohort. More recently, another scoring system has been proposed, but it was not available at the time of completion of the present study (22). We showed that 45 out of 78 MMPs (58%) had IgG and/or IgA that reacted with epidermal and/or dermal side of salt-split skin by IIF-SSS, confirming that this technique is the most sensitive approach to detect autoantibodies in patients with MMP. In contrast, standard MO IIF should probably be abandoned for assessing patients with MMP.

In contrast with a previous study, in our cohort the presence of both circulating IgG and IgA anti-BMZ antibodies by IIF was not associated with more severe disease ($p=0.563$, data not shown) (18), suggesting that IIF-SSS results are not helpful to predict the clinical severity of MMP.

Longitudinal studies of a cohort of patients with positivity against laminin 332 suggested that this form is

associated with an increased relative risk of solid cancers (23, 24). In contrast, a recent study did not confirm these results, showing that the presence of solid tumours and lymphomas was not higher in patients with anti-laminin 332 autoantibodies (11). In the present study no significant correlation was found between laminin 332 reactivity and the proportion of patients with an associated internal cancer. The reported frequency of reactivity to laminin 332 in patients with MMP ranged from 18% to 30% (11, 25–29). In our cohort of MMP patients, 9 of 78 (11, 5%) reacted to laminin 332, and 4 of 9 were negative by IIF-SSS, demonstrating that, in these MMP patients, immunoblotting on affinity-purified laminin 332 is more sensitive than IIF-SSS. These data are in line with a recent study showing that almost half of MMP sera that were found to be positive for anti-laminin 332 antibodies by ELISA were negative by IIF-SSS (11). Moreover, data from our study and from the study by Bernard et al. (11) clearly suggest that, despite IIF-SSS being the most sensitive first-line serological test for detecting circulating autoantibodies in MMP, it is probably less helpful than originally thought for predicting laminin 332 positivity. All 3 chains of laminin 332 have been shown to be bound by MMP sera; however, according with previously reported data the $\alpha 3$ subunit is the most-recognized chain of laminin 332 in our cohort of patients (10). Of note, there was no significant relationship between laminin 332 positivity, disease severity and clinical variant.

Since the interaction between laminin 332 and BP180 has a crucial role in dermal-epidermal and chorio-epidermal adhesion (15, 16, 30, 31), autoantibodies against laminin 332 and/or BP180 may contribute to the pathogenesis of MMP by interfering with this adhesion complex. In this context, we have shown that 33% of patients with MMP possessed circulating autoantibodies against the BP180 molecule (specifically, its immunodominant region NC16A used as antigen in the commercial ELISA), indicating a role of this protein in the pathogenesis of MMP. Interestingly, Oyama and co-workers have shown a higher reactivity (75% of MMP sera) against the entire BP180 antigen, further confirming that regions other than NC16A may be recognized by MMP autoantibodies (5–7). In particular, a frequent reactivity of MMP patients' autoantibodies against the C-terminal portion of BP180 has been reported, the reason for which is unknown (3, 7). The observation that patients with oral pemphigoid without scarring phenotype frequently react to the C-terminal portion of BP180 challenged the possible relation of this reactivity with the scarring phenotype (7).

The significant correlation between BP180 reactivity and exclusive cutaneous and/or oral involvement is in line with previous studies in which reactivity against NC16A was mainly found in a cohort of MMP patients with exclusively oral involvement and MMP patients

with skin involvement (3, 7). In this context, the inverse correlation between BP180 reactivity and disease severity might provide a predictive marker relevant for the management of the patients, and challenge the hypothesis about the possible role of BP180 autoantibodies in the pathogenesis of MMP.

Antigens targeted by IgG autoantibodies in MMP included BP230 (6, 7, 11). In our cohort, 11.5% of patients with MMP recognized BP230 and, interestingly, almost in all cases reacted also to BP180. In a previous study on patients with BP, an autoimmune bullous disease characterized by a predominantly cutaneous involvement, Di Zenzo and co-workers (32) have demonstrated that IgG autoantibodies first targeted the BP180 ectodomain and only subsequently recognized BP230. In the light of these findings it could be postulated that in these patients with MMP an intermolecular epitope spreading phenomenon occurred. In particular, an initial immune response against the extracellular immunodominant epitope of BP180 could induce tissue damage that eventually leads to disease progression associated with further IgG recognition of an intracellular antigen, BP230. In this context, even if never reported for patients with MMP, the detected anti-Col VII reactivity could also be due to an epitope spreading phenomenon, at least, in 2 of 3 Col VII-positive patients, which also targeted BP180 and BP230 (33, 34). The remaining case with exclusive reactivity against Col VII represents an epidermolysis bullosa acquisita with predominantly mucosal involvement (skin, genital and ocular) and scar formation. In these patients, the Col VII reactivity appears to be significantly related to disease severity, showing a role of such autoantibodies in the disease pathogenesis. Interestingly, a number of MMP sera (29%), higher than previously reported in a limited cohort of Japanese patients with MMP (13%) (35), showed IgG and/or IgA that reacted with both epidermal and dermal side of salt-split skin by IIF. This finding could suggest that Italian patients with MMP may have autoantibodies to multiple antigens residing in both epidermal and dermal sides. To confirm a possible racial difference between Japanese and Italian patients further studies are needed on larger cohorts.

One of the major limitations of our study was that we employed only the most well-established diagnostic procedure, such as ELISAs based on BP180, BP230 and Col VII and immunoblotting on affinity purified laminin 332. However, other antigens ($\alpha 6$, $\beta 4$) have been reported to be targeted by MMP autoantibodies (6, 8, 9) and should be investigated in further studies. In accordance with Hayakawa et al. (35) suggesting that a combination of immunological testing for circulating autoantibodies is useful for the diagnosis of MMP, and in light of our findings, we can draw an algorithm for the efficient serological diagnosis of MMP. In particular, in patients with positive DIF we suggest performing IIF-SSS that could provide an

IgA- and/or IgG-positive result in 58% of cases. Of note, in the presence of a typical clinical picture and negative DIF also after a second biopsy, further immunological studies may be necessary and could represent surrogate markers for diagnosis (36, 37). Secondly, the use of commercially available ELISAs, that are simple, rapid, give quantitative results and require a small amount of serum, could be important to detect autoantibody reactivity in IIF-negative sera or could also have a confirmatory role. Specifically, the most efficient hierarchy process involves performing a BP180 ELISA, which is positive in 33% of patients, and IB/ELISA on integrin $\alpha 6$, $\beta 4$ and C-terminal domain of BP180 antigen, which has been reported positive especially in MMP patients with oral, ocular involvement and with scarring phenotype, respectively (3, 8, 9). Thereafter, IB on laminin 332 that yields positive in 11.5% of patients or laminin 332 ELISA, even if not available in most laboratories, should be performed. MMP sera that are negative for IIF, as well as for BP180, $\alpha 6\beta 4$ integrin and laminin 332 ELISA, should be tested with Col VII ELISA (which is positive

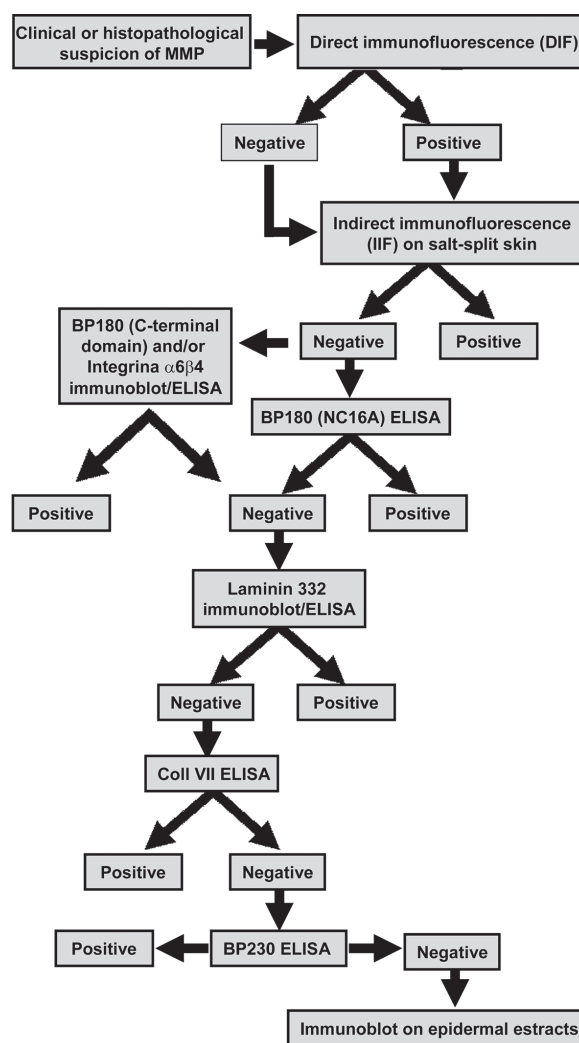


Fig. 3. Mucous membrane pemphigoid serological algorithm.

in 4% of patients). BP230 ELISA, which was found to be positive in 9 sera in our study, representing the sole positive test in only one of them, should be performed as the final diagnostic assay in doubtful cases that have negative results in the other tests. Since the combined sensitivity of these assays is 77% (without considering the BP180 C-terminal domain and $\alpha 6\beta 4$ reactivity not analysed in the present study), the remaining patients who were not positive in any diagnostic procedure used (i.e. in the present study 18 out of the 78 patients with MMP) could be analysed by immunoblot on epithelial extracts to detect other possible target antigens (Fig. 3). Further studies are needed to evaluate the possible advantages of the use of commercially available diagnostic procedures based on multiple antigens (38).

ACKNOWLEDGEMENTS

The authors acknowledge the support of the Italian Ministry of Health (Ricerca Corrente 2014–2015).

The authors declare no conflicts of interest.

REFERENCES

- Chan LS, Ahmed AR, Anhalt GJ, Bernauer W, Cooper KD, Elder MJ, et al. The first international consensus on mucous membrane pemphigoid: definition, diagnostic criteria, pathogenic factors, medical treatment, and prognostic indicators. *Arch Dermatol* 2002; 138: 370–379.
- Di Zenzo G, Carrozzo M, Chan L. Urban legend series: mucous membrane pemphigoid. *Oral Dis* 2014; 20: 35–34.
- Balding SD, Prost C, Diaz LA, Bernard P, Bedane C, Aberdam D, et al. Cicatricial pemphigoid autoantibodies react with multiple sites on the BP180 extracellular domain. *J Invest Dermatol* 1996; 106: 141–146.
- Murakami H, Nishioka S, Setterfield J, Bhogal BS, Black MM, Zillikens D, et al. Analysis of antigens targeted by circulating IgG and IgA autoantibodies in 50 patients with cicatricial pemphigoid. *J Dermatol Sci* 1998; 17: 39–44.
- Schmidt E, Skrobek C, Kromminga A, Hashimoto T, Messer G, Bröcker EB, et al. Cicatricial pemphigoid: IgA and IgG autoantibodies target epitopes on both intra- and extracellular domains of bullous pemphigoid antigen 180. *Br J Dermatol* 2001; 145: 778–783.
- Oyama N, Setterfield JF, Powell AM, Sakuma-Oyama Y, Albert S, Bhogal BS, et al. Bullous pemphigoid antigen II (BP180) and its soluble extracellular domains are major autoantigens in mucous membrane pemphigoid: the pathogenic relevance to HLA class II alleles and disease severity. *Br J Dermatol* 2006; 154: 90–98.
- Calabresi V, Carrozzo M, Cozzani E, Arduino P, Bertolusso G, Tirone F, et al. Oral pemphigoid autoantibodies preferentially target BP180 ectodomain. *Clin Immunol* 2007; 122: 207–213.
- Bhol KC, Goss L, Kumari S, Colon JE, Ahmed AR. Autoantibodies to human $\alpha 6$ integrin in patients with oral pemphigoid. *J Dent Res* 2001; 80: 1711–1715.
- Bhol KC, Colon JE, Ahmed AR. Autoantibody in mucous membrane pemphigoid binds to an intracellular epitope on human $\beta 4$ integrin and causes basement membrane zone separation in oral mucosa in an organ culture model. *J Invest Dermatol* 2003; 120: 701–702.
- Lazarova Z, Salato VK, Lanschuetzer CM, Janson M, Fairley JA, Yancey KB. IgG anti laminin-332 autoantibodies are present in a subset of patients with mucous membrane, but not bullous, pemphigoid. *J Am Acad Dermatol* 2008; 58: 951–958.
- Bernard P, Antonicelli F, Bedane C, Joly P, Le Roux-Villet C, Duvert-Lehembre S, et al. Prevalence and clinical significance of anti-laminin 332 autoantibodies detected by a novel enzyme-linked immunosorbent assay in mucous membrane pemphigoid. *JAMA Dermatol* 2013; 149: 533–540.
- Borradori L, Koch PJ, Niessen CM, Erkeland S, van Leusden MR, Sonnenberg A. The localization of bullous pemphigoid antigen 180 (BP180) in hemidesmosomes is mediated by its cytoplasmic domain and seems to be regulated by the $\beta 4$ integrin subunit. *J Cell Biol* 1997; 136: 1333–1347.
- Fontao L, Favre B, Riou S, Geerts D, Jaunin F, Saurat JH, et al. Interaction of the bullous pemphigoid antigen 1 (BP230) and desmoplakin with intermediate filaments is mediated by distinct sequences within their COOH terminus. *Mol Biol Cell* 2003; 14: 1978–1992.
- Tsuruta D, Hashimoto T, Hamill KJ, Jones JC. Hemidesmosomes and focal contact proteins: functions and cross-talk in keratinocytes, bullous diseases and wound healing. *J Dermatol Sci* 2011; 62: 1–7.
- Nishie W, Kiritsi D, Nyström A, Hofmann SC, Bruckner-Tuderman L. Dynamic interactions of epidermal collagen XVII with the extracellular matrix: laminin 332 as a major binding partner. *Am J Pathol* 2011; 179: 829–837.
- Van den Bergh F, Eliason SL, Giudice GJ. Type XVII collagen (BP180) can function as a cell-matrix adhesion molecule via binding to laminin 332. *Matrix Biol* 2011; 30: 100–108.
- Lazarova Z, Yee C, Darling T, Briggaman RA, Yancey KB. Passive transfer of anti-laminin 5 antibodies induces subepidermal blisters in neonatal mice. *J Clin Invest* 1996; 98: 1509–1518.
- Setterfield J, Shirlaw PJ, Kerr-Muir M, Neill S, Bhogal BS, Morgan P, et al. Mucous membrane pemphigoid: a dual circulating antibody response with IgG and IgA signifies a more severe and persistent disease. *Br J Dermatol* 1998; 138: 602–610.
- Marinkovich MP, Lunstrum GP, Burgeson RE. The anchoring filament protein kalinin is synthesized and secreted as a high molecular weight precursor. *J Biol Chem* 1992; 267: 17900–17906.
- Di Zenzo G, El Hachem M, Diociaiuti A, Boldrini R, Calabresi V, Cianfarani F, et al. A truncating mutation in the laminin-332 α chain highlights the role of the LG45 proteolytic domain in regulating keratinocyte adhesion and migration. *Br J Dermatol* 2014; 168: 1205–1214.
- Scully C, Carrozzo M, Gandolfo S, Puiatti P, Monteil R. Update on mucous membrane pemphigoid: a heterogeneous immune-mediated subepithelial blistering entity. *Oral Surg Oral Med Oral Pathol Oral Radiol Endod* 1999; 88: 56–58.
- Murrell DF, Marinovic B, Caux F, Prost C, Ahmed R, Wozniak K, et al. Definitions and outcome measures for mucous membrane pemphigoid: recommendations of an international panel of experts. *J Am Acad Dermatol* 2015; 72: 168–174.
- Egan CA, Lazarova Z, Darling TN, Yee C, Coté T, Yancey KB. Anti-epiligrin cicatricial pemphigoid and relative risk for cancer. *Lancet* 2001; 357: 1850–1851.
- Egan CA, Lazarova Z, Darling TN, Yee C, Yancey KB. Anti-epiligrin cicatricial pemphigoid: clinical findings, immunopathogenesis, and significant associations. *Medicine (Baltimore)* 2003; 82: 177–186.
- Chan LS, Yancey KB, Hammerberg C, Soong HK, Regezi

- JA, Johnson K, et al. Immune-mediated subepithelial blistering diseases of mucous membranes: pure ocular cicatricial pemphigoid is a unique clinical and immunopathological entity distinct from bullous pemphigoid and other subsets identified by antigenic specificity of autoantibodies. *Arch Dermatol* 1993; 129: 448–455.
26. Ghohestani RF, Nicolas JF, Rousselle P, Claudy AL. Diagnostic value of indirect immunofluorescence on sodium chloride-split skin in differential diagnosis of subepidermal autoimmune bullous dermatoses. *Arch Dermatol* 1997; 133: 1102–1107.
 27. Leverkus M, Schmidt E, Lazarova Z, Bröcker EB, Yancey KB, Zillikens D. Antiepiligrin cicatricial pemphigoid: an underdiagnosed entity within the spectrum of scarring autoimmune subepidermal bullous diseases? *Arch Dermatol* 1999; 135: 1091–1098.
 28. Yeh SW, Usman AQ, Ahmed AR. Profile of autoantibody to basement membrane zone proteins in patients with mucous membrane pemphigoid: long-term follow up and influence of therapy. *Clin Immunol* 2004; 112: 268–272.
 29. Grootenboer-Mignot S, Descamps V, Picard-Dahan C, Nicaise-Roland P, Prost-Squarcioni C, Leroux-Villet C, et al. Place of human amniotic membrane immunoblotting in the diagnosis of autoimmune bullous dermatoses. *Br J Dermatol* 2010; 162: 743–750.
 30. Borradori L, Sonnenberg A. Structure and function of hemidesmosomes: more than simple adhesion complexes. *J Invest Dermatol* 1999; 112: 411–418.
 31. Nievers MG, Kuikman I, Geerts D, Leigh IM, Sonnenberg A. Formation of hemidesmosome-like structures in the absence of ligand binding by the $(\alpha)6(\beta)4$ integrin requires binding of HD1/plectin to the cytoplasmic domain of the $(\beta)4$ integrin subunit. *J Cell Sci* 2000; 113: 963–973.
 32. Di Zenzo G, Thoma-Uszynski S, Calabresi V, Fontao L, Hofmann SC, Lacour JP, et al. Demonstration of epitope spreading phenomena in bullous pemphigoid: results of a prospective multicenter study. *J Invest Dermatol* 2011; 131: 2271–2280.
 33. Yang B, Wang C, Wu M, Du D, Yan X, Zhou G, et al. A case of pemphigoid gestationis with concurrent IgG antibodies to BP180, BP230 and type VII collagen. *Australas J Dermatol* 2014; 55: 15–18.
 34. Sakaguchi M, Bito T, Oda Y, Kikusawa A, Nishigori C, Munetsugu T, et al. Three cases of linear IgA/IgG bullous dermatosis showing IgA and IgG reactivity with multiple antigens, particularly laminin-332. *JAMA Dermatol* 2013; 149: 1308–1313.
 35. Hayakawa T, Furumura M, Fukano H, Li X, Ishii N, Hamada T, et al. Diagnosis of oral mucous membrane pemphigoid by means of combined serologic testing. *Oral Surg Oral Med Oral Pathol Oral Radiol* 2014; 117: 483–496.
 36. Carrozzo M, Arduino PG, Baldovino S, Di Zenzo G, Salzano S, Calabresi V, Roccatello D. Minocycline in combination with mycophenolate mofetil in oral mucous membrane pemphigoid. *Eur J Dermatol* 2008; 18: 198–200.
 37. Bagan J, Lo Muzio L, Scully C. Mucosal disease series. Number III. Mucous membrane pemphigoid. *Oral Dis* 2005; 11: 197–218.
 38. van Beek N, Rentzsch K, Probst C, Komorowski L, Kasperkiewicz M, Fechner K, et al. Serological diagnosis of autoimmune bullous skin diseases: prospective comparison of the BIOCHIP mosaic-based indirect immunofluorescence technique with the conventional multi-step single test strategy. *Orphanet J Rare Dis* 2012; 7: 49.