

AperTO - Archivio Istituzionale Open Access dell'Università di Torino

**A novel homozygous change of CLCN2 (p.His590Pro) is associated with a subclinical form of leukoencephalopathy with ataxia (LKPAT)**

**This is the author's manuscript**

*Original Citation:*

*Availability:*

This version is available <http://hdl.handle.net/2318/1637344> since 2017-10-25T16:29:50Z

*Published version:*

DOI:10.1136/jnnp-2016-315525

*Terms of use:*

Open Access

Anyone can freely access the full text of works made available as "Open Access". Works made available under a Creative Commons license can be used according to the terms and conditions of said license. Use of all other works requires consent of the right holder (author or publisher) if not exempted from copyright protection by the applicable law.

(Article begins on next page)



# UNIVERSITÀ DEGLI STUDI DI TORINO

***This is an author version of the contribution published on:***

*Questa è la versione dell'autore dell'opera:*

*[J Neurol Neurosurg Psychiatry. 2017 Oct;88(10):894-896. doi: 10.1136/jnnp-2016-315525.]*

***The definitive version is available at:***

*La versione definitiva è disponibile alla URL:*

*[<http://jnnp.bmj.com/content/88/10/894.long>]*

A novel homozygous change of *CLCN2* (p.His590Pro) is associated with a subclinical form of Leukoencephalopathy with Ataxia (LKPAT).

Elisa Giorgio<sup>1\*</sup>, Giovanna Vaula<sup>2\*</sup>, Paolo Benna<sup>3,4</sup>, Nicola Lo Buono<sup>5</sup>, Chiara Maria Eandi<sup>6</sup>, Dino Daniele<sup>7</sup>, Cecilia Mancini<sup>1</sup>, Simona Cavalieri<sup>8</sup>, Eleonora Di Gregorio<sup>8</sup>, Elisa Pozzi<sup>1</sup>, Marta Ferrero<sup>1</sup>, Maria Teresa Giordana<sup>2,3</sup>, Christel Depienne<sup>9,10</sup>, Alfredo Brusco<sup>1,8</sup>

\* These authors equally contributed to this work.

<sup>1</sup> University of Torino, Department of Medical Sciences, Medical Genetics Unit, 10126, Torino, Italy

<sup>2</sup> Città della Salute e della Scienza University Hospital, Neurology 1, 10126, Torino, Italy

<sup>3</sup> University of Torino, Department of Neuroscience "Rita Levi Montalcini", 10126, Torino, Italy

<sup>4</sup> Città della Salute e della Scienza University Hospital, Department of Neuroscience and Mental Health, 10126, Torino, Italy

<sup>5</sup> University of Torino, Department of Medical Sciences, Laboratory of Immunogenetics, 10126, Torino, Italy

<sup>6</sup> University of Torino, Department of Surgical Science, Eye Clinic, 10126 Torino Italy

<sup>7</sup> Città della Salute e della Scienza University Hospital, Department of Neurosciences, Neuroradiology Unit, 10126, Torino, Italy

<sup>8</sup> Città della Salute e della Scienza University Hospital, Medical Genetics Unit, 10126, Torino, Italy

<sup>9</sup> Département de Médecine translationnelle et Neurogénétique, IGBMC, CNRS UMR 7104/INSERM U964/Université de Strasbourg, 67400 Illkirch, France.

<sup>10</sup> Laboratoire de cytogénétique, Institut de génétique médicale d'Alsace, Hôpitaux Universitaires de Strasbourg, 67000 Strasbourg, France.

Key words: *CLCN2*, *CLC-2*, leukoencephalopathy, LKPAT, intramyelinic edema

Corresponding author: Alfredo Brusco, University of Torino, Department of Medical Sciences, via Santena 19, 10126, Torino, Italy. Fax +390116706582; e-mail: [alfredo.brusco@unito.it](mailto:alfredo.brusco@unito.it)

Conflict of interest: none to declare

CLC-2 is a plasma membrane chloride channel with widespread expression in the human body, including the brain. Its function is still being studied, although it is thought to have a role in ion and water homeostasis in the brain. CLC-2 is part of a complex containing GlialCAM and MLC1. Both these genes are associated with autosomal recessive human leukodystrophies with intramyelinic edema. Biallelic mutations in CLCN2, encoding the CLC-2 channel, have been reported in patients with a rare form of Leukoencephalopathy with Ataxia (LKPAT; MIM # 615651). No peculiar neurological features have been reported for this disease, although slight visual impairment due to chorioretinopathy or optic atrophy, mild ataxia, learning disabilities and headaches are recurrent symptoms in patients. However, MRI shows a typical diagnostic pattern that consists of white matter signal abnormalities in the posterior limbs of the internal capsules, cerebral peduncles, pontine pyramidal tracts and in the middle cerebellar peduncles, associated with lower Apparent Diffusion Coefficient (ADC) values in most cases. Specific anomalies of Brainstem Auditory Evoked Potentials (BAEP) have also been described [1-3].

Here, we report on a 52 year-old Moroccan woman presenting with mild and asymptomatic bilateral optic atrophy detected at a routine ophthalmological examination for presbyopia. Best-corrected high-contrast visual acuity was 20/20 in both eyes. Anterior segment and intraocular pressures were normal, and pupillary reflexes were present. Upon fundus biomicroscopy, mild pallor and excavation of the optic disc were evident in both eyes. Moreover, in her left eye, myelinated retinal nerve fibers were present, while her right eye was normal (Figure 1). No alterations were evident upon examination with optical coherence tomography (Supplementary Figure 1) or fundus autofluorescence in either eye. A chronic simple glaucoma and retinal vessel pathology were excluded. Her familial and personal clinical history was unremarkable, apart from a moderate headache, and blood exams were normal. The neurological examination was normal except for bilateral mild optic disc pallor at

funduscopy (Figure 1). At the neurophysiological study, a normal latency and amplitude of the visual evoked potential (VEP) responses were documented, while BAEPs were characterized by a marked increase in the III-V interval, representative of ponto-mesencephalic conduction time, a normal latency of I wave, normal I-III interval values, and V wave amplitude (Supplementary Figure 2). MRI displayed an unusual pattern of symmetrical white matter anomalies suggestive of LKPAT (Figure 1A). Post contrast MRI did not demonstrate any enhancement.

Informed consent was obtained from the patient, and the Internal Review Board committee of the Department of Medical Sciences (University of Turin) approved this study. We analyzed all coding exons and flanking intron boundaries of CLCN2 (NM\_004366) by PCR amplification of blood-extracted genomic DNA (Qiagen, Mannheim, Germany; conditions available upon request), followed by Sanger sequencing (Life Technologies, Carlsbad, CA, USA). We identified the homozygous c.1769A>C (p.His590Pro) missense variant in exon 16 (Figure 1B). This change was not reported in any genetic database (ExAC v.0.3.1, dbSNPs147), and was shown to affect a highly conserved residue (Figure 1C), predicted to be pathogenic based on bioinformatics analyses (SIFT, PolyPhen2, I-Mutant, Mutation taster, PHD-SNP, SNAP-F; Table 1). To ascertain the role of this mutation on the protein, we compared the subcellular localization of the wild type and mutated ClC-2 protein after transient transfection of VERO cells with the V5-His6-tagged ClC-2 expression plasmid [1]. We demonstrated that the p.His590Pro ClC-2 protein barely reaches the plasma membrane and accumulates within the endoplasmic reticulum, with a pattern similar to the positive control plasmid carrying the known pathogenic p.Ala500Val variant (Figure 1D) [1]. These *in vitro* findings corroborate a pathogenic role for the p.His590Pro missense change.

There have only been eight LKPAT patients described in the literature (Supplementary Table 2). Depienne et al. reported six unrelated cases with homozygous or compound heterozygous mutations in

the *CLCN2* gene [1]. A subclinical form of leukodystrophy associated with infertility was also reported in a man with a novel homozygous *CLCN2* mutation [2]. More recently, Hanagasi et al. described a 22 year-old woman with paroxysmal kinesigenic dyskinesia due to a homozygous *CLCN2* mutation [3]. Our case resembles other LKPAT cases, characterized by a very mild clinical phenotype despite a clear MRI abnormality involving the pyramidal tracts. This clinical/radiological discrepancy suggests that white matter anomalies could cause intramyelinic edema, which does not impair the axonal function. Conversely, the compromised chloride channel function may be harmful for the visual and auditory systems, as suggested by the optic atrophy and the BAEP anomalies found in our patient, as well as in the animal model of the disease [4]. The animal model displays a “pure” slowing conduction with preservation of the synchronous activation of potential generators. This pattern is distinct from those observed in the vast majority of genetic or acquired myelin pathologies in which slowing conduction and potential dispersion occur concomitantly. Moreover, myelin disorders are usually characterized by a prevalent slowing conduction in the I-III interval, both in murine models of myelination defects [5] and in human leukodystrophies.

However, a selective increase in the III-V interval is far more common in acquired disorders that determine a brainstem focal lesion.

In conclusion, we report on a novel case of subclinical leukodystrophy associated with *CLCN2* mutations. Our case confirms the extreme variable clinical presentation of LKPAT and emphasizes the importance of recognizing specific MRI patterns as a guidance to genetic tests in adult leukoencephalopathies.

## Figure legends

### Figure 1. MRI, molecular and *in vitro* analyses.

**Panel A: MRI abnormalities.** FLAIR (1-3) and DWI (4-6) images show hyperintensity of the pyramidal tracts in the posterior limbs of internal capsules (arrowheads in 1, 4), midbrain cerebral peduncles (arrowheads in 2, 5), and middle cerebellar peduncles and pons (light green and light blue arrowheads, respectively, in 3, 6). No restriction at the ADC map was present (7-9). **Panel B: fundus biomicroscopy signs.** Mild pallor and excavation of the optic disc in both eyes (L and R) and myelinated retinal nerve fibers in the left eye (L). **Panel C: molecular analysis.** The p.His590Pro change is shown. **Panel D: *in vitro* studies.** Subcellular localization of the CIC-2 wild type (WT), p.Ala500Val (with a known pathogenic change [1]) and p.His590Pro variant proteins is shown (green). A marker of the endoplasmic reticulum (anti-calreticulin, red) was used to verify co-localization by confocal microscopy. Note that wild type CIC-2 protein typically reaches the plasma membrane, whereas both the CIC-2(p.Ala500Val) and CIC-2(p.His590Pro) proteins are retained in the endoplasmic reticulum. A 10X inset is shown. Scale bar = 25  $\mu$ M.

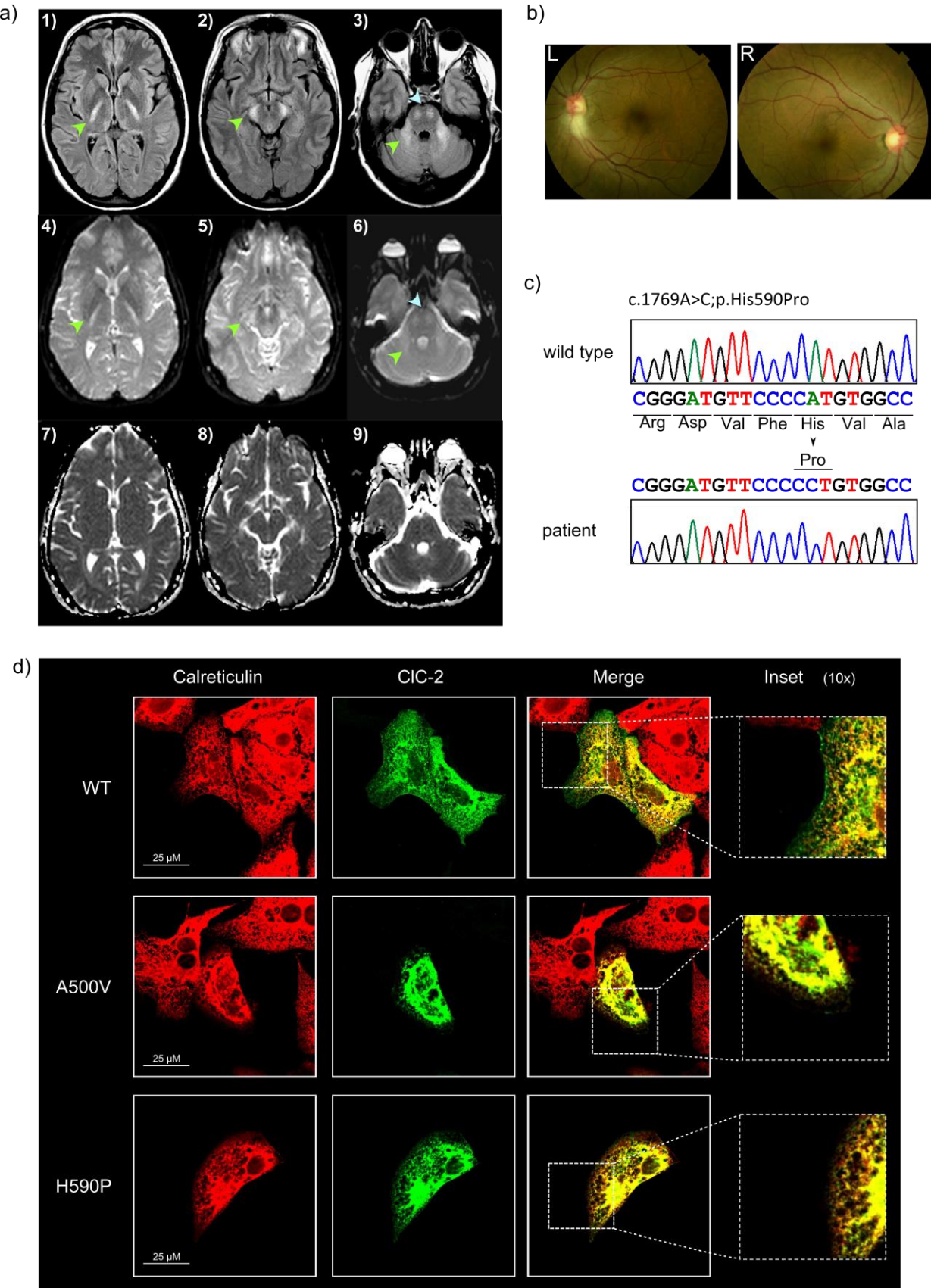
## Acknowledgements

We grateful acknowledge patient collaboration. This work was supported by MURST60% and Associazione “E.E. Rulfo per la Genetica Medica” (to A.B.).

## Bibliography

1. Depienne C, Bugiani M, Dupuits C, et al. Brain white matter oedema due to CLC-2 chloride channel deficiency: an observational analytical study. *Lancet Neurol* 2013;**12**(7):659-68.
2. Di Bella D, Pareyson D, Savoardo M, et al. Subclinical leukodystrophy and infertility in a man with a novel homozygous CLCN2 mutation. *Neurology* 2014;**83**(13):1217-8.
3. Hanagasi HA, Bilgic B, Abbink TE, et al. Secondary paroxysmal kinesigenic dyskinesia associated with CLCN2 gene mutation. *Parkinsonism Relat Disord* 2015;**21**(5):544-6.
4. Blanz J, Schweizer M, Auberson M, et al. Leukoencephalopathy upon disruption of the chloride channel CLC-2. *J Neurosci* 2007;**27**(24):6581-9.
5. Shah SN, Salamy A. Auditory-evoked far-field potentials in myelin deficient mutant quaking mice. *Neuroscience* 1980;**5**(12):2321-3.

Figure 1

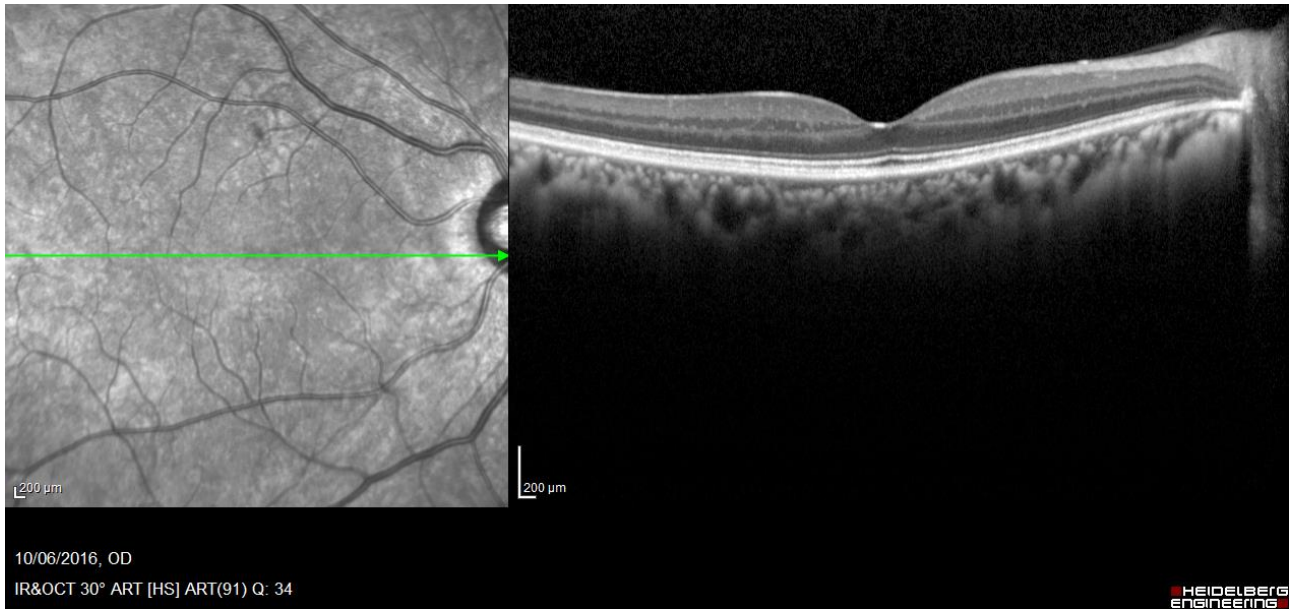




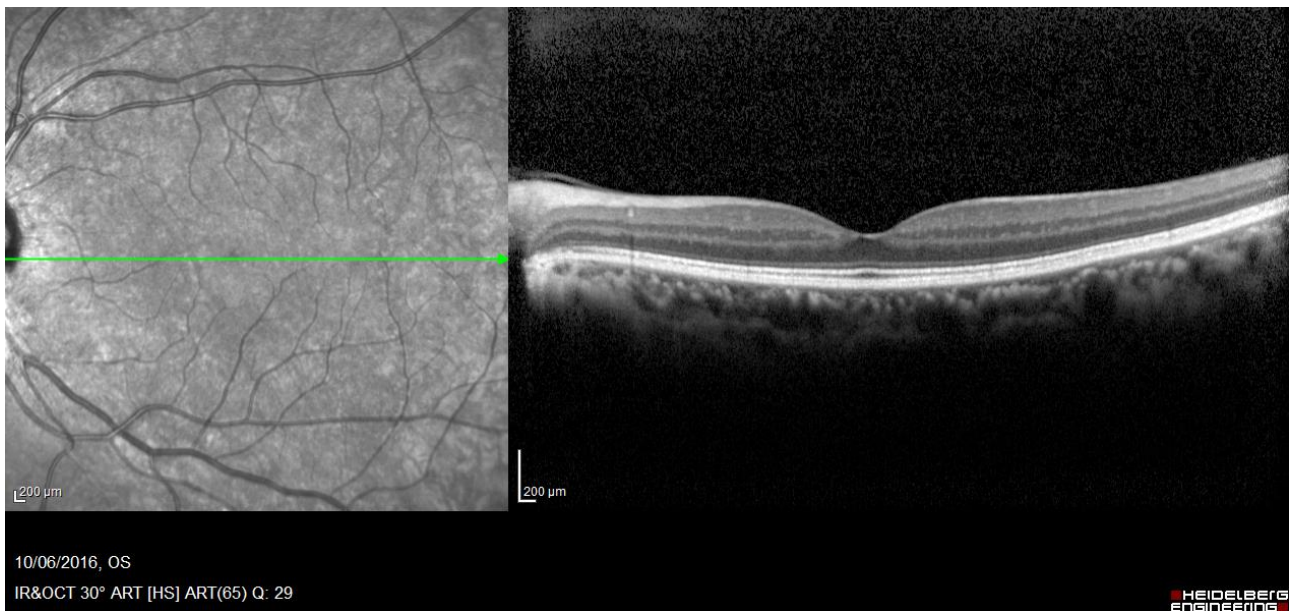
## Supplements

### Supplementary Figure 1: optical coherence tomography.

Right Eye: no alteration

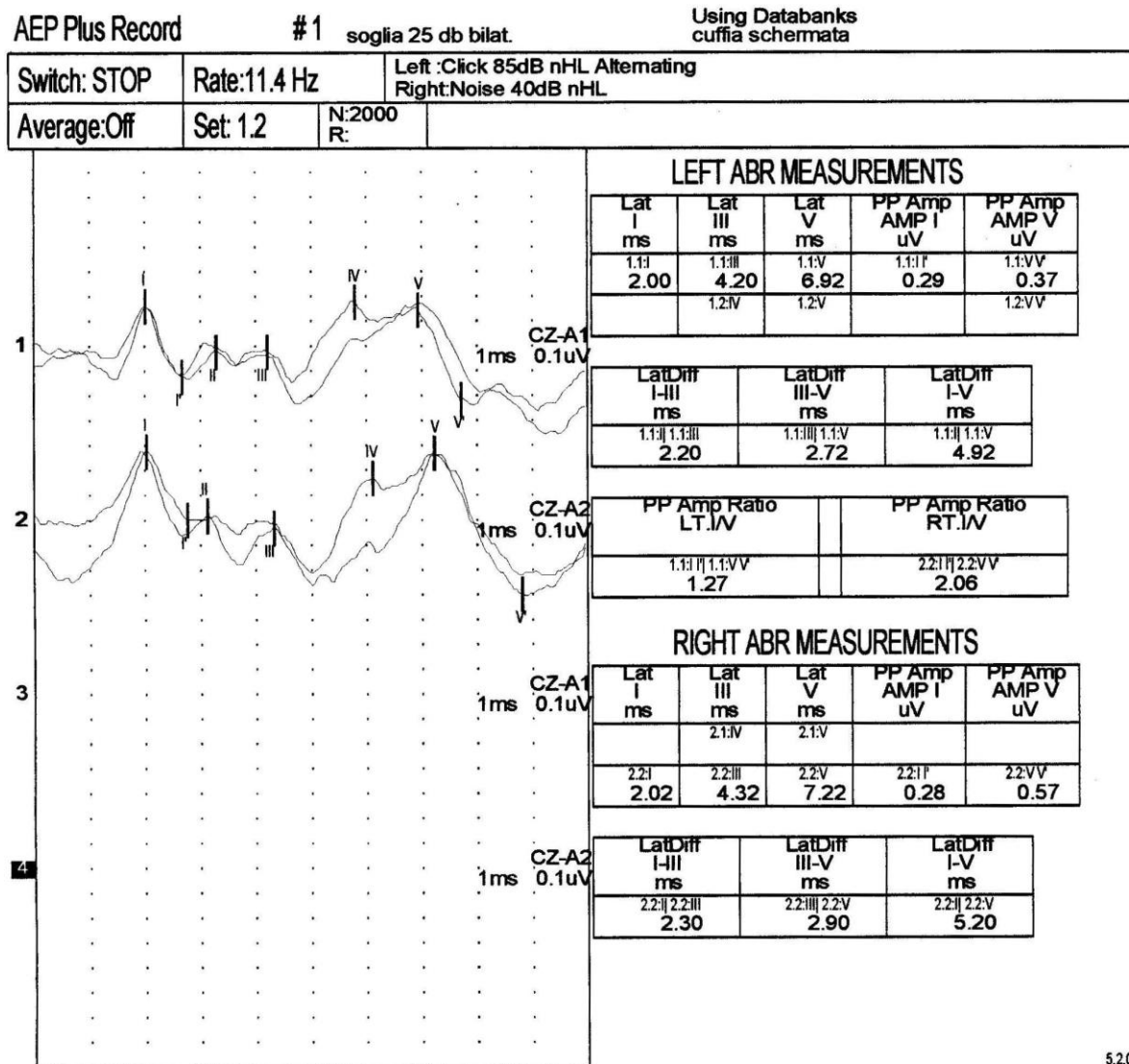


Left Eye: no alteration



## Supplementary Figure 2: BAEP and VEP findings.

BAEP: marked increase in the III-V interval



5.20h

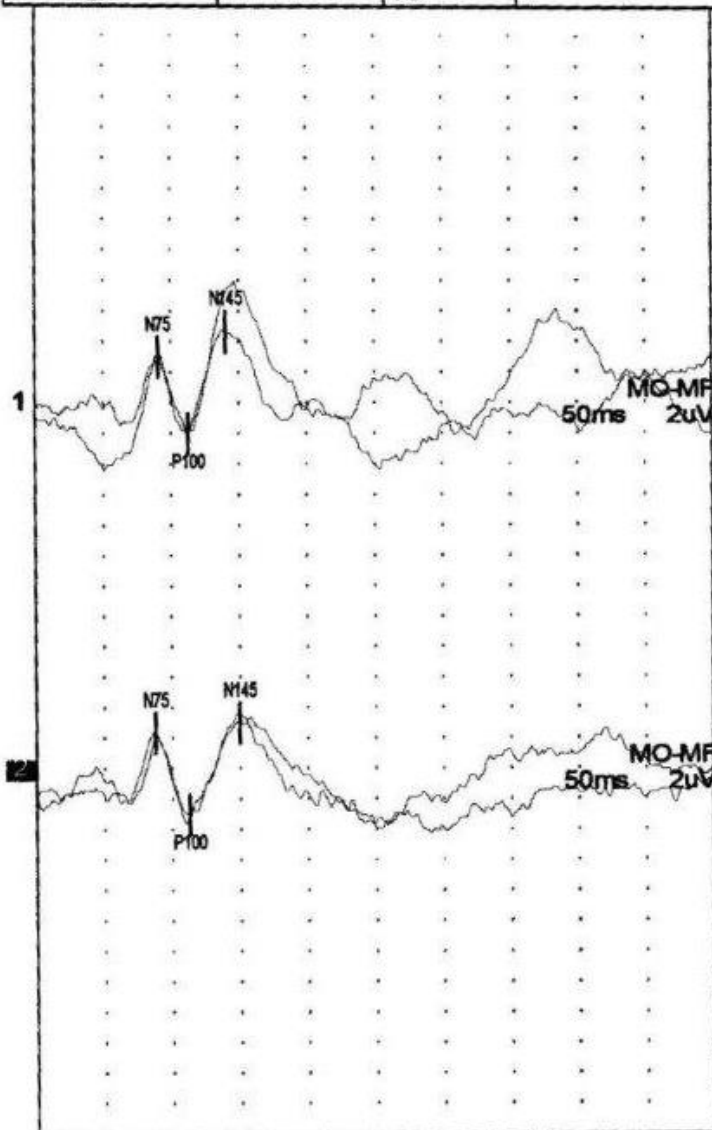
VEP: normal and symmetrical (P100) latency and amplitude.

VEP Plus Record

#1 Visual Angle=0.27'

1Ch PRVEP Master Montage  
216A & Databanks

Switch: STOP Rate: 1.6Hz 1015 Stimulator

Average: Off Set: 1.1 N: 100  
R:

## LEFT EYE MEASUREMENTS

Text	Lat N75 ms	Lat P100 ms	Lat N145 ms	PP Amp 75-100 uV
MO	1.1:N75 89.5	1.1:P100 112	1.1:N145 140	1.1:N75 P100 5.24

## RIGHT EYE MEASUREMENTS

Text	Lat N75 ms	Lat P100 ms	Lat N145 ms	PP Amp 75-100 uV
MO	2.1:N75 86.5	2.1:P100 112	2.1:N145 149	2.1:N75 P100 5.39

## INTEROCULAR MEASUREMENTS

Text	Lat Diff LT-RT ms	PP Amp Ratio LT-RT %
MO	1.1:P100  2.1:P100 0.50	1.1:N75 P100  2.1:N75 P100 103

Software	Information	Description	Value output	Bibliography
<b>SIFT</b>	Pathogenic or not predictor	damaging	0	Ng and Henikoff (2001)
<b>PolyPhen-2</b>	Pathogenic or not predictor	Possibly damaging	0.77	Adzhubei IA et al. (2010)
<b>I-Mutant</b>	Stability changes predictor	Increase stability	-0.01	Capriotti et al. (2005)
<b>Mutation Taster</b>	Pathogenic or not predictor	damaging	0.97	Schwarz et al. (2014)
<b>SNAP-F</b>	Pathogenic or not predictor	Non-neutral	3	Bromberg and Rost (2007)
<b>PHD-SNP</b>	Pathogenic or not predictor	Disease	5	Capriotti et al. (2006)

**Supplementary Table 1.** *In silico* prediction of variant pathogenicity and the evolutionary conservation among mammals of the histidine 590 residue using the “Multiz Alignment of 100 Vertebrates” track of the UCSC genome browser ([www.genome.ucsc.edu](http://www.genome.ucsc.edu))

	590
Human	DVP <b>H</b> VAL
Rhesus	DVP <b>H</b> VAL
Mouse	DVP <b>H</b> VAL
Rabbit	DVP <b>H</b> VAL
Cow	DVP <b>H</b> VAL
Elephant	DVP <b>H</b> VAL
Opossum	DVP <b>H</b> VAL

**Supplementary Table 2:** LKPAT patients described in the literature.

	Depienne et al., 2013 (1)	Depienne et al., 2013 (2)	Depienne et al., 2013 (3)	Depienne et al., 2013 (4)	Depienne et al., 2013 (5)	Depienne et al., 2013 (6)	Di Bella et al., 2014	Hanagasi et al., 2015	Our patient
<b>Gender/ ancestry</b>	F/North Africa	F/North Africa	F/North Africa	F/Europe	M/Europe	F/Europe	M/Europe	F/Middle East	F/ North Africa
<b>Age at first neurological sign</b>	44 yrs.	57 yrs.	30 yrs.	12 yrs.	6 yrs.	3 yrs.	42 yrs.	7 yrs.	52 yrs.
<b>Symptom at onset</b>	Action tremor Mild gait ataxia	Tinnitus Vertigo	Chorioretinopathy Psychosis	Learning disability Headache	Headache	Action tremor Mild gait ataxia	Postural hand tremor Palmomental reflex Increased deep tendon reflexes Bilateral Hoffman sign	Mild bilateral hand tremor	Presbiopia Headache
<b>Disease course</b>	Stable	Progressive	Stable	Stable	Stable	Stable	Stepwise	Stable	Stable
<b>Vision</b>	Normal	20/80 RE 20/400 LE	1/10 RE 1/50 LE	Normal with glasses	Normal with glasses Strabismus	Normal	Normal	Normal	Presbyopia
<b>Fundoscopy and optic nerve</b>	Normal	Retinoschisis Bilateral optic neuropathy	Retinal atrophy Choroidal neovascularisation Bilateral optic neuropathy	Normal	Normal	Normal	Normal	Normal	Bilateral mild pallor and excavation of the optic disc Myelinated retinal nerve fibers in left eye
<b>Hearing</b>	Normal	Perceptive hearing loss	Normal	Normal	Normal	Normal	Normal	Normal	Normal
<b>Pyramidal</b>	No	No	No	Mild spasticity	No	Mild spasticity	Increased deep tendon reflexes Bilateral Hoffman	No	No

signs							sign		
<b>Cerebellar signs</b>	Mild ataxia	Mild ataxia	Mild ataxia	Mild ataxia	Mild ataxia Nystagmus	Mild ataxia	Postural hand tremor	Mild dysmetria Dysidiadochokinesia	no
<b>Other neurological signs</b>							Palmomental reflex	Paroxysmal kinesigenic dyskinesia	
<b>Headhache</b>	No	No	Yes	Severe	Severe	No	No	No	Mild
<b>Other</b>							Azoospermia		