

AperTO - Archivio Istituzionale Open Access dell'Università di Torino

Dermoscopic features in canine dermatophytosis: some preliminary observations

This is the author's manuscript

Original Citation:

Availability:

This version is available <http://hdl.handle.net/2318/1647520> since 2017-09-11T16:47:18Z

Published version:

DOI:10.1111/vde.12407

Terms of use:

Open Access

Anyone can freely access the full text of works made available as "Open Access". Works made available under a Creative Commons license can be used according to the terms and conditions of said license. Use of all other works requires consent of the right holder (author or publisher) if not exempted from copyright protection by the applicable law.

(Article begins on next page)

This is the author's final version of the contribution published as:

Scarampella, Fabia; Zanna, Giordana; Peano, Andrea. Dermoscopic features in canine dermatophytosis: some preliminary observations. *VETERINARY DERMATOLOGY*. 28 (2) pp: 255-256.
DOI: 10.1111/vde.12407

The publisher's version is available at:

<http://onlinelibrary.wiley.com/doi/10.1111/vde.12407/fullpdf>

When citing, please refer to the published version.

Link to this full text:

<http://hdl.handle.net/>

Dermoscopic features in canine dermatophytosis: some preliminary observations

Fabia Scarpella*, **Giordana Zanna†** and **Andrea Peano‡**

*Studio Dermatologico Veterinario, via Sismondi 62,
20133 Milano, Italy

†Istituto Veterinario di Novara, S.P.9 Granozzo con
Monticello, 28060 Novara, Italy

‡Department of Veterinary Sciences, Parasitology
Section, University of Turin, Via Verdi 8, 10124 Torino, Italy

In cats, dermoscopy has been reported to be a potentially useful point-of-care test to identify infected hairs to sample for dermatophyte culture.¹ Indeed, comma-like hairs which appear as opaque, slightly curved, broken hairs characterized by an homogeneous thickness have been described as the main dermoscopic features in feline dermatophytosis due to *Microsporum canis* and *Microsporum gypsum*.^{1,2} Characteristic comma and corkscrew hairs are reported with both ectothrix and endothrix types of fungal invasion in human tinea capitis.^{3,4} Therefore, even while fungal culture remains the gold standard for the diagnosis of dermatophytosis, in both humans and animals, dermoscopy may assist in the initial clinical screening.⁵ To the best of the authors' knowledge, no study has investigated the usefulness of dermoscopy in helping to diagnose naturally occurring dermatophytosis in dogs. We report on six client-owned dogs presenting with multiple lesions of patchy alopecia due to *M. canis* infection that were evaluated with dermoscopy. All dogs presented with multifocal alopecia and variable amounts of scale (Fig. 1a,c,e,g,i,k). None of the dogs was reported to be pruritic. Two dogs were mongrels with a light short-haired coat, one was a Jack Russell terrier and one a French bulldog with a light smooth coat, and two were toy poodles, one with black and one with grey curly hair. There were three intact males and three intact females ranging in age from 3 to 60 months (mean 18 months). All dogs showed no abnormalities on physical examination and none had been treated with any local or systemic antimicrobial agent before the visit. Each alopecic lesion was evaluated with a Wood's lamp and dermoscopy. All procedures were well tolerated and no restraint or sedation was required. Dermoscopy of skin lesions was performed at 10-fold magnification with a nonpolarized dermoscope (Heine Delta 20, Heine Optotechnik GmbH & Co. KG; Herrsching, Germany). The glass plate of the dermoscope was applied to the lesion without immersion fluid and the images were captured in JPEG format. The dermoscope's contact plate was cleaned and disinfected with quaternary ammonium compounds (Microbac_ Tissues, Paul Hartmann AG; Heidenheim, Germany) to prevent contamination. Broken hairs were plucked from the lesions and submitted for fungal culture and microscopic examination. Where present, fluorescent hairs and comma-like structures were selected. Wood's lamp examination was positive in three dogs (two with short hair and one with a smooth coat). *Microsporum canis* infection was confirmed in all six dogs. The most common findings observed with dermoscopy were opaque, broken hairs characterized by a sharp, slanting end and homogeneous thickness (five of six dogs), and large white/yellow scales (six of six dogs) (Fig. 1).

Microscopic examination of the glowing hairs seen on Wood's lamp examination allowed the visualization of hyphae and spores along the hair shafts in the three positive dogs. Microscopic examination of the comma-like structures confirmed the presence of hyphae and spores along the hair shaft including two infected dogs that were negative on Wood's lamp examination. Wood's lamp and dermoscopy were both negative in the toy poodle with grey curly coat. In this dog, large amounts of scale and peripilar casts were present on the patchy lesions.

Comma-like structures were easier to identify in dogs with smooth or short-haired coats than those with curly hair. These preliminary observations suggest that further investigation of dermoscopy as a potential screening test for *M. canis* infection in dogs is warranted, particularly in cases that are Wood's lamp negative. Controlled studies with larger numbers of animals are needed to assess the sensitivity, specificity and reproducibility of this screening method.

Sources of Funding

This study was self-funded.

Conflict of Interest

No conflicts of interest have been declared.

References

1. Dong C, Angus J, Scarpella F et al. Evaluation of dermoscopy in the diagnosis of naturally occurring dermatophytosis in cats. *Vet Dermatol* 2016; 27: 275–e65.
2. Scarpella F, Zanna G, Peano A et al. Dermoscopic features in 12 cats with dermatophytosis and in 12 cats with self-induced alopecia due to other causes: an observational descriptive study. *Vet Dermatol* 2015; 26: 282–e63.
3. Miteva M, Tosti A. Dermoscopy of hair shaft disorders. *J Am Acad Dermatol* 2013; 68: 473–481.
4. Slowinska M, Rudnicka L, Schwartz RA et al. Comma hairs: a dermoscopic marker for tinea capitis. A rapid diagnostic method. *J Am Acad Dermatol* 2008; 59(Suppl): S77–S79.
5. Pinheiro AM, Lobato LA, Varella TC. Dermoscopy findings in tinea capitis. Case report and literature review. *An Bras Dermatol* 2012; 87: 313–314.

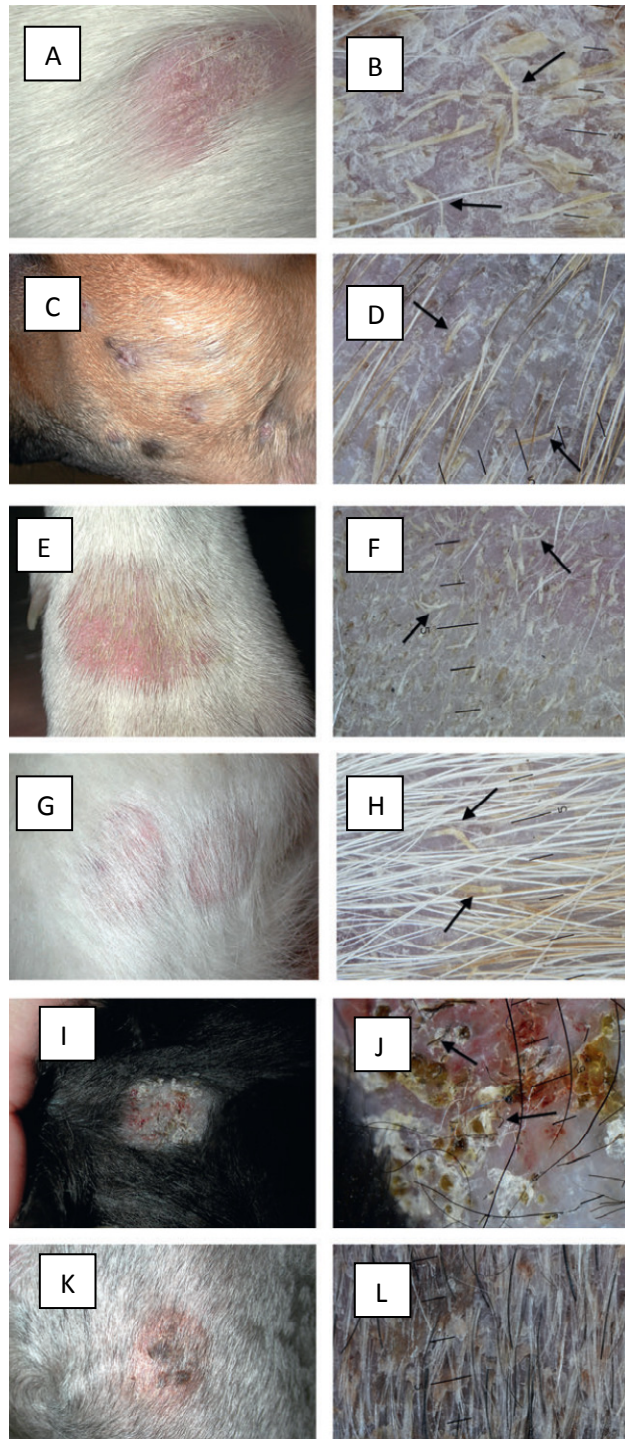


Figure 1. Clinical appearance of dermatophytosis due to *Microsporum canis*, with dermoscopic findings in a Jack Russell terrier dog (a), a French bulldog (c), two mongrel dogs (e, g) and two toy poodles (i, k). Dermoscopic images in five of the dogs (b, d, f, h, j) under 10-fold magnification show numerous broken, thickened hairs characterized by sharp, sloped ends (comma-like structures) and variable numbers of scales. Large numbers of scales and follicular casts are the only dermoscopic features in one of the two toy poodles (l).