

## RESEARCH PAPER

# Hens, Health and Husbandry: Integrated Approaches to Past Poultry-keeping in England

B. Tyr Fothergill\*, Julia Best†, Alison Foster\* and Beatrice Demarchi‡,§

This paper sheds new light on aspects of Roman and Anglo-Saxon chicken (*Gallus gallus*) husbandry and health through integrating analyses of chicken skeletal remains and eggshell from five archaeological sites in England (Fishbourne Roman Palace, Flixborough, Lydinge, Princesshay, and Uley). In addition to standardised archaeozoological study, over 10,400 chicken elements from these sites were subjected to palaeopathological and metrical analyses to clarify the relationship between husbandry methods and signs of disease and injury. Radiographic examination contributed to differential diagnosis of lesions and identification of medullary bone in complete appendicular elements. Eggshell examination was conducted on material from Flixborough using Zooarchaeology by Mass Spectrometry and Scanning Electron Microscopy to identify species and developmental stage. Combined, these techniques demonstrate previously-unknown patterns of egg production and consumption. By integrating these approaches, our results reveal previously unconsidered aspects of chicken husbandry and illuminate the broader value and social impact of past chicken-human relationships from the first millennium AD.

**Keywords:** Chicken husbandry; England; Eggshell; Medullary bone; Osteometrics; Palaeopathology

## Introduction

Chickens are ubiquitous beings in the present day, familiar as essential producers of flesh and egg protein, feathers, and dung, but also inhabiting less frequently considered roles as companion, participant in blood sport, and religious or national symbol. The global archaeology and history of chickens suggests that they have been husbanded for a similarly wide array of purposes in the past, and that this is true of what is now England. Archaeological evidence shows that chickens entered Britain (primarily England) in the Iron Age, via a complex intercontinental network (Armour-Chelu 1991; Ashdown 1979; Hamilton 2000; Legge et al. 1989; Maltby 1987). Whilst most examples are Late Iron Age in date (after 100 BC), a series of new calibrated radiocarbon dates demonstrates that chickens were rare but present from the later Early and Middle Iron Age in some areas of England (Best et al. unpublished; Kitch 2006; Strid 2015). Although specialist reports describing chicken bones excavated from archaeological sites in Britain are commonplace, only limited interpretations are routinely offered and archaeological studies focusing on quotidian management practices or less-

quantifiable aspects of chicken-human relationships are rare. The latter category, whilst valuable, includes mainly broad-brush considerations of the spread of chicken husbandry (such as Poole 2010, Sykes 2012), regionally-bounded studies (e.g. Fothergill 2016, Thomas et al. 2013), or narrowly focussed investigations of a single pathology (including Brothwell 2002).

Chicken keeping in England has been tackled by several authors, often as the most prominent region represented within British scholarship and situated primarily within historical frameworks. As is the case for the archaeological literature, some works are comprehensive and synthetic whilst others emphasise specific aspects or regions. Edward Brown wrote on the history of poultry husbandry in Britain in a general sense (1930), Joan Thirsk included chicken keeping as a component of studies covering alternative agriculture and women's work (1997; 2006), and Karen Sayer has discussed gendered aspects of chicken husbandry in a rural context (2013). Brian Short investigated chicken cramming as an industrial innovation in the Weald of Sussex from the mid-nineteenth century to the mid-twentieth century (1982), and Philip Slavin has examined the demesne accounts to clarify the place of chicken husbandry in Late Medieval eastern England (2009).

The goal of the present paper is to clarify, enhance, and help to complete the existing picture of past chicken husbandry and health across five sites from the Roman and Anglo-Saxon periods (Fishbourne, Flixborough, Lydinge,

\* University of Leicester, GB

† Bournemouth University, GB

‡ University of York, GB

§ University of Turin, IT

Corresponding author: B. Tyr Fothergill (bf63@le.ac.uk)

Princesshay, and Uley) in England. We integrated legacy data gathered during initial analysis of these assemblages with primary analysis by multiple methods in order to go beyond acknowledgment of the presence of chickens, and contribute a more fine-grained study of chicken-human relationships in a range of environments from the first to tenth centuries AD.

### Methods

Standardised zooarchaeological recording was completed on the chicken elements from all sites considered here, whether by an author of this paper or a previous analyst. This enabled us to convert the recording systems used by each analyst to the protocols described by Cohen and Serjeantson (1996, 109–112), which we have employed for comparative purposes. The Fishbourne assemblage was analysed by Martyn Allen (2011; Allen and Sykes 2011) and by Julia Best and Mark Maltby, Flixborough by Deborah Jaques (Dobney et al. 2007), Lyminge by Alison Foster and Tyr Fothergill, and Uley by Bruce Levitan (1993), with detailed re-analysis of the chicken remains by the authors of this paper and Katrien Janin. Although the Princesshay material was initially described by Broderick (2013), we use the figures supplied by Coles (unpublished) here as the bone records were directly associated with x-ray analysis and analysed in conjunction with authors from this paper. Wherever possible, we used the methods outlined in MacDonald (1992) and Tomek and Bochen-ski (2009) to exclude guinea fowl and pheasant from our analyses. A programme of genetic analyses was also run for a subsample of remains from each site. In any case, the presence of these species would be negligible and unlikely to affect our findings. All fragments of chicken bone were measured to at least a tenth of a millimetre in each case. Although some variation with regard to siding and zoning was present, this did not affect the results presented here. For the Lyminge and Uley assemblages, the analysts recorded categories of aging following Thomas et al. (2014) as well as butchery type and location, rodent and carnivore gnawing, burning, root etching, weathering, and other modifications.

### Demography

Juvenile bones were not sexed by any method or used in the metrical analyses, and their identification was based upon a porous appearance, with chick bones identified only at a very early state of skeletal maturation. Age categories follow Thomas et al. (2014). A number of skeletal elements were identified from individuals affected by the ‘creeper’ gene, which disproportionately shortens the distal limbs (Gordon et al. 2015; Hutt 1949). These were not included for metrical analyses. Log-scaling was used to enable comparisons of elements of different sizes across sites, and is a useful tool for visualising sexual dimorphism (Figures 2–8). This was achieved by log-scaling the measurements against the corresponding value from the same skeletal element from a ‘standard chicken’, a modern dual-purpose Warren-Ranger hybrid hen skeleton in the comparative collection at the University of Leicester (chicken

metrics have been log-scaled against this individual previously, see Thomas et al. 2013; Fothergill 2016). Medullary bone, an endosteal layer of bone that serves as a calcium reservoir during egg laying, is an accurate indicator of female sex and was recorded by macroscopic and microscopic inspection, as well as by radiography. Spurs, spur scars, and spur shields were recorded but not accepted as the sole indicator of male sex (at least one spurred hen features in this study, and spurred hens are an occasional feature of modern flocks).

### Palaeopathology

We examined chicken remains from the five sites for signs of disease and injury, then described and recorded these using an adapted version of the protocols established by Vann and Thomas (2006). We use the category ‘Trauma’ instead of ‘Fracture’ on the basis that fractures are a type of trauma, and use metrical analysis at the assemblage level instead of categorising size increase as pathological. For linguistic terminology regarding diagnostic certainty, we follow Appleby et al. (2015). Lesions were examined both macroscopically and microscopically before being photographed and subjected to digital radiographic examination using a Xograph DRagon mobile x-ray unit (52 KvP; 1.6 mAs; 0.025 s).

### Medullary bone

For each site, whole femora and tibiotarsi were subjected to x-ray analysis. In chickens, medullary bone occurs most regularly and to the greatest extent in these elements, largely due to excellent vascular supply (Best unpublished, van Neer et al. 2002: 129–132). As such, these elements are the most representative bones for reconstructing sex and egg laying. For Fishbourne, Lyminge, Princesshay, and Uley all complete femora and tibiotarsi were x-rayed (90, 115, 10, and 28 specimens respectively) and all fragmented remains (for all skeletal elements) were examined by the authors. Due to access and time constraints, only a sample (97 specimens; 23.2%) of the Flixborough femora and tibiotarsi were analysed by x-ray; these elements were randomly selected from contexts spanning the entire temporal range of the site. In addition to these primary elements, a sample group of tarsometatarsi from each site was analysed to explore spur development and examine the occurrence of medullary bone in spurred individuals. If articulated bone groups (hereafter referred to as ABGs) were present, all complete elements from the relevant individual were x-rayed. Lyminge and Princesshay were analysed with a Faxitron self-contained x-ray unit, whereas Flixborough and Uley were analysed with a DRagon mobile x-ray unit. Fishbourne was analysed with both units as a control (Best unpublished).

### Eggshell

We observed, photographed, and analysed eggshell using a Keyence Digital Microscope VHX 5000 series. We calculated the density of mammillae per mm<sup>2</sup>, measured eggshell thickness, and recorded morphological characteristics of the mammillae to document the stage of

chick development (Best et al. unpublished; Beacham and Durand 2007: 1610–1615; Sidell 1993).

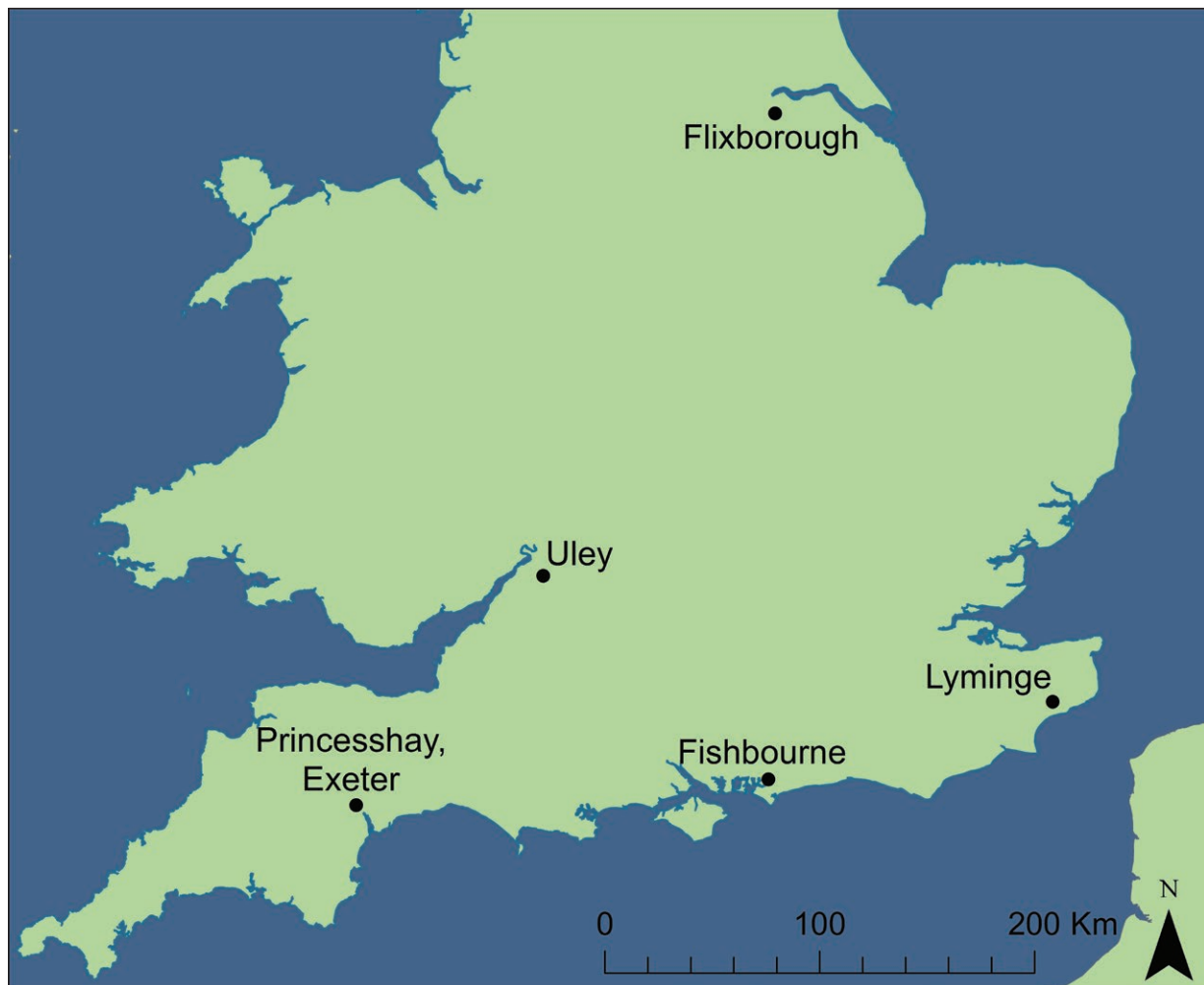
We conducted the taxonomic identification of the eggshell by ZooMS (Zooarchaeology by Mass Spectrometry), using marker peptides of known amino acid sequences (Presslee 2015). We prepared the eggshell fragments to isolate, extract and analyse (by MALDI-MS) the intracrystalline fraction of proteins only, according to the methods detailed in Presslee (2015), Demarchi et al (2016) and Jonuks et al (2017). Three replicates for each archaeological sample were averaged. The mass-over-charge

( $m/z$ ) values detected in the spectra of the archaeological samples were compared (within a tolerance of 0.1Da) to marker  $m/z$  values obtained on a reference collection including 22 avian taxa (Presslee 2015).

#### Materials

The assemblages used in this study originated from Roman or Anglo-Saxon sites across England that were situated in a range of environments (**Figure 1**).

**Table 1** below shows assemblage details for the study sites. Assemblage NISPs are taken from reports on the



**Figure 1:** Study sites shown by location.

**Table 1:** Study sites, associated date ranges, NISP, and references. Additional NISPs including elements from ABGs are shown in brackets.

Site	Date (AD)	Assemblage NISP	Observed <i>G.g.</i> NISP	% <i>G.g.</i>	Assemblage Reference
Fishbourne	1st–4th c	29700	570 (metric) (910 medullary)	3.06	Allen and Sykes 2011; Allen 2011
Flixborough	7th–11th c	41206	4585	13.81	Dobney et al. 2007
Lyminge	5th–9th c	6910	2425 [2589]	35.09 [37.48]	Knapp Unpublished
Princesshay	1st–3rd c	1692	243	14.36	Coles Unpublished
Uley	1st–4th c	77878	2647	3.4	Levitan 1993

entire assemblage; chicken NISPs and percentages are based on our observations in order to eliminate any potential issues of representation arising from diverse counting methodologies employed on different projects. The abbreviation *G.g.* has been used in places of *Gallus gallus*.

Apart from typical issues of preservation that affect all archaeological animal bone, avian remains are particularly vulnerable to underrepresentation due to their size, especially when sieving is not carried out or a small mesh size is not used (O'Connor 2008a: 34). This may have reduced the representation of small elements (e.g. phalanges, vertebrae) in assemblages where hand collection was used (Flixborough) or sieving methods changed over time (Fishbourne, Uley). However, these smaller elements were not used in the metrical analyses applied here, nor were they targeted for radiographic examination of medullary bone. Underrepresentation is also a major problem for the recovery of eggshell, which is rarely collected by hand unless in the form of relatively whole eggs. Like bone, eggshell can also be damaged or completely destroyed by soil conditions, particularly acidity. Pathologies can be obscured by taphonomic processes, which can make them more difficult to detect. Also, the impact of taphonomy can be mediated by the presence of pathology, which can potentially increase or decrease the vulnerability of the affected skeletal element (Bartosiewicz 2008). Medullary bone in fragmented material can be obscured by compacted soil in the endosteal cavity, and cleaning is therefore important.

#### **Fishbourne**

Fishbourne Roman Palace and its immediate environs have been excavated several times since the 1960s, and a summary of these endeavours is presented in Allen and Sykes (2011: 9–11). Excavation and sieving methods changed over time, which may have differentially impacted the proportions of smaller or more delicate elements. Preservation of the assemblage varied between the excavated areas, with avian elements from the main palace appearing better preserved than those from Fishbourne East. Materials from Fishbourne date from the Late Iron Age to the fourth century AD, with the vast majority of faunal remains originating from before the second to third centuries AD (Allen and Sykes 2011: 13). Allen and Sykes note that the proportion of chickens present in the earlier material from Fishbourne is well above the national average for that period (2011: 17). Allen's interpretations of the purposes for chicken husbandry at Fishbourne include egg-laying and cock-fighting, and he links the high proportions of chickens with the status of the site (Allen 2011: 344–345).

#### **Flixborough**

Flixborough is situated in North Lincolnshire near the River Trent and dates from the early seventh to the eleventh century. It has been described as 'an exceptionally wealthy Anglo-Saxon settlement' with a postulated monastic phase (Dobney and Loveluck 2007: 1), and was excavated from 1989–1991 (Loveluck and Atkinson 2007). The faunal assemblage was hand collected, and metrical

data were gathered using a set of replicable protocols and a diagnostic zoning system was also employed (Appendix 1 in Dobney et al. 2007). Avian elements were not sided during analysis, and juvenile elements were not recorded, which prevents estimated comparisons of proportions of adults, juveniles, and chicks. However, when we examined the material for pathologies and medullary bone, we observed very few juvenile elements (notably fewer than Lyminge and Uley) and found that the overall preservation of the skeletal material was good. A bimodal distribution of greatest length measurements in the Flixborough chicken tarsometatarsi led the original analyst to conclude that both male and female chickens were present at the site. Some elements (particularly from Phase 4–5b) are interpreted as capons (Dobney et al. 2007: 171–173), and we will return to this in our discussion.

#### **Lyminge**

The site of Lyminge, an Anglo-Saxon monastery, great hall, and settlement dating from the fifth to the ninth centuries AD, was excavated from 2012–2015 by a University of Reading team led by Gabor Thomas. We were granted access to the faunal assemblage from the 2008–2012 seasons, which was recovered by a combination of sieving and hand collection. Bone preservation was sometimes very poor, with substantial concretions on some elements preventing measurement and potential identification of pathologies. Although distinct spatial areas of the site were excavated in different seasons, the phasing for Lyminge was not available at the time this paper was written. The complete faunal analysis, including data from our examinations of the 2008–2012 chicken assemblages, is in preparation (Knapp unpublished).

#### **Princesshay**

Portions of the Roman town of Exeter (AD 50 to 241) were excavated prior to the redevelopment of the Princesshay area by Exeter Archaeology. Faunal remains were recovered using a combination of sieving and hand collection. The chicken elements from this assemblage were well preserved and made available to us by Charlotte Coles, who is in the process of publishing a full report of the faunal material (Coles unpublished). Phasing by context was not available, but the small size of the assemblage renders any attempt to construct a detailed temporal comparison problematic regardless of the absence of contextual phasing.

#### **Uley**

With support from what is now Historic England, an area of 2,150 square metres was excavated from 1977–1979 at Uley, with sieving employed in the final year of excavation (Woodward and Leach 1993). Although the strata excavated ranged in date from the Prehistoric to Medieval and modern, the focus of the site monograph and associated reports was the Roman religious architecture and related spaces dating from the first to early fifth centuries AD. Animal bones were not spatially recorded (apart from 'scatters of bone' during the 1979 field season, Woodward and Leach 1993: 10), but Levitan's report on the non-human



vertebrate remains phases the bones by species and structure for phases 4 through 6 (1993: 260, 276–293). Unfortunately, contextual phasing was not available for all phases, and could only be reconstructed for some portions of the assemblage. In the microfiche accompanying the monograph, chickens at Uley are interpreted primarily as having ‘association with ritual activity’ (Levitan 1993: 2:A3), but cock-fighting is also mentioned as a possible reason for their presence. During the recent re-analysis of the Uley assemblage, we observed that the preservation was more variable than at any other site considered. In some cases, species designations and measurements were impossible; in others, small and delicate elements were in excellent condition.

**Results**

**Demography**

In order to compare demographic aspects of chicken husbandry, we obtained a total of 2,785 length measurements from *Gallus gallus* appendicular elements, counted 120 tarsometatarsal spurs and 57 scars, and documented medullary bone in fragmented material and in complete femora and tibiotarsi from all sites (Table 2). These were used to generate estimated proportions of male and female chickens at the study sites. One spurred tarsometatarsus from Lyminge had medullary bone present, and one tarsometatarsus from Flixborough with female metrics had a spur. The former clearly represents a hen with spurs, and the latter may also, but the Lyminge example was unfortunately not complete enough to obtain a length measurement.

Table 3 shows the number of greatest length measurements (GL) by site and element, and Figures 2–8 illustrate the log-scaled values of these from all five sites using Gaussian kernel density estimates (Wessa 2015).

The intersection of the x and y axes represents the value of the relevant standard chicken metric, against which the corresponding values are log-scaled with size increasing from left to right on the x axis. The y axis shows the density at which these values cluster, with a higher density indicating a greater number of measurements with that value. The wing elements (Figures 2–5) show a range of different metrical profiles. Flixborough and Lyminge both have clear bimodal distributions, but the greater density of elements with shorter lengths at Lyminge suggests an adult population dominated by hens, whereas Flixborough’s profile is more balanced. Fishbourne’s wing element profiles are indistinct, although some dimorphism is evident from the humerus values (Figure 3). Princesshay shows some bimodality, with a dominance of males in every element apart from the carpometacarpus, which is also true of Uley in every element. Additional areas of increased kernel density (clustering of values) are present at these two sites; these are especially evident in the ulna and may indicate the presence of different breeds of chicken.

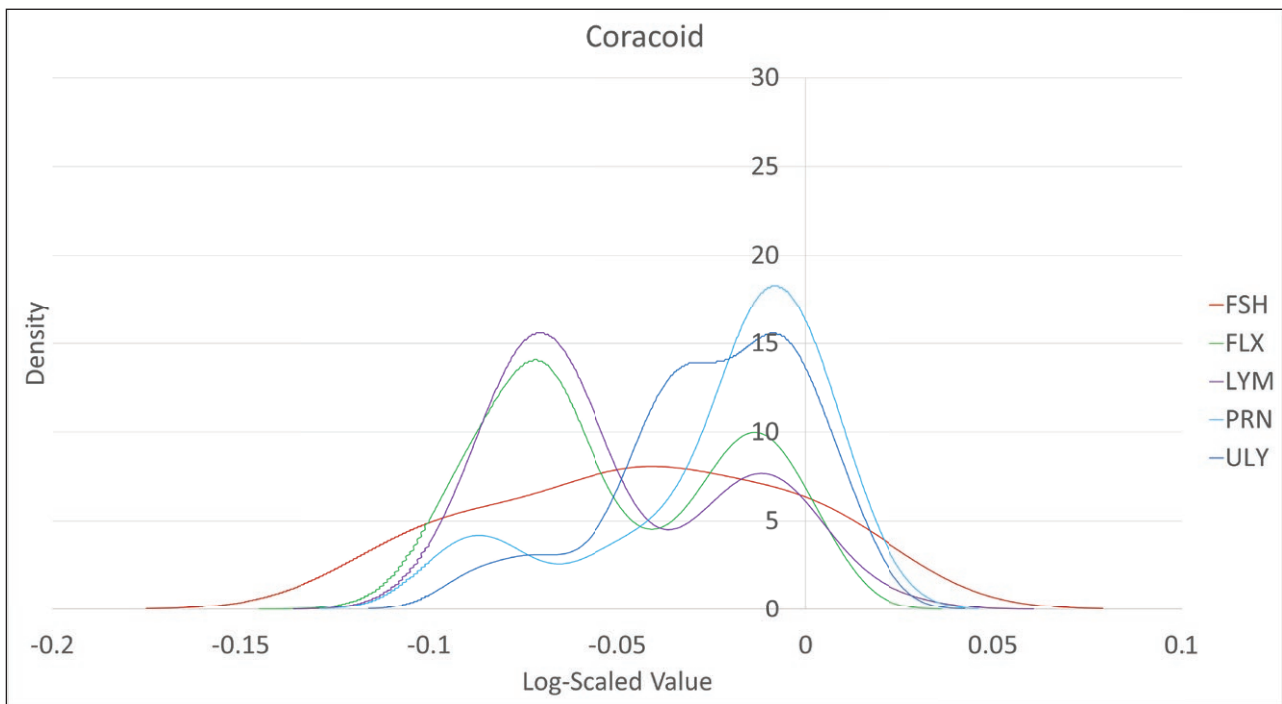
The high kernel density of larger tibiotarsal measurements at Uley has necessitated expansion of the y-axis for the leg element graphs (Figures 6–8). Again, Lyminge and Flixborough show varying levels of bimodality, with the former having greater proportions of hens. Fishbourne presents a rather indistinct profile once more, and although no femoral lengths were available

**Table 2:** Chicken population data: number of greatest length measurements, metrical sex estimates, medullary bone (MB) frequency in fragmented bone, medullary bone minimum total including x-ray data [total with ABGs], tarsometatarsus frequency, frequency of tarsometatarsal spurs, frequency of tarsometatarsal spur scars, and frequency of tarsometatarsal spur absences (actual absence in adults rather than a lack of the relevant anatomic region).

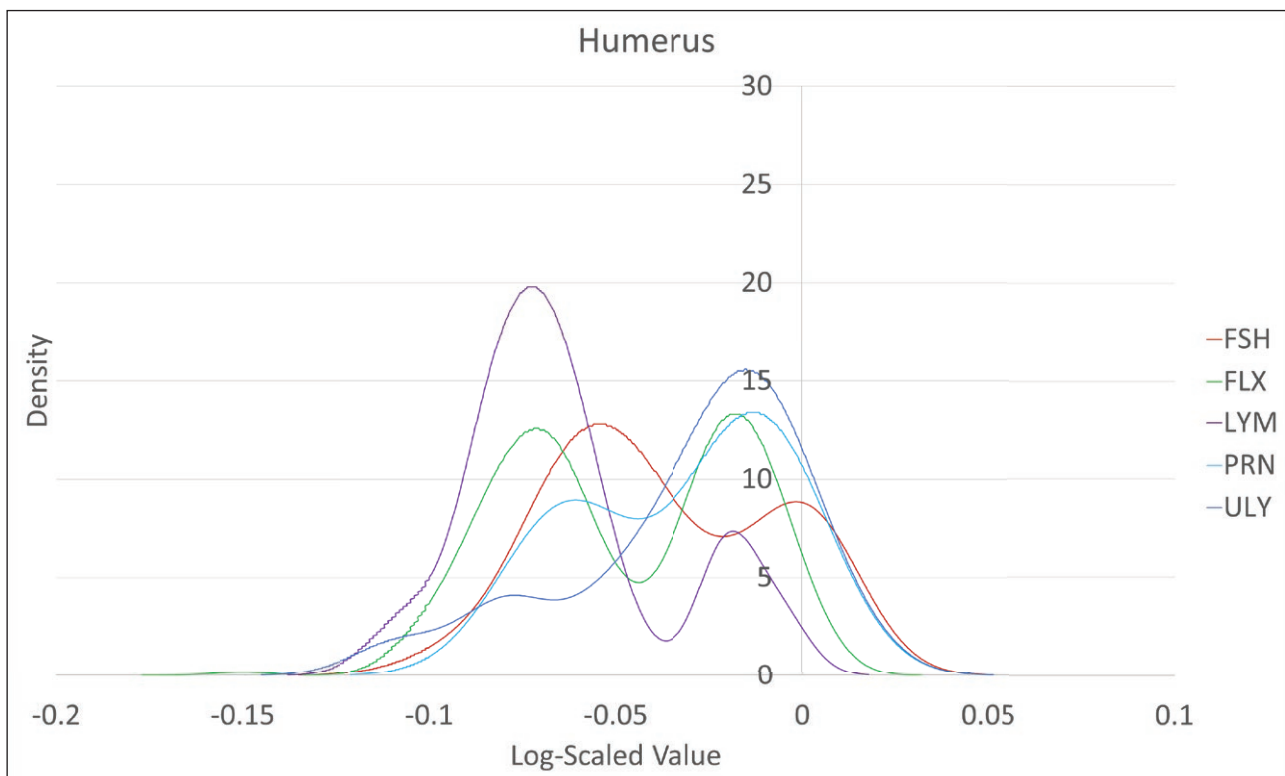
Site	No. GL values	Metrical est. % female	MB in Frag.	MB min. Total	TMT Total	TMT Spur	TMT Scar	TMT Spur Absent
Fishbourne	170	61.8	58	94	61	3	2	24
Flixborough	1733	54	N/A	32	329+	32	34	262
Lyminge	509	79	53	93 [106]	357 [370]	15	7	260 [270]
Princesshay	72	33.3	0	0	40	4	5	12
Uley	301	12	19	20	226	66	9	16

**Table 3:** Numbers of greatest length (GL) measurements by site and element.

	Coracoid	Humerus	Ulna	CMC	Femur	TBT	TMT
Fishbourne	10	26	26	10	75	8	18
Flixborough	344	299	301	344	237	168	142
Lyminge	66	58	51	66	52	26	21
Princesshay	14	8	18	14	0	7	7
Uley	50	49	37	50	42	5	22
<b>Total</b>	<b>484</b>	<b>440</b>	<b>433</b>	<b>484</b>	<b>406</b>	<b>214</b>	<b>210</b>



**Figure 2:** Kernel density estimates for log-scaled coracoid GL, all sites.



**Figure 3:** Kernel density estimates for log-scaled humerus GL, all sites.

from Princesshay, the few measurements from the other two leg elements provide a mixed picture. Uley is clearly male-dominated with regard to every element, and has two dense concentrations of larger-sized tibiotarsi, which could represent males from different breeds of chicken.

In addition to the data collected on age category (Thomas et al. 2014), some elements at each site bore signs of arthropathy that were likely to be age-related (**Table 4**).

The comparatively high proportions of arthropathy at Lyminge are notable, and although it is a feature of the

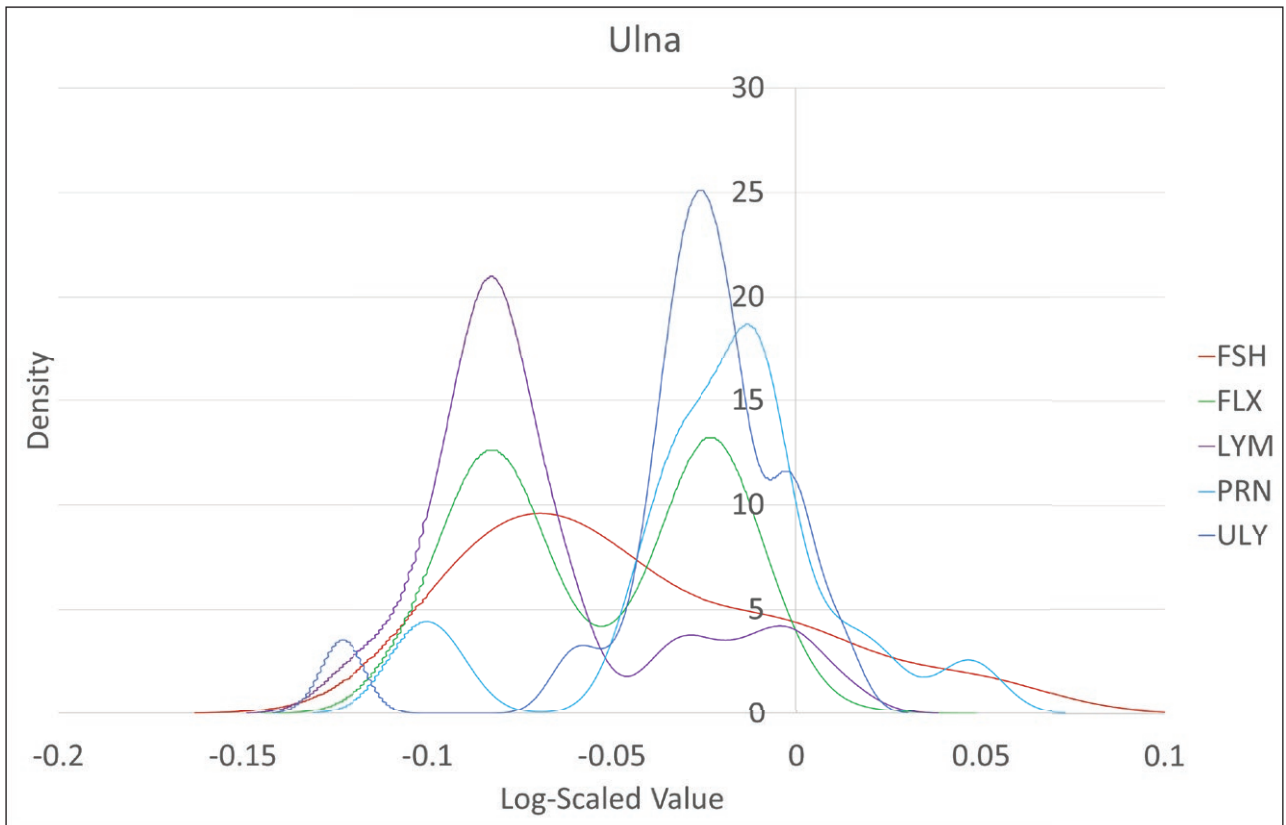


Figure 4: Kernel density estimates for log-scaled ulna GL, all sites.

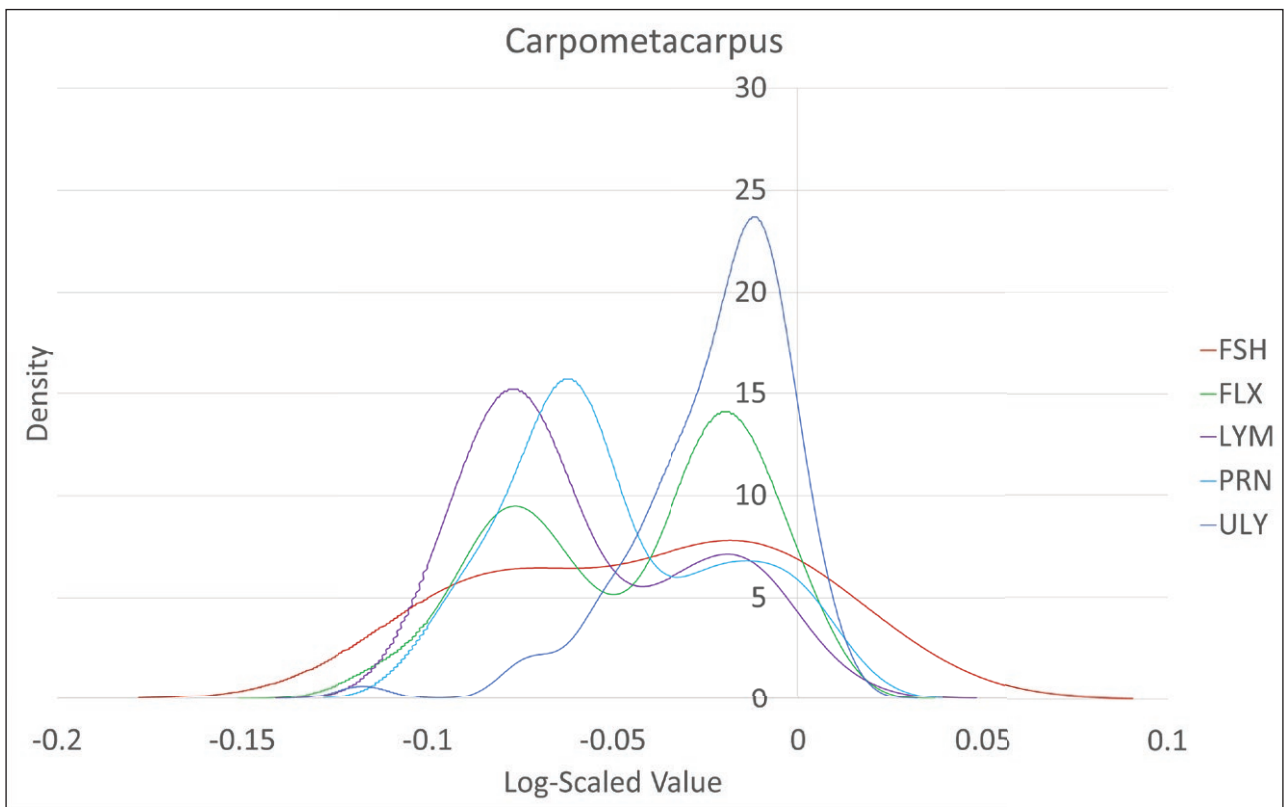
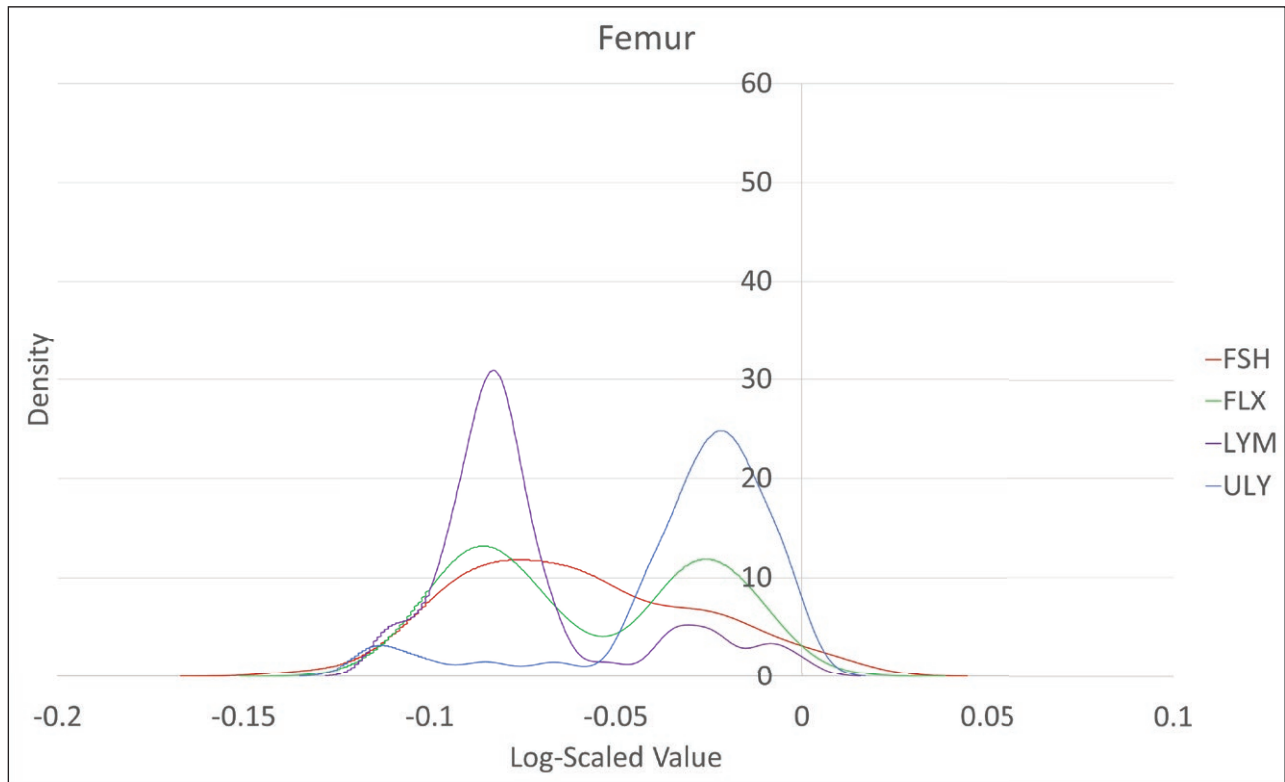
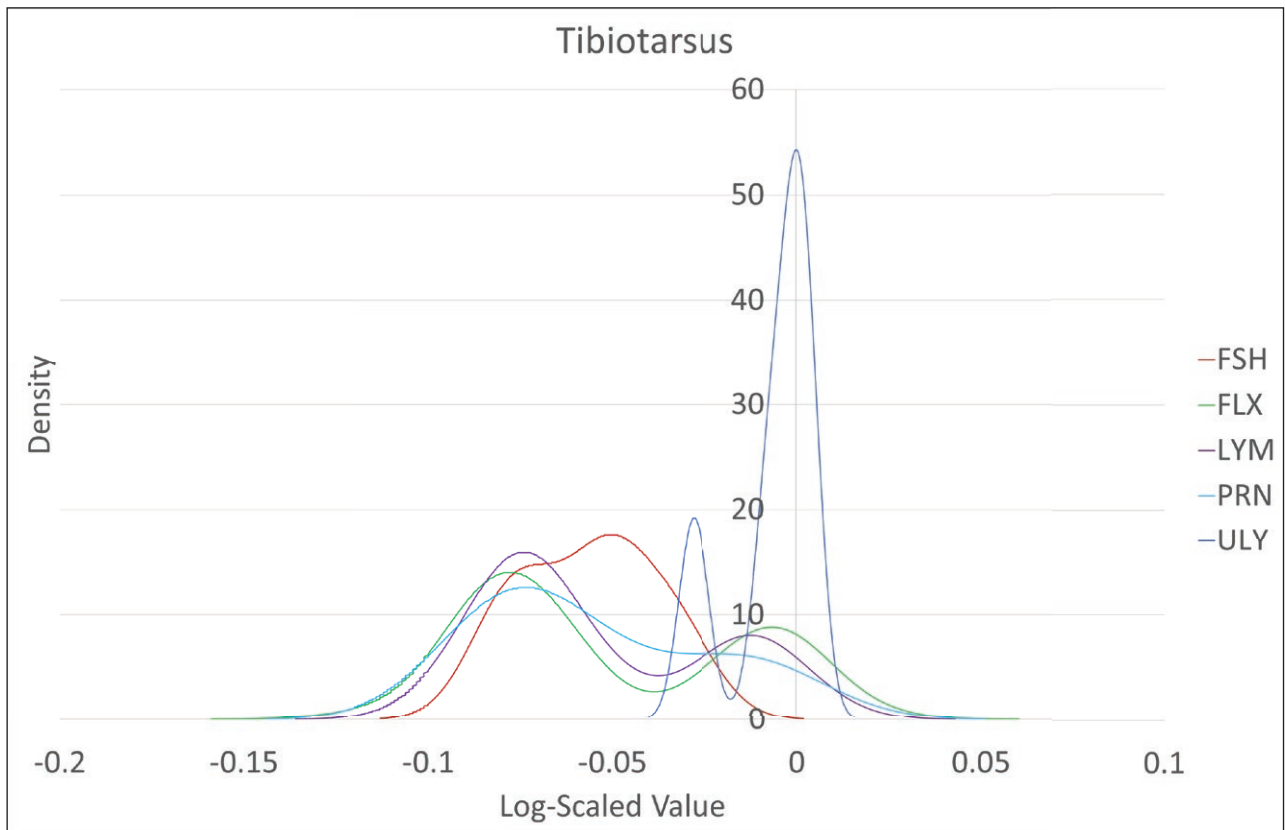


Figure 5: Kernel density estimates for log-scaled carpometacarpus GL, all sites.



**Figure 6:** Kernel density estimates for log-scaled femur GL, all sites (measurements not available from Princesshay).

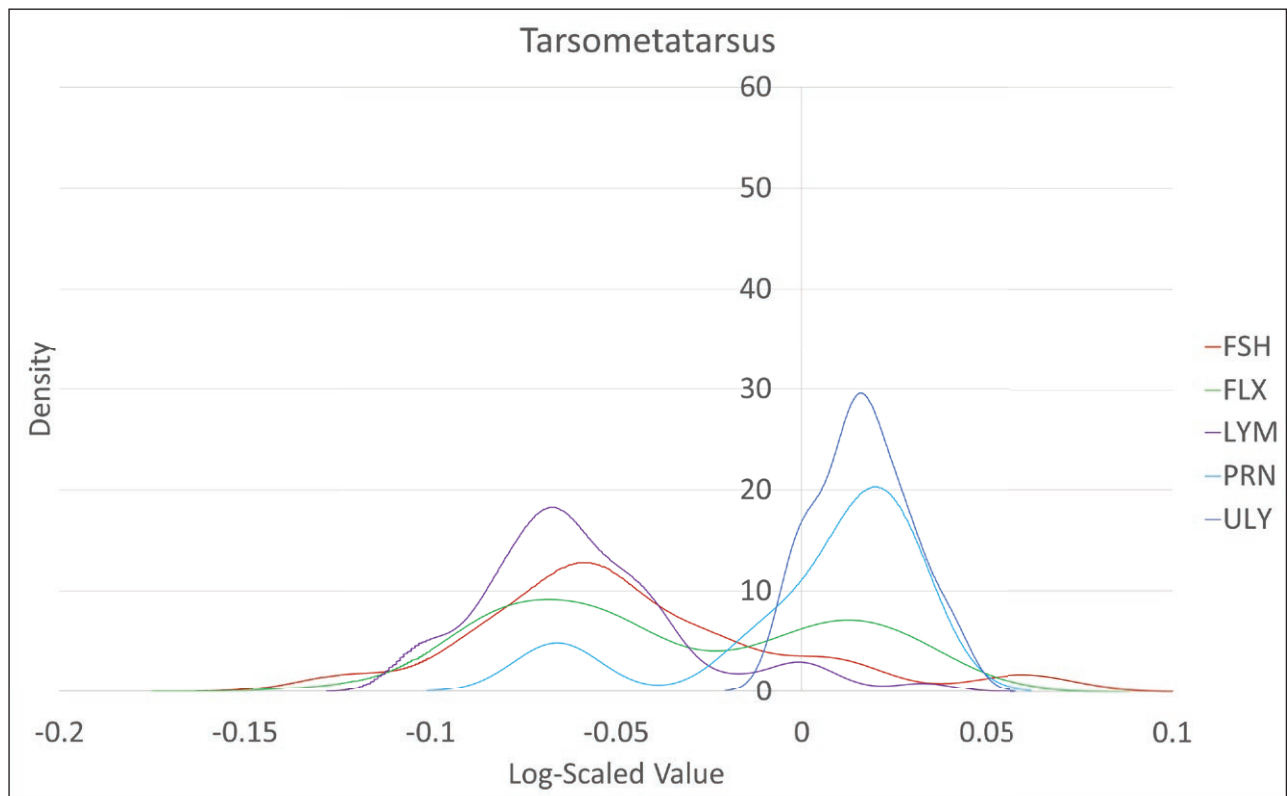


**Figure 7:** Kernel density estimates for log-scaled tibiotarsus GL, all sites.

distinctive pathological profile of the site, the high percentage of adult hens at the site also suggests an egg-laying purpose for chicken husbandry. Conversely, the low

proportion of arthropathy in addition to high percentages of males and juveniles at Uley supports an interpretation of chickens in a sacred or culinary role. Princesshay is





**Figure 8:** Kernel density estimates for log-scaled tarsometatarsus GL, all sites.

**Table 4:** Chicken population data: probable age-related arthropathy and percentages of adult, juvenile, and chick elements. Where no further information on immature specimens was available, elements were considered juvenile.

Site	G.g. NISP	% with arthropathy	% adult	% juvenile	% chick	% indeterminate
Fishbourne	570 (910 age)	0.9	92.3	7	0.7	N/A
Flixborough	4585	0.3	c. 85	c. 15	N/A	N/A
Lyminge	2425	1.4	84.9	12	2.8	0.3
Princesshay	243	0.8	84	16.1	0	N/A
Uley	2647	0.3	69.1	20.5	8.4	1.9

the smallest assemblage considered here, and resembles Fishbourne with regard to levels of arthropathy, but has low numbers of hens like Uley. Fishbourne has the lowest overall proportion of juveniles, again suggesting a greater use of older birds.

**Palaeopathology**

In this study, we identified 177 lesions (OED: “tissue which has suffered damage through injury or disease”, of which multiple instances can occur as part of pathological development) in 151 skeletal elements across all assemblages. The overall frequencies of pathology by site are presented in **Table 5**, and **Figures 9–13** illustrate the frequency of pathology by element for each assemblage.

In describing the lesions encountered in the assemblages, we categorised them according to general type (**Table 6**, adapted from Vann and Thomas 2006), and attempted differential diagnosis. Bone formation lesions

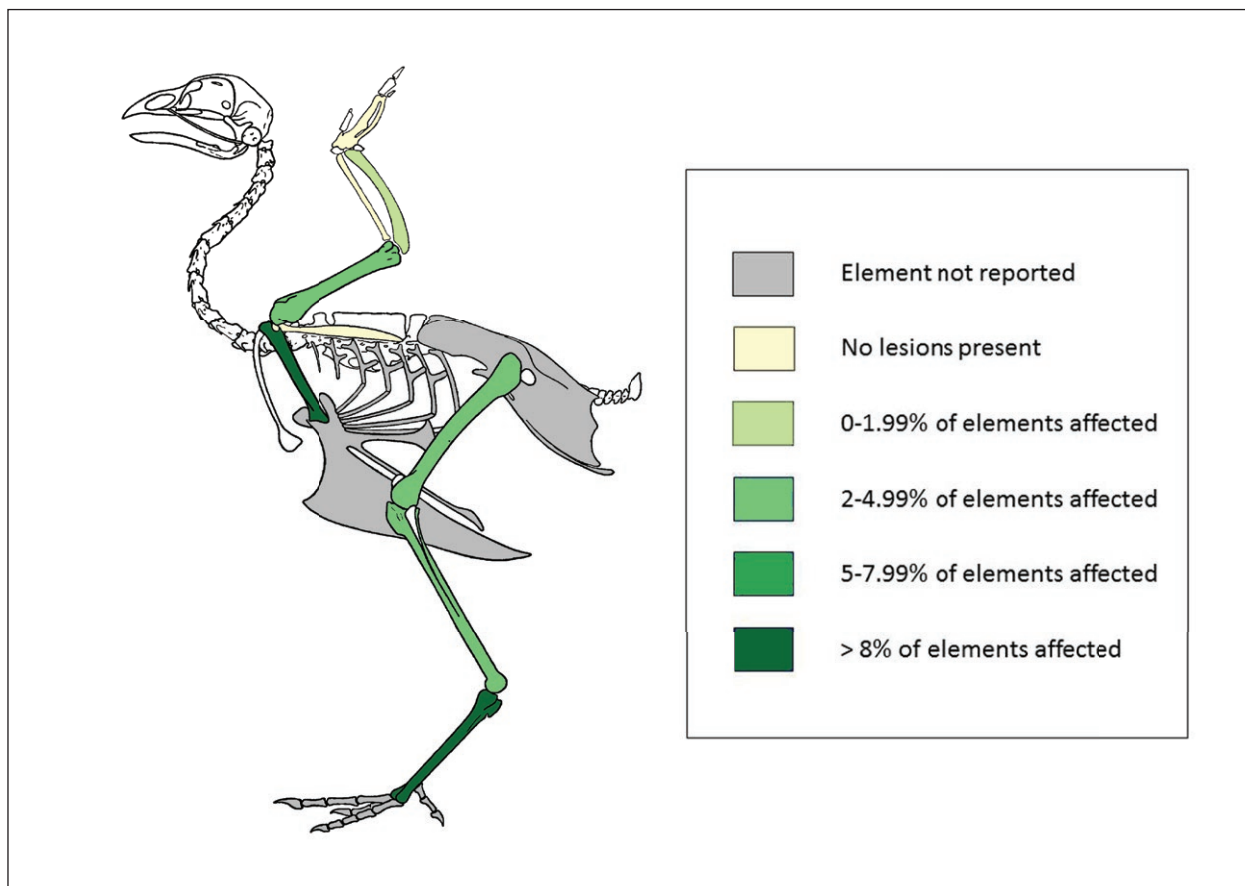
are where unusual osteoblastic activity or neoplasia has occurred (e.g. increased bone density, osteophytes) and bone destruction is the opposite, (e.g. necrosis, pitting at articulations). Trauma includes any direct injury to the bone, including fractures; secondary changes following soft-tissue injuries are also noted. Shape alterations involve the overall morphology of the element, e.g. bowing or diaphyseal expansion.

**Distinct groups and differential diagnosis of pathologies**

In some cases, it was possible to build upon the general categories to identify narrower sub-categories of pathology consisting of anatomically similar lesion groups, and differential diagnosis of avian osteopetrosis was achieved in eight cases. **Figures 14–16** below show the relative anatomical frequency of these by element, with arthropathy further narrowed to proximal or distal zones of articula-

**Table 5:** Quantification of lesions and elements affected by pathology.

	<i>G.g.</i> NISP	Lesions	Pathological elements	% lesions	% pathological elements
Fishbourne	570	26	19	4.6	3.3
Flixborough	4585	28	28	0.6	0.6
Lyminge	2425	79	63	3.3	2.6
Princesshay	243	8	7	3.3	2.9
Uley	2647	36	34	1.4	1.3
<b>Study Total</b>	10470	177	151	<b>N/A</b>	<b>N/A</b>



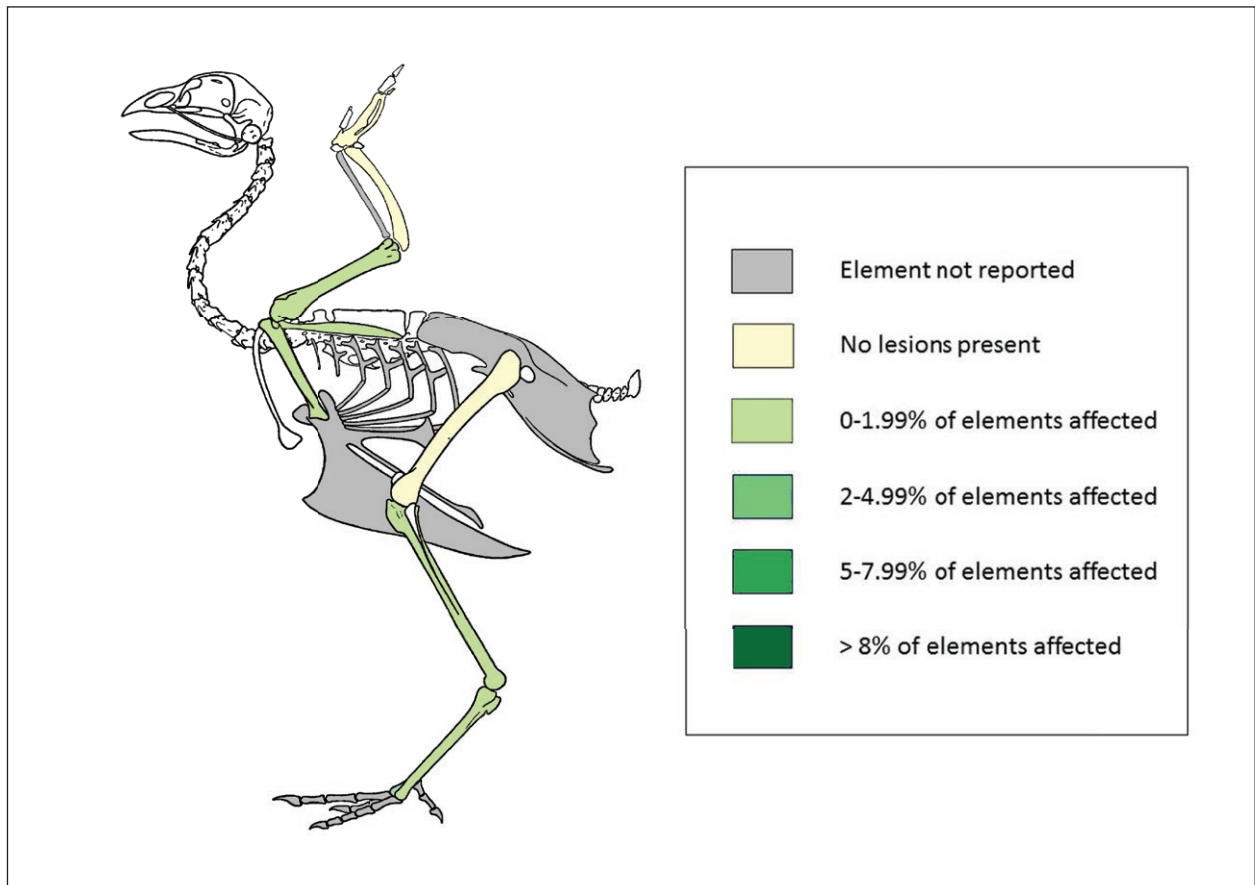
**Figure 9:** Overall frequency of pathology in the Fishbourne assemblage.

tion. We describe how we use the terms arthropathy, avian osteopetrosis, and fractures, then discuss pathologies that occur only at one site in the context of that assemblage.

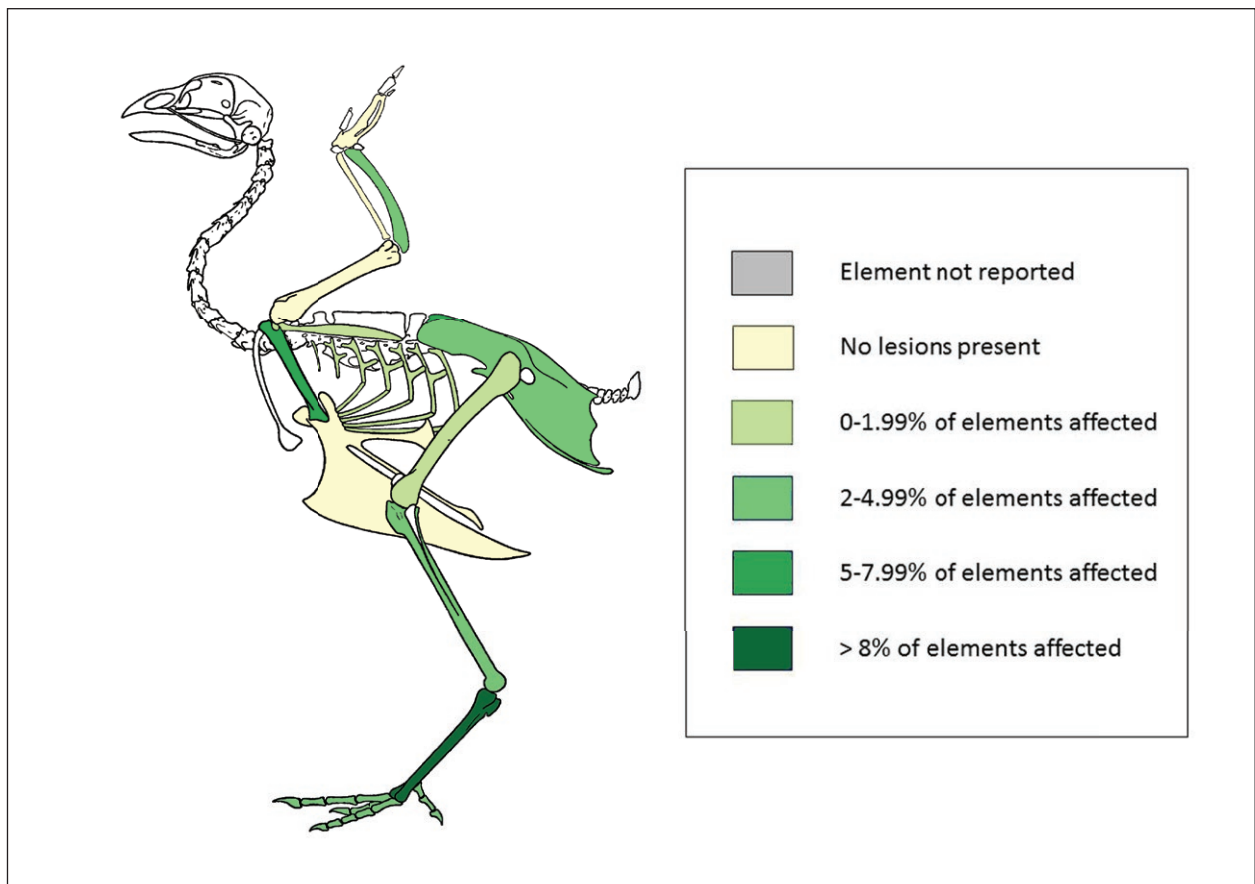
**Arthropathy**

Joint disease, often simplistically termed ‘osteoarthritis’ (OA), is often identified in faunal bone using four factors (following Baker and Brothwell 1981: 115). These criteria are a useful starting point, but the pathogenesis of the disease is complex and originates in the growth or articular cartilage (Rothschild and Panza 2007, O’Connor 2008b), rather than the osseous, subchondral tissue (though Brandt et al. 2006 point out that other soft tissues could also be a primary lesion focus). Much attention to arthropathy in faunal assemblages focuses on cattle and caprines, but birds have not been neglected (Bartosie-

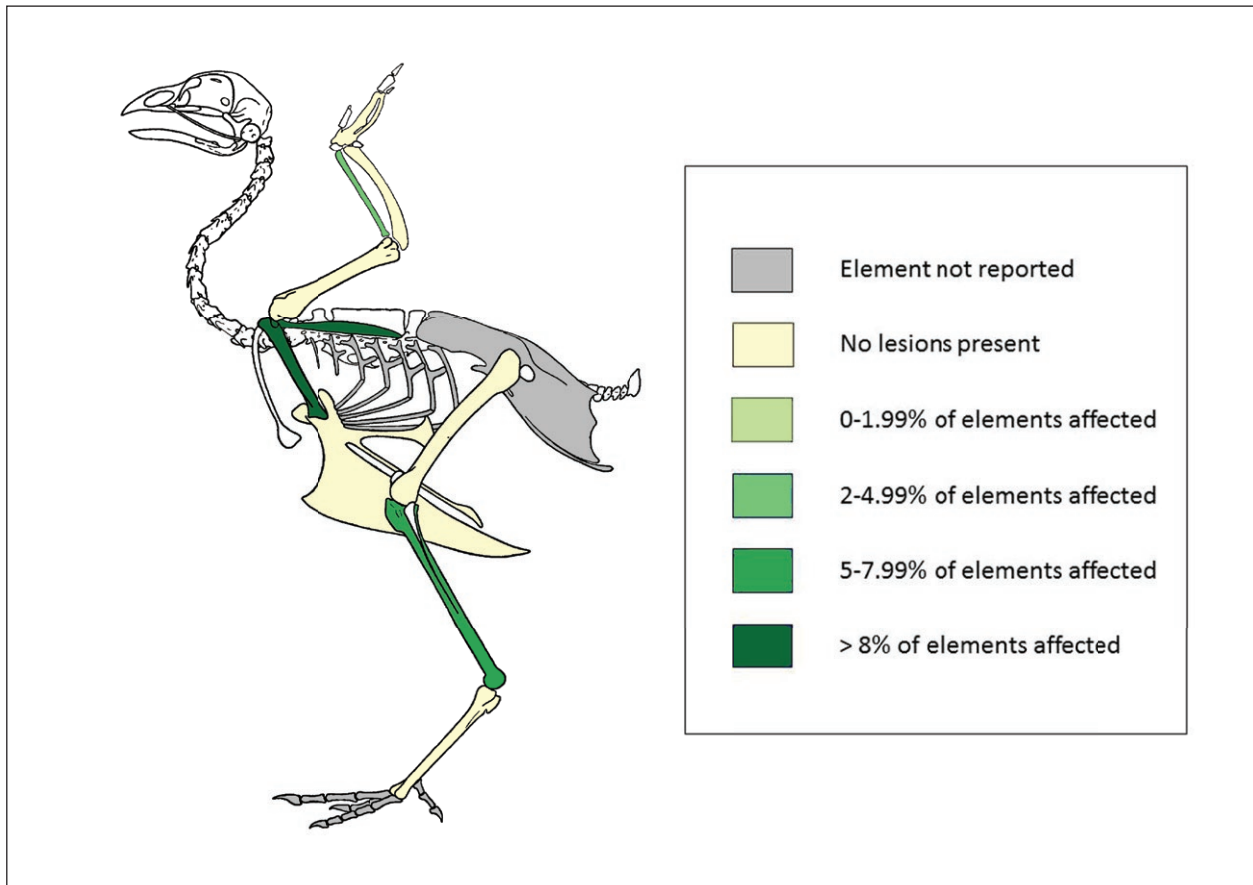
wicz and Gál 2013: 232), particularly as joint-specific analogues for understanding the aetiology and pathogenesis of the disease in humans (Rothschild and Panza 2006a; 2006b; 2007). Evidence from research on avian remains suggests that arthropathies vary in expression by species and age (Rothschild and Panza 2007; van der Kraan 2008), but reports on links between arthropathy and individual weight examine specific groups (Early Cretaceous birds; falconidae and columbiformes) and present conflicting results (Rothschild et al. 2012; Rothschild and Panza 2006a). We follow O’Connor (2008b: 183) in acknowledging four categories of arthropathy (osteoarthritis, osteochondrosis, infectious arthropathy, traumatic arthropathy). Joint-affecting lesions that could not be categorised to a high degree of diagnostic certainty were classed as ‘consistent with arthropathy’. Fifty-nine examples of



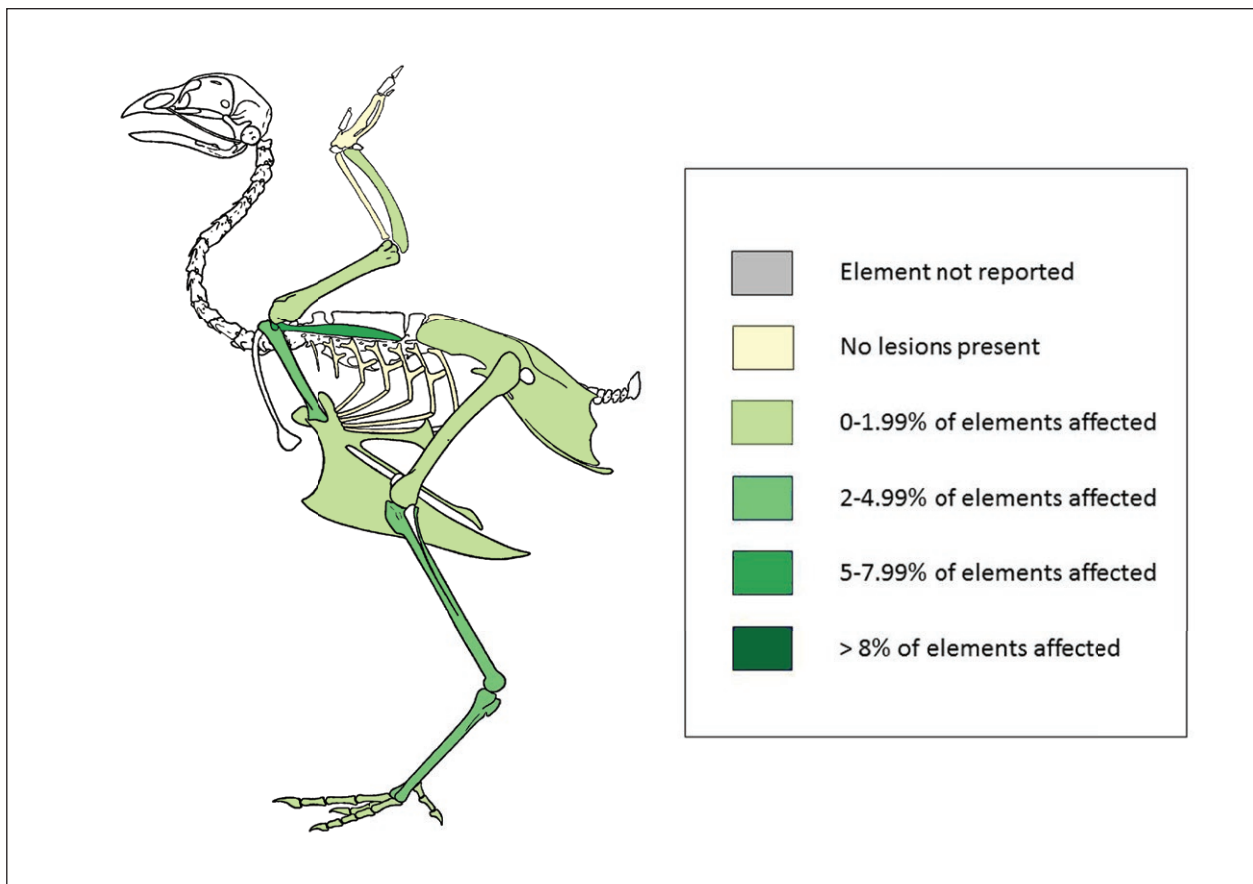
**Figure 10:** Overall frequency of pathology in the Flixborough assemblage.



**Figure 11:** Overall frequency of pathology in the Lyminge assemblage.



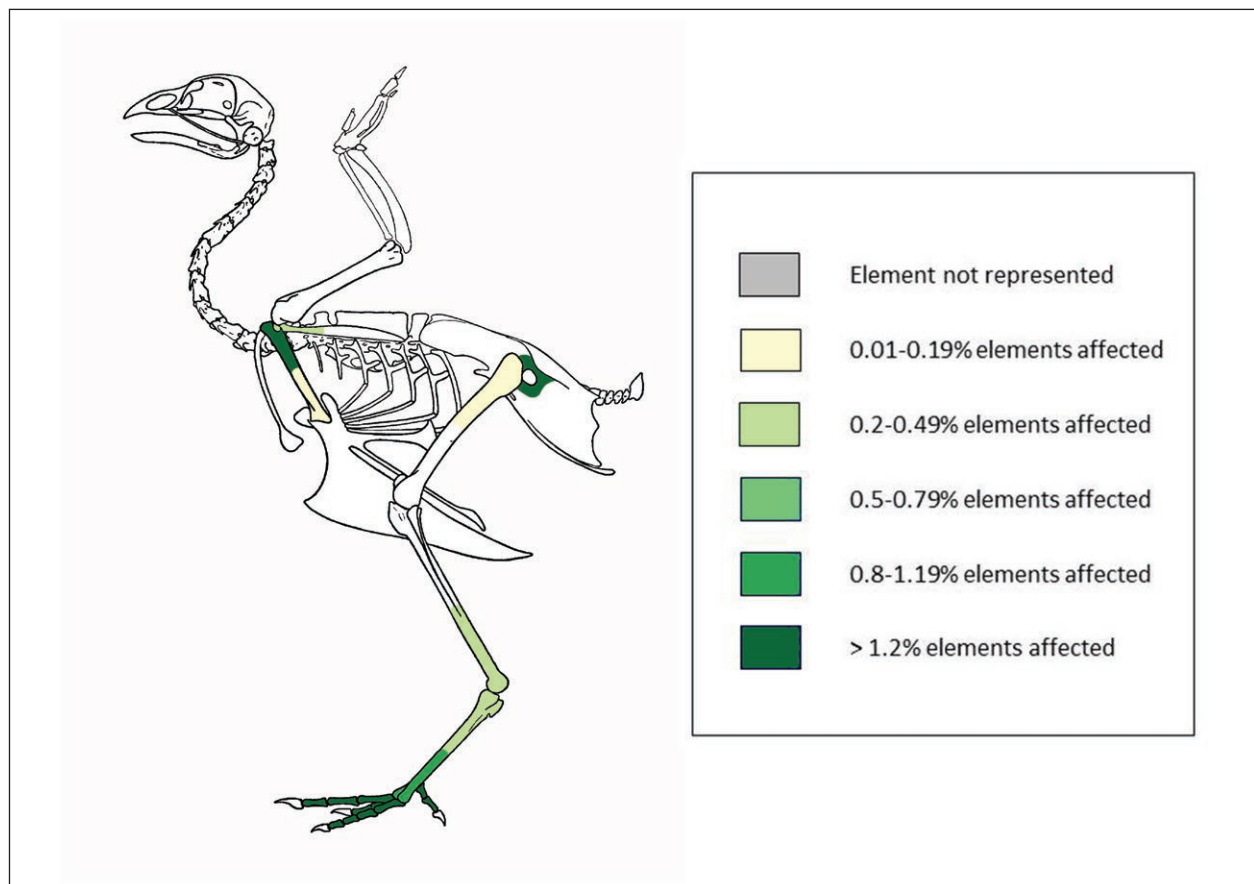
**Figure 12:** Overall frequency of pathology in the Princesshay assemblage.



**Figure 13:** Overall frequency of pathology in the Uley assemblage.

**Table 6:** Lesions by site according to general pathology type.

	Bone formation	Bone destruction	Trauma	Shape alteration	Total
Fishbourne	17	4	2	3	26
Flixborough	21	0	2	5	28
Lyminge	53	9	8	9	79
Princesshay	6	1	0	1	8
Uley	29	1	4	2	36
<b>Total</b>	126	15	16	20	177

**Figure 14:** Frequency of arthropathy across all assemblages, by affected articulation.

arthropathy were present across all assemblages. The high apparent frequency of acetabular pathology in **Figure 14** above is the result of these elements being recorded only at Lyminge and Uley.

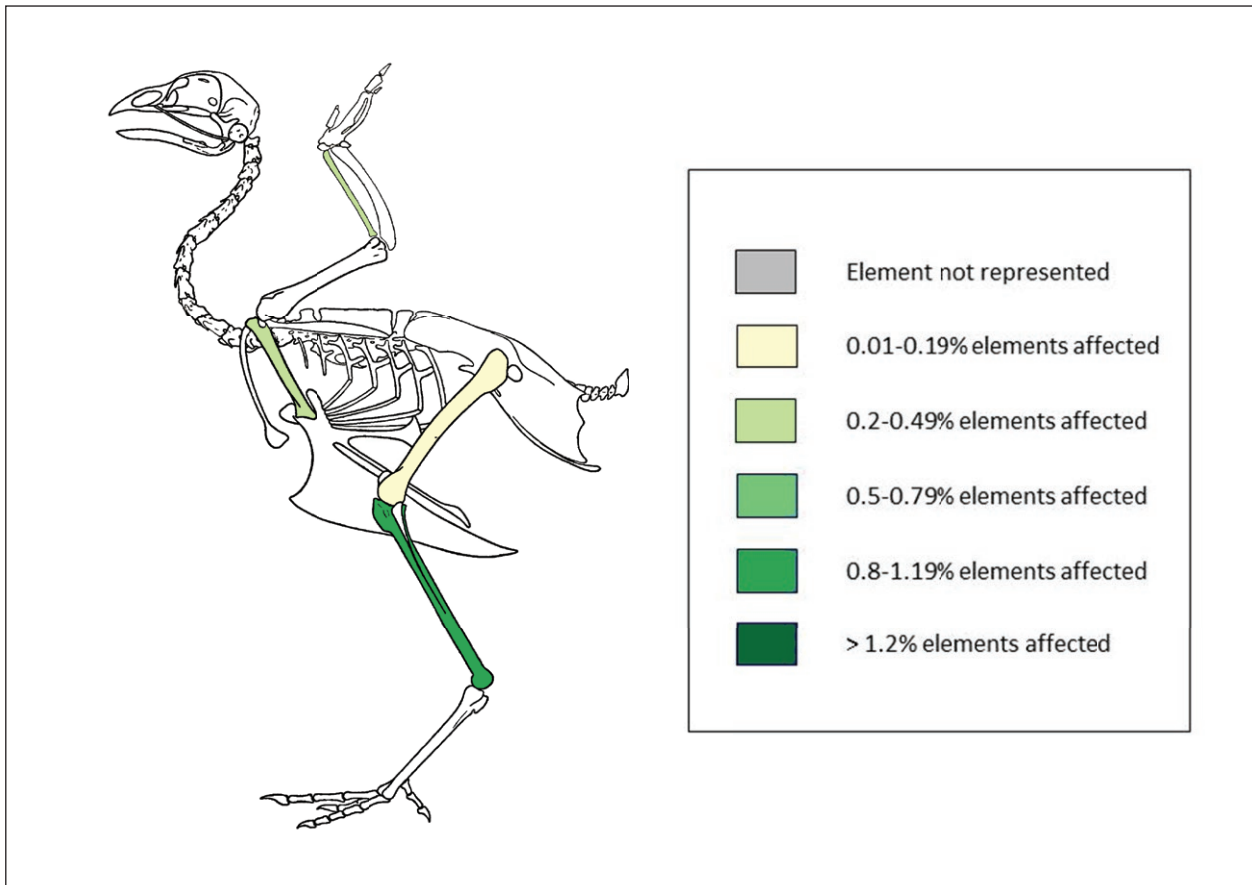
#### Avian Osteopetrosis

Avian osteopetrosis is a term used to describe the changes in skeletal morphology that present in some individuals infected by a range of avian leucosis viruses of different subgroups, which are transmitted by several methods and affect many domestic species (Payne 1992). Brothwell's seminal paper described archaeological instances of the disease across England (2002), and a fresh re-visitation of the topic with a wider, European remit is currently in progress (Fothergill accepted). Differential diagnosis of this condition required eliminating post-traumatic callus

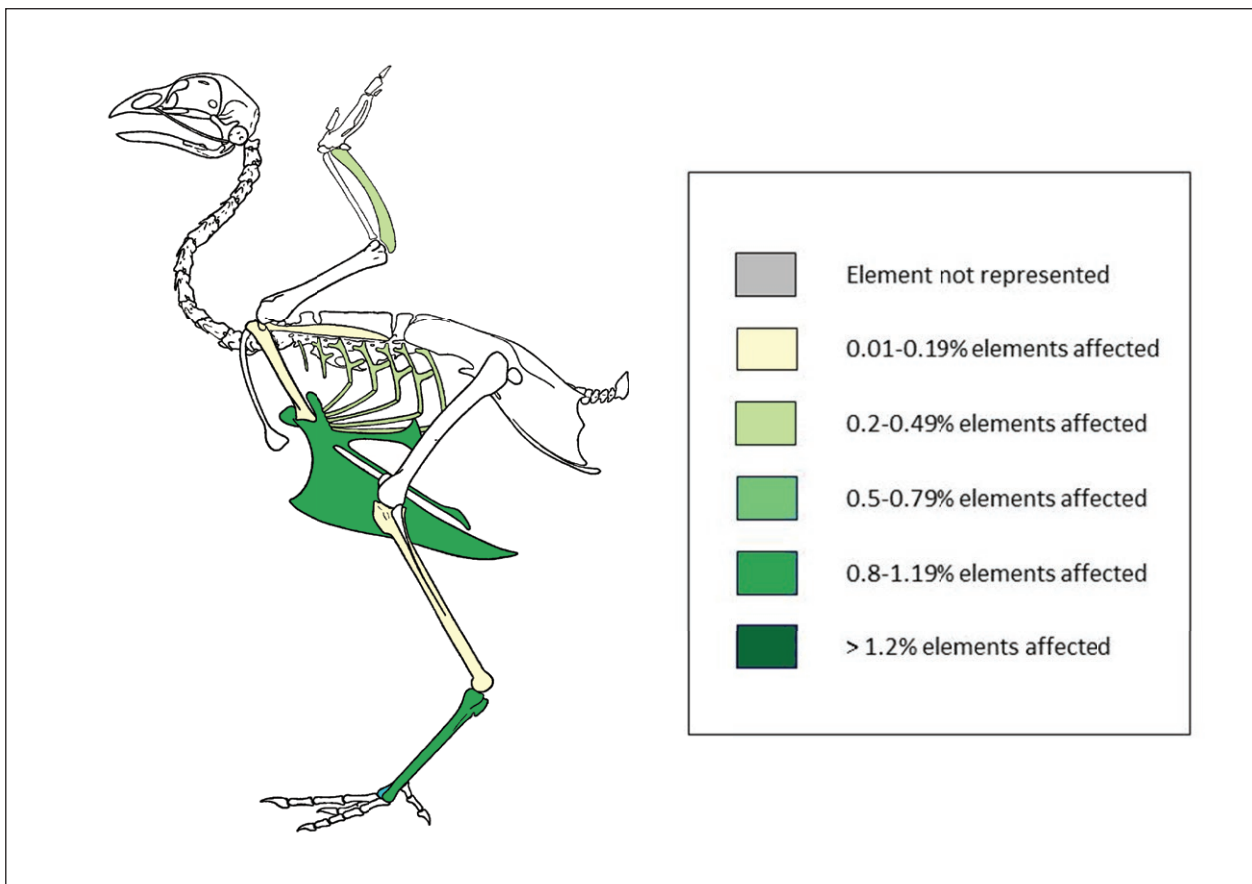
formation as a possible cause for the inflated appearance of the diaphysis of the affected elements (excluded by a lack of anatomical deviation in each case), and the presence of increased bone density and incursion of new bone into the endosteal cavity (**Figure 18**). Across all assemblages, eight elements at Fishbourne, Princesshay, and Uley had lesions diagnostic of avian osteopetrosis.

#### Fracture

We class fractures as a type of trauma where there is a primary injury to the bone itself, rather than a reaction to secondary to soft tissue trauma. Fractures can be acute, the result of a single event, or chronic (stress fractures, or fractures that do not heal over time). Several types of fracture can be distinguished (Baker and Brothwell 1981: 85; Bartosiewicz and Gál 2013: 46–57, 219–222), and those

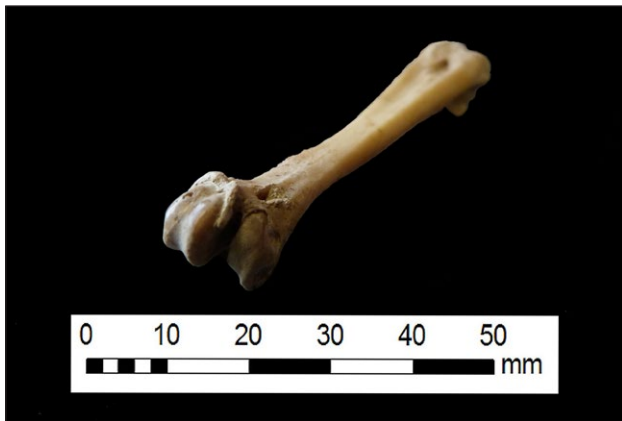

**Figure 15:** Frequency of avian osteopetrosis across Fishbourne, Princesshay, and Uley.

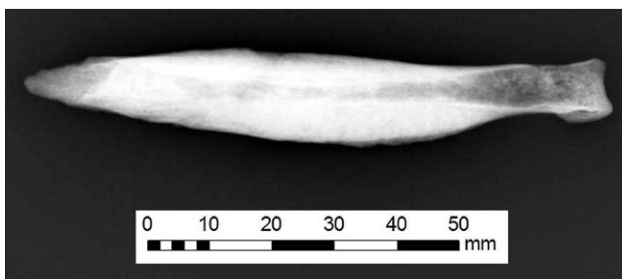


**Figure 16:** Frequency of fractures across affected assemblages (all sites apart from Princesshay).





**Figure 17:** Arthropathy in a tarsometatarsus from Lyminge (LYM09, 1566).



**Figure 18:** Avian osteopetrosis in a tibiotarsus from Fishbourne Roman Palace (FB61, 2(2), CHCFB:FB61/CB5).

present in the materials studied were recorded following Muller's system of classification (2010). Sixteen fractures were present across all sites and were present in every assemblage apart from Princesshay. The frequency of fractures to the sternum is inflated by the fact that this element was recorded only at Lyminge and Uley.

#### Fishbourne

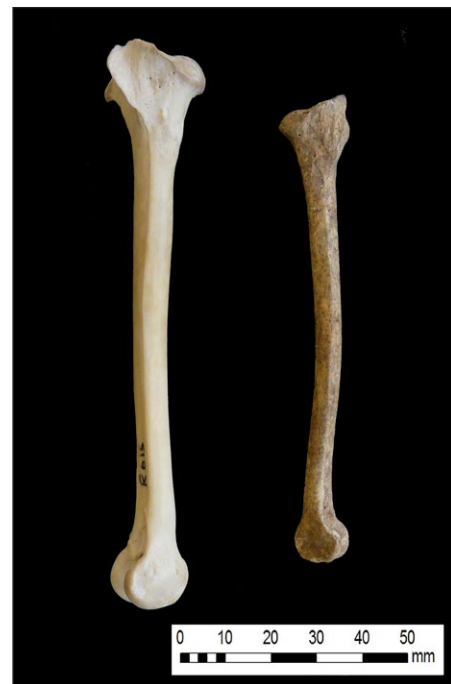The Fishbourne assemblage has the highest overall proportion of pathologies in the assemblages considered here, and five osteopetrotic lesions are present in comparison to two at Princesshay and one at Uley. Fishbourne has no pathologies unique to the assemblage, but a combination of lesions present in a femur is consistent with infection by a pyogenic agent (pus-producing bacteria), there are five examples of lesions consistent with arthropathy, and two fractures were also noted.

#### Flixborough

Flixborough had the lowest proportion of pathologies present. Thirteen elements showed signs consistent with arthropathy and two fractures were recorded (Figure 19). Shape change, in the form of angular deformity (approximately 5°) and bowing in a medio-posterior direction, was present in five tibiotarsi. This pathology was only identified at Flixborough (Figure 20). These changes were not consistent with those associated with avian tibial dyschondroplasia (Fothergill et al. 2012). Furthermore, no evidence of fracture was detected and the length of affected elements was consistent with others from the same site,



**Figure 19:** Simple transverse fracture in a tarsometatarsus from Fishbourne (FB67, 397 (5)).

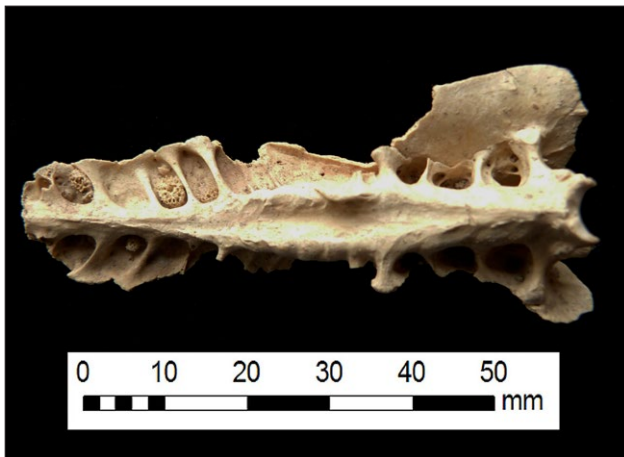


**Figure 20:** Shape change in a tibiotarsus from Flixborough (FLX89, 5617) with a modern comparative (left).

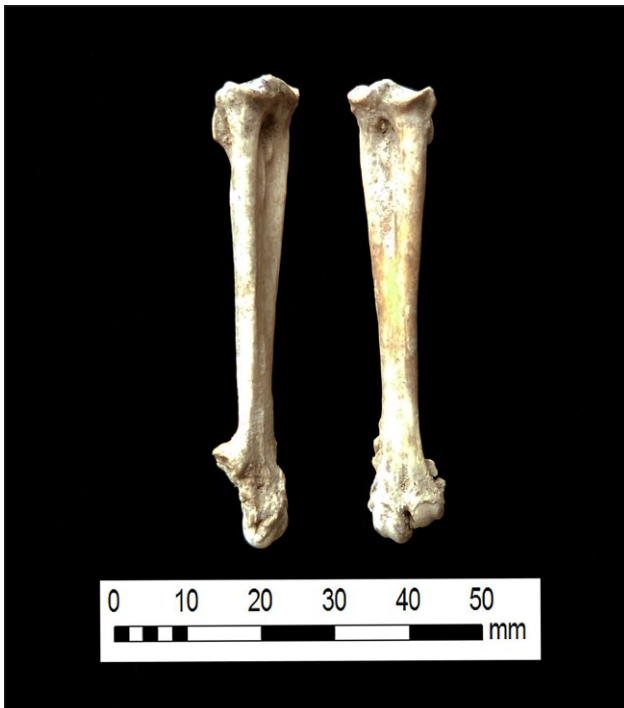eliminating chondrodystrophy (Gordon et al. 2015). The appearance of these elements is consistent with a bone mineralisation failure due to a metabolic disease, such as osteomalacia or rickets (Thorp 1994: 213).

#### Lyminge

In addition to having the highest proportion of lesions consistent with arthropathy (1.4% of all chicken elements,  $n = 34$ ) and nine instances of fracture, two groups of lesions occurred only at Lyminge. The first of these is new bone formation of unknown aetiology in three synsacra (Figure 21), an element not represented in the Fishbourne, Flixborough, or Princesshay assemblages. These resemble a condition previously described in chicken remains excavated from Post-Medieval Chester (Gordon 2016). The second group consists of eight mature tarsometatarsi with a constellation of lesions resembling arthropathy (marginal, prolific osteophyte formation; eburnation or pitting of articular surfaces, Figure 17), but with the addition of noticeable expansion of the proximal metaphysis and necrosis (Figure 22). One possibility is a more specific diagnosis of viral arthritis, wherein



**Figure 21:** Synsacral neoplasia (new tissue with a spongy appearance in cavities between the synsacro-caudal vertebrae) from Lyminge (LYM09, 1333).



**Figure 22:** Pedal pathology unique to Lyminge (LYM09, 1500).

the bony tissue of the proximal tarsometatarsus ('hock joint') in chickens may have an inflammatory reaction (Glass et al. 1973). In addition, 53% of lesions at Lyminge affected tarsometatarsi and phalanges, the highest proportion of pedal pathology in any assemblage (the second highest is Uley, 20%; Fishbourne and Flixborough had 10%, and Princesshay had none).

#### Princesshay

Although Princesshay was the smallest assemblage examined for this study, it was second only to Fishbourne with regard to overall pathological frequency. We noted two pathologies consistent with arthropathy and one lesion diagnostic of avian osteopetrosis. Prin-

cesshay has similar proportions of lesions consistent with arthropathy (0.82% of all chicken elements) to Fishbourne (0.87%).

#### Uley

Oral pathology and other lesions in the caprine remains excavated from Uley were reported (Levitan 1993), but these were not described in other taxa. Although the faunal report states that the avian assemblage was to undergo specialist palaeopathological analysis, this was never undertaken (Levitan 1993: 2:A8). From our re-analysis, nine elements from Uley bear lesions consistent with arthropathy, three fractures are present, one instance of osteopetrosis was diagnosed, and one distal tibiotarsus shows evidence of infection by a pyogenic agent.

#### Medullary bone and eggshell

The rates of medullary bone presence and absence have provided intriguing insights into chicken husbandry and egg-laying at each site.

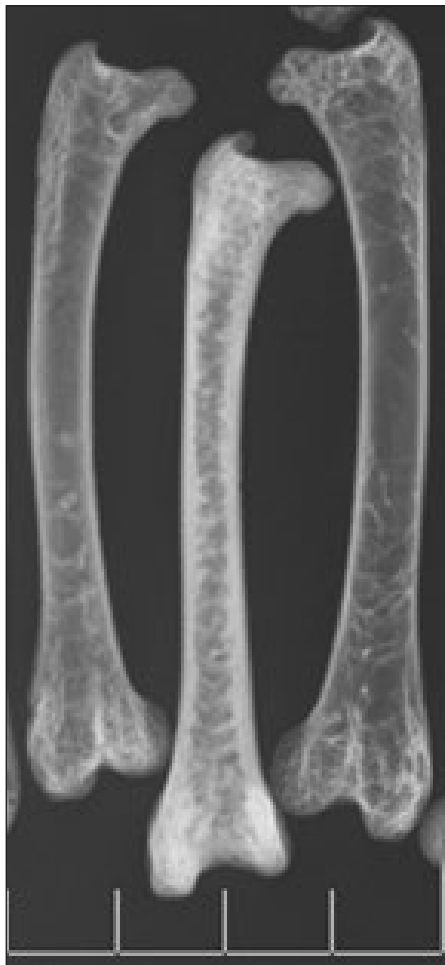#### Fishbourne

Eggshell was reportedly found in one trench within the internal garden at Fishbourne, but unfortunately it has subsequently been lost and was not available for analysis. No eggshell was recovered from other areas of the site (Allen 2011: 233–234). This may be due partially to recovery practices, as much of the zooarchaeological material comes from the 1960s excavations in which faunal remains were entirely hand-collected. However, no eggshell was recovered from later wet-sieved excavations either (Allen 2011). Medullary bone can therefore be a valuable tool for providing insights into potential egg laying profiles of flocks at or near Fishbourne. Birds and eggs may have been brought into or moved out of the site, and as such these birds may not have been laying at Fishbourne. Similarly, eggshell presence does not necessarily prove on-site egg production. Nonetheless, medullary bone profiles identify the presence of egg-producing hens in the Fishbourne faunal resources. Overall, 247 adult chicken femora were identified (in the larger assemblage NISP of 910, rather than the observed NISP of 570 used for metrical analyses). When medullary bone was observed only in fragmented bones, it was identified in 17% of the femora assemblage. However, many of the femora were whole and medullary bone could therefore not be examined. Under x-ray analysis, medullary bone was identified in 35% of the whole femora. This increased the overall occurrence in femora from 17 to 28%. Unlike the femora, most of the tibiotarsi were fragmented, and as such x-ray analysis did not alter the observed occurrence of medullary bone in 7% of these elements. When all skeletal elements are considered, at least 10% of the Fishbourne adult NISP were medullary-bearing bones from females around the time of lay. Due to the relatively high occurrence of skeletal elements that were less likely to contain medullary bone, and the greater reliability of femora for displaying medullary bone in laying chickens, this overall frequency of breeding females is very likely to be underestimated. Using femora

and/or tibiotarsi as a proxy is therefore a valuable method of sex profiling. Although it can be difficult to accurately measure the extent of medullary bone fill of the endosteal cavity in some x-rayed specimens, it appears that in over two-thirds of cases where it occurred, it was primarily present in thin layers, perhaps suggesting that birds ceasing to lay were culled (**Figure 23**). This observation is supported by the fragmented bone assemblage, wherein 64% of medullary bone occurrences were thin fills or consisted of very small traces.

#### Flixborough

In the observed sample of x-rayed elements from Flixborough, medullary bone occurred in at least of 33% of the femora and 19% of the tibiotarsi. Medullary bone was rarer in other skeletal elements, but in the small fragmented assemblage that was recorded during sample extraction, it was also observed in both the coracoid and tarsometatarsus. Although some of the bones have medullary deposits filling the majority of the endosteal cavity, in 50% of the x-rayed samples the medullary bone is only present only as a thin trace. This may indicate that whilst birds were killed at a variety of times and points of life, slaughter of females may have been focused on birds



**Figure 23:** Example femora from Fishbourne showing (left to right), no medullary bone, a characteristically thin layer of medullary bone, and no medullary bone.

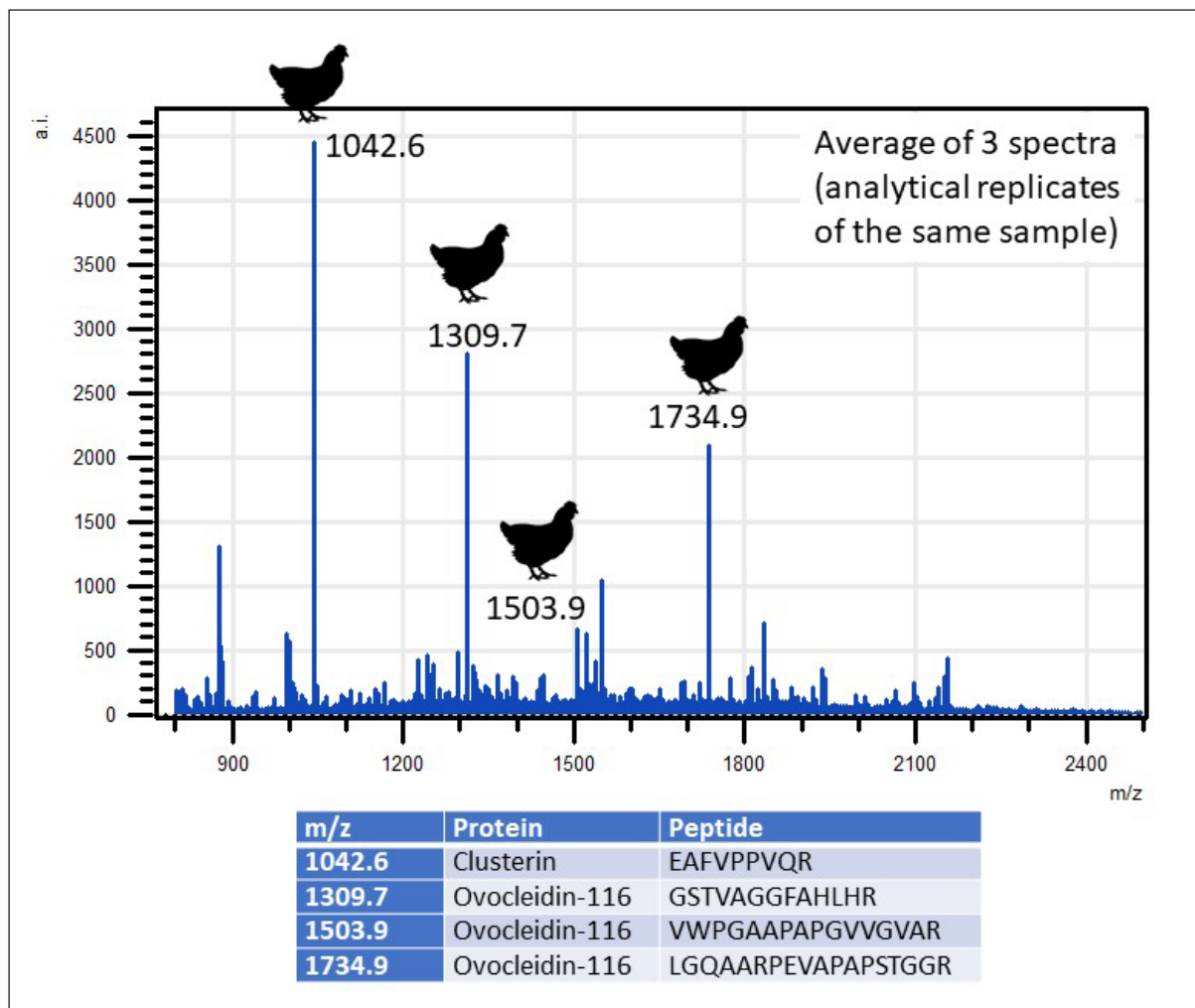
that were at the end of laying (either temporarily, e.g. the moult, or more permanently as a result of increased age or poor health).

A large quantity of eggshell was recovered from Flixborough, particularly from Phase 4–5b (the postulated monastic phase) (Dobney et al. 2007: 52–53, 180–181). Fifty samples, covering all phases and feature types, were analysed, representing a total of 312 eggshell fragments. From the designated contexts, fragments of the eggshell assemblage were randomly selected to reduce the chance of unintentional species-biased selection. As eggshell cannot be quantified like bone due to the lack of diagnostic zones, it is plausible that several fragments in a context originate from the same egg. However, the degree of variation in mammillae size and shape suggested that multiple different eggs per context were present. Chicken was by far the most common species represented (a representative ZooMS spectrum is shown in **Figure 24**), with much smaller quantities of goose eggs (which appear from ZooMS and microscopy to be predominantly grey geese, *Anser sp.*). Most of the chicken eggshell fragments came from freshly laid eggs (**Figure 25**), which, if fertile, were within approximately the first 10 days of incubation (Best et al. Unpublished; Beacham and Durand 2007; Blom and Lilja 2004; Karlsson and Lilja 2008). A small number of chicken eggshells displayed limited, regular, mammillae reabsorption, characteristic of chick development, but no conclusively hatched chicken eggs were identified.

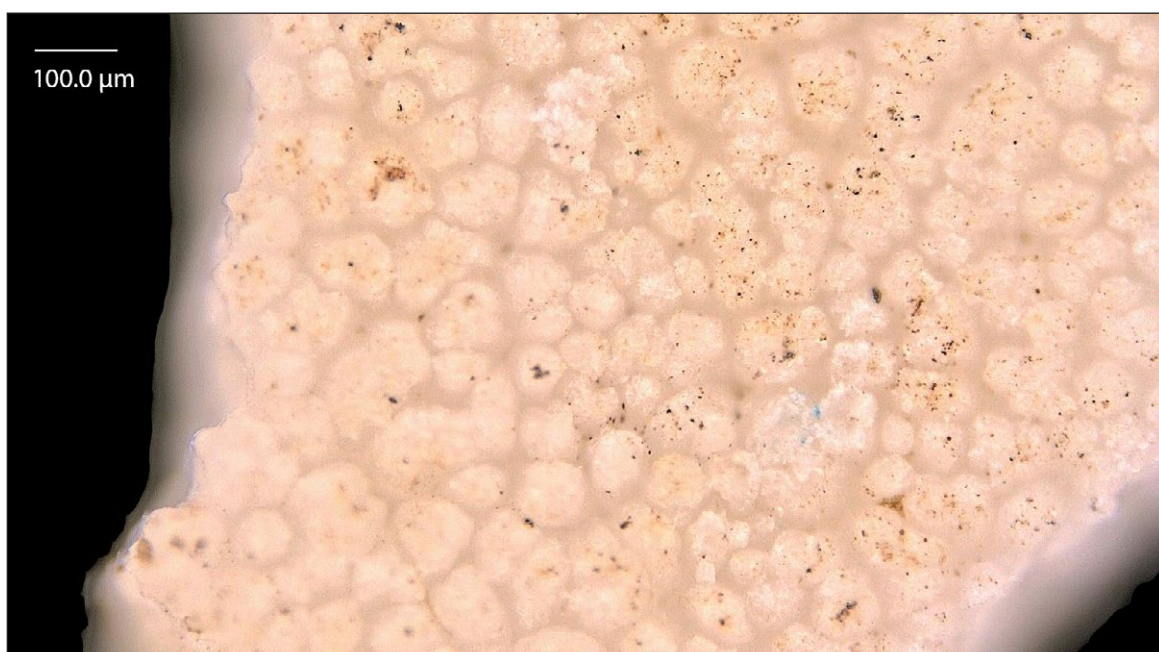
#### Lyminge

No eggs were recovered from this site (potentially due to damage through leeching in the chalk, or as a result of anthropogenic activities). Despite this, the disarticulated bone assemblage (excluding ABGs) demonstrates that Lyminge had a high occurrence of laying females, with 49% of complete femora and 36% of complete tibiotarsi containing medullary bone. When combined with the occurrences recorded in fragmented bones, medullary bone was present in at least 28% of the total adult femora and 25% of the tibiotarsi. The fill was often substantial, indicating that these birds were in active lay around the time of death. This was particularly noticeable in the femora, where medullary bone filled the endosteal cavity in 47% of the x-rayed specimens with medullary bone, and a further 37% were half full. A comparable state of fill was also observed in the fragmented bones. Notably, 80% the medullary bearing bones identified by x-ray correlated with metrically-assigned females. The remaining 20% were bones that could not be metrically assigned to sex. Within the fragmented assemblage, medullary bone was found in one spurred tarsometatarsus. Due to the high standard of recovery at Lyminge and the presence of large numbers of skeletal elements that rarely contained medullary bone or were unsuitable for x-ray analysis, the proportion of medullary-bearing bones as part of the overall adult NISP appears unremarkable (4%). However, its frequency in the most representative elements (femora and tibiotarsi) indicates that egg laying females were a key part of the Lyminge avian population.





**Figure 24:** Representative mass spectrum (ZoomS) of one Flixborough chicken eggshell fragment from a late 7th to mid-8th century AD dump deposit (average of three analytical replicates). The identified taxonomic markers are highlighted (following Presslee 2015; Presslee et al. unpublished).



**Figure 25:** Microscopy showing a freshly laid chicken egg from a ninth to early tenth-century pit fill at Flixborough.

The site produced a large number of ABGs, a minimum of nine. Of the eight adult ABGs, four were definitely females in part of the laying phase, and at least one other was probably female (based on metrics and the absence of a tarsometatarsal spur). These ABGs also enabled examination of medullary bone throughout the skeleton of individual birds (**Figure 26**). As expected, medullary deposits occurred most frequently and extensively in the femur and tibiotarsus, but also in smaller quantities in the ulna, tarsometatarsus, and coracoid. This pattern is largely consistent for Romano-British and Medieval chicken populations, and correlates with medullary bone formation occurring primarily in skeletal elements with a good blood supply, however, the skeletal distribution varies by individual, location, period, and potentially breed-specific factors (Best unpublished; van Neer et al. 2002: 129–132).

#### Princesshay

No eggshell was recovered at this site. Medullary bone was not identified in any of the fragmented material, nor was any visible in the x-ray analysis. Whilst this does not negate the possibility that medullary bone may be present in skeletal elements that were not x-rayed (and potentially as very thin traces in the x-rayed material), it is highly likely that most of the birds were not in lay. When combined with the relatively high number of spurs and scars (occurring on 23% of the tarsometatarsi) it is probable that many of these birds were male, although the metrics suggest that females out of lay may also be present.

#### Uley

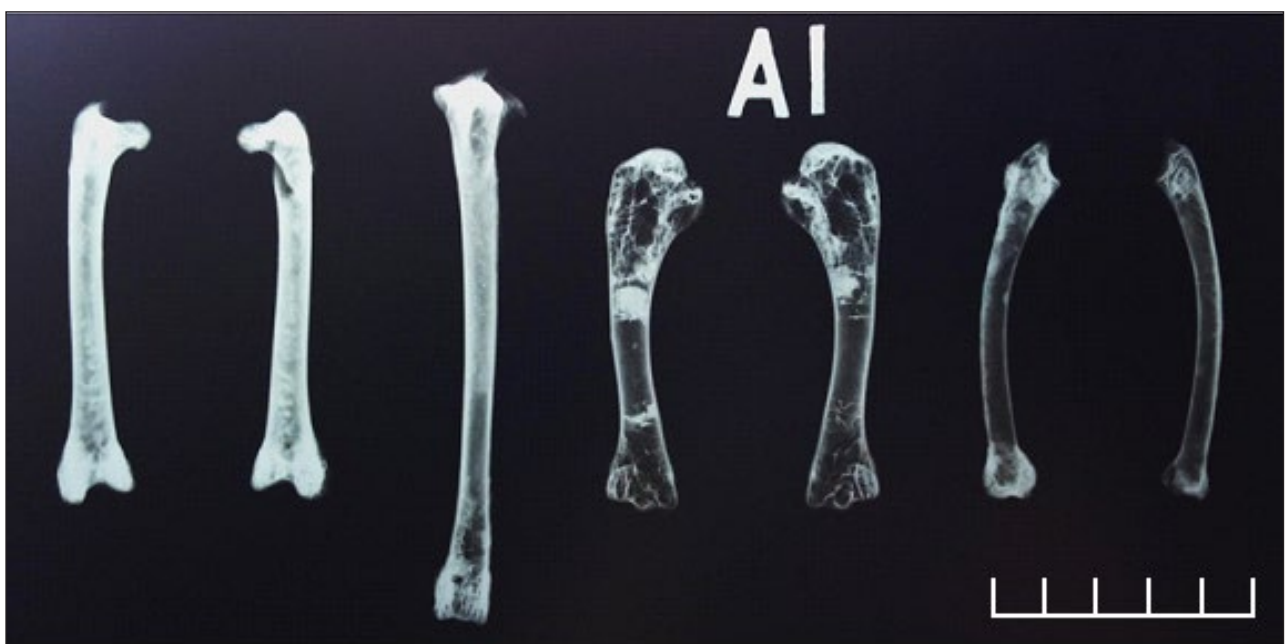No eggshell was recovered from this site. Uley has a very low occurrence of laying females. Medullary bone was recorded in 19 fragmented bones, with a single definitive and three possible identifications noted in the x-rays

(**Figure 27**). Therefore, the minimum medullary bone occurrence accounts for under 1% of the chicken NISP. This fits the overall profile of Uley being very male dominated, but demonstrates that some breeding females were present. Although no medullary bone was identified in the spurred tarsometatarsi, it is possible that elements with medullary bone originated from spurred hens mistaken for male birds.

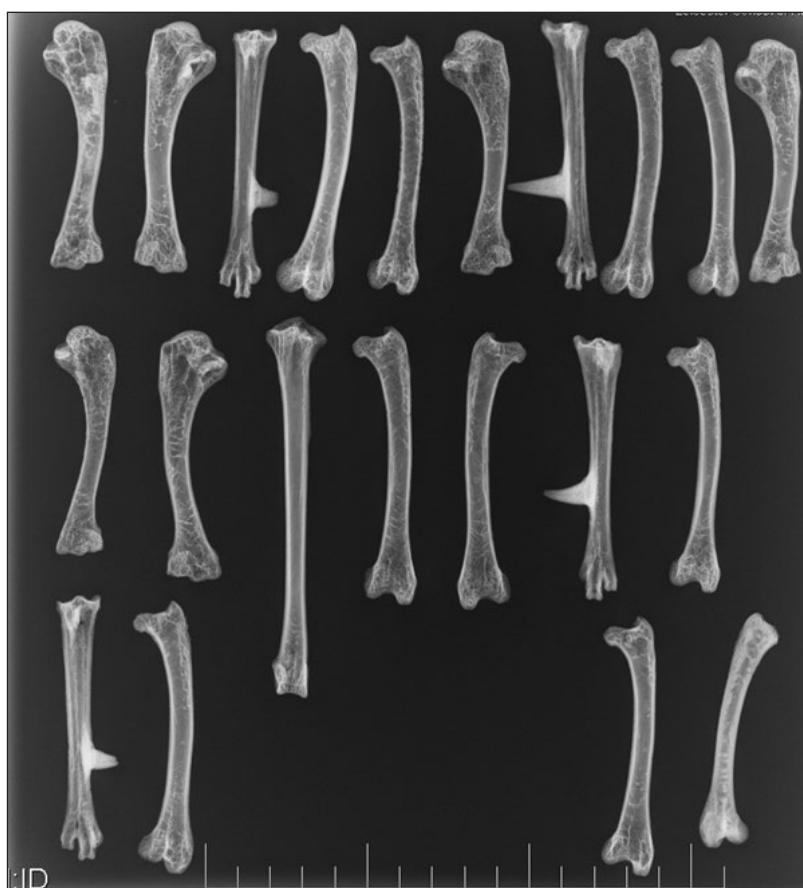#### Discussion

Although a lack of contextual phasing at most sites in this study prevents a more detailed temporal comparison, some similarities are present in assemblages from broadly contemporaneous sites.

Avian osteopetrosis was identified only at the Roman-period sites in this study: Fishbourne, Princesshay, and Uley. Fishbourne and Princesshay also have broadly similar overall proportions of pathology and arthropathy, whilst Uley's values for these are lower than every other site in the study apart from Flixborough (**Table 5**). This may reflect the high proportion of younger animals in the Uley assemblage, which are less likely to accumulate skeletal pathologies over a shorter lifespan. Although the sample of Princesshay element measurements is small, some kernel density estimates show metrical similarities with Uley (**Figures 2–4**). The percentage of chickens as part of the overall Princesshay assemblage is second only to Lyminge in this study. Studies of Roman chicken distribution by site type have indicated that chickens form a larger proportion of faunal assemblages from urban sites (Maltby 1997; 2016), and this is likely a factor in their high representation at this Exeter-based site. Whilst chickens were very probably kept in urban contexts during this period, these birds are unlikely to account for all of the chickens present in these settings, with trade from outside almost certainly



**Figure 26:** ABG1 from Lyminge showing differential deposition of medullary bone throughout the skeleton. Context 680.



**Figure 27:** A selection of femora, tibiotarsi and tarsometatarsi from Uley. Humeri are also included in this x-ray for bone density comparisons. The bottom right femur displays a thin layer of medullary bone.

playing a role (Maltby 1997; 2016). High proportions of chicken are also present in several Roman-period temple assemblages described by King, including Uley (2005: 335), and are a defining characteristic of assemblages from Mithraea (e.g. Lentacker et al. 2004). Although it is likely that many factors are responsible for this pattern, a sacred role for some of the Princesshay chickens cannot be entirely excluded, and this assemblage may contain the remains of animals raised or traded for multiple purposes. Fishbourne metrics show much less definition with regard to sexual dimorphism peaks as compared to Princesshay or Uley, which suggests that a range of differently-sized adult chickens are represented and may hint at chickens being brought in from nearby areas. Some of the Uley kernel density estimates also show clusters of metrical peaks. Although true castration (removal of the testes rather than spur removal) may have been practiced, there is evidence for the existence of chicken breeds in the Roman period (Brothwell 1979), which presents another potential cause for this pattern.

The Anglo-Saxon sites of Flixborough and Lyminge contrast in terms of overall pathological frequency and the incidence of lesion groups. They have the lowest and highest proportions of arthropathy respectively, and each assemblage has different, exclusive lesion groups. Flixborough has lesions consistent with osteomalacia present, whilst Lyminge has a large proportion of pedal pathology, much of which appears arthropathic. It may be that such lesions

inform upon the conditions the Lyminge chickens were housed in, as there is a definitive link between damp environmental conditions and higher rates of pedal pathology, especially in hens (Wang et al. 1998). The metrics in both assemblages are similar, and both sites show distinctive metrical peaks, albeit with generally higher proportions of female elements at Lyminge. This, particularly when combined with the medullary data, suggests the use of an egg production husbandry strategy, and the high proportions of pathology (especially arthropathy) at Lyminge is consistent with chickens kept beyond skeletal maturity. The low overall pathological frequency in the Flixborough assemblage is notable, as few juveniles were identified and the kernel density estimates are split relatively evenly between the sexes. Since male chickens have a reputation for aggression and violence, high frequencies of trauma may have been expected, but this is not reflected in the assemblage. Osteomalacia, a likely cause of the tibiotarsal shape change in the Flixborough assemblage, arises from a deficiency of calcium, phosphorus, or vitamin D, the result of dietary or environmental factors (Thorp 1994: 213). There may have been some human intervention in the lives of chickens at Flixborough, with at a degree of control over feeding and movement to protect the birds from predation and injury, perhaps limiting their diet or exposure to sunlight in the process, and it is possible that the skeletal impact of managed egg-laying also played a role.



One interpretation of the tarsometatarsal metrics from Flixborough is that the greatest length measurements intermediate between the male and female values represent caponised males (Dobney et al. 2007: 171–173). Caponisation (castration of male avians) is not easily detectable in archaeological material, and any attempt to identify capons by metrical methods could be thwarted by variation in analytical practice. Although it is clear from the writings of Aldrovandi that capons were created by surgical removal of their gonads by the seventeenth century AD (1963), earlier methods are not necessarily consistent and Columella describes the process in the first century AD as the removal of the spurs with hot irons (De Re Rustica, vol. 8, ch. 2, 3–6). Evidence of oxen and wethers is attested to by a range of sources, but caponisation of avians in the sense that would impact skeletal development requires invasive, surgical removal of the testes. The kernel density estimates of tarsometatarsal length from Flixborough show a balanced bimodal distribution with more variation than Princesshay, but less variation than Fishbourne, for example (**Figure 8**), and each of these sites was recorded by a different analyst. Whilst it is possible that the chickens of Flixborough were surgically castrated, it may also be that multiple breeds of chicken were kept at the site.

When the outcomes of metrical and palaeopathological analyses are combined with the medullary bone and eggshell results, it is clear that chickens have played multiple and varied roles across the study sites and have been husbanded accordingly. The sex proportions evident in the assemblages from Uley and Princesshay indicate regimes focused on males, probably for sacred and culinary purposes. The importance of sex in selecting appropriate animal sacrifice in the context of Roman religious practices has been discussed extensively (e.g. Ekroth 2014: 334), and undoubtedly played a role in the proportion of male elements recovered from religious sites. Full-sized males may also have been ideal for eating, and their culling would prevent continued resource expenditure on a bird with limited secondary products.

A predominance of hens and a focus on egg production is evident from our analyses of assemblages from Lyminge, Flixborough, and perhaps also Fishbourne. The Medieval study sites more clearly show evidence of managed egg production and hen-focused husbandry regimes, though this could be due in part to individual characteristics of the specific sites considered. Such approaches would have been present in Roman Britain, as both chicken meat and eggs were increasingly important dietary items in this period (Maltby et al. unpublished). At Lyminge, the assemblage with the largest medullary bone dataset, it is apparent that the presence of medullary bone corresponds strongly to the high proportion of metrically-assigned females, highlighting the validity of metrical sexing, whilst demonstrating the value of an integrated approach. Preliminary results from a programme of DNA analysis on Fishbourne, Flixborough, and Lyminge chickens (although targeting a smaller number of samples) also support the observed trends in sex and demography described here (Lebrasseur and Larson pers.

comm.). By combining these approaches, a robust overall demographic profile can be created for site assemblages despite the limitations of individual strands of evidence.

### Conclusion

The metrical, pathological, medullary, and eggshell data show enormous variation across the assemblages from both the Roman and Anglo-Saxon sites, demonstrating the intersection of site characteristics, environmental factors, cultural perceptions, and husbandry strategies.

The Fishbourne chicken assemblage in particular presents a mixed picture. The metrical data suggest that a variety of chicken shapes are present, perhaps different breeds of birds that may have been brought to the site or raised nearby. Of all the sites considered here, the metrical profiles from Fishbourne are the least distinctive, perhaps related to a lack of dimorphic bimodality (e.g. mainly one sex was represented for that element) or representing multiple, overlapping size groups. The medullary results indicate that at least 10% of chicken elements from Fishbourne were from females that died or were killed at around the time of lay. This is far below the metrical estimate for the proportion of females at the site, which is complicated by two factors. Although we did not include juvenile or 'creeper' elements in our metrical analysis, the presence of smaller breeds could be artificially inflating the estimate of females; it is also possible that female chickens were mainly slaughtered when they were past lay, perhaps supported by the insubstantial nature of the medullary bone that was identified in a large proportion of the elements from Fishbourne. The occurrence of medullary bone in 28% of femora (a good medullary reservoir) suggests that this figure may be under-representative. Five instances of avian osteopetrosis, a result of infection by an avian leucosis virus, are characteristic of well-connected sites in the Roman period. This may also support the conjecture that imported flocks included females past their prime egg-laying period. It is also worth considering that some of the dating for this site is limited, and as such there may be diachronic changes in breed size that are not currently detectable but may have influenced trends in the metrical data.

The Flixborough metrical element profiles show balanced bimodal distributions, reflecting roughly equal numbers of males and females. Flixborough had the lowest frequency of pathology overall, as well as the only possible candidates for rickets or osteomalacia across all assemblages. Although medullary bone has only been examined in a sample from this assemblage, the results indicate that laying females were present on site, fairly numerous, and were probably largely killed at the end of their laying lives. The majority of analysed eggshell originated from chicken eggs, and most of these came from eggs which, if fertilised, were less than ten days post-lay. Together, this suggests that egg production was part of the chicken husbandry strategy at Flixborough. Considering the high-status nature of this settlement, it remains to be established whether some of these birds and eggs were being imported into the site, or raised entirely in the locality. However, considering the wider zooarchaeological

evidence, it is likely that a large proportion of the chickens were kept on-site. Current programmes of isotopic and lipid analysis (Miller and Sykes unpublished; Colonese et al. unpublished) may shed further light on this.

In many ways, our results are clearest with regard to Lyminge. The high percentage of chickens in the assemblage, proportion of hens, rates of probable age-related joint disease, and amounts of medullary bone all support the interpretation that the Lyminge chickens were husbanded primarily for egg production. This is in keeping with most readings of the rule of Saint Benedict with regard to monastic diet in the Medieval period, which suggest that eggs could be eaten on most days (Harvey 1993: 61). If so, the management of hens was likely a component of quotidian activity for the monastic community at Lyminge. There is no skeletal evidence of dietary deficiency, but the high frequency of pedal pathology could be partly the result of the environment in which they were kept.

Although the size of the Princesshay assemblage hampers extensive interpretation, some general trends are notable. Firstly, the presence of avian osteopetrosis hints at connections with the Roman world with regard to transport links and husbandry practices. A high number of adults are present in the assemblage, but little arthropathy is present (like Fishbourne). Furthermore, only a third of elements are estimated to be female, and no medullary bone was identified. In fact, the metrical profiles for some elements closely resemble Uley, with multiple peaks and high proportions of males, and it may be that entertainment or sacred practices are in part responsible for this distribution, in addition to other practices. What may be the most important common feature linking these two sites is the high likelihood of birds being traded in from external locations, which may have shaped their respective demographics. At Princesshay, these birds could have been destined for culinary use (and perhaps other roles), whereas the similar profile of birds at Uley were likely to have been selected for sacred activities.

Our findings from Uley are generally consistent with Levitan's interpretation of the assemblage (1993). With high proportions of males, mainly adult, juveniles in later stages of growth, and fewer than 1% of the chicken elements showing medullary bone, it is highly likely that the primary purpose of the chickens in the assemblage was related to sacred activities at the site.

Despite the host of caveats surrounding the survival, recovery, analysis, and reporting of avian remains, our integration of multiple strands of evidence has highlighted aspects of diverse chicken husbandry practices at sites in Roman and Anglo-Saxon England and offers a glimpse of past human-chicken relationships. Many interpretive possibilities exist with regard to the analysis of avifaunal remains, including eggshell, particularly in the light of recent methodological advances. Integrated analyses are becoming more commonplace in avian zooarchaeology, and such endeavours will not only increase our understanding of avian-human interactions, but contribute to the continued development of research on relationships between humans and other animals in the past.

### Acknowledgements

Many thanks to Deborah Jaques, Alison Foster, Charlotte Coles, Katrien Janin, Zoe Knapp, Martyn Allen, Martin Sterry, Sam Presslee, Matthew Collins, Ophélie Lebrasseur, Greger Larson, Gabor Thomas, Richard Thomas, Mark Maltby, and Terry O'Connor for providing data, discussion, and support. We are grateful to NERC/AHRC for grant (NF/2015/2/5), the EPSRC and also the ORAU for enabling the referral to a new programme of radiocarbon dating. We also extend our thanks to Matilda Holmes and two anonymous reviewers, whose comments improved this manuscript. We gratefully acknowledge our project funders, the AHRC, who supported the research described in this paper and the preparation of this manuscript (AH/L006979/1).

### Competing Interests

The authors have no competing interests to declare.

### References

- Aldrovandi, U** 1963 *Aldrovandi on Chickens: The Ornithology of Ulisse Aldrovandi, Vol. II Book XIV (1600)*. Translation by Lind, L R Norman: University of Oklahoma Press.
- Allen, M** 2011 *Animalscapes and empire: new perspectives on the Iron Age/Romano British transition*. (Unpublished thesis (PhD), University of Nottingham).
- Allen, M and Sykes, N** 2011 *New animals, new landscapes and new worldviews: the Iron Age to Roman transition at Fishbourne. Sussex Archaeological Collections, 149: 7–24.*
- Appleby, J, Thomas, R and Buikstra, J** 2015 *Increasing confidence in paleopathological diagnosis—Application of the Istanbul terminological framework. International Journal of Paleopathology, 8: 19–21. DOI: <https://doi.org/10.1016/j.ijpp.2014.07.003>*
- Armour-Chelu, M** 1991 *The faunal remains*. In: Sharples, N (Ed.) 1991 *Maiden Castle: excavations and field survey 1985–1986*. English Heritage Archaeological Report 19, pp. 139–151.
- Ashdown, R** 1979 *The avian bones from Station Road, Puckering*. In: Partridge, C (Ed.) *Excavations at Puckeridge and Braughing 1975–9*. Hertfordshire Archaeology 7, pp. 92–96.
- Baker, J and Brothwell, D** 1981 *Animal diseases in archaeology*. London and New York: Academic Press.
- Bartosiewicz, L** 2008 *Taphonomy and palaeopathology in archaeozoology. Geobios, 4(1): 69–77. DOI: <https://doi.org/10.1016/j.geobios.2006.02.004>*
- Bartosiewicz, L and Gál, E** 2013 *Shuffling nags, lame ducks: The archaeology of animal disease*. Oxford and Oakville: Oxbow.
- Beacham, E B and Durand, S R** 2007 *Eggshell and the archaeological record: new insights into turkey husbandry in the American Southwest. Journal of Archaeological Science, 34: 1610–1621. DOI: <https://doi.org/10.1016/j.jas.2006.11.015>*
- Blom, J and Lilja, C** 2004 *A comparative study of growth, skeletal development and eggshell composition in some species of birds. Journal of Zoology,*

- 262: 361–369. DOI: <https://doi.org/10.1017/S0952836903004746>
- Brandt, K D, Radin, E L, Dieppe, P A and Van De Putte, L** 2006 Yet more evidence that osteoarthritis is not a cartilage disease. *Annals of the Rheumatic Diseases*, 65(10): 1261–1264. DOI: <https://doi.org/10.1136/ard.2006.058347>
- Broderick, L** 2013 *Zooarchaeologica Isca Dumnoniorum*. Exeter: Exeter Archaeology.
- Brothwell, D** 1979 Roman evidence of a crested form of domestic fowl, as indicated by a skull showing associated cerebral hernia. *Journal of Archaeological Science*, 6(3): 291–293. DOI: [https://doi.org/10.1016/0305-4403\(79\)90007-4](https://doi.org/10.1016/0305-4403(79)90007-4)
- Brothwell, D** 2002 Ancient avian osteopetrosis: the current state of knowledge. *Acta Zoologica Cracoviana*, 45(Spec Iss): 315–318.
- Brown, E** 1930 *British Poultry Husbandry – its Evolution and History*. London: Chapman & Hall.
- Cohen, A and Serjeantson, D** 1996 *A Manual for the Identification of Bird Bones from Archaeological Sites*. London: Archetype Publications.
- Columella** 1954–1955 *De Re Rustica* 8.2.3–6. Loeb Classical Library Translation by E. S. Forster and E. Heffner, Harvard: Harvard University Press.
- Demarchi, B, Hall, S, Roncal-Herrero, T, Freeman, C L, Woolley, J, Crisp, M K, Wilson, J, Fotakis, A, Fischer, R, Kessler, B M, Rakownikow Jersie-Christensen, R, Olsen, J V, Haile, J, Thomas, J, Marean, C W, Parkington, J, Presslee, S, Lee-Thorp, J, Ditchfield, P, Hamilton, J F, Ward, M W, Wang, C M, Shaw, M D, Harrison, T, Domínguez-Rodrigo, M, MacPhee, R D E, Kwekason, A, Ecker, M, Kolska Horwitz, L, Chazan, M, Kröger, R, Thomas-Oates, J, Harding, J H, Cappellini, E, Penkman, K and Collins, M J** 2016 Protein sequences bound to mineral surfaces persist into deep time. *eLife*, 5: e17092. DOI: <https://doi.org/10.7554/eLife.17092>
- Dobney, K M, Jaques, D, Barrett, J and Johnstone, C** 2007 *Farmers, monks and aristocrats: the environmental archaeology of Anglo-Saxon Flixborough* (Vol. 3). Oxford: Oxbow Books.
- Ekroth, G** 2014 Animal sacrifice in antiquity. In: Campbell, G L (Ed.) *The Oxford Handbook of Animals in Classical Thought and Life*. Oxford: OUP, pp. 324–354.
- Fothergill, B T** 2016 Urban Animals: Human-Poultry Relationships in Later Post-Medieval Belfast. *International Journal of Historical Archaeology*, not yet paginated. DOI: <https://doi.org/10.1007/s10761-016-0331-z>
- Fothergill, B T, Thomas, R M and Morris, J** 2012 Avian tibial dyschondroplasia in 19<sup>th</sup>-century turkey (*Meleagris gallopavo* L. 1758) remains from the Royal London Hospital. *International Journal of Palaeopathology*, 2(4): 240–45. DOI: <https://doi.org/10.1016/j.ijpp.2012.10.003>
- Glass, S E, Naqi, S A, Hall, C F and Kerr, K M** 1973 Isolation and characterization of a virus associated with arthritis of chickens. *Avian Diseases*, 17(2): 415–424. DOI: <https://doi.org/10.2307/1589226>
- Gordon, R** 2016 *Feeding the city: zooarchaeological perspectives on urban provisioning and consumption behaviours in post-medieval England (AD1500–AD1900)* (Unpublished thesis (PhD), University of Leicester).
- Gordon, R, Thomas, R and Foster, A** 2015 The health impact of selective breeding in poultry: A probable case of ‘creeper’ chicken (*Gallus gallus*) from 16<sup>th</sup>-century Chester, England. *International Journal of Paleopathology*, 9: 1–7. DOI: <https://doi.org/10.1016/j.ijpp.2014.11.003>
- Hamilton, J** 2000 Animal husbandry. In: Cunliffe, B. and Poole, C. (Eds), *The Danebury Environs Programme: The Prehistory of a Wessex Landscape*, Volume 2 – Part 6. Oxford: Oxford Committee for Archaeology, pp. 131–45.
- Harvey, B** 1993 *Living and Dying in England 1100–1540: The Monastic Experience*. Oxford: Clarendon Press.
- Hutt, F B** 1949 *Genetics of the Fowl*. New York: McGraw-Hill, pp. 58–60.
- Jonuks, T, Oras, E, Best, J, Demarchi, B, Mänd, R, Presslee, S and Vahur, S** 2017 Multi-method Analysis of Avian Eggs as Grave Goods: Revealing Symbolism in Conversion Period Burials at Kukruse, NE Estonia. *Environmental Archaeology*: 1–14. DOI: <https://doi.org/10.1080/14614103.2016.1263374>
- Karlsson, O and Lilja, C** 2008 Eggshell structure, mode of development and growth rate in birds. *Zoology*, 111(6): 494–502 DOI: <https://doi.org/10.1016/j.zool.2007.11.005>
- King, A** 2005 Animal remains from temples in Roman Britain. *Britannia*, 36: 329–369. DOI: <https://doi.org/10.3815/000000005784016964>
- Kitch, J** 2006 *Animal bone from White Horse Stone, Aylesford, Kent. CTRL Specialist Report Series*. London: Channel Tunnel Rail Link London and Continental Railways Oxford Wessex Archaeology Joint Venture.
- Legge, A J, Williams, J and Williams, P** 1989 Animal remains from Blackhorse Road, Letchworth 90–95. In: Moss-Eccardt, J (Ed.), *Archaeological investigations in the Letchworth area, 1958–1974. Proceedings of the Cambridge Antiquarian Society*, 77: 35–103.
- Lentacker, A, Eryvynck, A and Van Neer, W** 2004 The symbolic meaning of the cock. The animal remains from the Mithraeum at Tienen (Belgium). In: Martens, M and De Boe, G (Eds.) *Roman Mithraism: the evidence of the Small Finds*. (Vol. 4). Belgium: Instituut voor het Archeologisch Patrimonium, pp. 57–80.
- Levitan, B** 1993 Vertebrate remains. In: Woodward, A and Leach, P (eds.) *The Uley Shrines: Excavation of a Ritual Complex on West Hill, Uley: Gloucestershire, 1977–9*. English Heritage Archaeological Report 17. English Heritage, London. 257–302.
- Loveluck, C and Atkinson, D** 2007 *The early medieval settlement remains from Flixborough, Lincolnshire: the occupation sequence, c. AD 600–1000*. Oxford: Oxbow.



- MacDonald, K** 1992 The domestic chicken (*Gallus gallus*) in Sub-Saharan Africa: a background to its introduction and its osteological differentiation from indigenous fowls (Numidinae and *Francolinus* sp.). *Journal of Archaeological Science*, 19: 303–318. DOI: [https://doi.org/10.1016/0305-4403\(92\)90019-Y](https://doi.org/10.1016/0305-4403(92)90019-Y)
- Maltby, M** 1987 *The animal bones from the excavations at Owlesbury, Hants. An Iron-Age and early Romano-British settlement*. London: Ancient Monuments Laboratory Report 6/87.
- Maltby, M** 1997 Domestic fowl on Romano-British sites: inter-site comparisons of abundance. *International Journal of Osteoarchaeology*, 7(4): 402–14. DOI: [https://doi.org/10.1002/\(SICI\)1099-1212\(199707/08\)7:4<402::AID-OA376>3.0.CO;2-A](https://doi.org/10.1002/(SICI)1099-1212(199707/08)7:4<402::AID-OA376>3.0.CO;2-A)
- Maltby, M** 2016 The Exploitation of Animals and Their Contribution to Urban Food Supply in Roman Southern England. In: Bird, D (Ed.) *Agriculture and Industry in South-Eastern Roman Britain*. Oxford: Oxbow, pp. 180–209.
- Muller, M** 2010 *Muller AO classification of fractures: Long bones*. Duebendorf: American Orthopaedic Trauma Association.
- O'Connor, T** 2008a *The archaeology of animal bones*. College Station: Texas A&M University Press.
- O'Connor, T** 2008b On the differential diagnosis of arthropathy in bovids. In: Grupe, G, McGlynn, G and Peters, J (Eds.), *Limping Together Through the Ages: Joint Afflictions and Bone Infections. Documenta Archaeobiologicae* 6. Rahden/Westf: Verlag Marie Leidorf, pp. 165–186.
- Payne, L N** 1992 Biology of avian retroviruses. In: Levy, J (Ed.) *The Retroviridae*, Vol. 1. New York: Springer, pp. 299–404. DOI: [https://doi.org/10.1007/978-1-4615-3372-6\\_6](https://doi.org/10.1007/978-1-4615-3372-6_6)
- Poole, K** 2010 Bird introductions. In: O'Connor, T and Sykes, N (Eds.) *Extinctions and Invasions: a Social History of British Fauna*, Oxford: Oxbow Books, pp. 156–65.
- Presslee, S** 2015 *Using ancient proteomics to identify the exploitation of bird eggs in archaeological contexts*. (Unpublished thesis MSc), University of York).
- Rothschild, B M** and **Panza, R** 2006a Inverse relationship of osteoarthritis to weight: the bird lesson. *Clinical and Experimental Rheumatology*, 24(2): 218.
- Rothschild, B M** and **Panza, R** 2006b Osteoarthritis is for the birds. *Clinical Rheumatology*, 25(5): 645–647. DOI: <https://doi.org/10.1007/s10067-005-0141-x>
- Rothschild, B M** and **Panza, R** 2007 Lack of bone stiffness/strength contribution to osteoarthritis—evidence for primary role of cartilage damage. *Rheumatology*, 46(2): 246–249. DOI: <https://doi.org/10.1093/rheumatology/kel263>
- Rothschild, B M**, **Xiaoting, Z** and **Martin, L D** 2012 Osteoarthritis in the early avian radiation: Earliest recognition of the disease in birds. *Cretaceous Research*, 35: 178–180. DOI: <https://doi.org/10.1016/j.cretres.2011.12.008>
- Sayer, K** 2013 'His footmarks on her shoulders': the place of women within poultry keeping in the British countryside, c. 1880 to c. 1980. *Agricultural History Review*, 61(2): 301–329.
- Short, B** 1982 'The Art and Craft of Chicken Cramming': Poultry in the Weald of Sussex 1850–1950. *The Agricultural History Review*, 30(1): 17–30.
- Sidell, E J** 1993 *A Methodology for the Identification of Archaeological Eggshells*. Philadelphia: University of Pennsylvania Museum of Archaeology.
- Slavin, P** 2009 Chicken Husbandry in Late-Medieval Eastern England c. 1250–1400. *Anthropozoologica*, 44(2): 35–56. DOI: <https://doi.org/10.5252/az2009n2a2>
- Strid, L** 2015 'Animal bone'. In: Andrews, P, Booth, P, Fitzpatrick, A P and Welsh, K (Eds.) *Digging at the Gateway: archaeological landscapes of south Thanet. The Archaeology of East Kent Access (Phase II), Volume 2: The Finds, Environment and Dating Reports*. Oxford: Oxford Archaeology, pp. 444–460.
- Sykes, N** 2012 A social perspective on the introduction of exotic animals: The case of the chicken. *World Archaeology*, 44(1): 158–169. DOI: <https://doi.org/10.1080/00438243.2012.646104>
- Thirsk, J** 1997 *Alternative Agriculture: a History*. Oxford: University Press.
- Thirsk, J** 2006 *Food in Early Modern England: Phases, Fads, Fashions 1500–1760*. London: Hambledon Continuum.
- Thomas, R H**, **Holmes, M** and **Morris, J** 2013 "So bigge as bigge may be": tracking size and shape change in domestic livestock in London (AD 1220–1900). *Journal of Archaeological Science*, 40(8): 3309–3325. DOI: <https://doi.org/10.1016/j.jas.2013.02.032>
- Thomas, R**, **Sadler, P** and **Cooper, J** 2014 Developmental Osteology of Cross-bred Red Junglefowl (*Gallus gallus* L. 1758) and the Implications for Ageing Chickens from Archaeological Sites. *International Journal of Osteoarchaeology*, 26: 176–188. DOI: <https://doi.org/10.1002/oa.2417>
- Thorpe, B H** 1994 Skeletal disorders in the fowl: a review. *Avian Pathology*, 23(2): 203–236. DOI: <https://doi.org/10.1080/03079459408418991>
- Tomek, T** and **Bochenski, Z** 2009 *A key for the identification of domestic bird bones in Europe: Galliformes and Columbiformes*. Kraków: Institute of Systematics and Evolution of Animals of the Polish Academy of Sciences.
- van der Kraan, P M** and **van den Berg, W B** 2008 Osteoarthritis in the context of ageing and evolution: Loss of chondrocyte differentiation block during ageing. *Ageing research reviews*, 7(2): 106–113. DOI: <https://doi.org/10.1016/j.arr.2007.10.001>
- Vann, S** and **Thomas, R** 2006 Humans, other animals and disease: a comparative approach towards the development of a standardised recording protocol for animal palaeopathology. *Internet Archaeology* 20. DOI: <https://doi.org/10.11141/ia.20.5>
- van Neer, W**, **Noyen, K** and **de Cupere, B** 2002 On the Use of Endosteal Layers and Medullary Bone from

- Domestic Fowl in Archaeozoological Studies. *Journal of Archaeological Science*, 29(2): 123–134. DOI: <https://doi.org/10.1006/jasc.2001.0696>
- Wang, G, Ekstrand, C and Svedberg, J** 1998 Wet litter and perches as risk factors for the development of foot pad dermatitis in floor-housed hens. *British Poultry Science*, 39(2): 191–197. DOI: <https://doi.org/10.1080/00071669889114>
- Wessa, P** 2015 Kernel Density Estimation (v1.0.12) in Free Statistics Software (v1.1.23-r7), Office for Research Development and Education. Available at: [http://www.wessa.net/rwasp\\_density.wasp/](http://www.wessa.net/rwasp_density.wasp/)
- Woodward, A and Leach, P** 1993 *The Uley Shrines: Excavation of a Ritual Complex on West Hill, Uley: Gloucestershire, 1977–9. English Heritage Archaeological Report 17*. London: English Heritage.

**How to cite this article:** Fothergill, B T, Best, J, Foster, A and Demarchi, B 2017 Hens, Health and Husbandry: Integrated Approaches to Past Poultry-keeping in England. *Open Quaternary*, 3: 5, pp. 1–25. DOI: <https://doi.org/10.5334/oq.34>

**Submitted:** 04 May 2017    **Accepted:** 08 August 2017    **Published:** 23 August 2017

**Copyright:** © 2017 The Author(s). This is an open-access article distributed under the terms of the Creative Commons Attribution 4.0 International License (CC-BY 4.0), which permits unrestricted use, distribution, and reproduction in any medium, provided the original author and source are credited. See <http://creativecommons.org/licenses/by/4.0/>.



*Open Quaternary* is a peer-reviewed open access journal published by Ubiquity Press.

**OPEN ACCESS** The Open Access icon, which is a stylized padlock with a circular arrow around it, indicating that the content is freely available.