

AperTO - Archivio Istituzionale Open Access dell'Università di Torino

Age-related vascularization and ossification of joints in children: an international pilot study to test multi-observer ultrasound reliability

This is the author's manuscript

Original Citation:

Availability:

This version is available <http://hdl.handle.net/2318/1658464> since 2018-01-20T23:37:01Z

Published version:

DOI:10.1002/acr.23335

Terms of use:

Open Access

Anyone can freely access the full text of works made available as "Open Access". Works made available under a Creative Commons license can be used according to the terms and conditions of said license. Use of all other works requires consent of the right holder (author or publisher) if not exempted from copyright protection by the applicable law.

(Article begins on next page)

Running title: Vascularization and ossification in healthy children: the OMERACT
paediatric ultrasound task force

**Age-related vascularization and ossification of joints in children: an
international pilot study to test multi-observer ultrasound reliability**

Daniel Windschall, MD¹; Paz Collado, MD, PhD²; Jelena Vojinovic, MD, PhD³; Silvia Magni-Manzoni, MD⁴; Peter Balint, MD⁵; George AW Bruyn, MD⁶; Cristina Hernandez-Diaz, MD⁷; Juan Carlos Nieto, MD⁸; Viviana Ravagnani, MD, PhD⁹; Nikolay Tzaribachev, MD¹⁰; Annamaria Iagnocco, MD¹¹; Maria Antonietta D'Agostino, MD, PhD¹²; Esperanza Naredo, MD⁸; on behalf of the OMERACT paediatric ultrasound subtask force

¹Department of Pediatrics, Asklepios Hospital Weissenfels, Weissenfels, Germany

²Department of Rheumatology, Transitional Care Clinic, Universitario Severo Ochoa, Madrid, Spain

³Department of Pediatrics, Clinical Center, Faculty of Medicine, University of Nis, Serbia

⁴Rheumatology Division, IRCCS Ospedale Pediatrico Bambino Gesù, Rome, Italy

⁵3rd Department of Rheumatology, National Institute of Rheumatology and Physiotherapy, Budapest, Hungary

⁶Department of Rheumatology, MC Groep, Lelystad, the Netherlands

⁷Instituto Nacional de Rehabilitación, Mexico City, Mexico

This article has been accepted for publication and undergone full peer review but has not been through the copyediting, typesetting, pagination and proofreading process, which may lead to differences between this version and the Version of Record. Please cite this article as doi: 10.1002/acr.23335

This article is protected by copyright. All rights reserved.

⁸Department of Rheumatology, Hospital General Universitario Gregorio Marañón and Complutense University, Madrid, Spain

⁹Department of Internal Medicine, ASST Mantova, C. Poma Hospital, Mantova, Italy

¹⁰Pediatric Rheumatology Research Institute, Bad Bramstedt, Germany

¹¹Rheumatology Unit, Università degli Studi di Torino, Turin, Italy

¹²APHP, Hôpital Ambroise Paré, Rheumatology Department, 92100 Boulogne-Billancourt; INSERM U1173, Laboratoire d'Excellence INFLAMEX, UFR Simone Veil, Versailles-Saint-Quentin University, 78180 Saint-Quentin en Yvelines, France

Corresponding author:

Daniel Windschall, MD

Department of Pediatrics, Asklepios Hospital Weissenfels

Naumburgerstrasse 76, Weissenfels 06667, Germany

Tel: 0049-3443 401780, Fax: 0049-3443 401254

E-mail: d.windschall@asklepios.com

Conflict of interest with regard to the work: None

Funding: Roche Pharma; Novartis Pharma

Key Words

Musculoskeletal ultrasound; joint vascularization; skeletal maturation; age-related findings; paediatric cohort

Abstract

Objective To determine the intra- and inter-observer reliability of ultrasound (US)-detected age-related joint vascularization and ossification grading in healthy children.

Methods Following standardized image acquisition and machine setting protocols, 10 international US experts examined four joints (wrist, second metacarpophalangeal joint, knee, and ankle) in 12 healthy children (divided into four age groups: 2–4, 5–8, 9–12, and 13–16 years). Grey-scale was used to detect the ossification grade, and power Doppler (PD) US was used to detect physiological vascularization. Ossification was graded from grade 0 (no ossification) to grade 3 (complete ossification). A positive PD signal was defined as any PD signal inside the joint. Kappa statistics were applied for intra- and inter-observer reliability.

Results According to the specific joint and age, up to four solitary PD signals (mean, 1.5) were detected within each joint area with predominant localization of the physiological vascularization in specific anatomic positions: fat pad, epiphysis, physis, and short bone cartilage. The kappa values for ossification grading were 0.87 (range, 0.85–0.91) and 0.58 for intra- and inter-observer reliability, respectively. The bias-adjusted kappa values for intra- and inter-observer reliability were 0.71 (range, 0.44–1.00) and 0.69, respectively.

Conclusion Detection of normal findings (i.e., grading of physiological ossification during skeletal maturation and identification of physiological vessels) can be highly reliable by using clear definitions and a standardized acquisition protocol. These data will permit development of a reliable and standardized US approach for evaluating paediatric joint pathologies.

Significance and Innovations

Knowledge of age-related ultrasound characteristics of healthy joints is essential to avoid misinterpretation of ultrasound findings in paediatric rheumatology.

Physiological joint vascularization and skeletal maturation show age- and joint-related variability by ultrasound.

After validation in a larger cohort, and our multi-observer study results may help to improve interpretation of normal and pathological musculoskeletal ultrasound findings.

INTRODUCTION

Accurate musculoskeletal ultrasound (US) assessment of disease activity and joint damage is becoming crucial in the clinical management of children with juvenile idiopathic arthritis (JIA). Several studies have reported that US has better sensitivity for detection of joint inflammation than does clinical assessment (1–5). However, before describing abnormalities in pathological conditions, it is important to define B-mode (i.e., grey-scale) and Doppler US findings in healthy children, including the features of different age groups. For this reason, an international paediatric sub-task force of the Outcome Measures in Rheumatology (OMERACT) US Group was created to validate the use of US in the assessment of joints in healthy children. The work of the OMERACT paediatric US task force has involved several steps. First, a Delphi survey that focused on the definitions of US findings in healthy children was developed and circulated among the group of experts (6). A standardized US scanning procedure for children of different age groups was then developed,

including a collection of images showing physiological vascularization at different joint sites (7). More recently, the paediatric US sub-task force focused on the reliability of US in the assessment of normal vascularization and the grading of skeletal maturation in healthy children.

The objectives of the present study were as follows: to assess the intra- and inter-observer reliability of identification of normal joint vascularization in healthy children in different age groups and to evaluate the intra- and inter-observer agreement of a new scoring system for assessing the grade of maturation of ossification nuclei in healthy children.

MATERIALS AND METHODS

Sonographers. Ten international US investigators with a minimum of 2 years of expertise in paediatric US participated in this study. All were members of the OMERACT paediatric US sub-task force and originated from seven different countries (Spain, 2; Italy, 2; Mexico, 1; Serbia, 1; the Netherlands, 1; Hungary, 1; and Germany, 2).

Healthy models. Twelve healthy children (5 girls, 7 boys) ranging in age from 2 to 16 years were recruited for this multi-observer study. The study was approved by the Ethics Committee of the Medical Board of Saxony-Anhalt in Halle, Germany. Written consent was obtained from all parents and children prior to inclusion in the study. Children with infections or other illnesses that could potentially influence the US characteristics of their joints were excluded. According to previous studies (6, 7), the children were stratified into four different age groups (Group 1, 2–4 years; Group 2, 5–8 years; Group 3, 9–12 years; and Group 4, 13–16 years) for the purposes of

statistical analysis. Group 1 included two boys (2 and 4 years) and one girl (3 years), Group 2 included three boys (5, 7, and 8 years) and one girl (6 years), Group 3 included two boys (9 and 11 years) and one girl (10 years), and Group 4 included two girls (14 and 16 years).

Protocol. The study was performed according to the scanning technique proposed in a previous study of the group (7, Suppl. 1). All investigators met for a consensus and training session the day before the exercise. A new semi-quantitative scoring system for assessing skeletal maturation was designed and circulated before the meeting based on a study about the development of ossification nuclei in newborns and the Delphi-consented definitions of the sonographic features of joints in healthy children (6, 8). The new scoring system, which described the steps involved in the skeletal development of long bones, small bones, and the patella on a four-degree scale (Figure 1), was reviewed by all investigators by comparison with representative joint images of variously aged children in the consensus face-to-face meeting. After the 10 investigators achieved 100% agreement on the new scoring system for assessing skeletal maturation, each US expert was assigned to one of three US machines for the practical exercises.

All examinations were performed with three types of real-time US scanners (Logiq S8, Logiq E9, and Logiq E; General Electric Medical Systems, Waukesha, WI, USA) using two types of multi-frequency linear transducers in power Doppler (PD) mode. The broad-spectrum linear matrix array transducer ML6-15-D (bandwidth, 4–15 MHz) was used with the Logiq S8 and Logiq E9, and the broad-spectrum linear array transducer 12L-RS (bandwidth, 5–13 MHz) was used with the Logiq E. PD was selected instead of colour Doppler based on the experience and daily use of the sonographers.

The scanner settings were consistently uniform for all measurements as follows: B-mode frequency, 10 to 15 MHz for all joints (adapted to age and examined joint); PD setting for the knee: pulse repetition frequency [PRF], 0.6 MHz and Doppler frequency [DF], 5 MHz; PD setting for the wrist/tibiotalar joint: PRF, 0.8 and DF, 7.7; and PD setting for the metacarpophalangeal joint (MCP): PRF, 0.8 and DF, 10.

Each child was assigned to undergo unilateral (right-side) dynamic B-mode and Doppler US of the wrist (radiocarpal and ulnocarpal), second MCP joint (MCP II), knee, and tibiotalar joint.

Eleven predefined joint regions were examined by each ultrasonographer in accordance with the recently published systematic method for scanning children (7, Suppl.1). These joint regions were the wrist longitudinal dorsal radial, dorsal midline, and dorsal ulnar regions; the MCP II longitudinal dorsal, lateral, and volar regions; the knee longitudinal suprapatellar (flexed at 30°) and transverse lateral (neutral position) regions; and the tibiotalar longitudinal dorsal lateral, midline, and medial regions. To obtain information on the whole joint, the sonographers were encouraged to sweep the transducer from medial to lateral and from proximal to distal in each joint region. To avoid misinterpretation due to reverberation artefacts, the Doppler box was always extended to the top of the images.

At the level of each examined predefined joint region, all sonographers performed the following tasks:

1. Assessment of physiological age-related vascularization (i.e., count of positive PD signals [visible vessels or vessel segments] and location [epiphysis, physis, fat pad, small bone cartilage] in each joint region).

2. Scoring of the degree of maturation of the ossification nuclei on a semi-quantitative scale (0–3) (Figure 1). Maturation was assessed in each of the following joints: lunate/wrist, metacarpal head/MCP II, patella/knee, and talus/tibiotalus. The definitions of grade 0 to 3 were as follows: Grade 0, nonossified epiphyseal bone, short bones, or patella; Grade 1, small ossification centres, dominant cartilage, and visible growth plate; Grade 2, large ossification centres, thin cartilage, and visible growth plate; and Grade 3, complete ossification.
3. Digital storage of images showing detected vessels.

To analyse the intra- and inter-observer reliability, each healthy child was examined twice and separately by 3 of 10 investigators using the same US equipment. The minimum interval between two assessments by the same sonographer was 4 hours. Each investigator recorded B-mode and PD images according to the proposed aims of the present study.

Statistics. The software package SPSS, version 22 (IBM, Armonk, NY, USA) and the software package R (R Foundation for Statistical Computing, Vienna, Austria) were used for the statistical analysis. Categorical and numerical data are expressed graphically as box-and-whisker plots (median, interquartile range), and nominal and ordinal data are presented as absolute values and percentages. Kappa values and agreement rates (%) were calculated for all inter- and intra-observer reliability analyses. Standard Cohen's kappa coefficients were used for intra-observer reliability of ossification scoring. Light's kappa coefficients were used to analyse the inter-observer reliability of ossification scoring among three operators (9). Additionally, inter- and intra-observer analyses of vascularization data (presence

of vessels/joint) were performed using the prevalence- and bias-adjusted kappa because in cases of a high or low prevalence of vascularization, low kappa values may be obtained even in the presence of high agreement (10, 11). Kappa coefficients were interpreted according to Landis and Koch (0.81–1.00, almost perfect; 0.61–0.80, good; 0.41–0.60, moderate; 0.21–0.40, fair; 0.10–0.20, slight; and <0.10, no agreement) (12).

RESULTS

In total, 48 joints (528 joint regions) of 12 healthy children aged 2 to 16 years were examined. All planned US investigations were performed in all children participating in the study.

Vascularization. The presence of physiological blood flow was detected in all joint regions in children of all ages. The PD signal count (vessels and vessel segments) for each joint and joint region is shown in Figure 2. Positive Doppler signals were most frequently detected in dorsal midline scans for the wrist, in lateral and volar scans for the MCP II, in transverse lateral scans for the knee, and almost equally in dorsal lateral, midline, and medial scans for the tibiotalar joint. Overall, the number of detected vessels, namely PD signals, was highest in the wrist, followed by the tibiotalar joint, knee, and MCP II. More vessels were seen in children aged 2 to 12 years than in those aged 13 to 16 years. In particular, vessels located at the epiphysis, at the physis, and in the small bone cartilage were more frequently detected in children aged 2 to 12 years. Overall, the epiphysis was the location with the highest number of detected vessels, but this varied depending on the joint. More small bone intra-cartilaginous vessels and fat pad vessels were identified in the wrist joint than in the physis or epiphysis. Most vessels in the MCP II were located at the

physis or epiphysis. Most vessels in the knee joint were located in the cartilaginous patella, followed by the fat pad, epiphysis, and physis. The detected vessels in the tibiotalar joint were most numerous in the fat pad, followed by the epiphysis, small bone cartilage, and physis. Examples and a graphical overview of physiological blood flow in various intra-articular joint regions are shown in Figure 3.

Table 1 summarizes the results of the reliability test for detection of physiological age-related Doppler US findings. The table shows the mean intra- and inter-observer kappa values, percentage agreements, and prevalence for the detection of physiological blood flow in the predefined joint regions.

For the wrist, the intra- and inter-observer reliability (percentage agreement/prevalence-adjusted kappa value) for detection of normal vascularization was 100% (kappa, 1.0); for the remaining joints, it varied from a minimum of 67% (kappa, 0.33) (round 1, inter-observer MCP II) to a maximum of 89% (kappa, 0.78) (round 2, inter-observer tibiotalar joint).

Ossification. The new four-degree scoring system for assessing physiological development of skeletal maturation was used in all participants (Figure 1). All degrees of skeletal maturation were observed in our paediatric cohort. The degree of ossification of all investigated joints correlated positively with increasing age (Figure 4).

The intra-observer reliability (percentage agreement/Cohen's kappa value) for scoring of skeletal maturation of the various predefined bones/joints ranged from 86% (Cohen's kappa, 0.85) to 92% (Cohen's kappa, 0.91). The inter-observer reliability (percentage agreement/Light's kappa value) for scoring of skeletal maturation of the various predefined bones/joints ranged from 41% (Light's kappa,

0.37) to 83% (Light's kappa, 0.82). Table 2 summarizes all intra- and inter-observer results, including the prevalence of the different ossification grades scored in our study.

DISCUSSION

There is still uncertainty regarding interpretation of US findings of pathological joint conditions in children because of the paucity of information about the US appearance of joints in healthy children. The first step toward standardization was the development of definitions of the US characteristics of joints in healthy children; the OMERACT US group recently agreed upon such definitions by an international Delphi consensus process (6). Because musculoskeletal US examination of children's joints is influenced by skeletal development and ossification, particularly in young infants in whom the growth plate and anechoic epiphyseal cartilage dominate the US imaging of joints (6), a key step was the development of a standardized method of performing US examinations in paediatric subjects. Consequently, the OMERACT US group developed a protocol designed to standardize the scanning of paediatric joints (7). This recently published study showed that the proposed standard US scans are applicable and reproducible in children regardless of age and that they provide essential information about physiological blood flow. Next, the OMERACT paediatric US group collaborated in an international multi-observer setting to assess the intra- and inter-observer reliability of the new OMERACT standard scans in healthy children.

The development of the skeletal system and the associated different stages of maturity of the ossification nuclei must be taken into account when performing musculoskeletal US in children (6–8, 13–15). At birth, cortical bone is present in

most of the long bone diaphyses, which at that stage are the primary ossification centres; the secondary centres in the epiphyses develop later (6–8). In a recently published US study assessing the skeletal development of neonates, the dimensions of the ossification centres correlated well with the neonates' age and maturity (8). Because children with JIA may have accelerated bone development associated with inflammation and hyper-vascularization of affected joints, assessment of the skeletal maturity of such children's joints could be very useful. On that basis, the OMERACT paediatric US group agreed on a new four-level scoring system for assessing the ossification stages of various joints. To the best of our knowledge, our study is the first to use this new semi-quantitative scoring system to assess skeletal maturity in healthy children (Figure 1). The present study showed that the scores correlated well with the children's ages (Figure 4). In addition, there was excellent intra-observer and moderate inter-observer agreement. Thus, this semi-quantitative scoring system seems to be feasible and should be tested in larger studies and in specific patient subgroups, such as those with JIA.

A very important aim of the present study was to evaluate the applicability and reliability of the recently published and proposed standard method for assessing physiological vascularization of joints in children (7). As several studies have shown, there is increasing evidence that Doppler US has an important role in the management of patients with JIA (16–19). More recent studies have indicated that Doppler US might assist in the evaluation of remission and detection of subclinical inflammatory activity (20–23). It is therefore very important for the sonographer to have experience with the detection of normal physiological joint vascularization to minimize misinterpretation of normal physiological vascularization as inflammation.

In the present study, we analysed the ability of 10 experienced international ultrasonographers to detect normal physiological vascularization in 12 healthy children of different ages. They identified physiological vascularization in all children and in all US scans, finding physiological vessels at the physis or epiphysis of long bones, in the intra-cartilaginous regions of the small bones and patella, and in the fat pad. There were some clear differences between the various examined joints and age groups. The highest number of vessels and vessel dots were detected in the wrist joint, followed by the tibiotalar and knee joints. The MCP II is a small joint and thus had the fewest vessels. Vessels located in the intra-cartilaginous regions of small bones or at the physis or epiphysis were found more frequently in 2- to 12-year-old participants. The presence of physiological vascularization at the physis or epiphysis of long bones and in the intra-cartilaginous regions of small bones seems to be specific to paediatric subjects; this observation requires confirmation by larger studies. In particular, the normal intra-articular vascularization in healthy children must be distinguished from the synovial hyper-vascularization of joints associated with inflammation in children with JIA.

In the present study, the intra- and inter-observer agreement regarding detection of normal vascularization was good except for the MCP II, for which agreement was moderate. The MCP II joint is a very small peripheral joint and showed the lowest number of vessels in our study. One particular factor that may have contributed to the higher variability in detecting vascularization, especially in the MCP II joint, was the very slow blood flow velocity in the normal vessels of joints; this blood flow is also influenced by the environmental temperature and children's activity before the examination. This might be an important issue for investigation in

Accepted Article

further studies. However, the inter- and intra-observer agreement for the MCP II joint was still moderate, requiring inclusion of the MCP II joint in further investigations. Other factors that may have played a role were the use of three different types of machines and the unequal experience of the sonographers in use of these US machines. The reasons for the differences in detecting vascularization among the three US devices cannot be determined because of the small size of our study. All machines were able to detect small vessels in all investigated joints. No obvious differences were present among the various machines and probes. This could be another interesting research topic for larger studies. Ultrasonographic assessment of very young children is often challenging because of their lack of compliance, resulting in the need for a longer examination time to detect small vessels. In the present study, the US examination time for all joints, especially in our smaller probands, was extended by up to 30 minutes compared with about 20 minutes in older children. However, the US examination was successfully completed in all participating probands. Thus, our study showed the presence of vascularization in healthy children's joints, which should be differentiated from possible pathological vascularization. The study also proved that the scanning method is able to detect normal vessels located at the physis or epiphysis, in the intra-cartilaginous regions of small bones, or in the fat pad of joints.

Despite our promising results, this study has several limitations. First, our assessment results using the new semi-quantitative scoring system to grade ossification must be considered unvalidated. Factors influencing the ossification of children's bones, such as sex, hormonal development, activity, hypermobility, and use with respect to side, should be added to further investigations in larger study

cohorts. Our study included only 12 children, and our results are therefore preliminary. Second, our data do not indicate the role of bone ossification in joint vascularization. Because vessels were more frequently located in the intra-cartilaginous regions of small bones or at the physis or epiphysis in younger patients, a lower ossification grade might be correlated with a higher number of detectable joint vessels. However, this theory must be investigated in a further study involving a higher number of probands. Finally, our results regarding vascularization must also be considered preliminary because we were unable to analyse potential influences on vascularization such as temperature, activity, weight, sex, and the use of different US devices in our small study cohort. However, the future task of the OMERACT US group is to review these preliminary results in a larger multicentre study and investigate all of the above-mentioned open questions.

In conclusion, our study provided a new semi-quantitative scoring system for assessing the skeletal maturity of paediatric joints and demonstrated the high reliability of US in the detection of normal joint vascularization. We successfully used the proposed standard scanning approaches to assess physiological vascularization regardless of age. Differences in normal vascularization were also identified depending on age and joint; however, our findings must be considered preliminary because of the small number of children studied. Larger studies with more models are required to validate our preliminary data with respect to side, sex, and age dependency. Another important step is the standardization of synovitis findings in children with JIA, especially regarding the detection of abnormal vascularization.

Acknowledgments

The authors thank all volunteers and their parents who participated in this study.

This study was supported by Novartis Pharma, Germany and Roche Pharma, Switzerland, who had no influence over the study design.

All authors declare that they have no conflict of interest with regard to the work.

References

1. Magni-Manzoni S, Collado P, Jousse-Joulin S, Naredo E, D'Agostino MA, Muratore V et al. Current state of musculoskeletal ultrasound in paediatric rheumatology: results of an international survey. *Rheumatology* 2014; 53: 491-6.
2. Lanni S, Wood M, Ravelli A, Magni-Manzoni S, Emery P, Wakefield RJ. Towards a role of ultrasound in children with juvenile idiopathic arthritis. *Rheumatology (Oxford)* 2013; 52: 413-20.
3. Collado P, Jousse-Joulin S, Alcalde M, Naredo E, D'Agostino MA. Is ultrasound a validated imaging tool for the diagnosis and management of synovitis in juvenile idiopathic arthritis? A systematic literature review. *Arthritis Care Res* 2012; 64: 1011-9.
4. Magni-Manzoni S, Epis O, Ravelli A, Klersey C, Veisconti C, Lanni S et al. Comparison of clinical versus ultrasound determined synovitis in juvenile idiopathic arthritis. *Arthritis Rheum* 2009; 61: 1497-504.
5. Breton S, Jousse-Joulin S, Cangemi C, de Parscau L, Colin D, Bressollette L et al. Comparison of clinical and ultrasonographic evaluations for peripheral synovitis in juvenile idiopathic arthritis. *Semin Arthritis Rheum* 2011; 41: 272-8.

- Accepted Article
6. Roth J, Jousse-Joulin S, Magni-Manzoni S, Rodriguez A, Tzaribachev N, Iagnocco A et al. Outcome measures in Rheumatology Ultrasound Group. Definitions for the sonographic features of joints in healthy children. *Arthritis Care Res* 2015; 67: 136-42.
 7. Collado P, Vojinovic J, Nieto JC, Windschall D, Magni-Manzoni S, Bruyn GA et al., on behalf of the OMERACT Ultrasound Group. Toward standardized musculoskeletal ultrasound in paediatric rheumatology: normal age-related ultrasound findings. *Arthritis Care Res* 2016; 68: 348-56.
 8. Windschall D, Pommerenke M, Haase R. Ultrasound assessment of the skeletal development of the proximal femoral, distal femoral and proximal tibial epiphyses in premature and mature neonates. *Ultrasound Med Biol* 2016; 42: 451-8.
 9. Light RJ. Measures of response agreement for qualitative data: some generalizations and alternatives. *Psychol Bull* 1971; 76: 365-77.
 10. Gwet KL. Handbook of inter-rater reliability: the definite guide to measuring the extent of agreement, 4th ed. Gaithersburg, USA: Advanced Analytics, LLC, 2014.
 11. Feinstein AR, Cicchetti DV. High agreement but low kappa: the problems of two paradoxes. *J Clin Epidemiol* 1990; 43: 543-9.
 12. Landis JR, Koch CG. The measurement of observer agreement for categorical data. *Biometrics* 1977; 33: 159-74.
 13. Collado P, Naredo E. Sonographic images of children's joints. Badalona: Euromedice Ediciones Medicas S.L., 2007.
 14. Spannow AH, Pfeiffer-Jensen M, Andersen NT, Herlin T, Stenbog E. Ultrasonographic measurements of joint cartilage thickness in healthy

children: age- and sex-related standard reference values. *J Rheumatol* 2010; 37: 2595-601.

15. Collado P, Naredo E, Calvo C, Crespo M. Assessment of the joint recesses and tendon sheaths in healthy children by high-resolution B-mode and power Doppler sonography. *Clin Exp Rheumatol* 2007; 25: 915-21.
16. Shahin AA, el-Mofty SA, el-Sheikh EA, Hafez HA, Ragab OM. Power Doppler sonography in the evaluation and follow-up of knee involvement in patients with juvenile idiopathic arthritis. *Z Rheumatol* 2001; 60: 148-55.
17. Wakefield RJ, Balint PV, Szkudlarek M, Filipucci E, Backhaus M, D'Agostino MA et al., for the OMERACT 7 Special Interest Group. Musculoskeletal ultrasound including definitions for ultrasonographic pathology. *J Rheumatol* 2005; 32: 2485-7.
18. Naredo E, Wakefield RJ, Iagnocco A, Terslev L, Filipucci E, Gandjbakhch F et al. The OMERACT Ultrasound Task Force—status and perspectives. *J Rheumatol* 2011; 38: 2063-7.
19. Sparchez M, Fodor D, Miu N. The role of power Doppler ultrasonography in comparison with biological markers in the evaluation of disease activity in juvenile idiopathic arthritis. *Med Ultrason* 2010; 12: 97-103.
20. Rebollo-Polo M, Koujok K, Weisser C, Jurencak R, Bruns A, Roth J. Ultrasound findings on patients with juvenile idiopathic arthritis in clinical remission. *Arthritis Care Res* 2011; 63: 1013-9.
21. Haslam KE, McCann LJ, Wyatt S, Wakefield RJ. The detection of subclinical synovitis by ultrasound in oligoarticular juvenile idiopathic arthritis: a pilot study. *Rheumatology (Oxford)* 2010; 49: 123-7.

22. Bugni Miotto V, de Freitas Tavares da Silva C, de Aguiar Vilela Mitraud S, Nely Vilar Furtado R, Esteves Hilario MO, Natour J et al. Do patients with juvenile idiopathic arthritis in remission exhibit active synovitis on joint ultrasound? *Rheumatol Int* 2014; 34: 937-45.
23. Magni-Manzoni S, Scirè CA, Ravelli A, Klersy C, Rossi S, Muratore V et al. Ultrasound-detected synovial abnormalities are frequent in clinically inactive juvenile idiopathic arthritis, but do not predict a flare of synovitis. *Ann Rheum Dis* 2013; 72: 223-8.

Table 1. Intra- and inter-observer agreement for detection of vascularization

| Joint region | Intra-observer | | | Inter-observer (round 1, round 2) | | |
|--------------|-------------------------------|--------------|-------------------|--------------------------------------|--------------|-------------------|
| | Percentage agreement, mean, % | Kappa*, mean | Prevalence n/exam | Percentage agreement, mean, % | Kappa*, mean | Prevalence n/exam |
| Wrist | 100 | 1 | 72/72 | 100, | 1, | 36/36 |
| | | | | 100 | 1 | 36/36 |
| MCP II | 72 | 0.44 | 56/72 | 67, | 0.33, | 27/36 |
| | | | | 72 | 0.44 | 30/36 |
| Knee | 83 | 0.67 | 62/72 | 83, | 0.67, | 31/36 |
| | | | | 83 | 0.67 | 31/36 |
| Tibiotalar | 86 | 0.72 | 67/72 | 83, | 0.67, | 33/36 |
| | | | | 89 | 0.78 | 34/36 |
| Mean | 85 | 0.71 | | 85 | 0.69 | |

*Prevalence- and bias-adjusted kappa, Prevalence n/exam = prevalence of positive Doppler signals/total number of musculoskeletal ultrasound examinations, MCP II = second metacarpophalangeal joint. Intra-observer analyses included 12 children, 10 observers, 3 observers/child, 72 examinations/joint, and 144 intra-observer tests. Inter-observer analyses included 12 children, 10 observers, 3 observers/child, 72 examinations/joint, and 96 inter-observer tests.

Table 2. Intra- and inter-observer agreement for scoring skeletal development

| Joint region | Intra-observer | | | | Inter-observer (round 1, round 2) | | | | | | | |
|--------------|-------------------------------|-------------------|--|-------|--------------------------------------|-------|-------------------------------|-------------------|--|-------|-------|------|
| | Percentage agreement, mean, % | Cohen kappa, mean | Prevalence n/examinations for ossification grade | | | | Percentage agreement, mean, % | Light Kappa, mean | Prevalence n/examinations for ossification grade | | | |
| | | | 0 | 1 | 2 | 3 | | | 0 | 1 | 2 | 3 |
| Wrist | 86 | 0.85 | 9/72 | 21/72 | 28/72 | 13/72 | 50, | 0.54, | 5/36 | 12/36 | 13/36 | 6/36 |
| | | | | | | | 67 | 0.69 | 4/36 | 9/36 | 15/36 | 7/36 |
| MCP | 92 | 0.91 | 0/72 | 21/72 | 38/72 | 13/72 | 58, | 0.55, | 0/36 | 9/36 | 19/36 | 6/36 |
| II | | | | | | | 66 | 0.64 | 0/36 | 10/36 | 19/36 | 7/36 |
| Knee | 89 | 0.88 | 8/72 | 15/72 | 38/72 | 11/72 | 83, | 0.83, | 4/36 | 7/36 | 19/36 | 6/36 |
| | | | | | | | 58 | 0.53 | 4/36 | 8/36 | 19/36 | 5/36 |
| Tibio-talar | 89 | 0.85 | 0/72 | 16/72 | 42/72 | 14/72 | 58, | 0.49, | 0/36 | 8/36 | 22/36 | 6/36 |
| | | | | | | | 41 | 0.37 | 0/36 | 8/36 | 20/36 | 8/36 |
| Mean | 89 | 0.88 | | | | | 60 | 0.58 | | | | |

MCP II = second metacarpophalangeal joint. Intra-observer analyses included 12 children, 10 observers, 3 observers/child, 72 examinations/joint, and 144 intra-observer tests. Inter-observer analyses included 12 children, 10 observers, 3 observers/child, 72 examinations/joint, and 96 inter-observer tests.

FIGURE LEGENDS

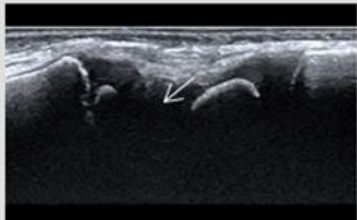
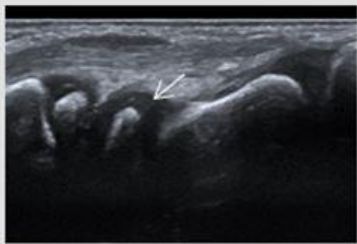

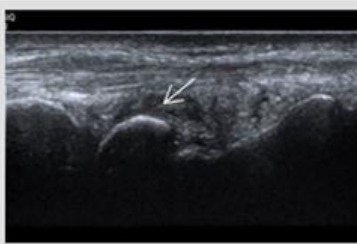
Figure 1. Semi-quantitative four-degree score to assess skeletal development in children.

Figure 2. Registered vessels according to predefined joint region. Data are presented as box-and-whisker plots (median, interquartile range).

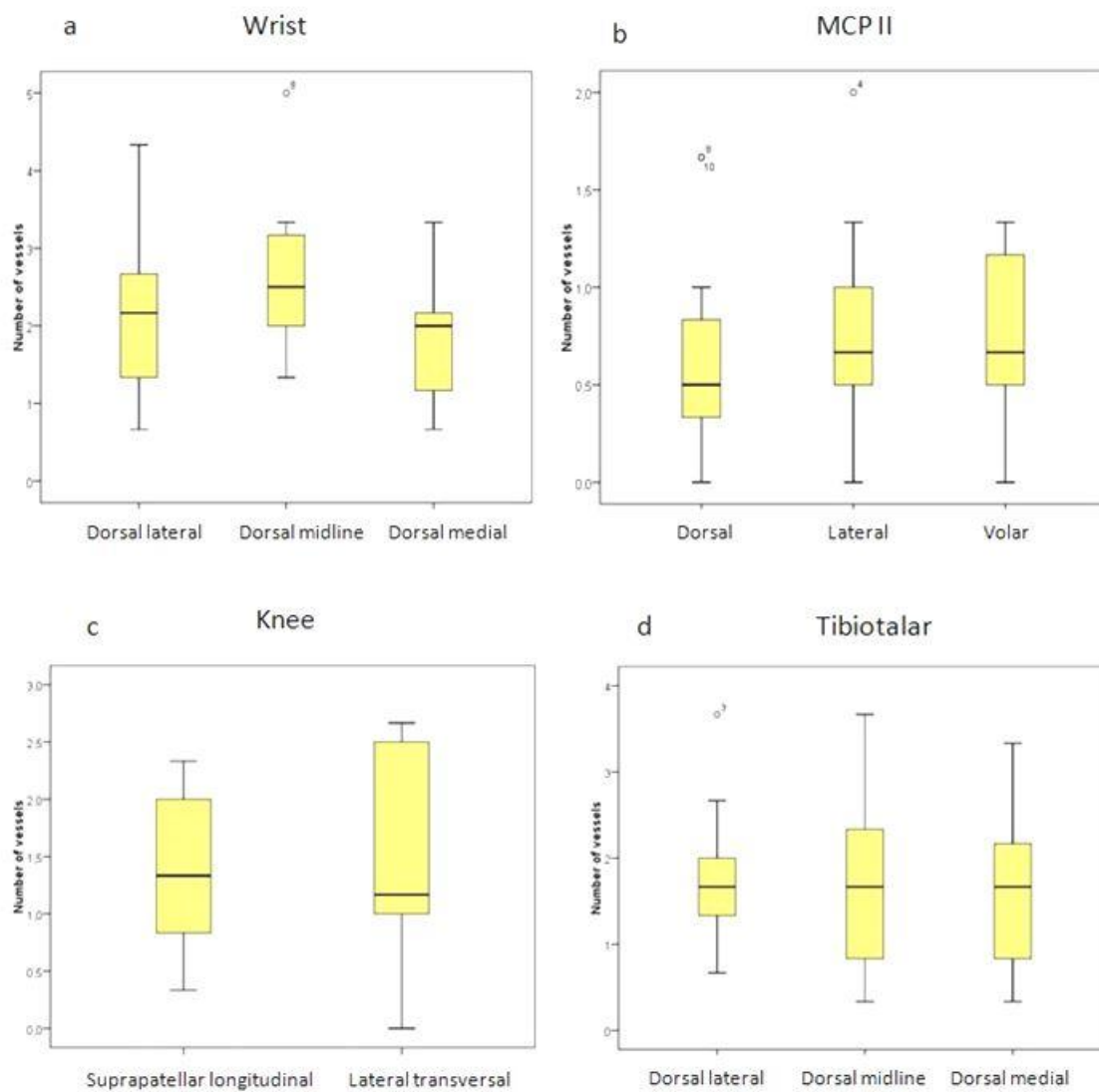
Figure 3. Registered vessels by power Doppler ultrasound. **(A)** Longitudinal scan, radial wrist: vessel located at the epiphysis (boy aged 4 years). **(B)** Longitudinal scan, suprapatellar knee: small vessel located in the intra-cartilaginous/patella region (boy aged 5 years). **(C)** Longitudinal scan, lateral MCP II: small vessel located at the physis (boy aged 7 years). **(D)** Registered locations of vessels according to age group (data are presented as box-and-whisker plots [mean, interquartile range]). Age groups: 1 (2–4 years), 2 (5–8 years), 3 (9–12 years), and 4 (13–16 years).

Figure 4. Scored ossification status of secondary ossification centres according to age group. Age groups: 1 (2–4 years), 2 (5–8 years), 3 (9–12 years), and 4 (13–16 years). Data are presented as box-and-whisker plots (median, interquartile range).

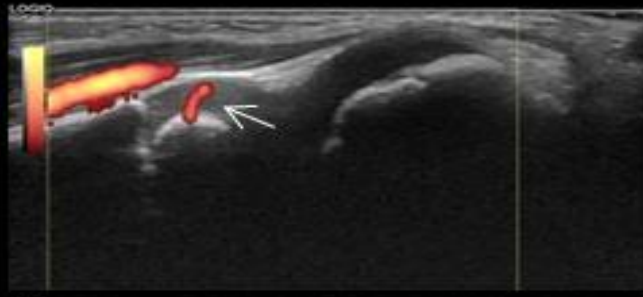
Semi-quantitative ultrasound score for assessing skeletal development (os lunate as example)

| | | |
|----------------------|---|---|
| Ossification grade 0 | Non-ossified epiphyseal bone, short bones or patella. |  |
| Ossification grade 1 | Small ossification centers, dominant cartilage, visible growth plate. |  |
| Ossification grade 2 | Large ossification centers, thin cartilage, visible growth plate. |  |
| Ossification grade 3 | Complete ossification. |  |

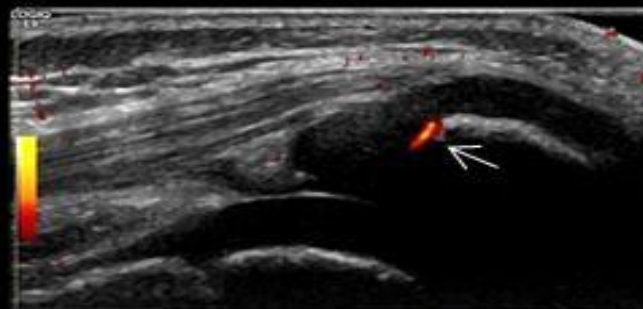
Registered vessels / joint region



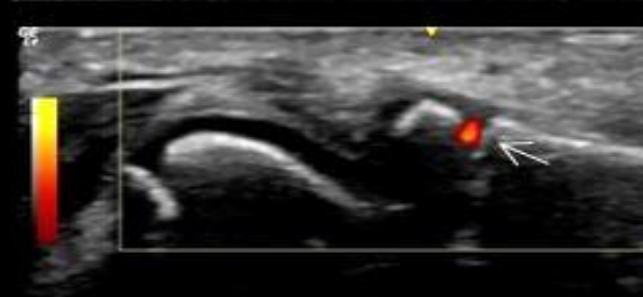
a



b



c



d

