

Embryologic Bases of Extended Radical Resection in Pancreatic Cancer

Felice Borghi, MD; Andrea Gattolin, MD; Diego Garbossa; Fabrizio Bogliatto; Marcello Garavoglia, MD; Alessandro Cesare Levi, MD

Objective: To analyze whether an embryologic “rationale” exists to the clinical and anatomicopathological data that suggest the execution of extended resections in patients with pancreatic cancer.

Methods: Reconstruction of serial histological sections of 18 human embryos and fetuses regarding the pancreatic region; anatomical microdissections of two 9-month fetuses.

Results: The ventral and dorsal pancreatic buds can be identified until the eighth week of development. A close developmental relationship between the dorsal pancreas and the

lymphatic and nervous structures in the dorsal mesogastrium is observed. Other lymphatic stations are exclusively related to the ventral pancreas. The posterior fusion of the dorsal mesogastrium is a late event in embryologic development.

Conclusions: The complete fusion of the 2 pancreatic buds occurs later than previously reported in the literature. The close embryologic relations of these buds with the lymphatic and nervous peripancreatic structures may support the need for extended resections in patients with pancreatic cancer.

Arch Surg. 1998;133:297-301

THE HIGH rate of local recurrence after resection of adenocarcinomas of the head of the pancreas, according to some authors,¹⁻³ is due to early lymph node involvement and local diffusion along lymphatic vessels, peripancreatic nerves, and connective tissues. Based on these premises, Japanese authors⁴ proposed extended radical resection to the second-level lymph nodes and to the peripancreatic tissue, reaching better 5-year survival results, especially regarding small and localized tumors.

Consequently, a new lymph node classification was proposed on the basis of postmortem studies and lymph node involvement in surgical specimens.⁴⁻⁶

The aim of this work was to study the embryologic development of the pancreas and its lymphatic and nervous structures to verify whether clinical and anatomicopathological data may be supported on an ontogenetic basis to increase the knowledge for future clinical studies on extended resections in patients with pancreatic cancer.

RESULTS

We describe the morphogenetic evolution of the pancreas and its lymphatic and con-

nective tissue in chronological order during different periods of aging through their relationships with contiguous organs (stomach, liver, etc) belonging to the mesogastric area (ie, all of the organs contained in the primitive mesogastrium).

CROWN-RUMP 12 mm (5 WEEKS)

The stomach, at the level of the pylorus, appears already to be partially rotated toward the right, and the duodenum is in front of the aorta, with marked proliferation of the mucosa (**Figure 1, A**).

The dorsal mesogastrium goes to the left and reaches the greater curve of the stomach to cover the organ. The glandular bud of the ventral pancreas is close to the anterior wall of the duodenum, the left portal vein, and the primitive common bile duct (Figure 1, B).

Caudally, the glandular bud of the dorsal pancreas, on the contrary, appears inside the dorsal mesogastrium (Figure 1, C).

After surrounding the stomach, the 2 mesothelial folds cover the duodenum, returning to the posterior abdominal wall. The primitive lesser sac appears between the stomach and the dorsal pancreatic bud (Figure 1, D). At this time of evolution, lymphatic structures cannot be found.

From the Department of Clinical Physiopathology, General Surgery Division (Drs Borghi and Gattolin), the Department of Anatomy-Pharmacology and Forensic Medicine (Dr Levi and Messrs Garbossa and Bogliatto), and the General Surgery Division, Hospital of Novara (Dr Garavoglia), University of Turin, Turin, Italy.

MATERIALS AND METHODS

Ten human embryos and 8 human fetuses ranging from 5 weeks (crown-rump, 12 mm) to 9 months were examined during the present investigation. After fixation with 10% formalin or Bouin liquid and embedment of the embryos and fetuses in paraffin, serial transverse and sagittal microtomic sections measuring 5 and 10 mm thick, respectively, were stained using hematoxylin-eosin, Azan-Mallory, Papanicolaou, or Masson modified by Goldberg. Photographs were taken of every section to obtain a 3-dimensional reconstruction of the pancreatic region.

An anatomical dissection of the mesogastric area was performed in two 9-month fetuses using the operative microscope, and was documented by macrophotographs.

CROWN-RUMP 16 TO 20 mm (6-7 WEEKS)

The sagittal sections show that the small bowel is outside the abdominal cavity and that the duodenum is surrounded by the liver.

The anterior wall of the duodenum is in close relation with the ventral pancreas, the distal part of the Wirsung duct, and the common bile duct. The primitive foramen of Winslow is observed in front of the pylorus and above the pancreas. The lesser sac is defined by the posterior reflection of the peritoneal folds after surrounding the gastric antrum. Toward the left, mesenteric vessels appear, modifying the topographic relations of the organs. At this level, the pancreas seems to be divided into 2 portions: the superior portion corresponds to the ventral pancreas, while the inferior portion, ie, the dorsal pancreatic bud, is inside the dorsal mesogastrium. It is in close relation with the lymphatic structures in front of the aorta and with some nerves that originate from the para-aortic plexus and go inside the pancreas itself.

More toward its tail, the pancreas loses its relationship with the posterior abdominal wall.

CROWN RUMP 29 mm (8 WEEKS)

In transverse sections, at the level of the celiac trunk, many lymphatic and nervous structures, the latter reaching the posterior wall of the dorsal pancreas, are observed (**Figure 2, A**).

More caudally, these structures originate in front of the adrenal glands, the kidneys, and the mesenteric vessels, going inside the pancreatic bud. In these sections, the pancreas is in the dorsal mesogastrium and seems to be divided into 2 parts by the superior mesenteric artery and the portal vein. Between the stomach and the pancreas, the lesser sac is well recognizable (**Figure 2, B**).

More caudally, this division increases and the 2 peritoneal folds that leave the gastric lesser curve go forward to the anterior wall of the primitive dorsal pancreas, and the ventral bud of the pancreas is only on the duodenum.

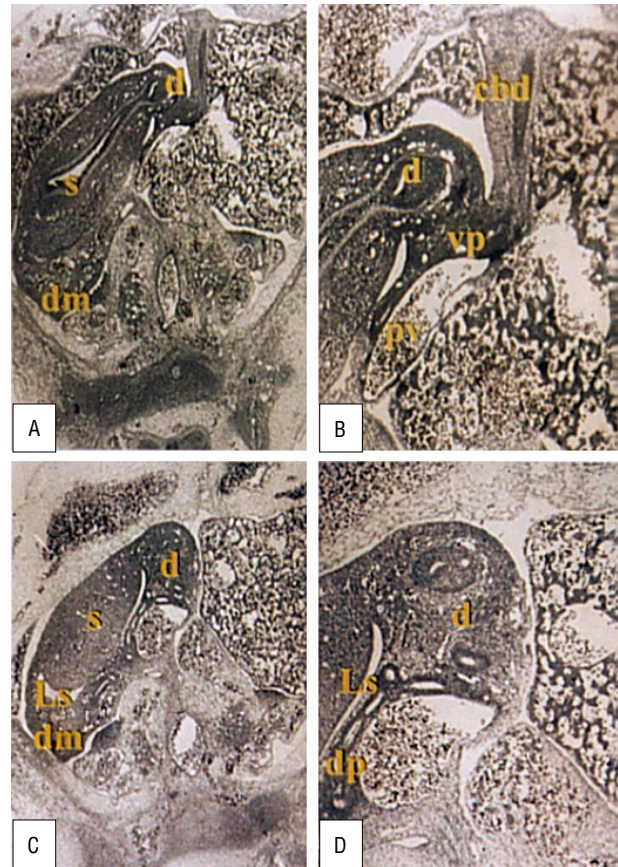


Figure 1. Transverse sections of human embryo crown-rump 12 mm (5 weeks). A and B, The major axis of the stomach (s) is partially rotated to the right, and the duodenum (d) is close to the ventral pancreas (vp) and the common bile duct (cbd). dm indicates dorsal mesogastrium C and D. Caudally, the dorsal pancreas (dp) is inside the dm, and the lesser sac (ls) appears between the stomach and the dorsal pancreas (Papanicolaou, original magnification $\times 40$ [A and C] and $\times 100$ [B and D]).

In all these sections, no lymphatic structures can be found in front of the primitive pancreas.

CROWN-RUMP 30 TO 60 mm (8-10 WEEKS)

At the level of the celiac trunk, inside the dorsal mesogastrium, there is the primitive pancreas, which is not on the duodenum. Behind the pancreas are some nervous and lymphatic structures, which leave the adrenal glands in front of the aorta and reach the pancreatic body following the organization of the celiac trunk. At this time, lymph nodes are well defined and surrounded by their capsule.

Inside the hepatoduodenal ligament we observe some lymphatic structures.

On the right side of the mesenteric artery the lymph nodes reach the posterior wall of the head of the pancreas, and on the left side they go forward to the posterosuperior wall of the pancreatic body. The nerves follow the course of the superior mesenteric artery until they penetrate the pancreas.

The peritoneum covers the pancreas and the duodenum, keeping inside some lymphatic structures that are situated laterally and behind the head of the pancreas.

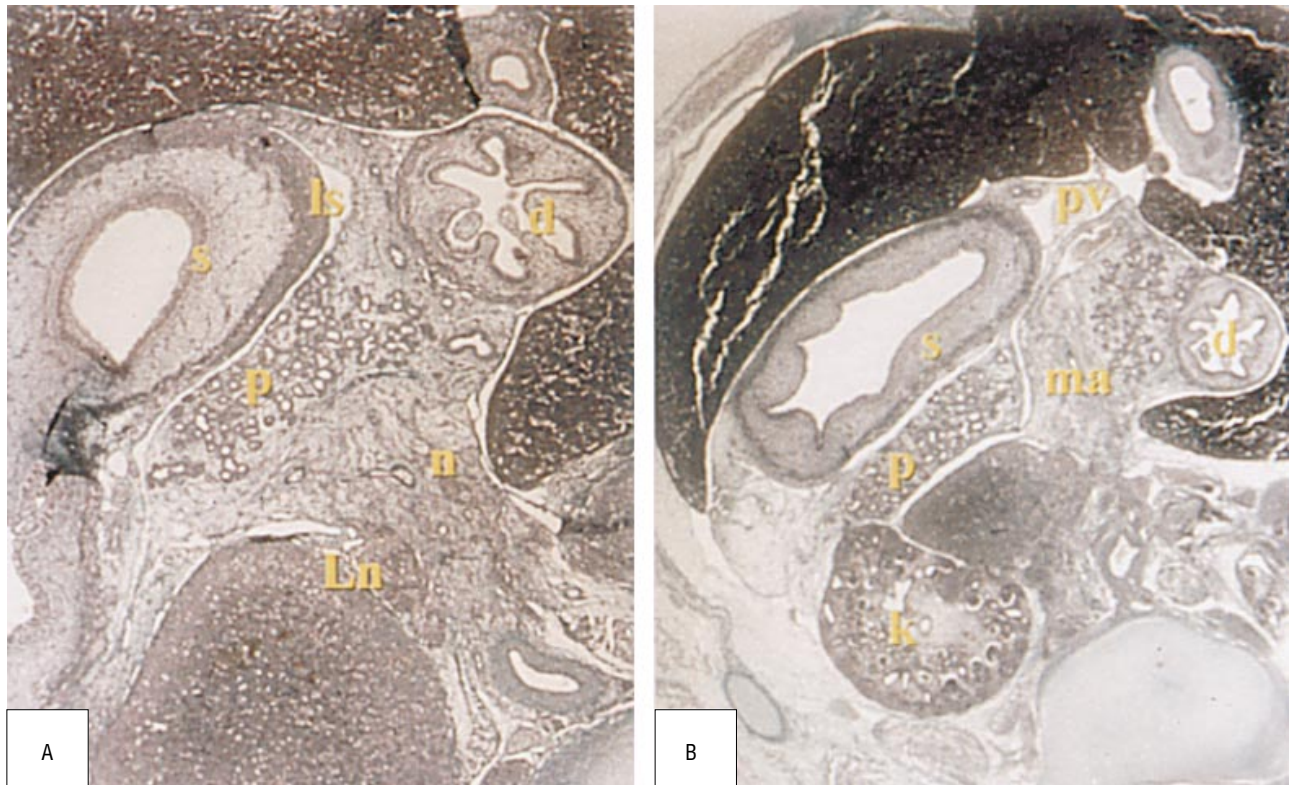


Figure 2. Transverse sections of human embryo crown-rump 29 mm (8 weeks). A, Many lymphatic (Ln) and nervous (n) structures at the level of the celiac trunk reach the posterior wall of the pancreas (p); the lesser sac (ls) is recognizable between the stomach (s) and the pancreas. d indicates duodenum. B, Caudally, the pancreas appears divided into 2 parts from the superior mesenteric artery (ma) and the portal vein (pv); the lymph nodes originate in front of the adrenal glands and the kidneys (k) (Masson modified by Goldberg, original magnification $\times 100$ [A] and $\times 40$ [B]).

CROWN-RUMP 90 TO 170 mm (12-20 WEEKS)

At the level of the celiac trunk, the lymph nodes are intermingled with the nervous elements, both contained inside the dorsal mesogastrium. The lymphatic and nervous structures proceed together, following the way of the splenic vessels, to the superior face of the head and to the body of the pancreas (**Figure 3, A**). In the opposite direction, they are placed inside the lesser omentum, toward the liver, along the way of the hepatic artery, laterally or medially to the artery itself (**Figure 3, B**).

At the origin of the superomesenteric artery we see a lot of para-aortic lymph nodes together with the nervous ganglia of the mesenteric plexus. These lymphatic structures reach the posterior face of the body of the pancreas together with some nervous fibers. At this level, some lymph nodes are found near the common bile duct inside the hepatoduodenal ligament (**Figure 3, C**). More caudally, the head of the pancreas makes close contact with the duodenum only. They are covered together by the peritoneum (**Figure 3, D**).

Some lymph nodes are posterior and caudal to the head of the pancreas, and others are lateral to the superior mesenteric artery.

FETUSES 9 MONTHS OLD

Dissection results of the mesogastric area show a particular weakness between the body and the tail of the pancreas and the posterior abdominal wall and a consequent easy mobilization.

It is possible to recognize the structures of the primitive dorsal mesogastrium, including the primitive pancreatic bud, the spleen, and the peritoneal folds that cover the gastric wall before they are definitely attached. The dorsal mesogastrium is of primary importance in defining the lesser sac.

COMMENT

To correctly and completely comprehend the relations between the pancreas and its lymphatic and nervous structures, it is necessary to examine the embryologic pancreatic evolution in the mesogastric region.

It is commonly considered that the pancreas originates from 2 different buds, ventral and dorsal, that merge during development to make the final organ.⁷⁻⁹ Our observations at the fifth week of embryologic development show that the 2 pancreatic buds are distinct.

In fact, the ventral bud, which is not composed of 2 lobes, as commonly described,¹⁰ is very close to the duodenal wall, the common hepatic duct, and the liver through the left branch of the portal vein. The dorsal bud is located in a more caudal position, unlike what is described in some textbooks, which report it more cranially,⁷ inside the 2 peritoneal folds that define the dorsal mesogastrium, already placed toward the left side.

Regarding the time of fusion of the 2 pancreatic buds, different data are presented in the literature. Some authors⁹ describe the fusion at the fifth week, whereas others suggest that this process is present at the end of the sixth or at the seventh week.¹¹

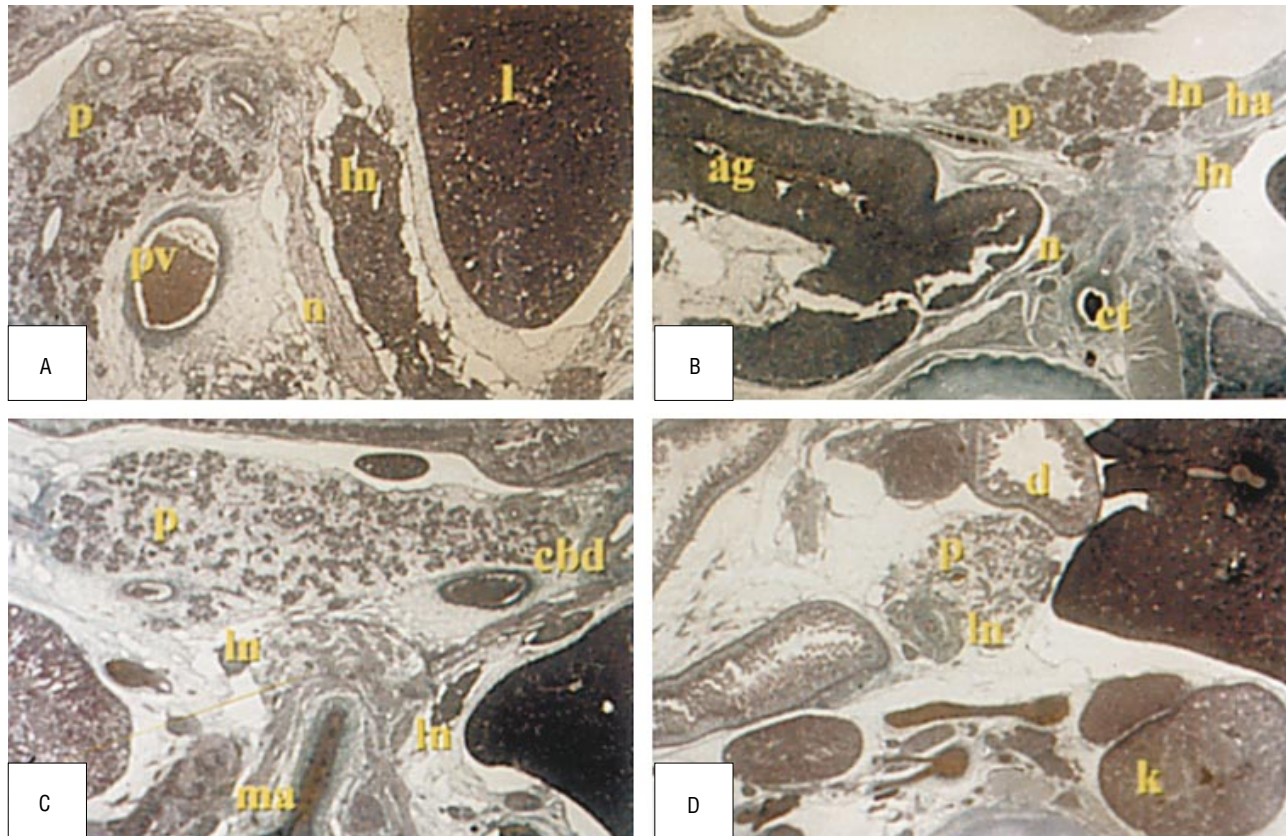


Figure 3. Transverse sections of human embryos at different ages of development. A, Embryo crown-rump 90 mm (12 weeks). The lymph nodes (ln) and the nerves (n) proceed together, following the portal vein (pv), to the superior face of the body of the pancreas (p). l indicates liver. B, Embryo crown-rump 160 mm (20 weeks). The lymph nodes are placed along the way of the hepatic artery (ha). ag indicates adrenal gland; ct, celiac trunk. C, Embryo crown-rump 100 mm (13 weeks). At the level of the superior mesenteric artery (ma) we observe the lymph nodes together with the mesenteric plexus and lymphatic structures near the common bile duct (cbd). D, Embryo crown-rump 100 mm (13 weeks). The head of the pancreas is in relation with only the duodenum (d). Some lymph nodes are posterior to the head of the pancreas. (Masson modified by Goldberg, original magnification $\times 20$ [A, B, and D] and $\times 40$ [C]). k indicates kidneys.

In our 6-week-old embryos, the rotation of the ventral pancreatic bud is not well completed, and therefore it appears still distinct from the dorsal one. Only at the seventh week does the pancreas lie posteriorly in a transversal plane, even if it is always possible to recognize the 2 buds divided from the mesenteric vessels and identifiable by the different pattern of the peritoneal folds reflection.

Following the elongation of the duodenum and the biliary duct, the ventral pancreatic bud goes to a caudal position, defining the uncinete process as shown by O'Rahilly and Muller.¹² Until the 11th week, it is possible to observe that the inferior part of the head of the pancreas has its own peritoneal relations, different from those of the remaining organ.

The lymphatic pathways of the pancreas have been studied by different authors. Evans and Ochsner¹³ show that the lymphatic flow from the posterior wall of the pancreas is drained at first by the pancreaticoduodenal lymph nodes and afterward by the para-aortic groups. More recently, Nagai¹⁴ reported that dye injected into the posterior region of the head of the pancreas drained toward the right or posterior side of the superior mesenteric artery and finally to the para-aortic lymph nodes.

Deki and Sato,⁶ in anatomical studies, hypothesize that this lymphatic pathway reaches the left renal vein. These data are confirmed by the findings in this work.

In fact, since the sixth week of development it is possible to observe the primitive lymphatic structures that extend from the celiac axis to the origin of the superior mesenteric artery and to the renal vessels. These structures are close to the posterior surface of the dorsal pancreatic bud.

Considering the poor surgical results regarding the 5-year survival rate in patients with pancreatic cancer, Ishikawa et al⁴ proposed an extended radical resection on the basis of a detailed classification of the lymph nodes according to their metastatic involvement.⁵

The planning of the lymphatic groups is divided into 2 levels. The level 1 resection includes the following lymphatic groups: the pyloric, the nodes placed, respectively, superiorly or inferiorly to the head of the pancreas, the nodes of the common hepatic artery, the anterior and posterior pancreaticoduodenal, and the group at the origin of the superior mesenteric artery. Our embryologic results confirm that those groups are close to the portion of the dorsal pancreatic bud that later will originate the superior part of the pancreas head. In our opinion, the inferior lymph nodes of the head of the pancreas and the posteroinferior pancreaticoduodenal lymph nodes belong to the ventral pancreatic bud. These data give value to the classification proposed by Kayahara et al,² who distinguish the lymph nodes of the head of the pancreas in the following numbered groups: 13^a and 17^a

and 13_b and 17_b. It was not possible in our study to show the development of the anterior pancreaticoduodenal lymph nodes. The superior and inferior lymphatic groups of the (1) pancreas body, (2) common hepatic duct, (3) celiac trunk, and (4) para-aortic vessels included in the level 2 resection have a common origin with the pancreas placed inside the primitive dorsal mesogastrium; these observations may be an embryologic "rationale" to the clinical studies in favor of an enlarged resection when a carcinoma of the head of the pancreas occurs.

We observe in our embryologic material the nerve fibers that originate from the para-aortic ganglia and reach the posterior face of the dorsal pancreas; they develop first with the lymphatic lacune and then with the lymphatic vessels and the lymphatic groups of the pancreas. The development of these structures takes place inside the mesenchyma of the dorsal mesogastrium, which will originate the retropancreatic connective tissue.

This embryologic and topographic displacement fits well with the tight ontogenetic relation of the nervous, lymphatic, and connective structures, confirming the hypothesis of a precocious metastatic involvement of these structures by a carcinoma of the head of the pancreas.^{2,3,15} So, the necessity suggested by Nagai¹⁴ of a complete remotion of the peripancreatic tissues may too be supported by these data.

Through embryologic study of the mesogastric area, it is also possible to evidence the relations of the organs of this region and the evolution in the displacement of the peritoneal folds of the primitive mesogastrium, from which the lesser sac develops. Even in complete fetuses, we observed a particular weakness between the posterior face of the dorsal pancreas, displaced transversally since the early stages, and the posterior abdominal wall. The persistence of this plane, which looks like the old displacement of the mesogastrium, allows us to easily rec-

ognize a correct surgical cleavage plane of the pancreas, which is not so immediately identifiable in adults.

Reprints: Alessandro Cesare Levi, MD, Department of Anatomy-Pharmacology and Forensic Medicine, C.so Massimo D'Azeglio 52, 10126 Turin, Italy.

REFERENCES

1. Nagai H, Kuroda A, Morioka Y. Lymphatic and local spread of T1 and T2 pancreatic cancer: a study of autopsy material. *Ann Surg.* 1986;204:65-71.
2. Kayahara M, Nagakawa T, Kobayashi H, et al. Lymphatic flow in carcinoma of the head of the pancreas. *Cancer.* 1992;70:2061-2066.
3. Nagakawa T, Konishi I, Higashino Y, et al. The spread and prognosis of carcinoma in the region of pancreas head. *Jpn J Surg.* 1989;5:510-518.
4. Ishikawa O, Ohhigashi H, Sasaki Y, et al. Practical usefulness of lymphatic and connective tissue clearance for the carcinoma of the pancreas head. *Ann Surg.* 1988;208:215-220.
5. Cubilla AL, Fortner J, Fitzgerald PJ. Lymph node involvement in carcinoma of the head of the pancreas area. *Cancer.* 1978;41:880-887.
6. Deki H, Sato T. An anatomical study of the peripancreatic lymphatics. *Surg Radiol Anat.* 1988;10:121-135.
7. Chiarugi G. *Istituzioni di Anatomia dell' Uomo.* Milano, Italy: Vallardi; 1968;8: 298-301.
8. Testut L, Latarjet A. *Traité d' Anatomie Humaine.* 8th ed. Paris, France: Doin G. Editeur; 1931;4.
9. Hamilton WJ, Mossman HW. *Hamilton, Boyd and Mossman's Human Embryology.* Cambridge, Mass: Hefter; 1972.
10. Adda G, Hannoun L, Loygue J. Development of the human pancreas: variations and pathology: a tentative classification. *Anat Clin.* 1984;5:275-283.
11. Skandalakis LJ, Rowe JS, Gray SW, Skandalakis JE. Surgical embryology and anatomy of the pancreas. *Surg Clin North Am.* 1993;73:661-697.
12. O'Rahilly R, Muller F. A model of the pancreas to illustrate its development. *Acta Anat.* 1978;100:380-385.
13. Evans BP, Ochsner A. The gross anatomy of the lymphatics of the human pancreas. *Surgery.* 1954;36:177-191.
14. Nagai H. An anatomical and pathological study of autopsy material on metastasis of pancreatic cancer to para-aortic lymph nodes. *Jpn J Surg.* 1987;88:308-317.
15. Nakao A, Harada A, Nonami T, et al. Lymph node metastases in carcinoma of the pancreas region. *Br J Surg.* 1995;82:399-402.

Surgical Anatomy

The short saphenous vein drains the lateral end of the dorsal venous arch of the foot. It runs below the lateral malleolus along the side of the Achilles tendon between the 2 heads of the gastrocnemius muscle. After piercing the popliteal fascia, it ends partly in the popliteal vein and partly in the profunda femoris vein.