

AperTO - Archivio Istituzionale Open Access dell'Università di Torino

Late-Onset Hepatic Veno-Occlusive Disease after Allografting: Report of Two Cases with Atypical Clinical Features Successfully Treated with Defibrotide

This is a pre print version of the following article:

Original Citation:

Availability:

This version is available <http://hdl.handle.net/2318/1660503> since 2018-02-22T15:46:07Z

Published version:

DOI:10.4084/MJHID.2018.001

Terms of use:

Open Access

Anyone can freely access the full text of works made available as "Open Access". Works made available under a Creative Commons license can be used according to the terms and conditions of said license. Use of all other works requires consent of the right holder (author or publisher) if not exempted from copyright protection by the applicable law.

(Article begins on next page)

Late-Onset Hepatic Veno-Occlusive Disease after Allografting: Report of Two Cases with Atypical Clinical Features Successfully Treated with Defibrotide

Alessia Castellino¹, Stefano Guidi², Chiara Maria Dellacasa³, Antonella Gozzini², Irene Donnini², Chiara Nozzoli², Sara Manetta³, Semra Aydin¹, Luisa Giaccone³, Moreno Festuccia³, Lucia Brunello³, Enrico Maffini³, Benedetto Bruno³, Ezio David⁴ and Alessandro Busca³.

¹ A.O.U. Città della Salute e della Scienza di Torino, Dipartimento di Oncologia, Ematologia, Torino, Italy.

² SODc Terapie Cellulari e Medicina TrASFusionale, AOU Careggi, Firenze.

³ A.O.U. Città della Salute e della Scienza di Torino, Dipartimento di Oncologia, SSD Trapianto allogenico di cellule staminali, Torino, Italy.

⁴ S.C. Anatomia Patologica 1, A.O.U. Città della Salute e della Scienza di Torino.

Competing interests: The authors have declared that no competing interests exist.

Abstract. Hepatic Veno-Occlusive Disease (VOD) is a potentially severe complication of hematopoietic stem cell transplantation (HSCT). Here we report two patients receiving an allogeneic HSCT who developed late onset VOD with atypical clinical features. The two patients presented with only few risk factors, namely, advanced acute leukemia, a myeloablative busulphan-containing regimen and received grafts from an unrelated donor. The first patient did not experience painful hepatomegaly and weight gain and both patients showed only a mild elevation in total serum bilirubin level. Most importantly, the two patients developed clinical signs beyond day 21 post-HSCT. Hepatic transjugular biopsy confirmed the diagnosis of VOD. Intravenous defibrotide was promptly started leading to a marked clinical improvement. Based on our experience, liver biopsy may represent a useful diagnostic tool when the clinical features of VOD are ambiguous. Early therapeutic intervention with defibrotide represents a crucial issue for the successful outcome of patients with VOD.

Keywords: Leukemia, Allogeneic Hematopoietic stem cell transplantation, Veno-occlusive disease, VOD

Introduction. Veno-occlusive disease (VOD), also known as sinusoidal obstruction syndrome (SOS), is a potentially life-threatening complication of hematopoietic stem cell transplantation (HSCT).¹ The diagnosis of VOD is primarily based on clinical criteria defined almost 20 years ago, including the triad of painful hepatomegaly, jaundice and fluid retention.²⁻⁴ This

observation could at least partially explain the highly variable incidence of VOD reported in the literature, ranging from 8% to 14%. VOD usually develops within 20-30 days after HSCT. However, few cases of late-onset VOD have been reported.⁵ According to this observation, the European Group for Bone marrow Transplantation (EBMT) recently endorsed the revised diagnostic criteria

Table 1. Criteria for definition of Late-Onset VOD (according to “The new classification from the European Society for Blood and Marrow Transplantation”, BMT 2016).⁶

Late Onset VOD (> 21 Days after HSCT)
Classical VOD/SOS beyond day 21: Bilirubin \geq 2 mg/dL <u>and two</u> of the following criteria: Painful hepatomegaly OR weight gain > 5% OR ascites
OR Histologically proven VOD/SOS
OR <u>Two or more</u> of the following criteria: Bilirubin \geq 2 mg/dL (or 34 micromols/L) OR Painful hepatomegaly OR weight gain > 5% OR ascites <u>moreover</u> , hemodynamical or/and ultrasound evidence of VOD/SOS

Abbreviations: EBMT =European Society for Blood and Marrow Transplantation; SOS =sinusoidal obstruction syndrome; VOD =veno-occlusive disease. These symptoms/signs should not be attributable to other causes.

for VOD/SOS, which now include either a classical form of VOD and a late-onset variant (**Table 1**).⁶

Here we describe two HSCT recipients who developed late-onset VOD with atypical clinical features.

Case 1. A 55-year-old male was diagnosed with acute myeloid leukemia in May 2015. He failed to achieve the complete remission (CR) after two induction chemotherapy courses with high dose cytarabine, idarubicin and etoposide and salvage treatment with fludarabine and idarubicin. The presence of a matched unrelated donor in the International Marrow Donor Registries prompted us to proceed with an allogeneic HSCT following a “sequential” conditioning regimen. The patient was initially treated with mitoxantrone (6 mg/sqm/day), etoposide (80 mg/sqm/day) and cytarabine (1 g/sqm/day for four days), followed, 10 days later, by a conditioning which included i.v. Busulphan (3.2 mg/kg/day) and Fludarabine (50 mg/mq/day) for four days and the infusion of mobilized donor peripheral blood stem cells (PBSC). Graft-vs.-Host disease (GVHD) prophylaxis consisted of anti-thymocyte globulin, cyclosporine and a short course of methotrexate. An absolute neutrophil count higher than $0.5 \times 10^9/L$ and a platelet count higher than 20.000/mcl were achieved on day + 13. On day + 33, the patient suddenly showed abdominal distension with ascites, increase in liver enzymes (AST 391 U/l, ALT 245 U/l) and in total bilirubin (1.2 mg/dL) and signs of liver and renal insufficiency (INR 1.43; aPTT 65.5’’; serum creatinine value 3.04 mg/dL). The patient did not present either painful hepatomegaly or weight gain >2%, or signs of intestinal or cutaneous acute GVHD. Viral

hepatitis was ruled out by microbiological testing. Ultrasonography showed normal liver parenchyma, regular biliary tract, moderate splenomegaly (15 cm) with ascites and right pleural effusion. Doppler exam ruled out portal vein thrombosis but showed increased portal vein diameter (10 mm) suggestive of portal hypertension. Paracentesis was performed and showed presence of transudate fluid (serum albumin = 3 mg/dL, ascites albumin 1.5 mg/dL, serum-ascites albumin ratio = 2).

Given that clinical symptoms and laboratory tests did not allow to discriminate between VOD, acute GVHD, toxicity or infective causes, a hepatic transjugular biopsy was performed. Histology studies showed the expansion of the hepatic sinusoid spaces, with gaps in the sinusoidal barrier which were highly suggestive of hepatic VOD in the light of the involvement of zone 3, zone 2 and partially zone 1 of the hepatic acinus (**Figure 1**).

Intravenous defibrotide was started at the dose of 6.25 mg/kg QID on day +37 for 21 days, along with ancillary therapy including albumin replacement and low dose diuretics; nonsteroids have been administered. Two-three days after the beginning of defibrotide, the patient showed a marked clinical improvement with gradual improvement and normalization of liver and renal function tests (**Figure 2**). One week after the beginning of defibrotide, the patient developed hemorrhagic cystitis, treated with 2 bladder instillations of hyaluronic acid which led to progressive improvement and complete resolution upon regular discontinuation of defibrotide after 21 days of treatment. Hemorrhagic cystitis did not require an earlier discontinuation of defibrotide. During the treatment course, platelet count

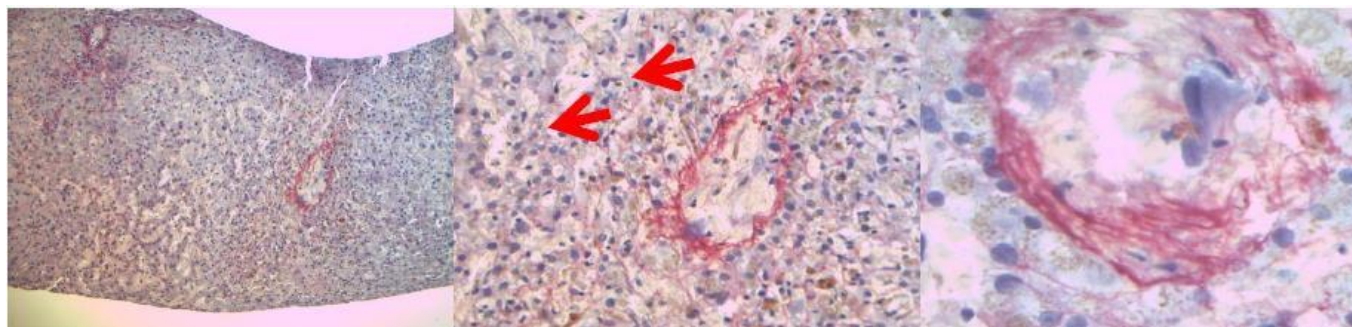


Figure 1. Images of hepatic transjugular biopsy: in the middle, the red arrows showed the expansion of hepatic sinusoid spaces, on the right the figure showed a centrilobular vein.

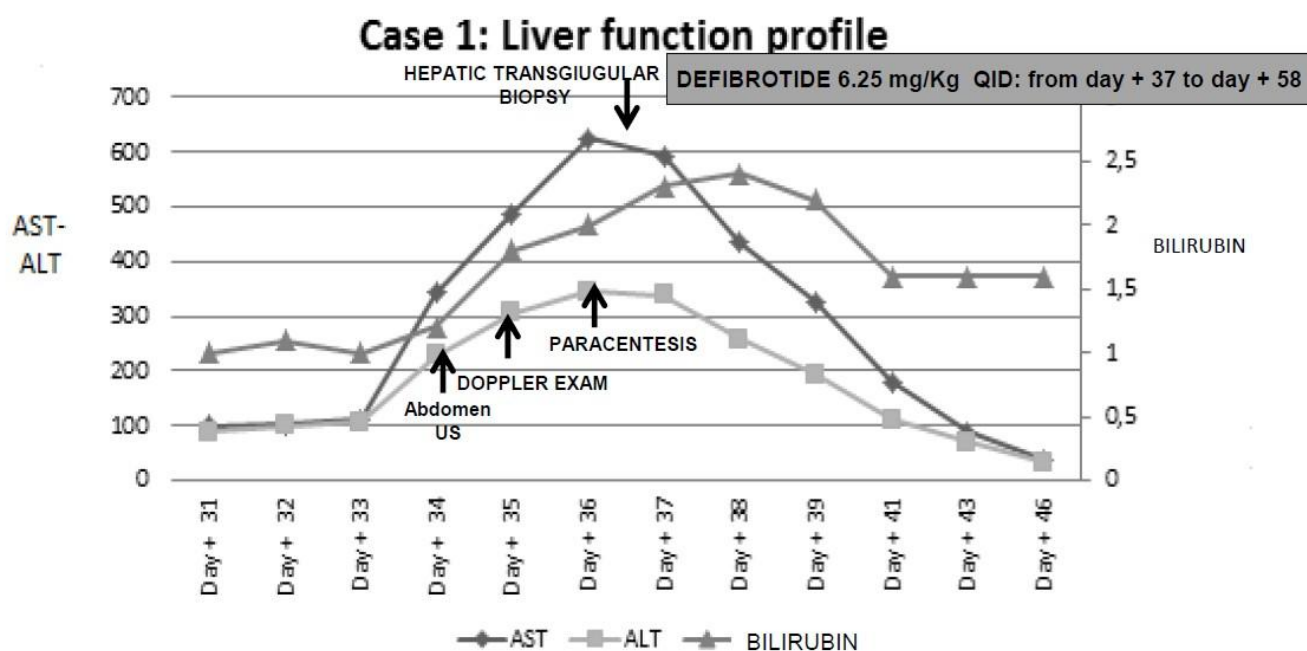


Figure 2. Diagnostic interventions with liver function profile from clinical onset of VOD until resolution, and treatment of VOD in case 1.

remained low between 10.000 to 20.000/mmc even with transfusion support. The patient was discharged on day +76 in complete remission of his underlying disease on low doses of cyclosporine.

Case 2. A 46-year old male was diagnosed with acute myeloid leukemia - normal karyotype, FLT3, and NPM1 wild-type - in May 2015. The patient was treated with idarubicin plus etoposide and cytarabine with no hematologic response. Complete remission was subsequently obtained with a course of high-dose cytarabine, followed consolidation with 2 additional courses of high-dose cytarabine. An unrelated marrow donor search was started and a partially (one-antigen mismatched) HLA-matched donor was identified. The patient received mobilized donor HSCT after a conditioning regimen with Thiotepa (5 mg/kg/day for 2 days), Busulphan (3,2 mg/kg/day for 3 days) and Fludarabine (50 mg/kg/day for 3

days). GvHD prophylaxis included cyclosporine, short course methotrexate, and anti-thymocyte globulin ATG (2,5 mg/kg/day for 3 days). Neutrophil and platelet engraftment occurred on day +14 and +12 respectively. The patient experienced a transient skin rash suggestive of grade I acute GVHD on day +19, and 3 episodes of CMV reactivation on days +27, +43 and +82 successfully treated with preemptive valganciclovir and immunoglobulins.

The patient was readmitted because of severe anemia and thrombocytopenia (Hb 5,8 gr/dl; platelet 5000/ul) and complaints of right abdominal pain with melena on day +89. Significant weight gain (+7 kg) along with abdominal distension and anasarca were observed on day +91. Laboratory exams showed total bilirubin 3,30 mg/dl, AST/ALT 140/164 UI, GGT 725 UI, INR 1,7; aPTT 41,3", serum creatinine 2,0 mg/dl; platelet count was 20.000/mmc. An abdominal CT scan revealed ascites and hepatic

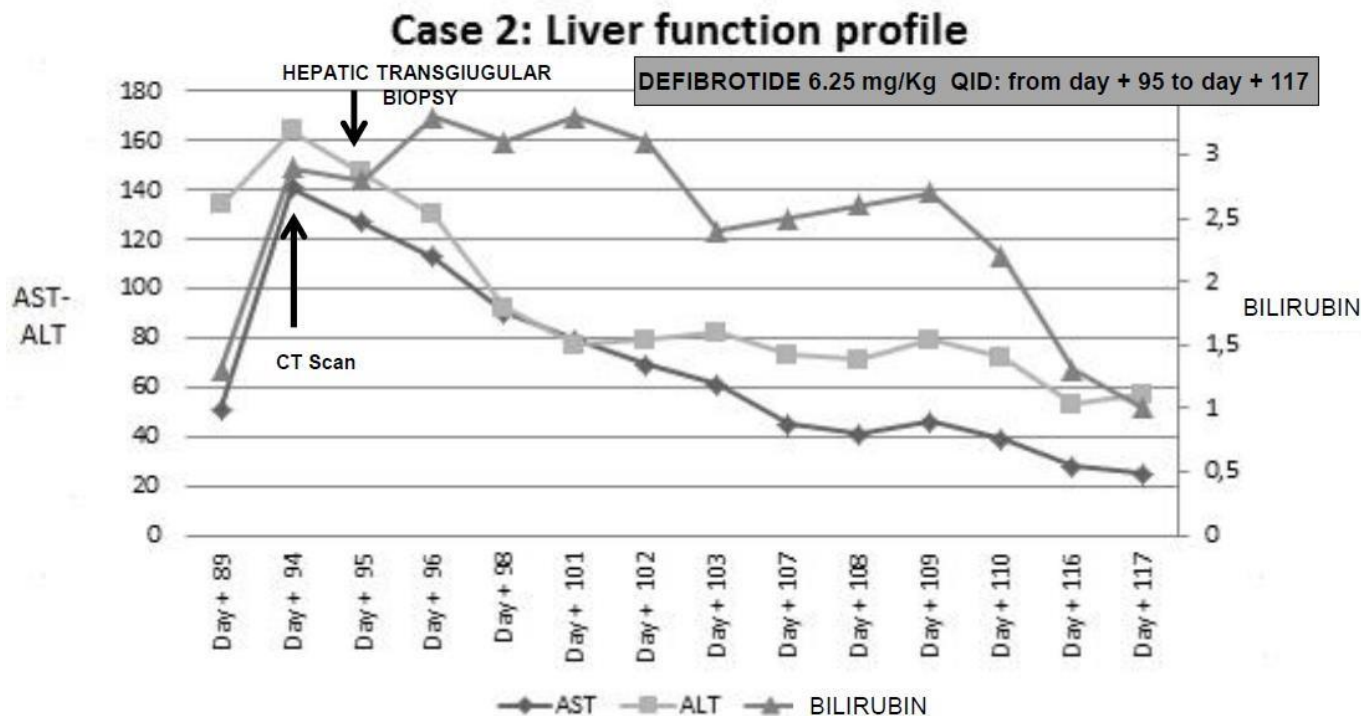


Figure 3. Diagnostic interventions with liver function profile from clinical onset of VOD until resolution, and treatment of VOD in case 2.

veins compression. Transjugular measurement of the hepatic venous pressure gradient showed severe sinusoidal portal hypertension with a significant transhepatic/caval gradient diagnostic for severe VOD. Transjugular liver biopsy showed sinusoidal dilation and bleeding with erythrocytes in the Disse space, and significant iron overload. Histology studies were consistent with severe VOD.

Intravenous defibrotide was promptly started at the dose of 6.25 mg/kg QID for 22 days.

Ancillary therapy included plasma and red blood cells transfusions, no steroid have been administered. A complete and sustained response was achieved. The patient was discharged on day +121. The patient is currently alive, 188 days after transplant, with normal liver function, no evidence of GvHD, or any other relevant clinical complication. A bone marrow aspirate showed complete remission of his underlying disease.

Discussion. Recognition of potential risk factors for VOD is a key point for early diagnosis and prompt therapeutic intervention. Recently, the EBMT group has categorized these risk factors as transplant-, hepatic-, patient- and disease-related.⁷⁻⁹ Interestingly, our patients presented with only a few risk factors, namely, advanced acute leukemia, a myeloablative busulphan-containing conditioning and an unrelated donor. Moreover,

both patients did not show the typical clinical VOD features described by the Seattle²⁻³ and Baltimore⁴ criteria. In particular, the first patient did not experience either painful hepatomegaly or weight gain, and only a mild elevation in total serum bilirubin level was observed after the development of ascites, while the second patient showed only mild hyper-bilirubinemia concurrent with painful hepatomegaly and significant weight gain. Most importantly, both patients developed clinical signs beyond day 21 post-HSCT (on days +33 and +89 respectively). In this respect, it should be emphasized that the EBMT consensus⁶ has now recognized the existence of a “late onset” VOD, defined with less stringent diagnostic criteria and where hyper-bilirubinemia should no longer be mandatory for diagnosis. Overall, in these two patients, the short time between the onset of clinical symptoms and the final diagnosis, and the higher than 5 fold increase in transaminases combine to diagnose a severe form of VOD by the new EBMT criteria (**Table 1**)

Both the British guidelines¹⁰ and the EBMT recommendations indicate that liver biopsy should be reserved for those patients in whom the diagnosis of VOD is unclear, and there is an urgent need to rule out other possible causes of liver dysfunction. In our experience, a transjugular liver biopsy was safe despite severe thrombocytopenia and, most importantly, was

conclusive for the diagnosis of VOD ruling out drug toxicities, viral infections, sepsis or GVHD.¹¹⁻¹³ In keeping with our findings, Kis et al. reported only 1.8% of major complications during 166 transjugular liver biopsies.¹⁴

Defibrotide is the only agent approved for the treatment of VOD in Europe. Defibrotide has been shown to have antithrombotic and anti-inflammatory properties and may promote revascularization inducing endothelial cell proliferation and angiogenesis.¹⁵ In our patients, the combination of clinical features and histology studies prompted us to start defibrotide only a few days after the onset of symptoms. Our experience strengthens the observation reported by Richardson et al.,¹⁶ that the timely administration of defibrotide may represent a crucial issue for the successful outcome of patients with VOD. Sixty % of patients were alive when defibrotide was started within 2 days from the onset of symptoms as compared with 14% when treatment was delayed and started after 7 days. Similar results were reported by Corbacioglu et al.¹⁷ Our patients began defibrotide treatment within 7 days from the onset of symptoms but within 1 day from the

histological diagnosis. They did not fall exactly in the early treatment category. Nevertheless, defibrotide has been initiated within 7 days, representing the crucial threshold to achieve a good outcome. Phase 2 and 3 studies¹⁸⁻²² demonstrated that defibrotide was generally well tolerated with manageable toxicity. Hemorrhagic complications were reported as the most frequent adverse event. Hemorrhagic cystitis, which occurred in one of our patients, is a common complication in HSCT recipients. Though other causes may have been involved, we could not rule out that it may have been related to defibrotide treatment given its prompt resolution upon drug discontinuation.²²

Conclusions. VOD should be considered in the differential diagnosis of HSCT recipients who present with unexplained liver injuries, ascites and/or MOF. Liver biopsy may represent a useful diagnostic tool when the clinical criteria for VOD are not entirely fulfilled. Early therapeutic intervention with defibrotide may improve the clinical outcomes of these patients.

References:

1. Carreras E, et al. Venous-occlusive disease of the liver after hemopoietic cell transplantation. *Eur J Haematol* 2000;64: 281-291. <https://doi.org/10.1034/j.1600-0609.2000.9r200.x> PMID:10863974
2. McDonald, G.B., Hinds, M.S., Fisher, L.D., et al. Venous-occlusive disease of the liver and multiorgan failure after bone marrow transplantation: a cohort study of 355 patients. *Annals of Internal Medicine* 1993; 118, 255-267. <https://doi.org/10.7326/0003-4819-118-4-199302150-00003> PMID:8420443
3. Jones, R.J., Lee, K.S., Beschoner, W.E., et al. Venous-occlusive disease of the liver following bone marrow transplantation. *Transplantation*, 1987;44, 778-783. <https://doi.org/10.1097/00007890-198712000-00011> PMID:3321587
4. Lee, J.L., Gooley, T., Bensinger, W., et al. Venous-occlusive disease of the liver after busulfan, melphalan, and thiotepa conditioning therapy: incidence, risk factors, and outcome. *Biology of Blood and Marrow Transplantation*, 1999;5, 306-315. [https://doi.org/10.1016/S1083-8791\(99\)70006-6](https://doi.org/10.1016/S1083-8791(99)70006-6)
5. Coppel JA, Richardson PG, Soiffer R, Martin PL, Kernan NA, Chen A et al. Hepatic venous-occlusive disease following stem cell transplantation: incidence, clinical course, and outcome. *Biol Blood Marrow Transplant* 2010;16: 157-168. <https://doi.org/10.1016/j.bbmt.2009.08.024> PMID:19766729 PMID:PMC3018714
6. Mohty M, Malard F, Abecassis M, et al. Revised diagnosis and severity criteria for sinusoidal obstruction syndrome/venous-occlusive disease in adult patients: a new classification from the European Society for Blood and Marrow Transplantation. *BMT* 2016, 1-7.
7. Bearman SI, et al. The syndrome of hepatic venous-occlusive disease after marrow transplantation. *Blood* 1995; 85:3005-20. PMID:7756636
8. Carreras E, Bertz H, Arcese W, et al. Incidence and outcome of hepatic venous-occlusive disease after blood or marrow transplantation: A prospective cohort study of the European Group for Blood and Marrow Transplantation: European Group for Blood and Marrow Transplantation Chronic Leukemia Working Party. *Blood* 1998;92:3599-604. PMID:9808553
9. Cesaro, S., Pillon, M., Talenti, E., et al. A prospective survey on incidence, risk factors and therapy of hepatic venous-occlusive disease in children after hematopoietic stem cell transplantation. *Haematologica*, 2005;90, 1396-1404. PMID:16219577
10. Dignan FL, Wynn RF, Hadzic N, et al. BCSH/BSBMT guideline: diagnosis and management of venous-occlusive disease (sinusoidal obstruction syndrome) following hematopoietic stem cell transplantation. *BJH* 2013, 163, 444-457. <https://doi.org/10.1111/bjh.12558> PMID:24102514
11. DeLeve, L.D., Shulman, H.M. & McDonald, G.B. (2002) Toxic injury to hepatic sinusoids: sinusoidal obstruction syndrome (venous-occlusive disease). *Seminars in Liver Disease*, 22, 27. <https://doi.org/10.1055/s-2002-23204> PMID:11928077
12. Shulman, H.M., Gown, A.M. & Nugent, D.J. (1987) Hepatic venous-occlusive disease after bone marrow transplantation. Immunohistochemical identification of the material within occluded central venules. *The American Journal of Pathology*, 127, 549-558 PMID:2438942 PMID:PMC1899766
13. Shulman, H.M., Fisher, L.B., Schoch, H.G., Henne, K.W. & McDonald, G.B. (1994) Venous-occlusive disease of the liver after marrow transplantation: histological correlates of clinical signs and symptoms. *Hepatology*, 19, 1171-1181. <https://doi.org/10.1002/hep.1840190515> PMID:8175139
14. Kis b, Pamarthi V, Fan C-M et al. Safety and Utility of Transjugular Liver Biopsy in Hematopoietic Stem Cell Transplant Recipients. *J Vasc Interv Radiol* 2013; 24:85-89. <https://doi.org/10.1016/j.jvir.2012.09.011> PMID:23200125
15. Richardson, P.G., Elias, A.D., Krishnan, A., et al. Treatment of severe venous-occlusive disease with defibrotide: compassionate use results in response without significant toxicity in a high-risk population. *Blood*, 1998;92, 737-744. PMID:9680339
16. Richardson PG, Smith AR, Triplett BM, et al. Early Initiation of Defibrotide in Patients with Hepatic Venous-occlusive Disease/Sinusoidal Obstruction Syndrome Following Hematopoietic Stem Cell Transplantation Improves Day +100 Survival. *ASH* 2015. Poster Abs.
17. Corbacioglu S, Greil J, Peters C., et al. Defibrotide in the treatment of children with venous-occlusive disease (VOD): a retrospective

- multicentre study demonstrates therapeutic efficacy upon early intervention. *BMT* 2004; Jan;33(2):189-95. <https://doi.org/10.1038/sj.bmt.1704329>
18. Bearman, S.I., Anderson, G.L., Mori, M., Hinds, M.S., Shulman, H.M. & McDonald, G.B. (1993) Venoocclusive disease of the liver: development of a model for predicting fatal outcome after marrow transplantation. *Journal of Clinical Oncology*, 11, 1729-1736. <https://doi.org/10.1200/JCO.1993.11.9.1729> PMID:8355040
 19. Chopra R, Eaton JD, Grassi A, Potter M, Shaw B, Salat C, et al. Defibrotide for the treatment of hepatic veno-occlusive disease: Results of the European compassionate-use study. *Br J Haematol* 2000;111:1122-9. <https://doi.org/10.1046/j.1365-2141.2000.02475.x> PMID:11167751
 20. Richardson PG, Murakami C, Jin Z, Warren D, Momtaz P, Hoppensteadt D, et al. Multi-institutional use of defibrotide in 88 patients after stem cell transplantation with severe veno-occlusive disease and multisystem organ failure: response without significant toxicity in a high-risk population and factors predictive of outcome. *Blood* 2002;100:4337-43. <https://doi.org/10.1182/blood-2002-04-1216> PMID:12393437
 21. Richardson PG, Soiffer R, Antin J, Jin Z, Kurtzberg J, Martin P, et al. Defibrotide (DF) for the treatment of severe veno-occlusive disease (sVOD) and multi-organ failure (MOF) post SCT: Final results of a multi-center, randomized, dose-finding trial. *Blood* 2006;108:178.
 22. Richardson PG, Riches ML, Kernan NA, et al. Phase 3 trial of defibrotide for the treatment of severe veno-occlusive disease and multi-organ failure. *Blood*. 2016;127(13):1656-65. <https://doi.org/10.1182/blood-2015-10-676924> PMID:26825712 PMCid:PMC4817309
-