

Letters to the Editor

Real time visualization may be advisable to exclude aspiration in patients undergoing capsule endoscopy examination

Key words: Aspiration. Asymptomatic. Bronchial. Capsule endoscopy. Complication.

DOI: 10.17235/reed.2017.5244/2017

Dear Editor,

Capsule endoscopy (CE) is currently considered as a first line diagnostic tool for small bowel examination.

Some patients find swallowing the capsule difficult. However, capsule aspiration is relatively uncommon and is only reported in isolated cases. The majority of these cases are male (39/41; 95.1%) with an age ranging from 56-93 years (1,2) and only 4 (9.8%) patients had a recorded history of dysphagia. Twenty-four out of 41 (58.5%) patients experienced symptoms of capsule aspiration. The aspiration self-resolved in 11/41 patients and the CE was retrieved during bronchoscopy in the other cases.

We present the case of a 75 year old man with a history of chronic anemia who was referred for CE. He had a positive fecal occult blood test but the upper gastrointestinal endoscopy and colonoscopy were unremarkable. The patient denied a history of swallowing disorders. On ingestion of the device (PillCam® SB2, USA), no respiratory symptoms occurred. The patient was sent home and told to return 12 hours later to retrieve the data-recorder. Analysis of the video revealed that the capsule had stayed in his trachea for 7 hours (Fig. 1).

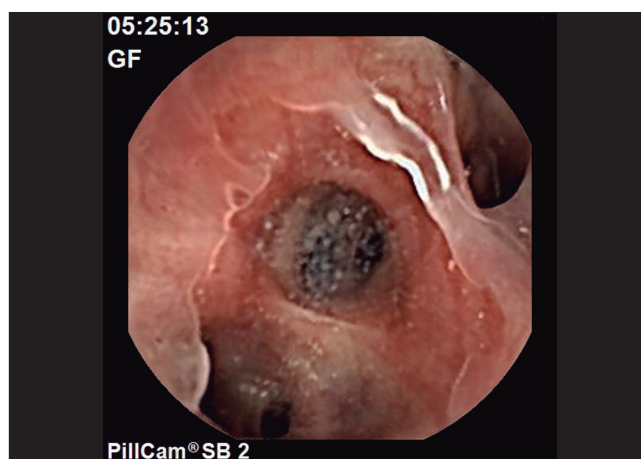


Fig. 1. Image of the middle lobe bronchus and lower right lobe bronchus transmitted by the endoscopic capsule.

Seven hours after ingestion, the first image of the esophagus appeared. The patient reported that when bending forward he had found the capsule in his mouth and he had swallowed it again without any problem.

The bronchial aspiration was not noticed until the video was seen the next day and there was no real-time video recorder available at the time of the examination. This is currently available in the majority of the medical centers as aspiration may be asymptomatic and the passage of the CE into the stomach should be confirmed before the patient leaves the clinic. Unfortunately this is not possible when administering the patency capsule.

Davide Giuseppe Ribaldone¹, Mauro Bruno¹,
Paolo Solidoro² and Claudio De Angelis¹

¹Gastroenterology - U. General and Specialist Medicine Department, Città della Salute e della Scienza of Turin, Turin, Italy. ²Division of Pulmonology, Cardiothoracic and Vascular Department, AOU Città della Salute e della Scienza di Torino, Turin, Italy

References

1. Juanmartiñena Fernández JF, Fernández-Urien I, Vila Costas JJ. Asymptomatic bronchial aspiration of capsule endoscope: a significant complication. *Rev Esp Enferm Dig* 2016;108:605. DOI: 10.17235/reed.2016.4363/2016
2. Fernández-Urien I, Carretero C, González B, et al. Incidence, clinical outcomes and therapeutic approaches of capsule endoscopy-related adverse events in a large study population. *Rev Esp Enferm Dig* 2015;107:745-52. DOI: 10.17235/reed.2015.3820/2015