

Atrial fibrillation ablation in a patient with a peculiar common postero-inferior pulmonary vein trunk

Massimo Magnano*, Federico Ferraris, Arianna Bissolino, and Matteo Anselmino

Division of Cardiology, Department of Medical Sciences, 'Città della Salute e della Scienza di Torino' Hospital, University of Turin, Corso Bramante 88, 10126 Turin, Italy

Received 26 November 2018; accepted 3 December 2018

A 76-year-old woman was referred for symptomatic drug resistant atrial fibrillation catheter ablation. Before the procedure, contrast-enhanced, ECG-synchronized, computed tomography angiography (CTA; Lightspeed VCT 64, General Electric, USA) was performed showing an atypical pulmonary vein (PV) anatomy^{1,2}: the two superior (right and left) PVs had normal separate ostia, while the two inferior PVs had a common postero-inferior trunk (Figure 1A,B); supernumerary PVs were absent. The oesophagus was located close to the posterior portion of this unusual common postero-inferior trunk (Figure 1C). Transoesophageal echocardiogram was performed the day before the procedure to exclude the presence of left atrial/appendage thrombi.

A 3D reconstruction of the left atrium (LA) was performed through a circular mapping catheter (Lasso[®], Biosense Webster, USA) and an irrigated ablation catheter (ThermoCool SmartTouch[®] SF, Biosense Webster, USA) using the Carto[®]3 electroanatomic mapping system (Biosense Webster, USA) and then merged with the CTA acquisition. In the absence of pre-acquired atrial imaging, as in more than half of the Electrophysiology labs in Europe,³ it would surely have been highly challenging to correctly recognize this atypical anatomy and to perform a safe and efficacious ablation procedure. In addition, given the wide diameter (27 × 35 mm), this atypical trunk would have likely caused a puzzling procedure if approached by cryoballoon (maximum balloon diameter 28 mm).

Superior PVs isolation was performed by point-by-point radiofrequency (RF) ablation in power control mode (Smartablate RF generator, Stockert, Germany) at 40 W (irrigation flow 15 mL/min), ablation index (AI) value of 500 in the anterior wall and 35 W, AI of 380–400 in the posterior wall.

Considering the peculiar anatomy and proximity to the oesophagus, electrical isolation of the common postero-inferior trunk was

obtained by RF application on the ridge of the posterior LA wall (Figure 1D–F) using reduced energy (15–20 W, irrigation flow 8 mL/min) and AI of 380.

The endpoint was complete PV isolation, confirmed by the absence of PV potentials on the Lasso[®] catheter after RF delivery.

Following the procedure, the patient was stable and, therefore discharged asymptomatic in second post-operative day. At 120-day follow-up, she remained asymptomatic and no arrhythmic relapses have been reported.

Consent: The authors confirm that written consent for submission and publication of this case report including image(s) and associated text has been obtained from the patient in line with COPE guidance.

Conflict of interest: none declared.

References

1. Anselmino M, Blandino A, Beninati S, Rovera C, Boffano C, Belletti M, Caponi D, Scaglione M, Cesarani F, Gaita F. Morphologic analysis of left atrial anatomy by magnetic resonance angiography in patients with atrial fibrillation: a large single center experience. *J Cardiovasc Electrophysiol* 2011;**22**:1–7.
2. Calkins H, Kuck KH, Cappato R, Brugada J, Camm AJ, Chen S-A, Crijns HJG, Damiano RJ, Davies DW, DiMarco J, Edgerton J, Ellenbogen K, Ezekowitz MD, Haines DE, Haissaguerre M, Hindricks G, Iesaka Y, Jackman W, Jalife J, Jais P, Kalman J, Keane D, Kim Y-H, Kirchhof P, Klein G, Kottkamp H, Kumagai K, Lindsay BD, Mansour M, Marchlinski FE, McCarthy PM, Mont JL, Morady F, Nademanee K, Nakagawa H, Natale A, Nattel S, Packer DL, Pappone C, Prystowsky E, Raviele A, Reddy V, Ruskin JN, Shemin RJ, Tsao H-M, Wilber D. 2012 HRS/EHRA/ECAS expert consensus statement on catheter and surgical ablation of atrial fibrillation: recommendations for patient selection, procedural techniques, patient management and follow-up, definitions, endpoints, and research trial design. *Heart Rhythm* 2012;**9**:632–696.
3. Pison L, Proclemer A, Bongioni MG, Marinakis G, Hernandez-Madrid A, Blomstrom-Lundqvist C. Imaging techniques in electrophysiology and implantable device procedures: results of the European Heart Rhythm Association survey. *Europace* 2013;**15**:1333–1336.

* Corresponding author. Tel: +39-0116335570, Fax: +39-0116335572, Email: massimomagnano88@gmail.com

Handling Editor: Borislav Dinov

Peer-reviewers: Philipp Sommer and Robert Schonbauer

© The Author(s) 2019. Published by Oxford University Press on behalf of the European Society of Cardiology.

This is an Open Access article distributed under the terms of the Creative Commons Attribution Non-Commercial License (<http://creativecommons.org/licenses/by-nc/4.0/>), which permits non-commercial re-use, distribution, and reproduction in any medium, provided the original work is properly cited. For commercial re-use, please contact journals.permissions@oup.com

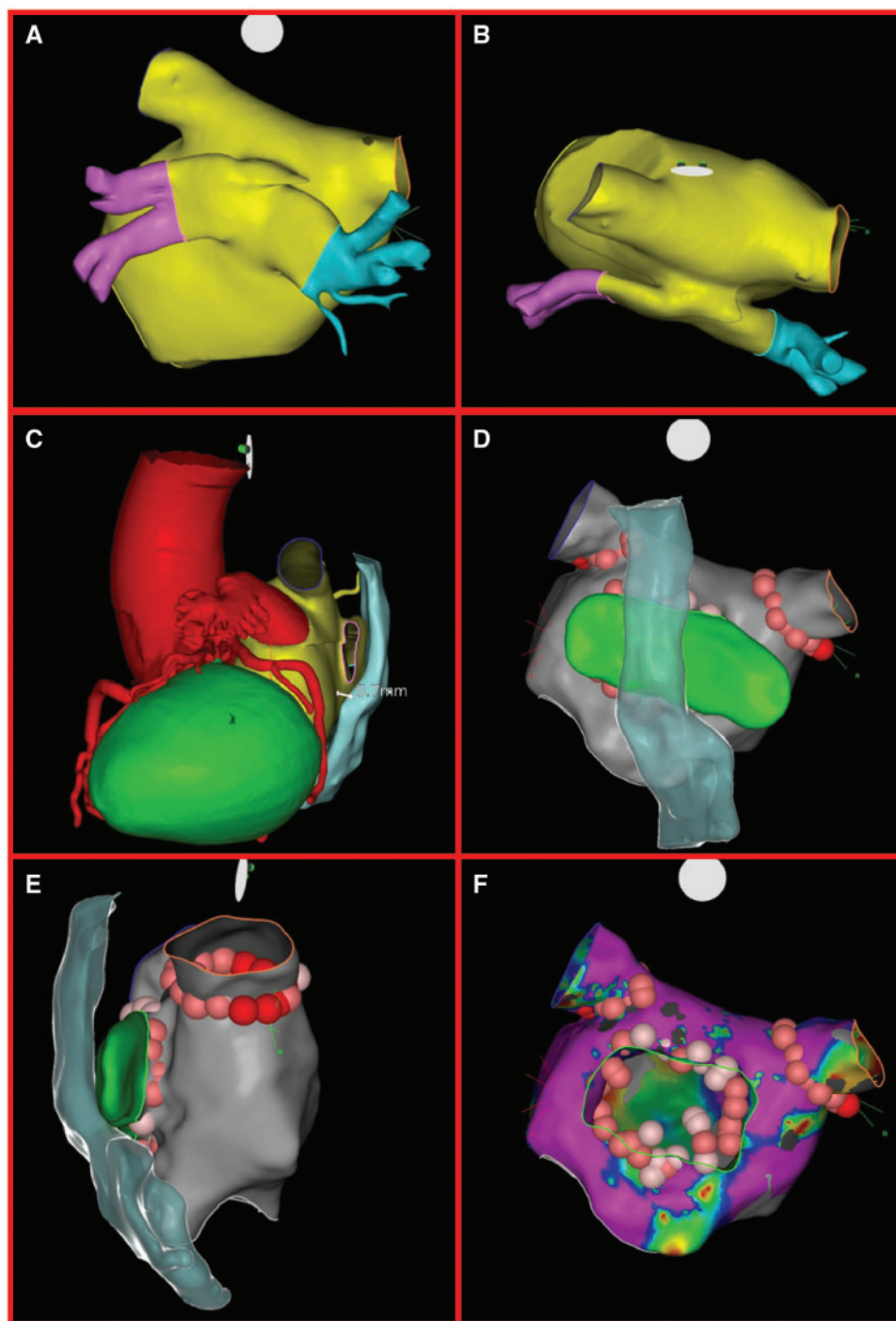


Figure 1 Postero-anterior (A) and cranial (B) computed tomography angiography reconstruction of the left atrium reconstruction highlighting the confluence of the inferior pulmonary veins in a common trunk, behind the left atrium's posterior wall. (C) Left lateral computed tomography angiography imaging cardiac reconstruction displaying the position of critical contiguous structures; particularly highlighting the distance between the oesophagus and the origin of the common posterior trunk at the posterior left atrium wall (5.7 mm). Postero-anterior (D) and right-lateral (E) left atrium fast anatomical mapping at Carto[®] 3 system (Biosense Webster Inc., USA) merged to computed tomography angiography reconstruction to demonstrate the position of the oesophagus; red and pink tags are the locations of the radiofrequency delivery. (F) A detail of ablation points in relation to the common posterior trunk ostium in the postero-anterior projection.