

Restoring Congenitally Missing Mandibular Central Incisor Using Lithium Disilicate Based Resin Bonded Prostheses: A Case Report

Elifnur Guzelce^{1*}, Francesco Bassi² and Ozgul Karacer³

¹DDS, Research Assistant, Gazi University Faculty of Dentistry Department of Prosthodontics, Emek, Ankara, Turkey.

²MD, DDS, Ph.D., Professor. University of Turin Faculty of Dentistry Department of Surgical Sciences, Dental School, Lingotto, Torino, Italy.

³DDS, Ph.D., Professor, Gazi University Faculty of Dentistry Department of Prosthodontics, Emek, Ankara, Turkey.

*Correspondence:

Elifnur Guzelce, DDS Research Assistant Department of Prosthodontics, Faculty of Dentistry, Gazi University Emek, Ankara, Turkey, Tel: +90 312 203 41 93, E-mail: eguzelce@hotmail.com.

Received: 24 April 2018; Accepted: 21 May 2018

Citation: Elifnur Guzelce, Francesco Bassi, Ozgul Karacer. Restoring Congenitally Missing Mandibular Central Incisor Using Lithium Disilicate Based Resin Bonded Prostheses: A Case Report. Oral Health Dental Sci. 2018; 2(2); 1-3.

ABSTRACT

This case report explains an alternative treatment procedure for congenitally missing mandibular right central incisor of a 17 years old female patient. Fabrication of all-ceramic resin bonded fixed partial dentures (RBFDPs) followed specific preparation design and features to accommodate two retainers. The Maryland Bridge was designed by using a copy milling system to protect the patient's aesthetic and dental integrity. The whole design was made with E-max press. Finishing of the treatment resulted in an esthetic and functional successful outcome with 1-year follow-up. RBFDP represents a minimally invasive, better aesthetics and durable treatment modality in young patients with single missing teeth when implant therapy is not the treatment choice.

Keywords

Dental Ceramics, Resin Bonded Prostheses, Esthetic.

Introduction

Congenitally missing teeth are a restorative problem in clinical dentistry in respect of treatment planning and rehabilitation. Some of the challenges associated with the anterior mandible and surrounding anatomy requires potentially aesthetic problems. Proper diagnosis and treatment planning are needed for a multidisciplinary approach in order to meet the demands of a missing tooth. Current treatment modalities with different therapeutic approaches for missing mandibular incisors involve resin-bonded fixed dental prosthesis (RBFDP), orthodontic treatment, full- veneer fixed dental prosthesis (FDP), dental implant for a single tooth replacement, extraction of one or more incisors and restoration with an implant supported FDP, extraction of one or more teeth and restoration with an FDP from # 22 to 27, extraction of one or more teeth and restoration with a removable dental prosthesis (RDP) [1].

As reported in many studies, implant restorations are one of the predictable treatments for single tooth failure cases and give

successful results [2]. Implant restorative treatments are considered the most conservative treatment approach since no modification of the adjacent teeth is needed [3]. The long-term success of dental implant therapy and functional outcome depends on many factors. The primary concern is restorative space, aesthetic outcome, and long-term restoration of function and true implant success is only manifested in restorations that are functional, aesthetic, and stable over time [1]. Implant therapy can present several contraindications when age of the patient is not appropriate, when restorative space on the arch is not enough or when the patient rejects implant therapy [4].

When implant treatment is not indicated, today, metal-ceramic and all ceramic resin bonded fixed partial (RBFDPs) with two-retainers design have been proposed as a conservative treatment approach for the replacement of missing teeth. This technique of bonded bridges was first presented by Brochette in 1963 [5].

Since then, there have been significant changes to RBFDPs regarding materials, design, tooth preparation [3]. For eliminating the problems related to metal frameworks, all-ceramic RBF PDs were introduced in the 90s. In Ceram Alumina (VITA Zahnfabrik,

Bad Sackingen, Germany), was used in the initial practices of all ceramic RBFDPs. And also lots of different ceramic materials including reinforced with leucite (IPS Empress), lithium disilicate (IPS Empress 2, IPS e.max) and zirconium oxide have been used in producing of RBFDPs [6].

In 1998, lithium disilicate (IPS Empress 2, Ivoclar Vivadent) was presented as a dental restorative material. Today, it has been updated and improved, and also called as the IPS e.max Press system [7]. Principally, this system includes two phases, phase I has homogeneously distributing lithium disilicate crystals ($\text{Li}_2\text{O}\cdot\text{SiO}_2$) and lithium orthophosphate, in a glass matrix creates phase II [8] Existence of these crystals in the structure at high proportion increase the mechanical properties of the material [9]. Thought the content of the system was composed by lithium disilicate like the Impress II system, the physical properties and aesthetics of the system were increased thanks to the different firing technique used [10].

Thin veneers, inlay and onlay restorations, conventional and implant supported crowns and bridges with three units are suggested to perform by manufacturer. Lithium disilicate-reinforced glass ceramics are widely used clinically due to their esthetic properties. However, their use in the posterior region is limited, because of inadequate mechanical properties [10]. So that, zirconia reinforced CAD system is offered to restore posterior region. In the present case reports lithium disilicate, is used to produce an all ceramic RBFDP considering superior mechanical and optical properties.

Case Report

Treatment planning

A 17-year-old female presented to the Faculty of Dentistry Gazi University Ankara, displeased with her smile. She had congenitally missing mandibular right central incisor (Figure 1). After clinical examination, radiographs, photographs, study casts were performed. Periodontal conditions, presence of caries, occlusal interferences, smile, esthetics, and facial symmetry were appreciated. After the evaluation, the RBFDP was designed with a copy milling system to maintain the patient's aesthetic and dental unity. The whole design was made with IPS E-max press.

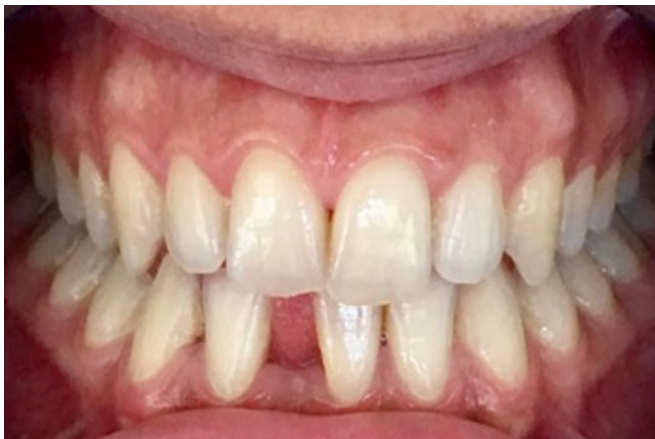

Figure 1: Preliminary intraoral image of the case. (Patient had congenitally missing mandibular right central incisor).

Teeth Preparations

The diagnostic cast was waxed to model cast to assess the size and morphology of mandibular incisors. The preparation edges were drawn on the model cast and then reported on teeth limited only at enamel boundaries (Figure 2). The mandibular right lateral incisor and left central incisor teeth were prepared. 1mm supragingival reduction extending to the centre of the interproximal contact, with an incisal finish line 2mm short of the incisal edge and 0,5-mm lingual reduction of the enamel.

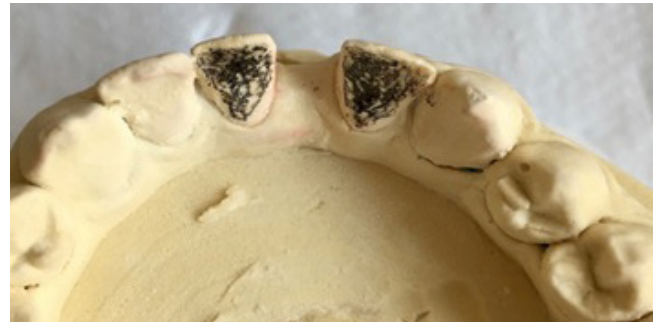

Figure 2: The preparation edges were drawn on the model cast.

Fabrication and cementation of restorations

Lithium disilicate-based ceramic was used to provide ideal aesthetics. The RBFDP was produced with IPS e.max Press (Figure 3). The retainers of the bridge were then etched with hydrofluoric acid and concentration 9.5% and silane was applied. The teeth, under dam, were etched with 37% orthophosphoric acid and rinsed with distilled water and dried with air and then the bridge was cemented with a dual-cure resin cement, Panavia F 2.0 (Kuraray). Finishing of the treatment resulted in an aesthetic and functional successful outcome. The patient was followed-up clinically for one year (Figure 4).

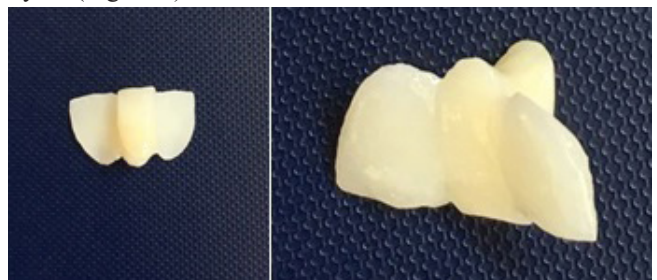


Figure 3: RBFDP was produced with IPS e.max Press.

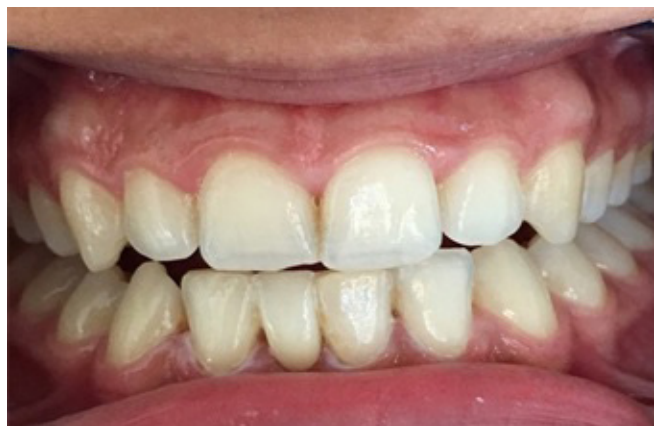

Figure 4: Intraoral image of the case after one year.

Discussion

The survival rate of RBFDPs is still considerably less than that of conventional fixed partial dentures. The principle reason for failure is possible debonding of the framework from the abutment teeth. In Audenino et al. study, where cementation was performed under dam or with the simple use of cotton rolls, the estimated survival probability for the first debonding or failure, considering all the 100 cases, was 85% after 5 years. The use of dental dam during cementation reduced the risk of debonding by ten times [11].

In a study published in 2011, the success rate of single-retainer all-ceramic RBFDPs made from glass-infiltrated alumina ceramic, observed for 10 years, success rate was found 94.4% [12].

In Sailer et al. study, 35 RBFDPs with substructures fabricated from IPS Empress or IPS e.max Press and veneered with IPS e.max Ceram were performed on 28 patients and reported a survival rate of 100% at 6 years and only 5,7% of ceramic chipping occurred [13]. Also the same, Sun et al. reported 100% survival rate approximately 4-year clinical follow-up of 35 anterior RBFDPs fabricated from IPS e.max Press [14].

Sasse et al., performed a randomized clinical trial on thirty anterior zirconia ceramic (IPS e.max ZirCAD veneered with IPS e.max Ceram) RBFDPs were in the follow-up period (mean: 41,7 months; min. 9,4, max. 55,9) two debondings happened. 100% survival rate was reported after three years observation [15].

Conclusion

RBFDP represents a minimally invasive, better aesthetic and durable treatment modality in young patients with single missing teeth when implant therapy is not a treatment choice. By selecting the most suitable material, all-ceramic RBFDPs can provide aesthetic and minimally invasive restorations and when following a suitable clinical procedure, the survival rate of the RBFDPs is comparable to conventional FDPs.

References

1. Fleigel JD, Salmon CA, Piper JM. Treatment Options for the Replacement of Missing Mandibular Incisors. *J Prosthodont.* 2011; 414-420.
2. Mayer TM, Hawley CE, Gunsolley JC, et al. The single-tooth

implant: a viable alternative for single-tooth replacement. *J Periodontol.* 2002; 73: 687-693.

3. Stylianou A, Liu P, O'Neal SJ, et al. Restoring Congenitally Missing Maxillary Lateral Incisors Using Zirconia-Based Resin Bonded Prostheses. *J Esthet Restor Dent.* 2016; 28: 8-17.
4. Sasse M, Kern M. All-ceramic resin-bonded fixed dental prostheses: Treatment planning, clinical procedures and outcome. *Quintessence Int.* 2014; 45: 291-297.
5. Kalghoum I, Azzouzi I, Khiari A, et al. All Ceramic Bonded Bridge: Clinical Procedure and Requirements. *Adv Dent & Oral Health.* 2017; 6: 1-5.
6. Turkcan I, Nemli S, Güngör M, et al. Chairside All-Ceramic Resin Bonded Fixed Partial Denture: Case Report and Review of the Literature. *Türkiye Klinikleri J Dental Sci Cases.* 2015; 1: 41-49.
7. Denry I, Holloway JA. Ceramics for Dental Applications: A Review. *Materials (Basel).* 2010; 3: 351-368.
8. Oh S, Dong J, Lüthy H. Strength and microstructure of IPS Empress 2 glass-ceramic after different treatments. *Int J.* 2000; 13: 468-472.
9. Albakry M, Guazzato M, Vincent Swain M. Biaxial Flexural Strength and Microstructure Changes of Two Recycled Pressable Glass Ceramics. *J Prosthodont.* 2004; 13: 141-149.
10. Vivadent AI. The Compatible All-Ceramic System. Technician and Instructor. Schaan. Liechtenstein. 2005.
11. Audenino G, Giannella G, Morello GM, et al. Resin-bonded fixed partial dentures: ten-year follow-up. *Int J Prosthodont.* 2006; 19: 22-23.
12. Kern M, Sasse M. Ten-year survival of anterior all-ceramic resin-bonded fixed dental prostheses. *J Adhes Dent.* 2011; 13: 407-410.
13. Sailer I, Bonani T, Brodbeck U, et al. Retrospective clinical study of single-retainer cantilever anterior and posterior glass-ceramic resin-bonded fixed dental prostheses at a mean follow-up of 6 years. *Int J Prosthodont.* 2013; 26: 443-450.
14. Sun Q, Chen L, Tian L, et al. Single-tooth replacement in the anterior arch by means of a cantilevered IPS e.max Press veneer-retained fixed partial denture: case series of 35 patients. *Int J Prosthodont.* 2013; 26: 181-187.
15. Sasse M, Eschbach S, Kern M. Randomized clinical trial on single retainer all-ceramic resin-bonded fixed partial dentures: Influence of the bonding system after up to 55 months. *J Dent.* 2012; 40: 783-786.