IRIS AperTO

UNIVERSITÀ DEGLI STUDI DI TORINO

AperTO - Archivio Istituzionale Open Access dell'Università di Torino

Prevalence and prognosis of lead masses in patients with cardiac implantable electronic devices without infection

This is the author's manuscript

Original Citation:

Availability:

This version is available http://hdl.handle.net/2318/1701637 since 2020-01-22T17:57:58Z

Published version:

DOI:10.2459/JCM.0000000000000797

Terms of use:

Open Access

Anyone can freely access the full text of works made available as "Open Access". Works made available under a Creative Commons license can be used according to the terms and conditions of said license. Use of all other works requires consent of the right holder (author or publisher) if not exempted from copyright protection by the applicable law.

(Article begins on next page)

12 October 2024

PREVALENCE AND PROGNOSIS OF LEAD MASSES IN PATIENTS WITH CARDIAC IMPLANTABLE ELECTRONIC DEVICES WITHOUT INFECTION

Short title: Lead masses without infection

Pier Giorgio Golzio[1] MD, FESC, FACC, FEHRA, FAIAC; Daniele Errigo[1] MD; Mattia Peyracchia[1] MD; Elisa Gallo[1] MD; Simone Frea[1] MD; Davide Castagno[1] MD, PhD; Carlo Budano[1] MD; Carla Giustetto[1] MD, Prof; and Mauro Rinaldi[1] MD, Prof.

[1]Division of Cardiology, Department of Internal Medicine, AOU Città della Salute e della Scienza, University of Turin, Italy.

All authors take responsibility for all aspects of the reliability and freedom from bias of the data presented and their discussed interpretation

Corresponding author: Pier Giorgio Golzio, MD, FESC, FACC, FEHRA, FAIAC

Division of Cardiology, Department of Internal Medicine, University of Turin

Azienda Ospedaliero-Universitaria Città della Salute e della Scienza di Torino – "Molinette"

Corso A. M. Dogliotti, 14 - 10126 Torino (Italy)

Phone: + 390116636165, +393332274241; Fax : +390116967053

e-mail: pg.golzio@gmail.com

All the authors have no grant support to disclose.

All the authors have no conflict of interest nor funding to disclose.

Author contributions:

- Pier Giorgio Golzio MD. He conceived, designed the study, acquired, analysed and interpreted data, drafted the manuscript and finally approved it.
- Daniele Errigo, MD. He acquired, analysed and interpreted data, contributed to drafting the paper, critically revised the manuscript and finally approved it.
- Mattia Peyracchia, MD. He acquired, analysed and interpreted data, contributed to drafting the paper, critically revised the manuscript and finally approved it.
- Elisa Gallo, MD. She participated in conceiving the study, mainly performed acquisition, analysis and interpretation of data, critically revised the manuscript and finally approved it.
- Simone Frea, MD. He performed interpretation of data, critically revised the manuscript and finally approved it.
- Davide Castagno, MD, PhD. He performed interpretation of data, critically revised the manuscript and finally approved it.
- Carlo Budano, MD. He critically revised the manuscript and finally approved it.
- Carla Giustetto, MD, Prof. She critically revised the manuscript and finally approved it.
- Mauro Rinaldi, MD, Prof. He's the mentorship and the head of the Department of Cardiovascular and Thoracic Diseases of our Institution. He critically revised the manuscript and finally approved it, attesting the integrity, completeness and accuracy of the reported data.

ABSTRACT

Background: Finding of intracardiac lead masses in patients with cardiac implantable electronic device remains controversial, since such masses have been observed in cases of exclusively local infections whereas they have not been recognized in patients with positive cultures of intravascular lead fragments. In this study we aim to describe the prevalence of intracardiac lead masses in true asymptomatic patients with cardiac implantable electronic devices, to identify their predictive factors and to define their prognostic impact at long-term follow-up.

Methods: 78 consecutive patients admitted over a six-month period for elective generator replacement without clinical evidence of infection were evaluated by transthoracic and transesophageal echocardiography and prospectively followed at in-clinic follow-up visits.

Results: Leads masses were found in 10 patients (12.8%). These patients had more frequently right ventricular dysfunction at univariate analysis (OR 2.71, P=0.010) and after baseline variables adjustment (HR 6.25, P=0.012). At 5-year follow-up without any specific therapy none of the patients suffered from any cardiac device infections, nor developed clinical signs of infections.

Conclusions: There is an evidence of clinical leads masses in asymptomatic patients with cardiac implantable electronic device. The value of these findings is still debated, as for aetiological interpretation and for therapeutic strategy, but they are not necessarily associated to an infection.

ABBREVIATIONS: IE: infective endocarditis; CIED: cardiac implantable electronic device; CDRIE: cardiac device-related infective endocarditis; LRIE: lead-related infective endocarditis; CDI: cardiac device infections; LM: leads masses; TEE: transesophageal echocardiography; TTE: transthoracic echocardiography; TLE: transvenous lead extraction.

Keywords: pacemaker; defibrillator; lead extraction; infection; lead masses, lead vegetations; transesophageal echocardiography.

TEXT

INTRODUCTION

A clear diagnosis of cardiac device-related infective endocarditis (CDRIE) is crucial to drive the indication to a therapy always expensive and requiring transvenous lead extraction (TLE) with associated mortality and risks. (1) Finding of intracardiac lead masses (LM) in patient with suspected endocarditis is a major criterion of the Duke diagnosis score, (2) but its value in patients with cardiac implantable electronic device (CIED) has been debated, since vegetations have been observed in cases of local infections, (3) whereas they have not been recognized in patients with positive cultures of intravascular lead fragments. (4)

In CDRIE local signs at the device pocket are often prevailing, (4) while systemic involvement may be absent. Laboratory data may be inconclusive, blood samples are frequently negative, and fever is the main presentation clue. (5) Transesophageal echocardiography (TEE), indeed, is important to increase sensitivity and specificity of the diagnosis of CDRIE. (6) Data are lacking about the prevalence of LM in true asymptomatic patients with CIED, and, at the same time, when LM are observed, they cannot unequivocally be associated with an infection. (7)

Aim of this study is to describe the prevalence of LM in a group of true asymptomatic patients with CIED, to identify their predictive factors and to evaluate the prognostic impact of LM at long-term follow-up.

METHODS

78 consecutive patients admitted to our centre for elective generator replacement and without clinical evidence of cardiac device infection (CDI) were enrolled over a six-month period between June and December 2013. Patients were followed at in-clinic follow-up visits.

The visits were scheduled at a 3 months interval during the first year after the detection of masses and yearly afterwards until June 2018 (5-year follow-up).

Exclusion criteria were signs or symptoms of suspected infection of the CIED pocket, previous pocket revisions other than elective replacement, fever or antibiotic therapy, anti-inflammatory or corticosteroid drugs administration in the last three months, clinical and hemodynamic instability. We also excluded patients with a poor clinical status or comorbidities likely to influence medium-term prognosis, such as oncological diseases with less than one-year expected survival, neoplastic cachexia, advanced chronic kidney disease (defined as creatinine clearance < 30 ml/m' or need for dialysis), advanced neurological disorders (defined as disabling cognitive impairment or motor impairment), on-going severe organ or systemic infections, and advanced severe heart failure (Ambulatory IV NYHA Class, need for any hemodynamic support, bridging for heart transplantation). The inclusion and exclusion criteria are summarized in Table 1.

Clinical features

Demographic and clinical variables as well as CIED data were collected at enrolment, see Table 2.

Echocardiographic imaging and second level examinations

All patients were evaluated by transthoracic echocardiography (TTE) and TEE during the same day of the procedure. Echocardiographic imaging was performed using a commercially available Philips i33 echocardiograph (Philips Medical Systems, Andover, Massachusetts). LM were defined as irregularly shaped, discrete echogenic masses and these were classified according to location, form and size (Figure 1). Right ventricle (RV) dysfunction was defined as M-Mode TAPSE < 17 mm and TDI S' < 9.5 cm/s.

When LM were found at TEE, second level examinations were performed in the first month after generator replacement, according to the physician choice: 18-fluorodeoxyglucose positron emission tomography/computed tomography (FDG-PET/CT) and ^{99m}Tc-hexamethypropylene-amine oxime labelled autologous white blood cell scintigraphy (WBC SPECT). All patients were re-evaluated by the same TEE instrument during follow-up at 3, 6 and 12 months after generator replacement. Thereafter, TEE examination was performed according to physician choice during yearly follow-up, and in all patients at the last follow-up visit.

Endpoints

Primary endpoint was to evaluate the prevalence of LM in asymptomatic patients. Secondary endpoints were to identify predictive factors of lead masses and to define their prognostic impact at long-term follow-up.

Statistical analysis

Categorical variables (presented as numbers and percentages) were compared with the use of Pearson's chi-squared test and Fisher' exact test. Parametric distribution of continuous variables (presented as means ± SD) was tested graphically and with Kolmorogov Smirnov and appropriate analyses were used according to the results. Univariate Cox regression analysis and baseline variables adjustment were used to identify predictors of LM. All statistical analyses were performed with SPSS 21 (SPSS Inc., Chicago, IL, USA) and differences were considered significant at α=0.05.

The study was performed in accordance to the latest Declaration of Helsinki and patients provided written informed consent to participate in the study and to undergo TEE for

experimental purposes. The Institutional Committee on Human Research at our institution approved the protocol.

RESULTS

Follow up was 60±4 months. Baseline characteristics of the study population are summarized in Table 2.

Cardiovascular risk factors and comorbidities are equally distributed between patients with and without LM. However, a higher prevalence of heart failure (HF) was observed in patients without lead masses (p=0.08).

As far as the CIED system, the types of different devices (single chamber pacemakers [SC PM], dual chamber PM [DC PM], single chamber implantable cardioverter-defibrillators [SC ICD], dual chamber ICD [DC ICD] and cardiac resynchronisation therapy-defibrillators [CRT-D]) were equally distributed between the two groups as the number of leads.

At TTE examination, increased thickness and hyperechogenicity of the lead was observed in 7 patients; LM were confirmed at TEE in the same 7 patients and detected in 3 more cases with negative TTE findings. Thus, LM where observed in 10 patients overall (12.8%). Specific characteristics concerning TEE-detected LM are summarized in Table 3 A.

Univariate analysis for all the baseline clinical variables, drug therapy, CIED and echocardiographic data was compelled. RV dysfunction was identified as the only independent predictor for development of LM (OR 2.71, P = 0.010) and remained significantly associated with LM after baseline variables adjustment (HR: 6.25, P = 0.012) (Table 3 B). The patients with RV dysfunction showed a normal or slightly enlarged right ventricular telediastolic diameter (range: 35-45 mm) and a mild-moderate tricuspid regurgitation (range: 2-3+/4+) with a mild increase of pulmonary pressure regime (range: 35-55 mmHg).

Second-level investigations, like FDG-PET/CT (performed in 6 patients) and WBC SPECT (performed in 4 patient) were carried out in patients with LM found at initial evaluation. Such investigations never disclosed active signs of infection along the leads.

WBC SPECT only showed increased captation at the device pocket in 2 patients. In these 2 patients such examinations were performed two and three weeks after the replacement procedure, respectively.

During follow-up, TEE was repeated in all patients, disclosing LM unchanged or slightly reduced, and no occurrence of new ones (Figure 2). At 5-year follow-up without any specific therapy, the asymptomatic patients with LM did not suffer from any CDI. One patient died for a non-cardiac disease (multiple myeloma).

DISCUSSION

LM in asymptomatic patients were observed in an unsuspected high percentage, about 13%. Clinical variables are equally represented in the groups with and without LM. The observed tendency toward a higher prevalence of HF in patients without LM was not statistically significant and due to the small group size.

Strength of the study

The strength of the study is the strict selection of the population. Moreover, the long follow-up time clears any doubt that in the absence of clinical suspicion of CDI LM findings has no clinical implications. The consecutive patients enrolment over a 6-months period is also an important criterion to rule out selection bias.

Comparison of TTE and TEE findings

Increased thickness and hyper echogenicity of the lead segment is the main finding at TTE, without a clear demonstration of definite, discrete individual masses. Such thickening has been observed in 7 out of 10 patients with subsequent positive TEE findings. Similar higher sensitivity of TEE in comparison of TTE has been observed also in CDRIE

populations. (6, 8) Probably, sensitivity of TEE is much higher in cases of “soft” masses during their formation and therefore during the acute phases of lead-related infective endocarditis (LRIE), (9) but this is not the case in our study, which refer to a chronic, stable situation. TEE has been useful in confirming lead thickening, and in disclosing occasional LM. TEE surely helped a better definition of the shape, profile and dimensions of the LM, their thickness, singleness and/or multiplicity (Figure 1), like is also well known for LRIE. (8)

However, a routine TEE is not feasible neither clinically warranted for the follow-up of asymptomatic CIED patients. Our results can promote a regular screening by means of TTE for lead morphology after CIED implantation. We think that at least a single baseline evaluation should be done at two-three years after implantation or at time of generator replacement. In performing such echocardiographic evaluation, particular attention has to be paid to slight but significant increase of thickness of the lead profile, thus suggesting in these peculiar cases a closer examination by means of TEE. Such baseline evaluation might represent a useful comparison in the subsequent course. In cases of controversial diagnosis of CDRIE, persistence of unchanged LM closely address to a non-infectious aetiology (Figure 2).

Prevalence of LM at TEE and intracardiac echocardiography (ICE)

TEE has been performed in our study in order to disclose the prevalence of LM in CIED patients and not for the diagnosis or evaluation of a certain/suspected cardiac disease like in other studies. (7, 10) In fact, our patients were admitted for elective generator replacement, representing a true “healthy” non-infectious population. Moreover, the strict inclusion criteria excluded a mild previous, recent or active CDI.

Other studies evaluated the prevalence of endocavitary masses in asymptomatic patients with CIED, undergoing TEE for different reasons (evaluation of valvular diseases,

cardioversion, transcatheter ablation). Such settings show a prevalence of LM about 5-28%, (7, 10, 11) but these populations may suffer from selection bias due to their cardiac concomitant diseases. Moreover, these studies are retrospective, (7, 10) or refer only to a small segment of the focused population.[11]

TTE and TEE sensitivity may be too low for masses located in the upper superior vena cava (USVC). These sites can be better evaluated by intracardiac echocardiography (ICE) (12, 13). By means of ICE the prevalence of intracardiac masses is 2 (14)-30% (15) at any level in patients undergoing trans-catheter ablation. In such a setting, these masses could represent the remnant of a past infectious process or more reasonably the fibrotic evolution of a thrombotic apposition. In cases of LRIE, ICE may be the only technique useful in detecting vegetations, (12, 16, 17) particularly fresh soft ones, or remnants or “ghosts” of residual fibrous tissue or endothelial flaps floating at USVC level and/or protruding in the right atrium after TLE. (18) ICE in comparison with TEE, has a greater sensitivity in disclosing LM on the ventricular lead at the tricuspid crossing, and on the tricuspid valve. This has been well documented in cases of LRIE. (16) The greater sensitivity of ICE at these locations might probably be due to technical issues. ICE can detect small, soft LM localized in cardiac areas that are not easily scanned from TEE, such as the atrio-ventricular part of the right ventricular lead and the tricuspid valve, anteriorly located away from the TEE beam. Apart from its costs, ICE in an invasive procedure, and therefore it is indicated for the diagnosis of LRIE, in the presence of a definite clinical suspicion, when all the other techniques are inconclusive, or for planning or monitoring TLE. (16, 17, 19, 20). Consequently, ICE is not warranted for screening of asymptomatic, stable, patients. Thus, the true prevalence and clinical significance of LM at USVC may be completely unknown.

Location of LM/RV dysfunction

Interestingly, LM were mainly found on the atrial lead in double chamber (DC) devices and along the atrial course of right ventricular (RV) lead in single chamber (SC) devices. Probably this finding might be due to low flow/staunching blood in the right atrial chamber, and to the close proximity to the auricle of the tip of the atrial lead. On the contrary, the distal part/tip of the RV lead has been less frequently found with LM, probably because the higher mechanical stress and pulsatile contact with the endocardium might preclude LM formation. Furthermore, this finding might be perhaps consistent with chronic thrombotic apposition as the aetiological mechanism responsible for LM formation. Such an interpretation can account for the observed strict association with RV dysfunction. In fact, this seem the pathological setting where the well-known Virchow factors (mainly stasis and turbulence) might act to increase thrombotic apposition along to CIED leads. To the best of our knowledge, this preferential location of LM at the atrial level has been never reported in literature.

In a different setting, such as ICE examination during ablation procedures, the occurrence of mobile lead thrombi (LT) on CIED leads, not routinely recognized by TTE, has already been studied by Others (15). Interestingly, according to our results, LT were more commonly identified in the right atrium than in the right ventricle. Moreover, LT were associated with higher pulmonary artery systolic pressure, further confirming the association found in our study with right ventricular dysfunction. Therefore, right ventricular dysfunction might represent a predisposing factor to thrombotic process or fibrotic apposition on the catheter due to an abnormal flow pattern inside the right atrial chamber.

Lung Multislice Computed Tomography Scan (Lung MSCT)

No patient underwent CT lung scan. Septic pulmonary embolism is a minor Duke criterion. (2) Moreover, signs of infected pulmonary embolism on CT angiography, consistent

with shifting of vegetations to the pulmonary bed, and also recurrent pneumonia in CIED carriers, have been recently proposed as new Duke major criteria for the diagnosis of LRIE. (21)

In this context, lung multislice computed tomography (MSCT) is considered in the diagnostic algorithm for the diagnosis of IE in European Society of Cardiology (ESC) Guidelines. (22) Indeed, in the previous version of the ESC Guidelines (23) the role of MSCT was restricted to the evaluation of IE-associated valvular abnormalities, particularly to the assessment of the perivalvular extent of abscesses and pseudo-aneurysms. Our patients were enrolled in the study before the publication of 2015 Guidelines, and we did not consider necessary to perform CT scan in apparently “healthy” subjects. The follow-up of our patients closely supports our behaviour, demonstrating that in this “healthy” clinical setting the use of MSCT does not add further significant diagnostic information and prognostic definition.

With regard to this patient profile, in the light of our experience, this practice should be discouraged in the future, involving significant toxicity owing to the use on contrast dye, without adding significant and useful information.

l8-Fluorodeoxyglucose positron emission tomography/computed tomography (FDG-PET/CT) and ^{99m}Tc-hexamethypropylene-amine oxime labelled autologous white blood cell scintigraphy (WBC SPECT)

In 2015 ESC included two other additional tools for the diagnosis of IE, (22) FDG-PET/CT WBC SPECT. In our experience, such techniques can be useful to disclose an occult or doubt infection, (24, 25) as demonstrated also by Others (26-29) and it can confirm the sterile nature of LM. FDG-PET/CT, however, can show false positive findings due to abnormal hypermetabolic activity at the CIED pocket owing to recent interventions. This

hypercaptation usually disappears 4 – 8 weeks after the procedure, and is never observed after 6 months (30)

FDG-PET/CT and WBC SPECT have been performed in our patients within one month. The positive results of WBC SPECT in two individual patients can be viewed as a nonspecific finding due to the recent surgery. Therefore caution should be exercised in interpreting data in cases of recent pocket procedures, and probably in such scenario FDG-PET/CT and WBC SPECT should not be performed.

A completely different setting lies in cases of clinical suspicion of pocket infection. It is well known that local symptoms at the pacemaker pocket may indicate a latent systemic infection. (4) In this case, vegetations can be found with unexpected prevalence, and noteworthy in local infection/chronic draining sinus, (3) thus confirming the infectious involvement of the whole CIED system. CDRIE has high morbidity and mortality, approximately 10-21 %. (31) Therefore, a prompt diagnosis and treatment in such cases is mandatory, due to the worst prognosis, further worsened also after a deferred TLE. (32)

Follow-up

At follow-up none of our patients suffered from long-term infectious complications. Our study clearly demonstrates that non-infectious intracardiac masses do not influence long-term prognosis with consequent important effects on therapeutic decisions.

LM are a major Duke criteria yet?

The application of classic Duke criteria (7) to patients with CIED is still debated. (21) The absence of vegetations, or their observation when clinical suspicion is lacking, does not allow ruling out or strengthening a clear diagnosis of CDRIE.

CIED system may represent a peculiar setting, where differentiating between infectious vegetations and non-infectious LM cannot be viewed apart from the strict evaluation of the clinical scenario. Probably lead vegetations alone have low sensitivity for diagnosing LRIE, being frequently absent even in cases of proven infective involvement documented by bacteriological analysis on lead fragments. (33) Probably, lead vegetations have low specificity, being observed also in absence of infection, as shown in our study.

The “strong” conclusion that the modified Duke's criteria, and particularly the value of LM, have to be reconsidered for the diagnosis of LRIE does not seem appropriate in the context of our study. However, in CIED patients, Duke’s criteria should be critically evaluated. Incidental non-infectious LM are not associated with increased morbidity and mortality. This has been yet demonstrated in other retrospective studies, where TEE has been performed for indications other than evaluation of LM in CIED patients. (10)

Our prospective long-term study strongly points out that when LM are accidentally disclosed by TEE performed for other indications, like before transcatheter ablation or for valve evaluation, no further diagnostic evaluation is required, like FDG-PET/CT scanning, WBC SPECT and lung MSCT. What is new and intriguing is the identification of a possible predictive factor, which may give further insights about the etio-pathogenesis of non-infectious LM.

STUDY LIMITATIONS

Our study has some limitations. First, it is a single centre study with a small sample size. Second, we don’t have any histological data of the LM that would be very useful to classify those findings. Third, TEE may miss some masses that, while present, are too small to be adequately visualize such the prevalence may be underestimated.

CONCLUSIONS

There is an evidence of clinical LM in asymptomatic patients with CIED, but they are not necessarily associated to an infection. The value of these findings is still debated. More studies are needed to understand the clinical role of these finding, how they can impact prognosis and indicate a specific therapy. These analyses are fundamental to reflect and reconsider the occurrence of LM/lead vegetations as a major diagnostic Duke's criteria of endocarditis in patients with CIED, that has to be interpreted in the light of, and regarding to, the clinical "infectious" or "sterile" scenario.

TABLES

Table 1. Inclusion and exclusion criteria.

Inclusion criteria	- Age ≥18 years - CIED dwelling time ≥ 6 months
Exclusion criteria	- Skin swelling or tenderness, adherence, eczema, abnormal pigmentation, erythema, warmth, pain, dehiscence, draining sinus at the level of the generator pocket or other signs / symptoms of suspected infection of the CIED pocket in progress - Previous pocket revisions or interventions other than elective replacement - Fever or other signs / symptoms of systemic infection in progress in the last 3 months - Antibiotics, anti-inflammatory or corticosteroid drugs administration in the last 3 months - History of CIED infection with prolonged antibiotics administration / CIED pocket revision / transvenous lead extraction - Contraindications to TEE - Age ≥ 80 years - Clinical/hemodynamic instability - Poor clinical status or comorbidities likely to influence medium-term prognosis (*) - Inability to provide informed consent - Patient's refusal.

(*) See text for explanation

Abbreviations: CIED = cardiac implantable electronic device; TEE = transesophageal echocardiography.

Table 2. Demographic and clinical variables, therapies, CIED and echocardiographic data.

		Whole population (78 patients)	Without LM (68 patients)	With LM (10 patients)	p value
Demographic characteristics					
	Age	71 (±10.3)	70.2 (±10.8)	74.1 (±5.8)	0.275
	Female gender	27 (34.6)	23 (33.8)	4 (40)	0.701
	Diabetes Mellitus	17 (21.8)	14 (20.6)	3 (30)	0.501
	CKD	19 (24.4)	17 (25)	2 (20)	0.731
	CAD	28 (35.9)	25 (36.8)	3 (30)	0.677
	HF	27 (34.6)	26 (38.2)	1 (10)	0.080
	Previous stroke/TIA	12 (15.4)	10 (14.7)	2 (20)	0.647
	AF	32 (41.1)	27 (39.7)	5 (50)	0.537
	Malignancy	3 (3.8)	2 (2.9)	1 (10)	0.278
Therapies					
	Aspirin	37 (47.4)	33 (48.5)	4 (40)	0.614
	Clopidogrel	7 (8.9)	6 (8.8)	1 (10)	0.903
	DAPT	6 (7.7)	5 (7.4)	1 (10)	0.769
	OAC	33 (42.3)	29 (42.6)	4 (40)	0.874
CIED data and history					

	SC PM	21 (26.9)	18 (26.5)	3 (30)	0.800
	DC PM	29 (37.2)	25 (36.8)	4 (40)	0.838
	SC ICD	9 (11.5)	8 (11.8)	1 (10)	0.946
	DC ICD	11 (14.1)	10 (14.7)	1 (10)	0.768
	CRT-D	7 (8.9)	6 (8.8)	1 (10)	0.852
	Leads number < 3	70 (89.8)	61 (89.7)	9 (90)	0.903
	Leads number ≥ 3	8 (10.3)	7 (10.3)	1 (10)	0.903
	Dwelling time > 5 years	78 (100)	68 (100)	10 (100)	
	Most recent procedure				
	- First implantation	61 (78.2)	55 (80.9)	6 (60)	0.28
	- Replacement	17 (21.8)	13 (19.1)	4 (23.5)	0.28
Echocardiographic data					
	EF	49 (±6.5)	48.1 (±15.7)	54 (±11.4)	0.258
	EF < 40%	27 (34.6)	25 (36.8)	3 (30)	0.677
	Atrial spontaneous echo contrast	8 (10.3)	7 (10.3)	1 (10)	0.977
	Right ventricular dysfunction	10 (12.8)	6 (8.8)	4 (40)	0.006
	Right atrium >19 cmq	35 (44.9)	28 (41.2)	4 (40)	0.944

Continuous variables are presented as means ± standard deviation (SD), while categorical variables as counts and percentage (%).

Abbreviations: CIED = cardiac implantable electronic devices; LM: lead masses; DM = diabetes mellitus; CKD = chronic kidney disease; CAD = coronary artery disease; MI = myocardial infarction; TIA = transient ischemic attack; AF = atrial fibrillation; SC PM = single chamber pacemaker, DC PM = dual chamber pacemaker; SC ICD = single chamber implantable cardioverter defibrillator; DC ICD = dual chamber implantable cardioverter defibrillator; CRT-D = cardiac resynchronization therapy defibrillator; HF= heart failure; DAPT = double antiplatelet therapy; OAC= oral anticoagulants; EF = ejection fraction; ESPAP= estimated systolic pulmonary arterial pressure.

Table 3A. Characteristics of patients with lead masses.

Patient #	CIED	Size of the Largest LM (mm^2)	Location of masses	Multiple masses	WBC ($x10^3$/ml)	CRP (mg/dL)	Fibrinogen (mg/dl)	Alive /Dead
1	SC PM	4	AV	No	6.63	3.15	298.65	Dead (Multiple Myeloma)
2	SC PM	9	VV	No	4.60	2.90	404.32	Alive
3	SC PM	8	VV	No	6.45	13.20	375.00	Alive
4	DC PM	2	AV	Yes	7.53	7.90	299.04	Alive
5	DC PM	11	AA	Yes	7.93	3.00	336.78	Alive
6	CRT-D	3	AV	No	8.56	4.74	197.17	Alive
7	DC PM	14	AV	Yes	6.34	2.00	200.00	Alive
8	DC PM	7	AV + AA	Yes	3.68	4.10	421.00	Alive
9	SC ICD	5	AV	No	5.39	0.50	277.42	Alive
10	DC ICD	7	VV	No	7.5	2.70	320.55	Alive

Table 3B. Univariate regression analysis for development of LM, before and after baseline variables adjustment.

	Univariate regression analysis		**After baseline variables adjustment**	
	OR	**P value**	**HR**	**P value**
Right ventricular dysfunction	2.71	0.010	6.25	0.012

Baseline variables considered for adjustment were all demographic characteristics: age, female gender, diabetes mellitus, CKD, CAD, HF, previous stroke/TIA, AF, malignancy.

Abbreviations: CIED = cardiac implantable electronic devices; LM: lead masses; SC PM = single chamber pacemaker; DC PM = dual chamber pacemaker; SC ICD = single chamber implantable cardioverter defibrillator; DC ICD = dual chamber implantable cardioverter defibrillator; CRT-D = cardiac resynchronization therapy defibrillator; AV = atrial tract of the ventricular lead; VV = ventricular tract of the ventricular lead; AA = atrial tract of the atrial lead; WBC = white blood cell; CRP = C-reactive protein; OR = odds ratio; HR = hazard ratio; DM = diabetes mellitus.

FIGURES LEGEND

Figure 1: Example of polylobate lead masses.

Increased thickness and hyper echogenicity of the lead segment is the main finding, with linear or irregularly-shaped profile. In this case, a multiple, polylobate-shaped profile is observed.

Figure 2: Persistence of unchanged lead masses at 1-year TEE follow-up. Left: baseline. Right: one-year after.

FIGURES

Figure 1

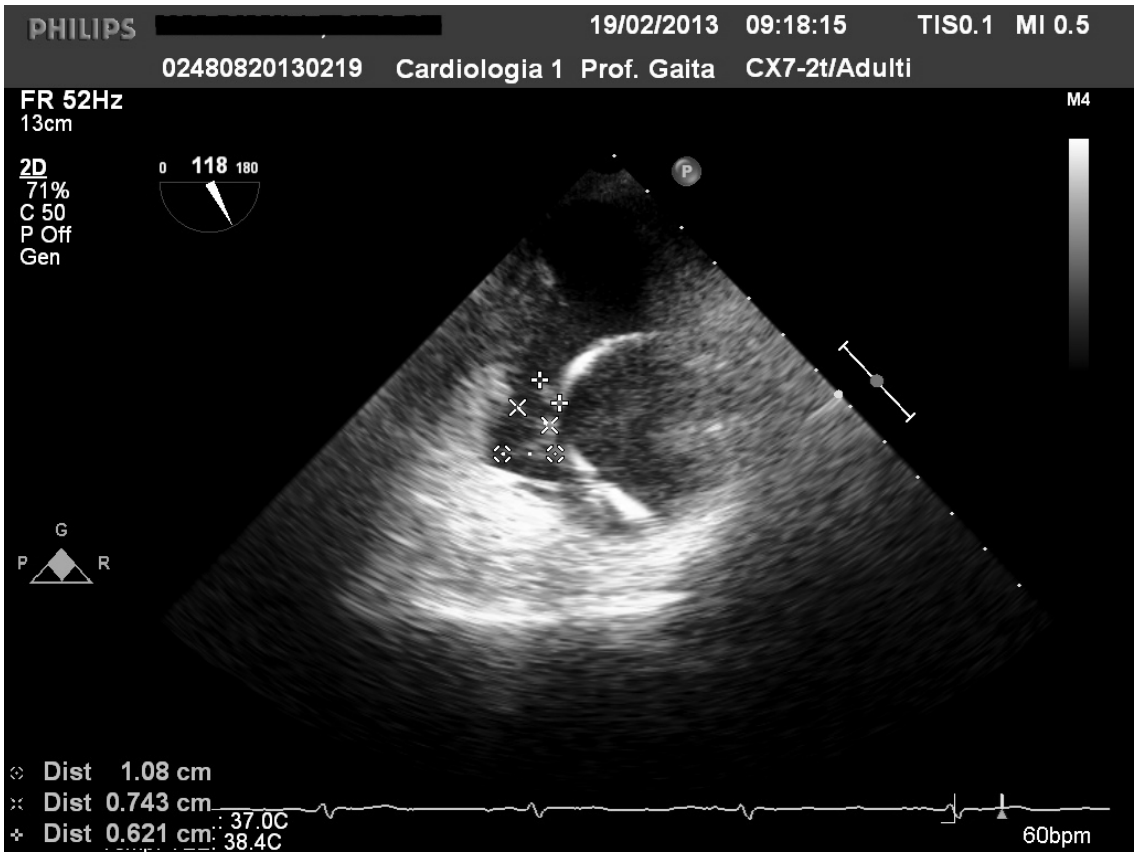

Figure 2

REFERENCES

1. Maytin M, Jones SO, Epstein LM. Long-term mortality after transvenous lead extraction. Circ Arrhythm Electrophysiol. 2012;5(2):252-7.
2. Li JS, Sexton DJ, Mick N, Nettles R, Fowler VG, Jr., Ryan T, et al. Proposed modifications to the Duke criteria for the diagnosis of infective endocarditis. Clin Infect Dis. 2000;30(4):633-8.
3. Golzio PG, Fanelli AL, Vinci M, Pelissero E, Morello M, Grosso Marra W, et al. Lead vegetations in patients with local and systemic cardiac device infections: prevalence, risk factors, and therapeutic effects. Europace. 2013;15(1):89-100.
4. Klug D, Wallet F, Lacroix D, Marquie C, Kouakam C, Kacet S, et al. Local symptoms at the site of pacemaker implantation indicate latent systemic infection. Heart. 2004;90(8):882-6.
5. Polewczyk A, Janion M, Podlaski R, Kutarski A. Clinical manifestations of lead-dependent infective endocarditis: analysis of 414 cases. Eur J Clin Microbiol Infect Dis. 2014;33(9):1601-8.
6. Victor F, De Place C, Camus C, Le Breton H, Leclercq C, Pavin D, et al. Pacemaker lead infection: echocardiographic features, management, and outcome. Heart. 1999;81(1):82-7.
7. Lo R, D'Anca M, Cohen T, Kerwin T. Incidence and prognosis of pacemaker lead-associated masses: a study of 1,569 transesophageal echocardiograms. J Invasive Cardiol. 2006;18(12):599-601.
8. Massoure PL, Reuter S, Lafitte S, Laborderie J, Bordachard P, Clementy J, et al. Pacemaker endocarditis: clinical features and management of 60 consecutive cases. Pacing Clin Electrophysiol. 2007;30(1):12-9.
9. Klug D, Lacroix D, Savoye C, Goullard L, Grandmougin D, Hennequin JL, et al. Systemic infection related to endocarditis on pacemaker leads: clinical presentation and management. Circulation. 1997;95(8):2098-107.
10. Downey BC, Juselius WE, Pandian NG, Estes NA, 3rd, Link MS. Incidence and significance of pacemaker and implantable cardioverter-defibrillator lead masses discovered during transesophageal echocardiography. Pacing Clin Electrophysiol. 2011;34(6):679-83.
11. Dundar C, Tigen K, Tanalp C, Izgi A, Karaahmet T, Cevik C, et al. The prevalence of echocardiographic accretions on the leads of patients with permanent pacemakers. J Am Soc Echocardiogr. 2011;24(7):803-7.
12. Koneru JN, Ellenbogen KA. Detection of transvenous pacemaker and ICD lead vegetations: the ICE cold facts. J Am Coll Cardiol. 2013;61(13):1406-8.
13. Dalal A, Asirvatham SJ, Chandrasekaran K, Seward JB, Tajik AJ. Intracardiac echocardiography in the detection of pacemaker lead endocarditis. J Am Soc Echocardiogr. 2002;15(9):1027-8.
14. Sugrue A, DeSimone CV, Lenz CJ, Packer DL, Asirvatham SJ. Mobile thrombus on cardiac implantable electronic device leads of patients undergoing cardiac ablation: incidence, management, and outcomes. J Interv Card Electrophysiol. 2016;46(2):115-20.
15. Supple GE, Ren JF, Zado ES, Marchlinski FE. Mobile thrombus on device leads in patients undergoing ablation: identification, incidence, location, and association with increased pulmonary artery systolic pressure. Circulation. 2011;124(7):772-8.

16. Narducci ML, Pelargonio G, Russo E, Marinaccio L, Di Monaco A, Perna F, et al. Usefulness of intracardiac echocardiography for the diagnosis of cardiovascular implantable electronic device-related endocarditis. J Am Coll Cardiol. 2013;61(13):1398-405.
17. Bongiorni MG, Di Cori A, Soldati E, Zucchelli G, Arena G, Segreti L, et al. Intracardiac echocardiography in patients with pacing and defibrillating leads: a feasibility study. Echocardiography. 2008;25(6):632-8.
18. Rizzello V, Dello Russo A, Casella M, Biddau R. Residual fibrous tissue floating in the right atrium after percutaneous pacemaker lead extraction: an unusual complication early detected by intracardiac echocardiography. Int J Cardiol. 2008;127(2):e67-8.
19. Sadek MM, Cooper JM, Frankel DS, Santangeli P, Epstein AE, Marchlinski FE, et al. Utility of intracardiac echocardiography during transvenous lead extraction. Heart Rhythm. 2017;14(12):1779-85.
20. Arena G, Bongiorni MG, Soldati E, Dell'Anna R, Mariani M. Utilità dell'ecografia intracardiaca durante le procedure di rimozione transvenosa degli elettrocateteri. Italian Heart J. 2002;3(Suppl. 7):120S.
21. Polewczyk A, Janion M, Kutarski A. Cardiac device infections: definition, classification, differential diagnosis, and management. Pol Arch Med Wewn. 2016;126(4):275-83.
22. Habib G, Lancellotti P, Antunes MJ, Bongiorni MG, Casalta JP, Del Zotti F, et al. 2015 ESC Guidelines for the management of infective endocarditis: The Task Force for the Management of Infective Endocarditis of the European Society of Cardiology (ESC). Endorsed by: European Association for Cardio-Thoracic Surgery (EACTS), the European Association of Nuclear Medicine (EANM). Eur Heart J. 2015;36(44):3075-128.
23. Habib G, Hoen B, Tornos P, Thuny F, Prendergast B, Vilacosta I, et al. Guidelines on the prevention, diagnosis, and treatment of infective endocarditis (new version 2009): the Task Force on the Prevention, Diagnosis, and Treatment of Infective Endocarditis of the European Society of Cardiology (ESC). Eur Heart J. 2009;30(19):2369-413.
24. Golzio PG, Manganiello S, Gaita F. Labelled leucocyte scintigraphy in an infected externalized Riata lead. Europace. 2014;16(10):1442.
25. Golzio PG, Gabbarini F, Anselmino M, Vinci M, Gaita F, Bongiorni MG. Gram-positive occult bacteremia in patients with pacemaker and mechanical valve prosthesis: a difficult therapeutic challenge. Europace. 2010;12(7):999-1002.
26. Juneau D, Golfam M, Hazra S, Zuckier LS, Garas S, Redpath C, et al. Positron Emission Tomography and Single-Photon Emission Computed Tomography Imaging in the Diagnosis of Cardiac Implantable Electronic Device Infection: A Systematic Review and Meta-Analysis. Circ Cardiovasc Imaging. 2017;10(4).
27. Ahmed FZ, James J, Cunnington C, Motwani M, Fullwood C, Hooper J, et al. Early diagnosis of cardiac implantable electronic device generator pocket infection using (1)(8)F-FDG-PET/CT. Eur Heart J Cardiovasc Imaging. 2015;16(5):521-30.
28. Erba PA, Conti U, Lazzeri E, Sollini M, Doria R, De Tommasi SM, et al. Added value of 99mTc-HMPAO-labeled leukocyte SPECT/CT in the characterization and management of patients with infectious endocarditis. J Nucl Med. 2012;53(8):1235-43.
29. Erba PA, Sollini M, Conti U, Bandera F, Tascini C, De Tommasi SM, et al. Radiolabeled WBC Scintigraphy in the Diagnostic Workup of Patients With Suspected Device-Related Infections. JACC Cardiovasc Imaging. 2013.
30. Sarrazin JF, Philippon F, Tessier M, Guimond J, Molin F, Champagne J, et al. Usefulness of fluorine-18 positron emission tomography/computed tomography for identification of cardiovascular implantable electronic device infections. J Am Coll Cardiol. 2012;59(18):1616-25.

31. Athan E, Chu VH, Tattevin P, Selton-Suty C, Jones P, Naber C, et al. Clinical characteristics and outcome of infective endocarditis involving implantable cardiac devices. JAMA. 2012;307(16):1727-35.
32. Diemberger I, Biffi M, Lorenzetti S, Martignani C, Raffaelli E, Ziacchi M, et al. Predictors of long-term survival free from relapses after extraction of infected CIED. Europace. 2018;20(6):1018-27.
33. Klug D, Wallet F, Kacet S, Courcol R. Detailed bacteriological tests to identificate the origin of transvenous pacing system infections indicate a high prevalence of multiple organisms. Am Heart J. 2005;149(2):322-8.