

Surgical procedures performed to improve the prosthetic prognosis in case of maxillary defects: a review of the literature

➤ **G. RUGGIERO¹, N. BOCCA², G. MAGRINI³, A. D'ADDONA³, M. CAROSSA², G. GASSINO²**

¹Department of Neurosciences, Reproductive and Odontostomatological Sciences, University "Federico II" of Naples, Naples, Italy

²Department of Surgical Sciences, Interdepartmental Center of Research (CIR), Dental School, Oral and Maxillofacial Rehabilitation, University of Turin, Turin, Italy

³Department of Dental Clinic, Catholic University of the Sacred Heart of Rome, Rome, Italy

TO CITE THIS ARTICLE

Ruggiero G, Bocca N, Magrini G, D'addona A, Carossa M, Gassino G. Surgical procedures performed to improve the prosthetic prognosis in case of maxillary defects: a review of the literature. *J Osseointegr* 2019;11(4):519-524.

DOI 10.23805 /JO.2019.11.03.09

ABSTRACT

Aim The purpose of this review is to address the surgical procedures that need to be followed to obtain a maxillary defect that can be suitable to receive a prosthesis.

Methods An extensive search of the literature was performed, on the databases of PubMed/Medline and Scopus, in addition to congress proceedings and books, written in English or Italian. Literature search was performed using combinations of the following keywords: ("obturator prognosis" OR "palatal obturator" OR "obturator prosthesis" OR "prosthetic prognosis") AND ("maxillectomy" OR "maxillary defect").

Results 35 articles, 2 books and 3 congress proceedings were included. After the study of the records included in this review, it was found that surgeon must preserve the anterior maxilla as much as possible, because it is the most suitable site for the placement of implants. Furthermore, if the implant site is involved in post-operative radiotherapy, it is advisable to know the x-ray dose of such an exposition. The surgical cut should preserve mucosa and bone support around the tooth adjacent to the defect, and keratinized mucosa should cover the palatal margin of the defect Equally important is to prepare an adequate access to the defect, because the turbinates and the bands of oral mucosa may prevent the prosthesis from engaging key areas of the defect, impairing function.

Conclusion A complete knowledge about the construction techniques and biological/mechanical principles of maxillofacial prosthesis is essential to perform surgical interventions that enhance the prosthetic prognosis.

KEYWORD Obturator prognosis, palatal obturator, obturator prosthesis, prosthetic prognosis, maxillary defect.

INTRODUCTION

Over the years, different classification systems of maxillary defects have been proposed, to describe the anatomical limits of defects following maxillectomy. In their systematic review, Bidra et al. (1) concluded that a description of the maxillectomy defect based on 6 criteria could be more objective and amenable to a universal use than a description of the defect based only on a classification system, because of the anatomic complexity of the maxilla and of the various types of maxillary defects that make it not easy to identify a single classification that meets the surgical and prosthetic requirements and that is easy to remember and use.

The six criteria identified by Bidra et al. were the following.

- 1) Dental status.
- 2) Oroantral/nasal communication status.
- 3) Soft palate and other contiguous structure involvement.
- 4) Superior-inferior extent.
- 5) Anterior-posterior extent.
- 6) Medial-lateral extent of the defect (1).

Currently, in oncological surgery, a conservative surgical approach is a must, allowing surgical aggressivity to be reduced to the minimum required to guarantee its effectiveness in terms of lesion removal and, at the same time, to allow the possibility of an efficient closure of the maxillary defect by a correct obturator prosthesis. An obturator is a prosthesis for closing an acquired or congenital opening of the palate (2). It is generally indicated for smaller defects, while microvascular grafts are highly recommended for larger defects, with particular reference to defects requiring a bone support. An obturator is the only solution to give the patient

a better life quality when a microvascular surgery approach is not feasible due to the characteristics and dimensions of the lesion or to poor systemic-medical conditions.

Multiple surgical techniques have been considered over the years to solve problems subsequent to maxillectomy, like free flaps including grafts harvested from rectus abdominus, radial forearm, lateral arm, fibula, iliac crest, and scapula (3, 4). This approach, however, is limited by difficulties in controlling facial contour, soft tissue prolapse, poor facial skin color match, and loss of direct tumor surveillance (3,5-8). Therefore, prosthetic rehabilitation should be taken into account by the clinical team, for the advantages that it is able to bring compared to surgery alone, such as: reduction in loss of substance, control of tumor recurrences, restoration of function and aesthetics.

As reported by El Fattah et al., clinical success in patients undergoing maxillectomy depends on some factors: pre-prosthetic surgical preparation of the defect site, dimension and location of the defect, amount and integrity of the remaining structures (3).

Therefore, the final result should be an "ideal maxillary defect" specifically created to receive a prosthesis, without compromising the tumor's resection, improving aesthetics, function and psychological status of the patient.

This paper is aimed at reviewing the literature on the surgical principles to improve prosthetic prognosis in patients with maxillary defects after maxillectomy.

METHODS

Search strategy

The authors performed an extensive search of the literature, published until January 2019, on the databases of PubMed/Medline and Scopus, in addition to congress proceedings, books and manuals related to the prosthetic rehabilitation of the maxillary defects, written in English or Italian. To avoid missing relevant studies, the authors also reviewed the reference lists of the identified articles, congress proceedings and books. Literature search was performed using combinations of the following keywords: ("obturator prognosis" OR "palatal obturator" OR "obturator prosthesis" OR "prosthetic prognosis") AND ("maxillectomy" OR "maxillary defect").

The literature search was completed in January 2019, and the studies included in this review were published between 1968 and September 2018.

The search strategy and results are reported in Table 1.

Inclusion and exclusion criteria

Studies were considered as appropriate for inclusion in this review if they met the following criteria.

1) Studies focusing on the prosthetic rehabilitation of

Database	Search strategy	Records
PubMed	("obturator prognosis" OR "palatal obturator" OR "obturator prosthesis" OR "prosthetic prognosis") AND ("maxillectomy" OR "maxillary defect")	155
Scopus	("obturator prognosis" OR "palatal obturator" OR "obturator prosthesis" OR "prosthetic prognosis") AND ("maxillectomy" OR "maxillary defect")	317
Books	Books published in Italian or English regarding maxillofacial prosthetic rehabilitation	2
Congress Proceedings	Manual search of the congress proceedings carried out during the events of the "International Congress on Maxillofacial Prosthetics" and of the "International Congress on Pre-Prosthetic Surgery"	3

TABLE 1 - Search strategy for each database and relative records

- the maxillary defects.
- 2) Studies based on the implant-prosthetic rehabilitation of the maxillary defects.
 - 3) Studies that address the problem of implant-prosthetic rehabilitation in the patient undergoing radiation therapy.
 - 4) Studies that provide useful explanations on the surgical procedures to be followed in order to rehabilitate the patient with a defect of the upper jaw.
 - 5) Studies published in Italian or English.
- The following were the exclusion criteria.
- 1) Non-human studies.
 - 2) *In vitro* studies.
 - 3) Studies published in languages other than English or Italian.

Data extraction

Following the inclusion criteria, three authors independently selected the articles by reading relevant abstracts. The full text of each identified article was then read to determine whether it was suitable for inclusion. The authors were in agreement regarding the inclusion of all the articles included in this review.

RESULTS

Study selection

The search strategy produced 472 records, many of which were duplicates, 317 from Scopus and 155 from PubMed. All the duplicates were removed, thus all of the selected databases produced 338 records. After the examination of titles, abstracts and keywords, the reviewers excluded 230 records, because they did not meet the inclusion and exclusion criteria. Of the remaining 108 records, 73 were excluded because they did not provide useful information to evaluate which surgical modifications should be followed to improve the prosthetic prognosis of the maxillary obturators. The remaining 35 articles were included in the present systematic review.

Furthermore, a manual search was conducted through manuals of maxillofacial prostheses and congress proceedings carried out during the events of the "International Congress on Maxillofacial Prosthetics" and of the "International Congress on Pre-Prosthetic Surgery". After this manual search, 2 books and 3 congress proceedings were included because they met the inclusion and exclusion criteria.

The workflow of the paper screening process is reported in Figure 1, according to the "PRISMA 2009 Flow Diagram" (9).

Evaluated surgical modifications

After an extensive review of the literature, the authors highlighted the points on which to focus on in order to improve the prosthetic prognosis of the obturators: the importance of the hard palate for the retention of implants; the usefulness of skin graft; the retention of the teeth adjacent to the defect; the preservation of palatal mucosa; the removal of the coronoid process and of the soft palate; the accessibility of the obturator through the defect; the implant therapy and the new digital technologies and finally the management of the patient undergoing radiotherapy.

Hard palate: retention of the anterior maxilla improves prosthetic prognosis through the enhancement of stability and support of the prosthesis (especially in highly atrophic ridges).

The anterior maxilla is the preferred site for the placement of implants in these edentulous patients, so if a large part of this region can be preserved, more implants can be positioned to achieve a better retention of the obturator prosthesis and an improved tolerance to masticatory forces (10).

Skin grafts: the key to the success of the prosthetic rehabilitation is the utilization of the lateral wall of the defect left by the surgical procedure. Covering the reflected cheek flap and other adjacent raw tissue surfaces with a split-thickness skin graft allows to enhance the obturator's retention and tolerance, in patients with total maxillectomy defects. Respiratory

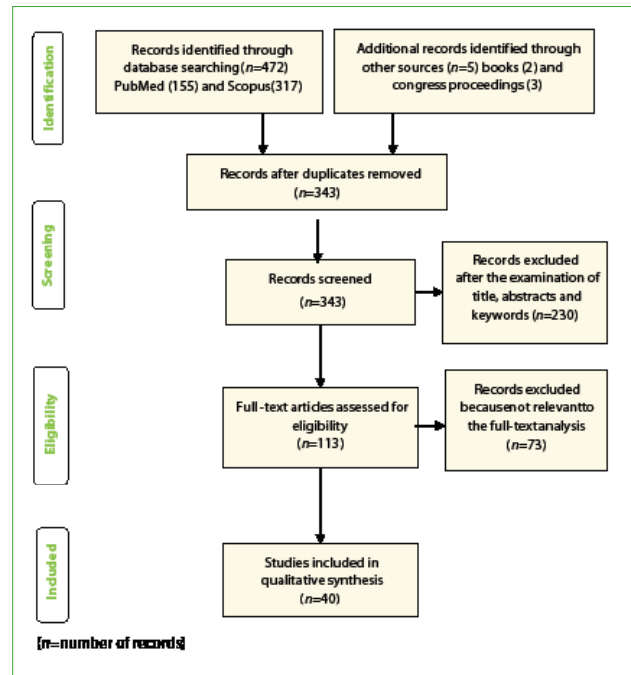


FIG. 1 The workflow of the paper screening process.

epithelium is less resistant to the abrasion caused by the obturator than keratinized stratified squamous epithelium. Moreover, when the defect is allowed to granulate and epithelialize spontaneously, it can be covered by poorly keratinized epithelium. Placement of the skin graft limits scarring and improves the flexibility of the cheek area, so there will be more support and better restoration of the midfacial contours with the obturator prosthesis. It is worth noticing that at the junction of the oral mucosa and the skin graft, a longitudinal scar band is formed, which creates a retentive pocket above and a support area below the band. Engaging the scar band superiorly and inferiorly with the prosthesis enhances retention, stability and support (10-15).

Transalveolar resection: the surgical incision should provide the availability of bone and mucosa near the tooth adjacent to the defect, although this can require the sacrifice of a dental element. This tooth is often involved in prosthetic retention, by using clasp and rest, and, in cases of large defects, can be subjected to excessive loads. Scarcity or lack of bone around this tooth significantly limits its involvement as a retaining element and makes a proper prosthetic design of the prosthesis difficult to obtain. For these reasons, maxillectomy should be performed making the bone resection at the center of the alveolar socket of the adjacent, previously extracted, tooth. It is critical that the line of incision of the mucosa is made laterally to the bone cutting line, so subsequently the mucosa will be reflected to cover the medial margin of the defect. This procedure provides a sufficient quantity of bone

to the distal side of the tooth medially localized to the defect (10). So, a satisfactory retention of this tooth in its alveolus will be ensured and it will maintain its retentive function.

Palatal mucosa: when possible, the surgeon should save some portions of the palatal mucosa normally included in the resection area. In addition, he should reflect this tissue during palatal bone resection, because it could be used later to cover the medial palatal bone margin. This bone margin should be surgically rounded before covering it with palatal mucosa.

Keratinized mucosa should cover the palatal margin of the defect, in such a way that the prosthesis may optimally engage this surface, so that the lateral stability of the prosthesis obturator can be improved. In fact, in these edentulous patients, the palatal margin of the defect often behaves as the fulcrum around which the prosthesis rotates during function.

Surgeons may perform a split-thickness skin graft to cover the medial surface of the defect, when an appropriate amount of palatal keratinized mucosa is not available due to the size of the tumor (10).

In patients undergoing hemimaxillectomy, with a reduced number of remaining teeth, the closure of the palatal flap with rotated temporalis muscle can lead to the onset of difficulties for the prosthetic rehabilitation. Some of these are the following.

- The different axes of rotation of the prosthesis.
- The possible difficulty in directing the occlusal forces along the long axes of the remaining teeth without applying excessive lateral loads.
- The possible difficulty in getting a good stability of the prosthesis during masticatory function (15).

Coronoid process: when mandible moves downward and forward, the coronoid process can cause the displacement of the disto-lateral portion of the obturator and/or the inflammation of the adjacent mucosa. Therefore, surgeon should remove the coronoid process, particularly when the resection extends posteriorly into the soft palate. If the coronoid process is not removed, then postoperative pain and limitation of mandibular movements will be observed (3, 17).

Soft palate: when less than one-third of the posterior aspect of the soft palate is left postsurgically in the resected side, the entire soft palate should be removed. This remnant band of intact soft palate, in fact, has neither innervation nor capacity for normal elevation, so that these nonfunctional bands often contract superiorly, thus preventing proper positioning of an obturator prosthesis designed to interface with the residual velopharyngeal musculature still present in the postero-lateral pharyngeal wall. However, surgeon should not remove the entire soft palate when there is an edentulous patient undergoing a total maxillectomy. In such situation the retention of the obturator is difficult and the extension of the obturator to the nasal side of the residual soft palate is an advantage that overcomes

the possible speech and leakage problems (10).

Access to the defect: structures such as the turbinates and bands of oral mucosa may prevent the prosthesis from engaging key areas of the defect, compromising its function. Actually, the extension of the obturator up the lateral wall of the defect enhances the retention and stability of the prosthesis, and the engagement of the lateral nasal side of the orbital floor provides support for the obturator. Naturally, the situation worsens when the post-surgical defect is very large. So, it is advisable to include the turbinates in the surgical resection, but this advice may not apply to small midline defects of the hard palate-soft palate junction because the superior extension of the obturator is not as critical (14).

Implants: when the prognosis for the remaining teeth is not favorable or when the patient is totally edentulous, the placement of some implants might be an effective therapeutic choice. The most appropriate and frequent site where they can be placed is the remaining premaxilla (10, 18, 19). In certain edentulous patients, the alveolar process under the maxillary sinus, like maxillary tuberosities, might offer sufficient bone for a proper implant placement.

These implants can be placed immediately after surgical resection of the tumor, but the use of bony sites adjacent to the defect is not advisable, except in some particular cases, because the maintenance of a proper hygiene becomes quite difficult around the implants (10).

In patients undergoing hemimaxillectomy, the defect does not allow an ideal distribution of the implants.

The placement of zygomatic implants and "patient-specific sub-periosteal implant" (20) can be considered to rehabilitate a largely compromised maxillary bone anatomy (20-21), and this solution can help to achieve an additional retentive element and a more balanced distribution of forces (22).

The retentive systems described in the literature to retain an obturator are: locators (23), bars (24-25), and telescopic attachments (26).

Another key point is to restore proper adherent mucosa in the insertion area of the implants.

In a case reported by Ciocca et al. (16), it has been reported that after a Le Fort I fracture (27), with retrusion of the maxilla and complete edentulism, bone veneers were positioned in the pre-maxilla in order to place implants allowing a greater prosthetic anchorage. However, this procedure led to a subsequent positioning of the fixtures in the lip mucosa with hygienic difficulties for the cleaning of the abutments (16).

Digital technology: it is an undisputable fact that, in the last years, Computer Aided Design/Computer Aided Manufacturing (CAD-CAM) systems and, more generally, digital technologies have become widespread in every field of dentistry. Recently, significant progress has been made with the use of implants and with digital technology to design surgical guides, patient-specific sub-periosteal implants, superstructures and

craniofacial implants (20, 28).

A study of Mertens et al. demonstrated that cross-arch CAD/CAM milled superstructures supported by implants and placed in both residual alveolar ridges and contralateral zygomatic bone could enhance obturator stability and improve functional outcomes (26, 29).

Furthermore, the CAD/CAM superstructures improved retention, without any mechanical or biological complications (26).

In the scientific literature there are several case reports and innovative digital workflows for the construction of an obturator prosthesis. The conventional procedures for the realization of these prostheses, however, are not totally supplanted by new digital technologies, in fact to date there is no protocol that does not require at least an "analogic" step compared to a workflow that therefore can not be defined totally digital, but "hybrid", because of the intercalation of at least one analogic step in a digital workflow.

In some works (30-33) the authors started from the digitization of the upper jaw; the digitization could be obtained with cone beam computed tomography (CBCT) systems (31-34) sometimes associated with the datasets of a magnetic resonance imaging (33) or of an intraoral scanner (IOS) or a laboratory scanner (30, 32).

Other authors (30) first scanned the upper jaw with an IOS and then they designed and printed (with three-dimensional printer) a metal frame as a support to obtain a functional impression of the defect.

George Michelinakis (31) scanned the maxilla using a CBCT system, and printed a three-dimensional model, useful to fabricate a custom acrylic tray for the final impression of the remaining maxilla and the maxillary defect.

Radiotherapy: the maxillofacial prosthodontist has a key role in limiting the negative effects of radiotherapy through the design and construction of specific devices that direct the rays towards the anatomical area that should have to be treated with radiotherapy and not in the healthy surrounding tissues not affected by the tumor.

Between the secondary effects that could cause difficulties for the prosthodontist, during the rehabilitation of maxillary defects, there are: trismus of the masticatory muscles, mucositis, quantitative and qualitative alterations of saliva and periodontal disease. If the positioning site of the implant is subjected to exposure of rays during the post-operative radiotherapy, then it will be advisable to know the dose to which this site will be subjected, because if the dose is excessive, then the positioning of the implants will be an unwise procedure at the time of tumor ablation.

If the use of radiation therapy is not programmed, then the placement of implants will be indicated at the time of surgical resection of the tumor, but if the use of radiation therapy is programmed, the placement of the implants must be made at least one and a half

months prior to the first session of radiotherapy, so it is influenced by staging and histology of the tumor (10, 35-38). The risk of osteoradionecrosis increases with doses exceeding 50Gy (39), 60Gy (40), 65Gy (41), and 70Gy (42); the necrosis of the soft tissues may occur with doses lesser than 50 Gy, while damage to the salivary glands can be achieved with doses lesser than 20 Gy (42-44).

In their study, Claudy et al. (45) concluded that there is a higher risk of failure if implants are installed within a period of less than 12 months after radiotherapy, however, there is no evidence from clinical trials to verify this risk (45).

CONCLUSION

The prosthodontist has the task of restoring aesthetics and function but such a task is not easy to achieve in cases of resected patients. Not only the effectiveness of rehabilitation depends on the extension of the residual alveolar ridge, but it is also related to the number of remaining teeth and the degree of resection. Today, new plastic surgery techniques and endosseous implants have enhanced the prognosis of such prosthetic rehabilitations.

Unfortunately, not all surgical interventions are performed in a way that plead a possible prosthetic rehabilitation; the reason could be that there is not always a complete knowledge about the construction techniques and biological/mechanical principles of maxillofacial prosthesis.

Conflict of interests

The authors declare no potential conflict of interests.

No funding.

REFERENCES

1. Bidra AS, Jacob RF, Taylor TD. Classification of maxillectomy defects: a systematic review and criteria necessary for a universal description. *J Prosthet Dent.* 2012;107:261-70.
2. Miller-Keane Encyclopedia and Dictionary of Medicine, Nursing, and Allied Health, Seventh Edition. 2003. Saunders, an imprint of Elsevier. S.v. "obturator." Available from <https://medical-dictionary.thefreedictionary.com/obturator>.
3. El Fattah H, Zaghoul A, Pedemonte E, Escuin T. Pre-Prosthetic surgical alterations in maxillectomy to enhance the prosthetic prognoses as part of rehabilitation of oral cancer patient. *Med Oral Patol Oral Cir Bucal.* 2012;17:262-70.
4. Adisman IK. Prosthesis serviceability for acquired jaw defects. *Dent Clin North Am.* 1990;34:265-84.
5. Cheney ML, Varvares MA, Nadol JB Jr. The temporoparietal fascial flap in head and neck reconstruction. *Arch Otolaryngol Head Neck Surg.* 1993;119:618-23.
6. Chepeha DB, Wang SJ, Marentette LJ, et al. Restoration of the orbital aesthetic subunit in complex midface defects. *Laryngoscope.* 2004;114:1706-13.

7. Ellis DS, Toth BA, Stewart WB. Temporoparietal fascial flap for orbital and eyelid reconstruction. *Plast Reconstr Surg.* 1992;89:606-12.
8. Olsen KD, Meland NB, Ebersold MJ, et al. Extensive defects of the sino-orbital region. Results with microvascular reconstruction. *Arch Otolaryngol Head Neck Surg.* 1992;118:828-33.
9. Liberati A, Altman DG, Tetzlaff J, et al. The PRISMA statement for reporting systematic reviews and meta-analyses of studies that evaluate health care interventions: explanation and elaboration. *J Clin Epidemiol* 2009;62:e1–34.
10. Beumer J 3rd, Marunick MT, Garrett N, et al. Rehabilitation of Maxillary Defects. In: Beumer J 3rd, Marunick MT, Esposito SJ et al. *Maxillofacial rehabilitation, Prosthodontic and Surgical Management of Cancer-Related, Acquired, and Congenital Defects of the Head and Neck.*, third edition. Quintessence Books. 2012; pp 161-165.
11. Wood RH, Carl W. Hollow silicone obturators for patients after total Maxillectomy. *J Prosthet Dent.* 1977;38:643-51.
12. Cheng AC, Somerville DA, Wee AG. Altered prosthodontic treatment approach for bilateral complete maxillectomy: a clinical report. *J Prosthet Dent.* 2004;92:120-4.
13. Sjövall L, Lindqvist C, Hallikainen D. A new method of reconstruction in a patient undergoing bilateral total maxillectomy. *Int J Oral Maxillofacial Surg.* 1992;21:342-5.
14. Beumer J 3rd, Nishimura R, Roumanas ED. Maxillary defects: Alterations at Surgery to Enhance the Prosthetic Prognosis. *Proceedings of the 1st International Congress on Maxillofacial Prosthetics.* 1994 April 27-30; Indian Wells, California; pp 22-26.
15. Desjardins R. Obturator prosthesis design for acquired maxillary defects. *J Prosthet Dent* 1978;39:424.
16. Ciocca L, Gassino G, Scotti R. Capitolo 1: Mascellare Superiore. In: Ciocca L, Scotti R, Marchetti C, Gassino G. *Lezioni di protesi maxillo-facciale.* Syllabus Addendum 2nd edition. Libreria Bonomo Editrice; 2008. pp 4-35.
17. Brown KE. Peripheral consideration in improving obturator retention. *J Prosthet Dent.* 1968;20:176-81.
18. Futran ND, Wadsworth JT, Villaret D, Farwell DG. Midface reconstruction with the fibula free flap. *Arch Otolaryngol Head Neck Surg.* 2002;128:161-6.
19. Roumanas ED, Nishimura RD, Davis BK, Beumer J 3rd. Clinical evaluation of implants retaining edentulous maxillary obturator prostheses. *J Prosthet Dent.* 1997;77:184-90.
20. N. Vosselman, B. J. Merema, K. P. Schepman, G. M. Raghoobar: Patient-specific subperiosteal zygoma implant for prosthetic rehabilitation of large maxillary defects after oncological resection. *Int. J. Oral Maxillofac. Surg.* 2019;48:115–117.
21. Mittal S, Agarwal M, Chatterjee D. Rehabilitation of Posterior Maxilla with Obturator Supported by Zygomatic Implants. *Case Rep Dent.* 2018 Apr 23;2018:3437417.
22. Miyamoto S, Ujigawa K, Kizu Y, et al. Biomechanical three-dimensional finite-element analysis of maxillary prostheses with implants. Design of number and position of implants for maxillary prostheses after hemimaxillectomy. *Int J Oral Maxillofac Surg.* 2012;39:1120-6.
23. Kreissl ME, Heydecke G, Metzger MC, Schoen R. Zygoma implant-supported prosthetic rehabilitation after partial maxillectomy using surgical navigation: a clinical report. *J Prosthet Dent.* 2007;97:121-8.
24. Nothdurft FP, Propson M, Spitzer WJ, Pospiech PR. Implant-borne prosthesis for an edentulous maxilla with a large maxillectomy defected step-wise therapy concept. *Schweizer Monatsschrift fur Zahnmedizin = Revue mensuelle suisse d'odonto-stomatologie = Rivista mensile svizzera di odontologia e stomatologia.* 2008;118:827-42.
25. Weischer T, Schettler D, Mohr C. Titanium implants in the zygoma as retaining elements after hemimaxillectomy. *Int J Oral Maxillofac Implants.* 1997;12:211-4.
26. Mertens C, de San Jose Gonzalez J, Freudlsperger C, et al. Implant-prosthetic rehabilitation of hemimaxillectomy defects with CAD/CAM suprastructures, *Journal of Cranio-Maxillo-Facial Surgery.* 2016;44:1812-8.
27. Le Fort, R. Etude experimental sur les fractures de la machoire superieure, Parts I, II, III. 1901;23:208–27, 360–79, 479–507.
28. Ariani N, Visser A, van Oort RP, et al. Current state of craniofacial prosthetic rehabilitation. *Int J Prosthodont.* 2013;26:57-67.
29. Schmidt BL, Pogrel MA, Young CW, Sharma A. Reconstruction of extensive maxillary defects using zygomatic implants. *J Oral Maxillofac Surg.* 2004;62:82-9.
30. Park JH, Lee KS, Lee JY, Shin SW. Fabricating a Maxillary Obturator Using an Intraoral Digital Impression: A Case History Report. *Int J Prosthodont.* 2017;30:266-268.
31. Michelinakis G. The use of cone beam computed tomography and three dimensional printing technology in the restoration of a maxillectomy patient using a dental implant retained obturator. *J Indian Prosthodont Soc.* 2017;17:406-411.
32. Ye H, Ma Q, Hou Y, et al. Generation and evaluation of 3D digital casts of maxillary defects based on multisource data registration: A pilot clinical study. *J Prosthet Dent.* 2017;118:790-795.
33. Kortés J, Dehnad H, Kotte ANT, et al. A novel digital workflow to manufacture personalized three-dimensional-printed hollow surgical obturators after maxillectomy. *Int J Oral Maxillofac Surg.* 2018;47:1214-1218.
34. Tasopoulos T, Kouveliotis G, Polyzois G, Karathanasi V. Fabrication of a 3D Printing Definitive Obturator Prosthesis: a Clinical Report. *Acta Stomatol Croat.* 2017;51:53-58.
35. Granstrom G, Bergstrom G, Tjellstrom A, Branemark P. Bone-anchored rehabilitation of irradiated head and neck cancer patients. *Proceedings of the 1st International Congress on Maxillofacial Prosthetics; 1994 April 27-30; Indian Wells, California; pp 286-291.*
36. Jacobsson M, Tjellstrom A, Thomson P, et al. Integration of titanium implants in irradiated bone. Histologic and clinical study. *Annual Otol. Rhinol. Laringol.* 1988;97:337.
37. Roumanas E, Nishimura R, Beumer J. Craniofacial defects and osteointegrated implants: six years follow up report on the success rates of craniofacial implants at UCLA. *Intl J Oral Maxillofac Implants.* 1994;9:579.
38. Weinlander M, Beumer J, Nishimura R. Histological and histomorphometrical evaluation of implant-bone interface after radiation therapy. *Proceedings of the 5th International Congress on Pre-Prosthetic Surgery; 1993 April 15-18; Vienna, Austria; p. 83.*
39. Visch LL, van Waas MA, Schmitz PI, Levendag PC. A clinical evaluation of implants in irradiated oral cancer patients. *Journal of dental research.* 2002;81:856-9.
40. Thorn JJ, Hansen HS, Specht L, Bastholt L. Osteoradionecrosis of the jaws: clinical characteristics and relation to the field of irradiation. *J Oral Maxillofac Surg.* 2000;58:1088-93.
41. Nguyen TD, Panis X, Froissart D, et al. Analysis of late complications after rapid hyperfractionated radiotherapy in advanced head and neck cancers. *Int J Radiat Oncol Biol Phys.* 1988;14:23-5.
42. Marx RE, Johnson RP. Studies in the radiobiology of osteoradionecrosis and their clinical significance. *Oral Surg Oral Med Oral Pathol.* 1987;64:379-90.
43. Jones KR, Lodge-Rigal RD, Reddick RL, et al. Prognostic factors in the recurrence of stage I and II squamous cell cancer of the oral cavity. *Arch Otolaryngol Head Neck Surg.* 1992;118:483-5.
44. Shugaa-Addin B, Al-Shamiri HM, Al-Maweri S, Tarakji B. The effect of radiotherapy on survival of dental implants in head and neck cancer patients. *J Clin Exp Dent.* 2016;8:e194-200.
45. Claudy MP, Miguens SA Jr, Celeste RK, et al. Time interval after radiotherapy and dental implant failure: systematic review of observational studies and meta-analysis. *Clin Implant Dent Relat Res.* 2015;17:402-11.