

AperTO - Archivio Istituzionale Open Access dell'Università di Torino

**Case series of six kidney transplanted patients with COVID-19 pneumonia treated with tocilizumab**

**This is the author's manuscript**

*Original Citation:*

*Availability:*

This version is available <http://hdl.handle.net/2318/1741494> since 2021-04-16T14:20:14Z

*Published version:*

DOI:10.1111/tid.13348

*Terms of use:*

Open Access

Anyone can freely access the full text of works made available as "Open Access". Works made available under a Creative Commons license can be used according to the terms and conditions of said license. Use of all other works requires consent of the right holder (author or publisher) if not exempted from copyright protection by the applicable law.

(Article begins on next page)



PROFESSOR LUIGI BIANCONE (Orcid ID : 0000-0002-7700-6350)

Article type : Case Report

**Case series of six kidney transplanted patients with COVID-19 pneumonia treated with tocilizumab**

Authors: Alberto Mella MD, PhD (1)  
Silvia Mingozzi MD (1)  
Ester Gallo MD (1)  
Antonio Lavacca MD (1)  
Maura Maria Rossetti MD (1)  
Roberta Clari MD (2)  
Olga Randone MD (3)  
Stefano Maffei MD (3)  
Mario Salomone MD (2)  
Daniele Imperiale MD (4)  
Luigi Biancone MD, PhD (1)

Authors' institutional affiliations:

- 1) Renal Transplant Center “A. Vercellone”, Nephrology, Dialysis and Renal Transplant Division, “Città della Salute e della Scienza” Hospital, Department of Medical Sciences, University of Turin, Turin, Italy

This article has been accepted for publication and undergone full peer review but has not been through the copyediting, typesetting, pagination and proofreading process, which may lead to differences between this version and the [Version of Record](#). Please cite this article as [doi: 10.1111/TID.13348](https://doi.org/10.1111/TID.13348)

This article is protected by copyright. All rights reserved

- 2) Department of Nephrology and Dialysis, Ospedale Maggiore di Chieri, Chieri, Italy
- 3) Department of Nephrology and Dialysis, Cardinal Massaia Hospital, Asti, Italy
- 4) Unit of Neurology, Ospedale Maria Vittoria, ASL TO2, Torino, Italy

Corresponding author: Luigi Biancone, [luigi.biancone@unito.it](mailto:luigi.biancone@unito.it)

Running Head: COVID-19+ kidney transplant: tocilizumab

## Abstract

Few reports described the outcome of kidney transplanted patients (KTs) affected by COVID-19 treated with interleukin-6 receptor inhibitor Tocilizumab (TCZ). We report our case series of 6 KT with COVID-19 pneumonia who received TCZ: all were of male gender, with a mean age of  $55.5 \pm 8.4$  years, a median time from transplantation of 3611 days (1465-5757); 5/6 had cardiovascular comorbidities, 1/6 had diabetes and 3/6 have one or more previous KT.

Four out of six patients died, at an average time of  $9.75 \pm 2.4$  days after tocilizumab administration, 3/6 due to a coexistent septic shock. Two patients improved after TCZ and were discharged at 20 and 21 days respectively; in both patient a significant increase of total lymphocyte count was observed.

In conclusion KT, where the role of peculiar factors such as chronic immunosuppression is still undetermined, represent a high-risk group with significant COVID-19 associated mortality. The evaluation of the TCZ effect in COVID-19 pneumonia requires controlled studies (ideally RCTs) in this specific population.



## Background

Severe acute respiratory syndrome coronavirus 2 (named SARS CoV-2/COVID-19) is a novel pandemic infectious disease, which emerged in Wuhan, China, in late December 2019 and spread rapidly worldwide<sup>1,2</sup>. At the time we are writing (05/10/2020) in Italy there are about 219000 patients infected, 28600 only in Piedmont, our region<sup>3</sup>. Clinically, the disease is characterized with fever, cough, dyspnea, diarrhea and eventually respiratory failure<sup>4,5</sup>. According to their intrinsic frailty and comorbidities, transplanted patients were considered a high-risk population<sup>6,7</sup>.

Tocilizumab (TCZ), a humanized monoclonal antibody against Interleukin-6 (IL-6) receptor widely adopted in adult rheumatoid arthritis and also used as rescue therapy for chronic antibody-mediated rejection in kidney transplantation<sup>8</sup>, has been recently registered for the treatment of severe or life-threatening chimeric antigen receptor T-cell induced cytokine release syndrome (CRS) in adult and pediatric patients<sup>9</sup>. In this context, because the development of acute respiratory distress syndrome (ARDS) in COVID-19 pneumonia has been associated with activation of the immune system and consequent cytokine storm with high levels of IL-6, some initial reports suggested a beneficial role of this drug<sup>10,11</sup>, also in solid organ transplanted patients<sup>12</sup>. Herein we reported our experience in 6 kidney transplanted patients treated with TCZ after occurrence of COVID-19 infection.

## Case series

Clinical characteristics and laboratory data are shown in Table 1 and 2. Figure 1 reported the timeline of maintenance immunosuppression, COVID-19 specific treatments and outcome. In all patients, diagnosis was performed by nasopharyngeal swab test (PCR) and chest radiography or high-resolution computed tomography (HRCT). TCZ was administered once daily for two consecutive days (dose 8 mg/kg) after a consultation with infectious disease specialist in patients with contemporary evidence of pulmonary involvement (oxygen saturation - SaO<sub>2</sub> - <93% if patients breath ambient air, or a ratio of the partial pressure of oxygen -PaO<sub>2</sub>- to the fraction of inspired oxygen - FiO<sub>2</sub>- of less than 300 mm Hg) and pro-inflammatory profile (C-reactive protein and/or IL-6 > x 10 normal values). All patients gave written informed consent for TCZ off-label use.

### *Patient 1*

41 years old patient. He received kidney transplant from deceased donor 15 years ago. Ongoing immunosuppressive therapy was composed by tacrolimus (TAC) and prednisone.

After few days of fever and cough patient was tested positive for COVID-19 on 03/25/2020. TAC was immediately discontinued while glucocorticoids (methylprednisolone 20 mg daily) were maintained. In the same day of the diagnosis, hydroxychloroquine and antiviral treatment (Darunavir/Ritonavir 800/100 mg) were started, in association with antibiotic therapy (cefepime). On day 7 after diagnosis, because of rapid worsening of respiratory status, TCZ was administered and repeated in day 8; concomitantly, according to progressive deterioration of kidney function and difficult management of fluid overload, continuous renal-replacement therapy (CRRT) was initiated. Despite the antibiotic therapy implementation with azithromycin, respiratory failure occurred needing mechanical ventilation from day 15; patient died two days after.

#### *Patient 2*

65 years old patient. He received kidney transplant from a deceased donor on March 2020. A negative COVID-19 test was obtained before kidney transplant, and no positive contact with COVID-19 subjects was reported in the days before KT.

Induction immunosuppressive therapy was composed by Thymoglobulin (for three days) and methylprednisolone, and subsequent maintenance therapy included TAC (levels 10-12 ng/mL), mycophenolate mofetil (MMF) and prednisone. Patient also received ganciclovir for CMV prophylaxis (CMV IgG-/donor CMV IgG+).

Eight days after KT patient experienced fever and cough; swab test was subsequently repeated and resulted positive. Immunosuppressive medications (TAC, MMF) were immediately stopped, except of glucocorticoids (methylprednisolone 20 mg/day). Patient started hydroxychloroquine (200 mg daily) and Darunavir/Ritonavir (800/100 mg daily) the day after, and remained hemodynamically stable with only slow reduction of peripheral oxygen saturation (94-95% with low-flow oxygen through nasal cannula); TCZ was administered on day 4 and 5.

On day 6 arterial pO<sub>2</sub> decreased and patient started non-invasive ventilation (NIV); after a further deterioration of pulmonary status mechanical ventilation was needed from day 7.

On day 8 blood and urinary cultures were both positive for multi-sensitive *Klebsiella Pneumoniae* (urinary culture was also positive for *Enterococcus Faecalis*), and antibiotic treatment was shifted from amoxicillin/clavulanic acid to cefepime.

Despite progressive modifications on antibiotic therapy (with at least adoption of gentamicin, piperacillin/tazobactam and daptomycin), fluid and medication support patient became oliguric (starting CRRT from day 12) and died on day 17.

#### *Patient 3*

54 years old patient. He received his third kidney transplant in 2014. Ongoing immunosuppressive therapy was composed by TAC and glucocorticoids. On 04/03/2020 patient experienced fever, emesis and diarrhea, and tested positive for COVID-19. TAC was immediately discontinued, and only methylprednisolone 20 mg/daily was maintained in association of hydroxychloroquine (200 mg/day). On day 2, hemoptoe and worsening of respiratory status occurred. Oral anticoagulant therapy (in patient with mechanical aortic valve) was stopped and replaced by low-molecular-weight heparin, and non-invasive ventilation (NIV) was started. TCZ was administered on day 2 and 3. On day 12, after an improvement in respiratory condition, NIV was suspended; patient was discharged on day 20. Currently (26 days after discharge), he recovered to normal pulmonary functional status, keeping only steroids (prednisone 25 mg/day) as immunosuppressive therapy.

#### *Patient 4*

62 years old patient. He performed his second KT on 2007. Immunosuppressive therapy was composed by TAC, MMF and steroids. On 03/22/2020 patient experienced fever, dyspnea and diarrhea and then tested positive for COVID-19. TAC and MMF were immediately discontinued. Hydroxychloroquine 200 mg daily, methylprednisolone 20 mg daily and piperacillin-tazobactam, in association to fluconazole, were started. A rapid worsening of respiratory status was observed from day 1 after diagnosis, needing mechanical ventilation. TCZ was administered (8 mg/kg) on day 16; respiratory status showed no improvement and patient deceased on day 26.

#### *Patient 5*

49 years old patient. He received kidney transplant 18 years ago. Ongoing immunosuppressive therapy was TAC, MMF and glucocorticoids. On 03/24/2020 he was admitted to the Emergency Department because fever and cough from two days. After positive swab test, TAC level was reduced, MMF was stopped, and hydroxychloroquine (200 mg/day) plus antibiotic therapy (ceftaroline) were started.

On day 4, after progressive worsening of respiratory status, TAC was discontinued and NIV plus TCZ were started. On day 11, IVIg (0.2 g/kg/day) were also administered for four consecutive days. On day 16 glucocorticoid therapy was increased with methylprednisolone 40 mg twice daily. NIV was discontinued on day 17 and the patient was discharged on day 21 after diagnosis.

Currently (12 days after discharge), pulmonary function recovered to basal patient's status and TAC target through level are progressively increased to 4-5 ng/mL with glucocorticoids maintained.

#### *Patient 6*

62 years old patient. He received KT in 2011. Ongoing immunosuppressive therapy was composed by TAC and glucocorticoids. Patient was admitted to Emergency Department on 04/03/2020 because of fever and dyspnea. After diagnosis of COVID-19 pneumonia, TAC was stopped on day 1 and treatment with hydroxychloroquine (200 mg daily) and amoxicillin-clavulanic acid (1 g twice daily) were started, in association with methylprednisolone 20 mg daily. Mechanical ventilation was also initiated on day 1; TCZ was administered on day 2 and 3. Despite all supportive therapies, pulmonary function rapidly declined and patient deceased on day 8 after diagnosis.

## Discussion

COVID-19 is now considered as the most prominent health-care problem around the world<sup>13</sup>.

Emerging data highlight the role of comorbid conditions (hypertension, diabetes, cardiovascular disease) and older age as major determinants of negative outcome<sup>10</sup>. Recently, kidney disease has also been associated with increased in-hospital mortality<sup>14</sup>.

Transplant patients, due to the combination of this frail profile associated with immunosuppressive medications, are considered a high-risk population<sup>15</sup>; despite preventive strategies and medication protocols are urgently needed, definite guidelines for KT are not currently established and different and specular approaches have so far been reported.

Some group suggest the immediately withdrawn of immunosuppressive drugs with only steroid maintenance<sup>1,16</sup>, despite steroid use is controversial and associated with reduced viral clearance<sup>17</sup>.

Other authors report a possible anti-viral effect of CNI inhibitors<sup>2,4,6,10,18</sup> suggesting per contrast their maintenance in solid organ transplanted patients, especially in liver transplants. This theory is also supported by the evidence that ARDS occurred in patients with important inflammatory activation (the so-called cytokine storm) and in this context immunosuppressive medications and anti-inflammatory drug (i.e. TCZ) may mitigate the damage. All these data are partially questioned by a recent US report<sup>19</sup> where mortality in KT patients is extremely high compared to normal population, despite a recent Spanish case-series detailed a more favorable picture<sup>20</sup>.

To date, few reports included TCZ-treated kidney transplanted patients with COVID-19 pneumonia<sup>12,19-23</sup> (Table 3): in all these available experiences inclusion criteria, dose, f/up and outcome indicators were different, and a significant number of cases were still inpatients.

Despite different timing, in our case series TCZ was administered at the same dosage after deterioration of pulmonary status and contemporary evidence of significant inflammatory activation (increase C-reactive protein and/or IL-6, if available). The adoption of TCZ determined a C-reactive protein reduction in all patients without significant modification in LDH or D-Dimer; also IL-6 decreased in the 2/3 patients with available test, albeit levels remain significantly upper the normal range. However, four out of six patients died; in the 2/6 who recovered a significant increase in lymphocyte count was observed, confirming that a restoration of lymphocyte activity is crucial for obtaining a favorable outcome<sup>24</sup>.

We need to underline that some factors may be confounding in the analysis of the direct effect of TCZ: for example, sepsis may have concurred to death in Patient 1, 4 and 6; however, as reported by other Authors, the virus caused a profound immunosuppression<sup>5,11</sup> and, in this context, the

Accepted Article  
result of combined inhibition of IL-6 receptor in predisposing to bacterial infections is not well understood. We also pointed out that we treated with TCZ only kidney transplanted patients who required hospitalization with significant reduction of pulmonary function and increase of inflammatory markers. At the time we are writing, 20 patients who received KT in our Center were tested positive for COVID-19, and 8/20 (including 4/8 who received TCZ) died. Because all patients with COVID-19 who do not need hospitalization were tested and remained at home we do not have laboratory/pulmonary functional markers to compare this cohort to TCZ treated patients.

In conclusion, despite these data should be evaluated with extremely caution and have some limitations (selection bias, availability of IL-6 dosage in all patients, absence of CD4+/CD8+ count), our study confirmed that kidney transplanted patients are a high-risk group with significant COVID-19 associated mortality. The effect of TCZ for COVID-19 pneumonia need of controlled studies (ideally RCTs) in this specific population.

#### **Disclosure**

The authors of this manuscript have no conflicts of interest to disclose as described by the Transplant Infectious Disease Journal.

The data that support the findings of this study are available from the corresponding author upon reasonable request.

#### **References**

1. Zhu L, Xu X, Ma K, et al. Successful recovery of COVID-19 pneumonia in a renal transplant recipient with long-term immunosuppression. *American Journal of Transplantation*. March 2020. doi:10.1111/ajt.15869.
2. Zhang H, Chen Y, Yuan Q, et al. Identification of Kidney Transplant Recipients with Coronavirus Disease 2019. *European Urology*. March 2020. doi:10.1016/j.eururo.2020.03.030.
3. Coronavirus (COVID-19) Data in Italy, Italian Health Department. <http://www.salute.gov.it/portale/nuovocoronavirus/dettaglioContenutiNuovoCoronavirus.jsp?lingua=italiano&id=5351&area=nuovoCoronavirus&menu=vuoto> , May 10 2020.
4. Wang J, Li X, Cao G, Wu X, Wang Z, et al. COVID-19 in a Kidney Transplant Patient. *European Urology*. March 2020. doi:10.1016/j.eururo.2020.03.036.

5. Huang C, Wang Y, Li X, et al. Clinical features of patients infected with 2019 novel coronavirus in Wuhan, China [published correction appears in *Lancet*. 2020 Jan 30;:]. *Lancet*. 2020;395(10223):497–506. doi:10.1016/S0140-6736(20)30183-5
6. Romanelli A, Mascolo S. Immunosuppression drug-related and clinical manifestation of Coronavirus disease 2019: A therapeutical hypothesis. *American Journal of Transplantation*. April 2020. doi:10.1111/ajt.15905.
7. Guillen E, Pineiro GJ, Revuelta I, et al. Case report of COVID-19 in a kidney transplant recipient: Does immunosuppression alter the clinical presentation? *American Journal of Transplantation*. March 2020. doi:10.1111/ajt.15874.
8. Choi J, Aubert O, Vo A, et al. Assessment of Tocilizumab (Anti-Interleukin-6 Receptor Monoclonal) as a Potential Treatment for Chronic Antibody-Mediated Rejection and Transplant Glomerulopathy in HLA-Sensitized Renal Allograft Recipients. *Am J Transplant*. 2017;17(9):2381–2389. doi:10.1111/ajt.14228
9. Kotch C, Barrett D, Teachey DT. Tocilizumab for the treatment of chimeric antigen receptor T cell-induced cytokine release syndrome. *Expert Rev Clin Immunol*. 2019;15(8):813–822. doi:10.1080/1744666X.2019.1629904
10. Ahmadpoor P, Rostaing L. Why the immune system fails to mount an adaptive immune response to a COVID-19 infection [published online ahead of print, 2020 Apr 1]. *Transpl Int*. 2020;10.1111/tri.13611. doi:10.1111/tri.13611
11. Luo P, Liu Y, Qiu L, et al. Tocilizumab treatment in COVID-19: A single center experience [published online ahead of print, 2020 Apr 6]. *J Med Virol*. 2020;10.1002/jmv.25801. doi:10.1002/jmv.25801
12. Fontana F, Alfano G, Mori G, et al. Covid-19 pneumonia in a kidney transplant recipient successfully treated with Tocilizumab and Hydroxychloroquine [published online ahead of print, 2020 Apr 23]. *Am J Transplant*. 2020;10.1111/ajt.15935. doi:10.1111/ajt.15935
13. World Health Organization. <https://www.who.int/emergencies/diseases/novel-coronavirus-2019>. Apr 27 2020.
14. Cheng Y, Luo R, Wang K, et al. Kidney disease is associated with in-hospital death of patients with COVID-19. *Kidney Int*. 2020;97(5):829–838. doi:10.1016/j.kint.2020.03.005
15. Alberici F, Delbarba E, Manenti C, et al. Management Of Patients On Dialysis And With Kidney Transplant During SARS-COV-2 (COVID-19) Pandemic In Brescia, Italy [published online ahead of print, 2020 Apr 4]. *Kidney Int Rep*. 2020;10.1016/j.ekir.2020.04.001.

doi:10.1016/j.ekir.2020.04.001

16. Gandolfini I, Delsante M, Fiaccadori E, et al. COVID-19 in kidney transplant recipients. *American Journal of Transplantation*. March 2020. doi:10.1111/ajt.15891.
17. Russell CD, Millar JE, Baillie JK. Clinical evidence does not support corticosteroid treatment for 2019-nCoV lung injury. *Lancet*. 2020;395(10223):473–475. doi:10.1016/S0140-6736(20)30317-2
18. Columbia University Kidney Transplant Program. Early Description of Coronavirus 2019 Disease in Kidney Transplant Recipients in New York [published online ahead of print, 2020 Apr 21]. *J Am Soc Nephrol*. 2020;ASN.2020030375. doi:10.1681/ASN.2020030375
19. Akalin E, Azzi Y, Bartash R, et al. Covid-19 and Kidney Transplantation [published online ahead of print, 2020 Apr 24]. *N Engl J Med*. 2020;10.1056/NEJMc2011117. doi:10.1056/NEJMc2011117
20. Montagud-Marrahi E, Cofan F, Torregrosa JV, et al. Preliminary data on outcomes of SARS-CoV-2 infection in a Spanish single centre cohort of kidney recipients [published online ahead of print, 2020 May 5]. *Am J Transplant*. 2020;10.1111/ajt.15970. doi:10.1111/ajt.15970
21. Fernández-Ruiz M, Andrés A, Loinaz C, et al. COVID-19 in solid organ transplant recipients: a single-center case series from Spain [published online ahead of print, 2020 Apr 16]. *Am J Transplant*. 2020;10.1111/ajt.15929. doi:10.1111/ajt.15929
22. Alberici F, Delbarba E, Manenti C, et al. A single center observational study of the clinical characteristics and short-term outcome of 20 kidney transplant patients admitted for SARS-CoV2 pneumonia [published online ahead of print, 2020 Apr 9]. *Kidney Int*. 2020;S0085-2538(20)30365-3. doi:10.1016/j.kint.2020.04.002
23. Pereira MR, Mohan S, Cohen DJ, et al. COVID-19 in Solid Organ Transplant Recipients: Initial Report from the US Epicenter [published online ahead of print, 2020 Apr 24]. *Am J Transplant*. 2020;10.1111/ajt.15941. doi:10.1111/ajt.15941
24. Chen N, Zhou M, Dong X, et al. Epidemiological and clinical characteristics of 99 cases of 2019 novel coronavirus pneumonia in Wuhan, China: a descriptive study. *Lancet*. 2020;395(10223):507–513. doi:10.1016/S0140-6736(20)30211-7

**Authors Contribution:** A.M., S.M. and L.B. wrote the main manuscript text; A.M., S.M., E.G., A.L., M.R., R.C., O.R., S.M., M.S., D.I., L.B. contributed to the conception, design and analysis of the data; all authors also contributed to the revision and approval of the final manuscript.



### Figure legend

**Figure 1: Therapeutic timeline for anti-COVID-19 and immunosuppressant medications in our case series.** MP: methylprednisolone; HCQ: hydroxychloroquine; DAR/RIT: Darunavir/Ritonavir; TCZ: tocilizumab; TAC: tacrolimus; MMF: mycophenolate mofetil; IVIg: intravenous immunoglobulin.

### Table legends

**Table 1:** Clinical characteristics, comorbidities and symptoms at presentation in our COVID-19 positive kidney transplant recipients.

**Table 2:** Laboratory and pulmonary functional tests before and after TCZ adoption in our COVID-19 positive kidney transplant recipients.

**Table 3:** Kidney transplant recipients with COVID-19 treated with tocilizumab (Pubmed update on 05/09/2020).

**Table 1.** Clinical characteristics, comorbidities and symptoms at presentation in our COVID-19 positive kidney transplant recipients

	<b>Patient 1</b>	<b>Patient 2</b>	<b>Patient 3</b>	<b>Patient 4</b>	<b>Patient 5</b>	<b>Patient 6</b>
<b>Gender</b>	Male	Male	Male	Male	Male	Male
<b>Age, years</b>	41	65	54	62	49	62
<b>Previous KT (n)</b>	No	Yes (1)	Yes (2)	Yes (1)	No	No
<b>Time from last KT, days</b>	5354	8	2053	4681	6411	3163
<b>Comorbidities</b>						
Hypertension	Yes	Yes	No	Yes	No	Yes
Diabetes mellitus	No	Yes	No	No	No	No
Cardiovascular disease	No	Yes	Yes	Yes	Yes	Yes
HCV infection**	No	No	No	Yes	Yes	No
<b>Immunosuppressive therapy</b>						
TAC	Yes	Yes	Yes	Yes	Yes	Yes
MMF	No	Yes	No	Yes	Yes	No
Steroids	Yes	Yes	Yes	Yes	Yes	Yes
<b>Symptoms at presentation</b>						
Fever	Yes	Yes	Yes	Yes	Yes	Yes
Cough	Yes	Yes	No	No	Yes	No
Dyspnea	No	No	No	Yes	No	Yes
Diarrhea	No	No	Yes	Yes	No	No

KT: kidney transplant; TAC: tacrolimus; MMF: mycophenolate mofetil

\*intended as last KT

\*\*negative HCV-RNA in both cases after eradication

**Table 2.** Laboratory and pulmonary functional tests before and after TCZ adoption in our COVID-19 positive kidney transplant recipients

	<b>Patient 1</b>	<b>Patient 2</b>	<b>Patient 3</b>	<b>Patient 4</b>	<b>Patient 5</b>	<b>Patient 6</b>
<b>C-reactive protein (mg/L)</b>						
Before TCZ	170.4	90.2	154.7	32	49.8	71.4
Day 3 after TCZ	35.4	20.3	44.6	12	23.7	8.6
At last f/up	3.6	34.9	2.24	10	0.6	2.4
<b>Procalcitonine (ng/mL)</b>						
Before TCZ	24.1	0.19	0.18	0.12	0.43	0.4
Day 3 after TCZ	1.02	0.1	0.3	0.13	0.29	NA
At last f/up	0.17	0.73	0.07	0.15	0.06	0.45
<b>White-cell count [lymphocyte] (per mm<sup>3</sup>)</b>						
Before TCZ	9930 [400]	7240 [370]	4380 [610]	13660 [230]	4130 [300]	7890 [480]
Day 3 after TCZ	11300 [230]	6270 [310]	4020 [800]	21790 [400]	4370 [330]	4110 [140]
At last f/up	6390 [850]	11720 [410]	3770 [950]	36890 [800]	6440 [1030]	10420 [380]
<b>Lactate dehydrogenase (UI/L)</b>						
Before TCZ	771	518	652	704	573	1068
Day 3 after TCZ	496	792	765	565	762	816
At last f/up	480	660	603	814	779	739

<b>D-Dimer (ng/mL)</b>						
Before TCZ	12552	707	730	3188	876	351
Day 3 after TCZ	18111	1497	840	2873	2020	<215
At last f/up	1565	2032	500	2842	1468	281
<b>Ferritin (ng/ml)</b>						
Before TCZ	1754	523	NA	830	1567	955
Day 3 after TCZ	1108	847	NA	637	1065	767
At last f/up	1310	906	NA	840	371	NA

<b>IL-6 (pg/mL)</b>						
Before TCZ	NA	NA	24.9*	465**	NA	312.5**
Day 3 after TCZ	NA	NA	188.7*	564.5**	NA	282.7**
At last f/up	NA	NA	63.3*	1077.6**	NA	NA
<b>PaO<sub>2</sub>/FiO<sub>2</sub> (mmHg)</b>						
Before TCZ	115	291	333	300	83	182
Day 3 after TCZ	135	203	256	111	291	265
At last f/up	92	87	493	170	347	187

TCZ: tocilizumab; PaO<sub>2</sub>: partial pressure of oxygen; FiO<sub>2</sub>: fraction of inspired oxygen

\*normal range 0-4.4

\*\*normal range 2-29

This article is protected by copyright. All rights reserved

**Table 3.** Kidney transplant recipients with COVID-19 treated with tocilizumab (Pubmed update on 05/09/2020)

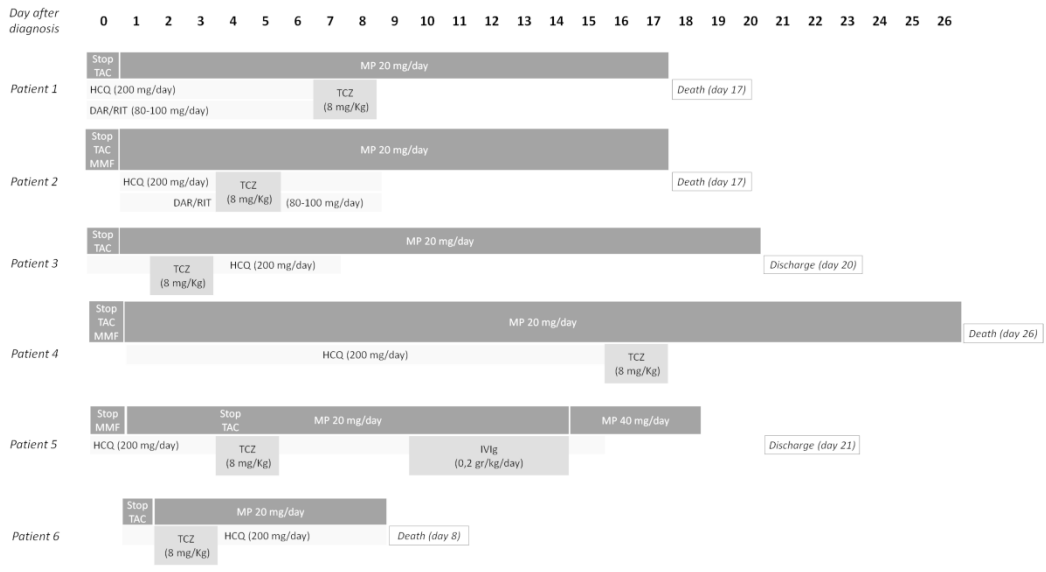
Author	Patients, n (studied population)	Criteria for tocilizumab adoption	Dose, mg (n)	Pulmonary outcome	Patients outcome at last f/up
Ferandez-Ruiz et al <sup>21</sup>	1 (1)	Progressive respiratory failure + increasing inflammatory parameters	600 mg iv (one dose)	Mild radiological improvement	Inpatient
Alberici et al <sup>22</sup>	6 (20)	Worsening of respiratory infection	8 mg/kg iv, max 800 mg (two doses, intervals 12-24 hours)	3/6 reduced oxygen requirement 2/6 radiological improvement	3/6 inpatient 2/6 death 1/6 discharged
Akalin et al <sup>19</sup>	2 (28)*	NA	NA	NA	NA (10/28 discharged)
Fontana et al <sup>12</sup>	1 (1)	PFTs deterioration + elevated IL-6	324 mg sc (one dose)	Recovery	Discharged
Montagud-Marrahi et al <sup>20</sup>	13 (26)*	NA	NA	NA	NA (21/26 discharged)
Pereira et al <sup>23</sup>	14 (90)**	Rapid pulmonary decompensation due to high and deleterious cytokine activity	400 mg sc or 8 mg/kg iv, max 800 mg (9/14 one dose,	NA	3/14 death 4/14 inpatient (ICU) 5/14 inpatient 2/14 discharged

			4/14 two doses, 1/14 three doses)		
--	--	--	--------------------------------------	--	--

iv: intravenous; sc: subcutaneous; NA: not available; ICU: intensive care unit

\*inpatient group

\*\*46/90 kidney tranplants



tid\_13348\_f1.tiff