

# Right phrenic nerve palsy following transcatheter radiofrequency current atrial fibrillation ablation: Case report

Journal of International Medical Research

2019, Vol. 47(7) 3438–3443



© The Author(s) 2019

Article reuse guidelines:

[sagepub.com/journals-permissions](http://sagepub.com/journals-permissions)

DOI: 10.1177/0300060519849267

[journals.sagepub.com/home/imr](http://journals.sagepub.com/home/imr)

**Gianmarco Abbadessa<sup>1</sup>, Luigi Lavorgna<sup>1</sup> ,**  
**Giovanni Cirillo<sup>1,2</sup>, Marinella Clerico<sup>3</sup>,**  
**Vincenzo Todisco<sup>1</sup>, Mario Cirillo<sup>4</sup>,**  
**Francesca Trojsi<sup>1</sup> ,** **Gioacchino Tedeschi<sup>1</sup> and**  
**Simona Bonavita<sup>1</sup>**

## Abstract

Phrenic nerve palsy (PNP) is a well-known complication of cardiac surgery or jugular/subclavian vein catheterization, presenting with cough, hiccups, dyspnoea/shortness of breath and, in some cases, ventilatory failure. Rarely, PNP is a complication of transcatheter radiofrequency ablation for atrial fibrillation. This report describes the case of a 72-year-old woman with a 2-year history of recurrent paroxysmal atrial fibrillation associated with occasional palpitations and shortness of breath who underwent routine transcatheter radiofrequency ablation. Three days after the procedure, the patient developed shortness of breath and progressive dyspnoea. Motor nerve conduction showed the absence of the right phrenic nerve compound motor action potential compared with the normal left side confirming the diagnosis of a right phrenic nerve palsy. This current case demonstrated the importance of undertaking an electrophysiological evaluation of phrenic nerve conduction after transcatheter radiofrequency ablation in patients presenting with palpitations and shortness of breath even if present a few days after the procedure.

<sup>1</sup>Department of Medical, Surgical, Neurological, Metabolic and Aging Sciences, I Division of Neurology and Neurophysiopathology, University of Campania Luigi Vanvitelli, Naples, Italy

<sup>2</sup>Laboratory of Human Anatomy and Morphology of Neural Networks, Department of Mental, Physical Health and Preventive Medicine, University of Campania Luigi Vanvitelli, Naples, Italy

<sup>3</sup>Department of Clinical and Biological Sciences, AOU San Luigi Gonzaga, Orbassano, Italy

<sup>4</sup>Division of Neuroradiology, University of Campania Luigi Vanvitelli, Naples, Italy

## Corresponding author:

Luigi Lavorgna, I Clinic of Neurology, University of Campania Luigi Vanvitelli, 2 Piazza Miraglia, 80138 Naples, Italy.

Email: [luigi.lavorgna@policliniconapoli.it](mailto:luigi.lavorgna@policliniconapoli.it)



## Keywords

Atrial fibrillation, radiofrequency ablation, phrenic nerve palsy

Date received: 17 January 2019; accepted: 17 April 2019

## Introduction

Phrenic nerve palsy (PNP) is a well-known complication of cardiac surgery or jugular/subclavian vein catheterization, presenting with cough, hiccups, dyspnoea/shortness of breath and, in some cases, ventilatory failure.<sup>1,2</sup> On rare occasions, PNP is a complication of transcatheter radiofrequency current atrial fibrillation ablation. This current report describes a case of PNP subsequent to transcatheter radiofrequency ablation for atrial fibrillation.

## Case report

In September 2017, a 72-year-old woman was referred to the cardiology unit of Casa di Cura Villa dei Fiori, Mugnano, Italy because of a 2-year history of recurrent paroxysmal atrial fibrillation associated with occasional palpitations and shortness of breath. She was on warfarin anticoagulation medication and no significant medical problems and structural heart disease were reported. Despite treatment with 100 g atenolol orally per day for 1 year, she experienced several pharmacological and electrical cardioversions and took the opportunity for a potentially curative approach with transcatheter radiofrequency ablation. The procedure was performed via the femoral route; 7-Fr catheters were used to map the left atrium and pulmonary veins. Energy applied was limited to a power of 20 W achieving a maximum temperature of 45°C. Radiofrequency applications lasted an average of 3–4 min per vein resulting in elimination of pulmonary vein action potentials. No phrenic nerve stimulation was

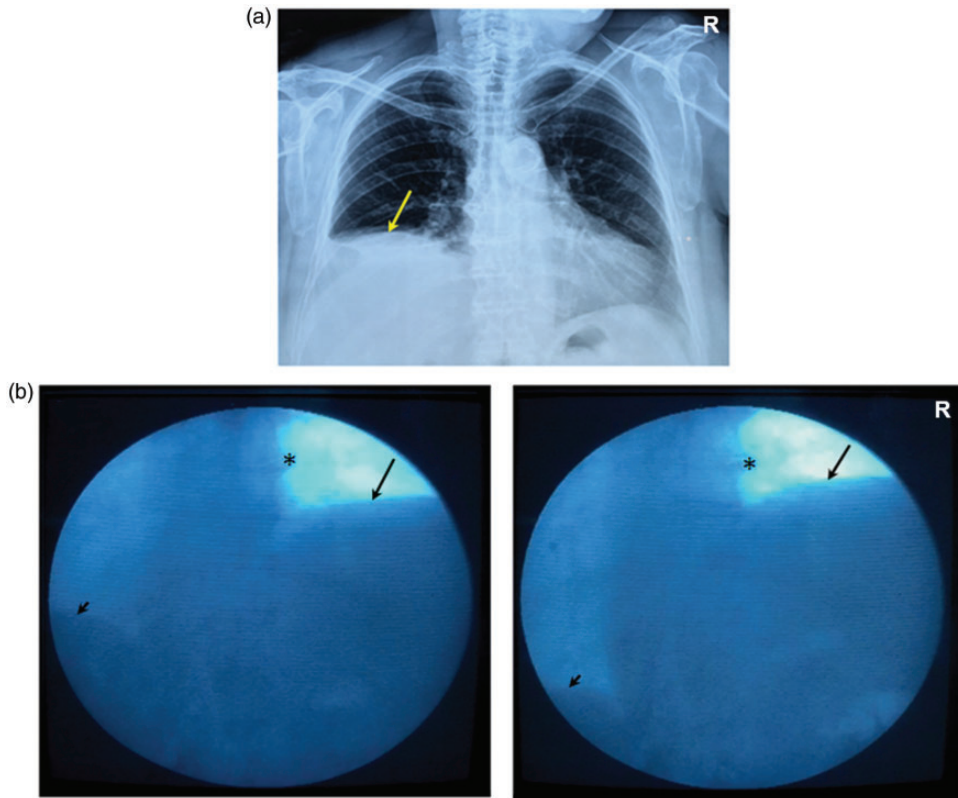
performed during ablation of the superior right pulmonary vein. During and immediately after the procedure, the patient presented with no symptoms.

Three days after the procedure, the patient developed shortness of breath and also progressive dyspnoea. Electrocardiograms and echocardiograms were well within normal limits, while the chest X-ray revealed an elevated right hemidiaphragm (Figure 1a).

Subsequently, the patient was referred to the I Division of Neurology and Neurophysiopathology, University of Campania Luigi Vanvitelli, Naples, Italy for neurological and neurophysiological assessments in February 2018. The neurological examination was of no particular relevance. The patient had no hiccups or cough. A fluoroscopic sniff test (i.e. diaphragm fluoroscopy), was performed during chest fluoroscopy, which demonstrated a lack of right hemidiaphragm movements during voluntary inspiration (Figure 1b). These findings suggested right phrenic nerve palsy. In addition, motor nerve conduction was examined and showed the absence of a right phrenic nerve compound motor action potential (CMAP) compared with the normal left side (Figure 2), confirming the diagnosis of right phrenic nerve palsy.

The patient did not require noninvasive mechanical ventilation. She experienced a spontaneous complete recovery within 2 months. Asymptomatic paralysis persisted at an 8-month follow-up visit.

Consent to publish this case report was received from the Ethics Committee of the University of Campania Luigi Vanvitelli, Naples, Italy. Verbal informed consent was obtained from the patient.

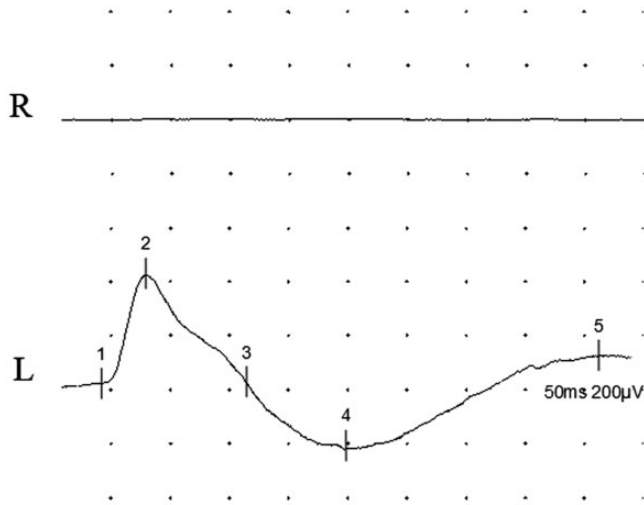


**Figure 1.** A 72-year-old woman with a 2-year history of recurrent paroxysmal atrial fibrillation associated with occasional palpitations and shortness of breath underwent routine transcatheter radiofrequency current atrial fibrillation ablation. Three days after the procedure, the patient developed shortness of breath and progressive dyspnoea. Chest radiography revealed an elevated right hemidiaphragm (yellow arrow) (A). A sniff test during chest fluoroscopy demonstrated a lack of right hemidiaphragm movements during voluntary inspiration (asterisk: T7–T8; long black arrow: right hemidiaphragm; short black arrow: left hemidiaphragm) (B). The colour version of this figure is available at: <http://imr.sagepub.com>.

## Discussion

Radiofrequency ablation is an effective tool in the management of symptomatic atrial fibrillation.<sup>3</sup> This procedure is more frequently associated with groin complications and pericardial effusion/cardiac tamponade, but it can cause right PNP due to the close proximity of the nerve to the right pulmonary veins and the right atrium.<sup>4</sup> PNP has been reported to be a rare complication of transcatheter

radiofrequency ablation. For example, a recent review reported only one case of PNP occurring during 2750 (0.04%) consecutive radiofrequency ablations for atrial fibrillation.<sup>5</sup> However, the use of a non-radiofrequency source of energy is unlikely to prevent this complication because phrenic nerve injury has been reported following ultrasound, laser and cryothermal ablation.<sup>6</sup> With the appearance of cryoballoon ablation, which is an effective tool for achieving pulmonary



**Figure 2.** A 72-year-old woman with a 2-year history of recurrent paroxysmal atrial fibrillation associated with occasional palpitations and shortness of breath underwent routine transcatheter radiofrequency current atrial fibrillation ablation. Three days after the procedure, the patient developed shortness of breath and progressive dyspnoea. Motor nerve conduction showed the absence of the right (R) phrenic nerve compound motor action potential compared with the normal left (L) side.

vein isolation, PNP has become more common with the rate in the range of 8–11% in some studies.<sup>7</sup>

The right phrenic nerve descends vertically from its origin and continues along the right anterolateral surface of the superior vena cava. Descending down the anterolateral wall of the superior vena cava, it approaches the superior cavo-atrial junction and follows in close proximity to the right-sided pulmonary veins. At this level, the distance between the right superior pulmonary vein and the right phrenic nerve is between 0.0 mm and 2.3 mm.<sup>8</sup> Therefore, the right phrenic nerve is particularly at risk when ablations are carried out in the superior vena cava and the right superior pulmonary vein.<sup>9</sup>

There is no reliable method of predicting phrenic nerve injury prior to the procedure. As reported previously, the only technique that predicts phrenic nerve injury is electromyography, which specifically records the phrenic nerve CMAP during ablation,

by means of two standard surface electrodes positioned across the diaphragm or by advancing a quadripolar catheter into the right hepatic vein during phrenic nerve pacing.<sup>10</sup>

The current patient developed symptoms 3 days after the ablation procedure and spontaneously recovered in 2 months. This clinical course was also described in a previous study of 18 patients who developed PNP after atrial fibrillation catheter ablation, in whom nine of the patients were diagnosed with PNP up to 3 days after the procedure.<sup>11</sup> The same study showed a significantly shorter recovery if the PNP diagnosis was made during the procedure as opposed to the diagnosis being made after the procedure: mean  $\pm$  SD recovery time of  $3 \pm 2$  months (median 1.5 months) versus  $7 \pm 5$  months (median 6 months) ( $P = 0.027$ ), respectively.<sup>11</sup>

Phrenic nerve injury can be diagnosed during a clinical examination and via a chest X-ray. Around 90% of unilateral

diaphragm palsy is diagnosed based on an elevated hemidiaphragm on routine chest X-rays.<sup>12</sup> The sniff test is a useful tool to diagnose PNP, as it shows paradoxical elevation of the paralyzed hemidiaphragm with inspiration, compared with the rapid descent of the normal hemidiaphragm.<sup>13</sup> The diagnosis should be confirmed with a phrenic nerve conduction study and diaphragm electromyography.<sup>14</sup>

In unilateral diaphragmatic paralysis, patients are usually asymptomatic, have a good prognosis and do not always need treatment. This is specifically true in the absence of underlying lung disease.<sup>15</sup> Symptomatic patients do not require treatment unless exercise limitation becomes significant or symptoms persist. If therapy is required, the first treatment option could be noninvasive mechanical ventilation. Another procedure often followed is the surgical plication of the affected hemidiaphragm.<sup>16</sup> As reported previously, chest physiotherapy led to a marked improvement in the functional outcome following post-cardiac surgery diaphragmatic palsy.<sup>17</sup>

In conclusion, this current case demonstrated the importance of undertaking an electrophysiological evaluation of phrenic nerve conduction after transcatheter radiofrequency ablation in patients presenting with palpitations and shortness of breath even if present a few days after the procedure.

#### Declaration of conflicting interest

The authors declare that there are no conflicts of interest.

#### Funding

This research received no specific grant from any funding agency in the public, commercial, or not-for-profit sectors.

#### ORCID iD

Luigi Lavorgna  <https://orcid.org/0000-0003-4625-4236>

Francesca Trojsi  <https://orcid.org/0000-0002-3790-8018>

#### References

1. Ahn EJ, Baek CW, Shin HY, et al. Phrenic nerve palsy after internal jugular venous catheter placement. *Korean J Anesthesiol* 2012; 63: 183–184.
2. Campbell AJ. Diaphragmatic Paralysis: A Critical Review of its Use as a Therapeutic Measure in Respiratory Disease: (Section of Medicine). *Proc R Soc Med* 1934; 27: 1555–1562.
3. Safaei N, Montazerghaem H, Azarfarin R, et al. Radiofrequency ablation for treatment of atrial fibrillation. *Bioimpacts* 2011; 1: 171–177.
4. Wongcharoen W, Lo LW and Chen SA. Collateral Damage from Catheter Ablation of Atrial Fibrillation Lessons Learnt in the Past Decade. *J Atr Fibrillation* 2013; 5: 831.
5. Voskoboinik A, Sparks PB, Morton JB, et al. Low rates of major complications for radiofrequency ablation of atrial fibrillation maintained over 14 years: a single centre experience of 2750 consecutive cases. *Heart Lung Circ* 2018; 27: 976–983.
6. Sacher F, Jais P, Stephenson K, et al. Phrenic nerve injury after catheter ablation of atrial fibrillation. *Indian Pacing Electrophysiol J* 2007; 7: 1–6.
7. Parikh V and Kowalski M. Comparison of phrenic nerve injury during atrial fibrillation ablation between different modalities, pathophysiology and management. *J Atr Fibrillation* 2015; 8: 1314.
8. Ramos-Villalobos LE, Colin Lizalde L, Márquez MF, et al. Postintervention dyspnea after radiofrequency catheter ablation: think of a phrenic nerve injury. *Case Rep Cardiol* 2017; 2017: 6418070.
9. Sanchez-Quintana D, Cabrera JA, Climent V, et al. How close are the phrenic nerves to cardiac structures? Implications for cardiac interventionalists. *J Cardiovasc Electrophysiol* 2005; 16: 309–313.
10. Kowalski M. Prevention of phrenic nerve palsy during cryoballoon ablation for atrial fibrillation. In: NY Chan (ed.) *The practice of catheter cryoablation for cardiac*

- arrhythmias*. Hoboken: Wiley Blackwell, 2014, pp.67–81.
11. Sacher F, Monahan KH, Thomas SP, et al. Phrenic nerve injury after atrial fibrillation catheter ablation: characterization and outcome in a multicenter study. *J Am Coll Cardiol* 2006; 47: 2498–2503.
  12. Chetta A, Rehman AK, Moxham J, et al. Chest radiography cannot predict diaphragm function. *Respir Med* 2005; 99: 39–44.
  13. Alexander C. Diaphragm movements and the diagnosis of diaphragmatic paralysis. *Clin Radiol* 1966; 17: 79–83.
  14. Dubé BP and Dres M. Diaphragm dysfunction: diagnostic approaches and management strategies. *J Clin Med* 2016; 5: E113.
  15. Piehler JM, Pairolero PC, Gracey DR, et al. Unexplained diaphragmatic paralysis: a harbinger of malignant disease? *J Thorac Cardiovasc Surg* 1982; 84: 861–864.
  16. Kuniyoshi Y, Yamashiro S, Miyagi K, et al. Diaphragmatic plication in adult patients with diaphragm paralysis after cardiac surgery. *Ann Thorac Cardiovasc Surg* 2004; 10: 160–166.
  17. Mehta Y, Vats M, Singh A, et al. Incidence and management of diaphragmatic palsy in patients after cardiac surgery. *Indian J Crit Care Med* 2008; 12: 91–95.