

# Choroidal Vascular Reactivity in Central Serous Chorioretinopathy

Felice Cardillo Piccolino,<sup>1</sup> Marco Lupidi,<sup>1-3</sup> Carlo Cagini,<sup>2</sup> Daniela Fruttini,<sup>4</sup> Massimo Nicolò,<sup>1,5</sup> Chiara Maria Eandi,<sup>1,6</sup> and Silvia Tito<sup>1</sup>

<sup>1</sup>Fondazione per la Macula Onlus, Di.N.O.G.Mi, University Eye Clinic, Università di Genova, Genova, Italy

<sup>2</sup>Department of Biomedical and Surgical Sciences, Section of Ophthalmology, University of Perugia, S. Maria della Misericordia Hospital, Perugia, Italy

<sup>3</sup>Centre de l'Odéon, Paris, France

<sup>4</sup>Department of Internal Medicine, University of Perugia, S. Maria della Misericordia Hospital, Perugia, Italy

<sup>5</sup>Clinica Oculistica Di.N.O.G.Mi, Università di Genova, Ospedale Policlinico San Martino, Genova, Italy

<sup>6</sup>Department of Surgical Sciences, Eye Clinic, University of Torino, Torino, Italy

Correspondence: Felice Cardillo Piccolino, Fondazione per la Macula Onlus, University Eye Clinic, Viale Benedetto XV 5, Genova 16132, Italy;

felice.cardillopiccolino@gmail.com.

Submitted: January 31, 2018

Accepted: July 7, 2018

Citation: Cardillo Piccolino F, Lupidi M, Cagini C, et al. Choroidal vascular reactivity in central serous chorioretinopathy. *Invest Ophthalmol Vis Sci*. 2018;59:3897-3905. <https://doi.org/10.1167/iovs.18-23995>

**PURPOSE.** To investigate by optical coherence tomography angiography (OCT-A) the choroidal vascular response to experimentally increased blood pressure in patients with central serous chorioretinopathy (CSCR).

**METHODS.** For this multicenter, observational, case-control study, we enrolled 35 patients with an established diagnose of CSCR and 25 age-matched healthy controls. All subjects underwent a handgrip isometric exercise to obtain elevation of blood pressure (BP). In the resting phase and during the physical effort, macular OCT-angiograms were acquired. Systemic hemodynamic data were recorded at baseline and during stress conditions using an electronic sphygmomanometer. The analysis of vascular density (VD) of the choriocapillaris (CC) was performed on OCT-angiograms. The results obtained in CSCR patients, both at baseline and during the stress test, were compared with those of healthy subjects.

**RESULTS.** Baseline and under stress values of systolic BP, diastolic BP, and mean arterial pressure were significantly higher ( $P < 0.05$ ) in CSCR patients compared to controls, reaching values in the range of hypertension during the exercise. Baseline VD values of the CC were significantly lower ( $P < 0.05$ ) in CSCR cases compared to healthy subjects. We noticed a significant increase ( $P < 0.05$ ) in these values under stress condition in CSCR patients and not in controls.

**CONCLUSIONS.** The present study suggests that choroidal blood flow is dysregulated in CSCR. During physical stress, CSCR patients easily reach critical values of BP that are not dampened by compensatory mechanisms in the choroidal vessels, as it happens in healthy subjects. The CC in CSCR could be particularly vulnerable to variations of systemic hemodynamics.

**Keywords:** OCT-Angiography, central serous chorioretinopathy, choroid, blood flow, choriocapillaris

Central serous chorioretinopathy (CSCR) is a chorioretinal disease characterized by an idiopathic neurosensory retinal detachment at the posterior pole, often associated with focal retinal pigment epithelium (RPE) detachments.<sup>1,2</sup> It is usually a self-limiting, benign disorder; however, it can become chronic and result in a permanent visual deterioration due to foveal atrophy.<sup>3-7</sup>

Choroidal vascular hyperpermeability and choroidal thickening—revealed by indocyanine green angiography (ICGA) and optical coherence tomography (OCT), respectively—suggest that changes in the choroid may have a key role in the pathophysiology of CSCR.<sup>8-10</sup> In addition to dye leakage from the inner choroid, ICGA shows a series of findings (including vascular filling delays, venous congestion, and shifting of the dye in the extravascular space) that testify to the presence of an abnormal choroidal blood flow in patients affected by CSCR.<sup>11-13</sup> Within the thickened choroid, enhanced depth imaging OCT and swept-source OCT reveal dilated choroidal

vessels and other structural alterations of the choroidal architecture that further reinforce the concept of a link between disturbances of choroidal circulation and CSCR.<sup>14,15</sup> High levels of circulating catecholamines, endogenous hypercortisolism, and exogenous corticosteroid administration have been associated with an increased risk of CSCR.<sup>16-18</sup> The mechanisms through which they determine a functional dysregulation of the choroidal vasculature are not yet clearly defined.

Blood flow in the choroid is regulated by the autonomic nervous system and by autoregulatory processes that seem to be very efficient in this ocular vascular district.<sup>19</sup>

Several studies using laser doppler flowmetry have demonstrated a rapid vascular regulation and adaptation of the human choroid during dynamic changes of the ocular perfusion pressure (OPP), obtained by experimental changes of the intraocular pressure (IOP) or blood pressure (BP).<sup>20-22</sup> Tittl et al.<sup>23</sup> observed that the subfoveal choroidal blood flow



significantly increases in patients with a history of chronic CSCR compared with control subjects during an increase of the arterial BP provoked by an isometric exercise. The authors suggested that a choroidal vascular dysregulation may have a role in the pathogenesis of CSCR or may be a consequence of the disease itself.<sup>23</sup> This local choroidal hemodynamic impairment in CSCR needs to be further characterized. The impact of BP changes on the choroidal perfusion should be also investigated, given that hypertension is often associated with CSCR.<sup>24,25</sup> Moreover, a type A personality and sympathetic hyperactivity frequently characterize these patients, easily leading to changes in systemic hemodynamics and OPP.<sup>26,27</sup>

New OCT technologies have substantially improved our capability in qualitatively and quantitatively evaluating the choroidal vasculature and perfusion.<sup>28,29</sup> OCT-Angiography (OCT-A), a recent label-free imaging modality that uses the blood cells motion as contrast, is able to provide information on the blood flow in the chorioretinal microvasculature.<sup>30,31</sup> In the present study, we used OCT-A to examine the choroidal vascular response of patients with CSCR to an abrupt increase of BP induced by isometric exercise. With a real-time evaluation of the behavior of blood flow in the choriocapillaris (CC), we looked for further confirmation that a dysfunctional choroidal vascular regulation may characterize patients with CSCR.

## METHODS

### Study Design

This case-control study was conducted at the Fondazione per la Macula Onlus (Genova, Italy) and the Eye Clinic at S. Maria Della Misericordia Hospital (Perugia, Italy).

Study patients and control subjects were examined by OCT-A before and during isometric exercise with a handgrip test (HGT) to evaluate the impact of an induced increase of BP and OPP on the choroidal vascular hemodynamics. The study was performed in accordance with the Declaration of Helsinki after approval by the Genova and Perugia Institutional Ethics Committees (IEC). Fully informed written consent was obtained from all the study patients prior to the full ophthalmologic examination and the HGT.

### Study Population

Patients with a documented history of CSCR and age-matched healthy controls were consecutively enrolled between November 2016 and November 2017. The initial diagnosis of CSCR was made on the basis of the presence of one or more leaking points on FA, choroidal vascular hyperpermeability on ICGA, structural OCT findings including subretinal fluid, serous pigmented epithelium detachments (PEDs), and choroidal thickening. Not included in the study were eyes with any amount of subretinal fluid accumulation, fibrovascular PEDs, or any other retinal change in the central macula that could influence OCT-A imaging of the examined choroid. Patients showing serous retinal detachment outside the OCT-A scanning area at the time of the examination were considered eligible for the study. The CSCR cohort was then divided into two different subgroups: active (A) or quiescent (Q) disease based on the presence or absence of extramacular subretinal fluid on structural-OCT scans. In case of bilateral history of CSCR, with both eyes eligible for the study, the study eye was randomly selected. CSCR patients with systemic hypertension (defined as systolic BP higher than 150 mm Hg or diastolic BP higher than 90 mm Hg at baseline) were not included in the study for safety reasons. In addition, subjects were excluded if

they had refractive error of 3 diopters or more, peripapillary choroidal dystrophy and staphyloma, established diagnosis of glaucoma, previous ocular surgery or laser photocoagulation, photodynamic therapy (PDT) in the previous 12 months and, in any case, not followed by reactivation of the disease, systemic steroidal therapy in the previous 6 months, or any evidence of eye disease that might interfere with the purpose of the study. Eyes with poor quality images on OCT-A (quality index lower than 40) due to poor fixation or media opacities that could confound the quantitative assessment were also excluded. Healthy subjects with best-corrected visual acuity (BCVA) of 20/20 or better and no history or clinical evidence of retinal disease or relevant systemic illness were included in the study as a control group. The entire study population underwent BCVA testing, slit-lamp biomicroscopy, intraocular pressure (IOP) baseline measurement, fundus evaluation, structural OCT and OCT-A (at baseline and during the isometric exercise).

### Experimental Protocol

Subjects were asked not to ingest caffeine or alcohol in the 12 hours before the examination. After steady-state conditions were reached, three BP measurements spaced 5 minutes apart were taken using a portable electronic sphygmomanometer (Omron Model M6; Omron Europe B.V., Hoofddorp, The Netherlands). The automated oscillometric approach allowed a range of measurements between 0 and 300 mm Hg of pressure and between 40 and 200 heartbeats. The test accuracy was about 3 mm Hg (armlet) and 5% (heartbeat). Insufflation was automatic and the subject's BP adapted, while an electronic controlled valve effected disinflation. The clinical accuracy was in accordance with the AAMISP10 auscultatory standard: 5 mm Hg of systematic bias and 8 mm Hg of Standard Deviation (SD). The sphygmomanometer wrist was set at the level of the heart to avoid potential positioning bias.

After pupil dilation with 1% tropicamide (Visumidriatic, Visufarma SpA, Rome, Italy) each patient underwent a baseline OCT-A examination. This OCT-angiogram was set as reference scan. The HGT was then executed using a Jamar hand dynamometer (Lafayette Instruments, Lafayette, IN, USA) on the dominant side, based on the American Society of Hand Therapist recommendation. The patients were seated in a comfortable position with elbow flexed at 90°, shoulder adducted, forearm and wrist in a neutral position.<sup>32</sup> They were instructed to squeeze the handle maximally and asked to avoid undue pain. The mean of three measurements was documented and a value equal to 30% of the maximal isometric handgrip strength was computed. Each enrolled subject performed the isometric handgrip exercise for 2.5 to 3 minutes maintaining the 30% of the maximal strength value. At 1.5 minutes from the beginning of the exercise, an OCT-A was started in the examined eye while systemic BP and heart rate were measured. This second OCT-A was acquired as a follow-up mode scan to maximize the superimposability of the two examinations. At the end of the OCT-A, the HGT was interrupted, and recovery of BP to baseline was checked in the following minutes. Systolic BP (SBP), diastolic BP (DBP), mean arterial pressure (MAP), and heart rate (HR) were recorded. OPP was also calculated as  $2/3 \text{ MAP} - \text{IOP}$ .<sup>33</sup>

### OCT-Angiography System Setup

The Spectralis OCT2 (Heidelberg Engineering GmbH, Heidelberg, Germany) was the 85 kHz Spectral Domain OCT device used to obtain OCT-angiograms. Detailed features of the OCT-A system have been previously described.<sup>34</sup> A high resolution OCT-A volume scan of  $15 \times 10^\circ$  (approximately  $4.5 \times 3 \text{ mm}$ )

centered in foveal area was acquired in each enrolled subject. The volume scan was made by 261 B-scans, and the automated averaging process was set at 35 frames per scan (distance between two consecutive B-scans of 11  $\mu\text{m}$ ). The OCT-A software (Heyex Software Version 1.9.201.0; Heidelberg Engineering) allowed visualization of angiograms both in C-scan (“en-face”) or B-scan projections. For our purpose only, C-scans were assessed. A maximum intensity projection algorithm was chosen to highlight the highest value voxel along a line of sight. In this way, all the structures showing a decorrelation signal and, when actively perfused, were easily detected.

The built-in software provides an automated segmentation algorithm for the retinal and choroidal vascular layers. Automated segmentation strategies were based on the capability of the device to distinguish different levels of reflectivity between contiguous retinal and choroidal layers on structural OCT. In the current study, we focused our investigation on the CC. En-face angiograms of this layer were taken immediately beneath the Bruch’s membrane (BM) with a 25  $\mu\text{m}$ -thick section whose boundaries were aligned on the BM’s profile. Potential fails in segmentation strategies were carefully checked on the B-scan projections. If segmentation errors occurred, cases were excluded from the study.

A quantitative analysis of OCT-angiograms was performed to detect flow, flow-void areas, and blood flow changes at the level of the CC. The first step of this analysis was thresholding the image with the Phansalkar method (radius of 15 pixels), a specifically designed automated local thresholding algorithm for low-contrast images.<sup>35</sup> This process was obtained by importing OCT-angiograms in FIJI, an available for free imaging software (expanded version of ImageJ, Version 1.51h; Wayne Rasband, National Institute of Health, Bethesda, MD, USA). The thresholded images were then analyzed with the Analyze Particles FIJI tool, which measured and computed all areas greater or equal to 1 pixel where there was flow (decorrelated pixels) information.<sup>36</sup> The CC vascular flow density (VD) was then computed as the ratio (expressed as percentage) between the number of decorrelated pixels and the total number of pixels composing the image. Quantitative data were obtained from a  $4 \times 3$  mm area (original image  $4.5 \times 3$  mm area,  $15^\circ \times 10^\circ$ ) to minimize the effects of artifacts at the edge of the C-scan. Each OCT-angiogram had a resolution of  $784 \times 520$  pixels.

A qualitative assessment of the CC on baseline and HGT OCT-angiograms was also performed to localize the perfusion changes. The potential stress-induced changes were better visualized with a subtraction protocol in the image calculator tool of FIJI.

The two OCT-A imaging sessions (baseline and under stress test) were performed by the same experienced operator (ML), within a single visit. All scans were independently reviewed by two investigators (FCP and ML) to ensure correct segmentation and sufficient image quality for post hoc analysis.

### Statistical Analysis

Quantitative variables were described by their mean and standard deviation (SD). The absolute and the relative (ratio of absolute difference and baseline value) differences between baseline and under stress quantitative data were also reported. The Shapiro-Wilk test was used to check whether the sample came from a normally distributed population. Depending on the statistical distribution, comparisons of means of independent variables were performed using the Student’s *t*-test or the Mann-Whitney test. The paired *t*-test or Wilcoxon-Mann-Whitney test was used to compare paired data. The linear regression analysis and the Pearson’s “*r*” or Spearman’s rank

correlation coefficient were used to measure the statistical dependence of quantitative variables. A *P* value of  $<0.05$  was considered as statistically significant. All statistical analyses were performed using the SAS System for Windows (release 9.4; SAS Institute, Inc., Cary, NC, USA).

## RESULTS

### Study Population

Fifty-seven eyes of 37 patients with an established diagnosis of CSCR were consecutively evaluated in the two recruitment centers. Fifteen eyes (26.3%) were excluded due to the presence of subretinal fluid accumulation or fibrovascular PEDs within the OCT-A scanning area, 2 eyes (3.5%) due to poor image quality, 3 eyes (5.3%) due to high refractive error, and 2 eyes (3.5%) due to baseline BP values in the range of hypertension. Thirty-five eyes of 35 patients matching the inclusion criteria, and 25 eyes of 25 age-matched healthy subjects were enrolled in the study. The mean age of CSCR patients was  $48.4 \pm 7.6$  years (range, 33–65 years) and the mean age for controls was  $42.9 \pm 8.3$  years (range, 26–59 years). Two females were in the CSCR group (5.7%), and in the control group (8%). The ethnicity was Caucasian in both samples. Mean IOP values were  $13.5 \pm 1.8$  mm Hg in the CSCR group and  $14.6 \pm 1.9$  mm Hg in the control group. Considering the CSCR patients, 14 had active disease and 21 had a quiescent condition. Fourteen eyes (40%) had history of PDT followed by reactivation of the disease, 20 (57%) had previously undergone a systemic steroidal therapy, and 6 (17%) were under treatment for systemic hypertension. None of the control subjects reported any actual or previous systemic therapy. No adverse events were reported during the entire patient assessment. The simultaneous OCT-A examination and the isometric handgrip exercise were well tolerated by all participating subjects.

### Hemodynamic Data

The mean and standard deviations of the SBP, DBP, MAP, and OPP both at baseline and during the isometric exercise are shown in Table 1. A statistically significant increase ( $P < 0.05$ ) between baseline and under-stress values was observed both in CSCR and healthy subjects. Baseline and under-stress data were significantly higher ( $P < 0.05$ ) in CSCR patients compared with controls. The absolute and relative differences ( $\Delta$  and  $\Delta r$ ) between baseline and under-stress data of CSCR did not significantly differ from those of healthy controls (Table 2).

### Quantitative Imaging Analysis

Results of the quantitative assessment of the CC are shown in Table 3. A statistically significant increase ( $P < 0.05$ ) in terms of VD was noticed in CSCR patients between baseline and under-stress values. The baseline VD data were significantly lower ( $P < 0.05$ ) in CSCR compared to healthy controls. No statistically significant differences were reported among baseline and under-stress VD values in the control group and between the two groups when considering under-stress data. Absolute and relative VD variations ( $\Delta\text{VD}$  CC) between baseline and under-stress data were significantly higher in CSCR patients than in healthy subjects (Table 4). A significantly different response ( $P < 0.05$ ) of CC-VD in CSCR patients compared to controls was also detected in a post-hoc analysis where we considered a CSCR subgroup (20 patients) with a baseline CC-VD value homogeneous with that of healthy subjects (CC-VD  $> 83\%$ ). Furthermore, a linear regression analysis without intercepts was computed for both groups to

TABLE 1. Hemodynamic Findings in CSCR Patients and Healthy Controls at Baseline and During the Isometric Handgrip Exercise

	CSCR Patients			Healthy Controls			P Value CSCR vs. Controls Baseline	P Value CSCR vs. Controls Under-Stress
	Baseline, Mean ± SD	Under-Stress, Mean ± SD	P Value Paired Data	Baseline, Mean ± SD	Under-Stress, Mean ± SD	P Value Paired Data		
SBP	126.94 ± 11.62	165.57 ± 16.41	<0.0001	112.20 ± 7.70	143.44 ± 10.95	<0.0001	<0.0001	<0.0001
DBP	83.4 ± 7.91	105.60 ± 10.68	<0.0001	75.12 ± 5.35	97.24 ± 7.12	<0.0001	<0.0001	0.0059
HR	70.29 ± 8.61	87.94 ± 11.15	<0.0001	69.68 ± 6.79	92.08 ± 10.99	<0.0001	0.8929	0.1011
MAP	97.88 ± 8.60	125.59 ± 11.46	<0.0001	87.48 ± 5.89	112.64 ± 7.71	<0.0001	<0.0001	<0.0001
OPP	56.24 ± 5.92	74.72 ± 7.53	<0.0001	48.59 ± 4.69	65.36 ± 5.38	<0.0001	<0.0001	<0.0001

give us a more accurate modeling of the phenomenon (Fig. 1). The slopes for patients with CSCR and controls were significantly different ( $P < 0.05$ ) both for the entire samples and for the subgroups with CC-VD  $> 83\%$ .

No other statistically significant correlations between hemodynamic changes and variations of OCTA quantitative parameters were observed. Moreover, no statistically significant correlations were appreciated between corticosteroid therapies or previous PDT and hemodynamic or OCTA quantitative findings. By considering the stratification of the CSCR group for the presence (A) or absence (Q) of subretinal fluid, a positive linear correlation was reported between OPP and CC-VD variations among baseline and under-stress data only in the Q sub-group. The absolute and relative variations of MAP and OPP were significantly higher ( $P < 0.05$ ) in Q cases compared to A cases. No significant differences in terms of age and sex were observed between A and Q cases. Instead a statistically significant difference ( $P = 0.002$ ) was noted for disease duration (77.3 months versus 122.2 months).

### Qualitative Imaging Analysis

A complete review of the structural B-scans composing each single OCTA volume scan was performed by two experienced examiners (FCP and ML). None of the analyzed cases showed shadowgraphic artifacts that may have negatively influenced the CC vascular flow assessment. At baseline, a less homogeneous pattern of the CC with prominent zones of reduced flow signal characterized CSCR cases compared with controls. In the same cases a certain rehash or increase of the CC flow signals was seen in the OCT-angiograms taken during HGT (Fig. 2). Large areas of flow voids visible in CSCR patient at baseline appeared reduced. The differential images showed that the new signals of blood flow were distributed diffusely in the examined area of CC. In the control group, the same images of the CC revealed few and widely spread new signals of decorrelation indicating a minimal or virtually absent increase of blood flow.

### DISCUSSION

In the present study, we used OCTA to investigate the choroidal vascular response to an abrupt elevation of the systemic BP in patients with CSCR. An increase of blood flow in the CC was obtained in these patients but not in a control group of healthy subjects. Our findings suggest that the physiological mechanisms controlling the homeostasis of choroidal circulation during hemodynamic stress may be dysregulated in CSCR.

Blood flow is driven in the choroidal vessels by the OPP, a positive pressure depending on the systemic BP and the IOP that opposes it. We experimentally increased the systemic BP, and consequently the OPP, through an isometric handgrip exercise that produces active stimulation of the sympathetic system through activation of mechanoreceptors during the increased muscle tension.<sup>37-39</sup> During this stress condition, there was a significant increase of SBP, DBP, MAP, HR, and OPP in both groups of the study. The baseline values of SBP and DBP were significantly higher in patients with CSCR; during the exercise, they reached values definitely in the range of hypertension (mean SBP = 165.57 mm Hg, mean DBP = 105.60 mm Hg). The under-stress values of BP in controls were significantly lower (mean SBP = 143.44 mm Hg, mean DBP = 97.24 mm Hg). Hypertension is already considered to be a risk factor for CSCR.<sup>24,25</sup> Our findings show that also in absence of a basal hypertension patients with CSCR, more than healthy subjects, may reach frank hypertensive values in occasion of physical stress. A dysfunction of the autonomic nervous system is widely recognized in people affected by CSCR.<sup>27</sup> Compared to healthy subjects, CSCR patients have a higher sympathetic tone, associated with type A personality, easy emotional stress, and high levels of catecholamines in the blood.<sup>16,26</sup> Psychological stress and increased BP are found strictly linked in people with sympathetic hyperactivity.<sup>40</sup> Our findings contribute to recognize a hemodynamic instability in patients with CSCR for whom physical efforts, as well as emotional stress, may produce significant BP variations and episodic hypertension. In addition to a high sympathetic activity, patients with

TABLE 2. Absolute and Relative Differences Between Baseline and Under-Stress Values in Terms of Hemodynamic Findings in CSCR Patients and Healthy Controls

	CSCR Patients		Healthy Controls		P Value CSCR vs. Controls (Δ)	P Value CSCR vs. Controls (Δr)
	Absolute Difference (Δ), Mean ± SD	Relative Difference (Δr), Mean ± SD	Absolute Difference (Δ), Mean ± SD	Relative Difference (Δr), Mean ± SD		
SBP	38.63 ± 15.28	31.0% ± 13.3%	31.24 ± 9.21	28.0% ± 8.3%	0.0541	0.3880
DBP	22.26 ± 8.94	27.2% ± 11.7%	22.12 ± 6.00	29.7% ± 8.4%	0.7354	0.2749
HR	17.66 ± 11.61	26.3% ± 17.9%	22.40 ± 9.59	32.5% ± 14.0%	0.0733	0.0795
MAP	27.71 ± 10.43	28.8% ± 11.8%	25.16 ± 6.57	29.0% ± 7.8%	0.4903	0.7997
MOPP	18.48 ± 6.95	33.6% ± 14.3%	16.77 ± 4.38	35.0% ± 9.8%	0.4700	0.5411

**TABLE 3.** Quantitative OCT-Angiography Assessment of Choriocapillaris Vascular Density in CSCR Patients and Healthy Controls at Baseline and During the Isometric Handgrip Exercise

	CSCR Patients			Healthy Controls			<i>P</i> Value CSCR vs. Controls Baseline	<i>P</i> Value CSCR vs. Controls Under-Stress
	Baseline, Mean ± SD	Under-Stress, Mean ± SD	<i>P</i> Value Paired Data	Baseline, Mean ± SD	Under-Stress, Mean ± SD	<i>P</i> Value Paired Data		
CC vascular density	82.7% ± 5.2%	85.9% ± 3.7%	<0.0001	86.9% ± 2.5%	86.8% ± 2.5%	0.6584	0.0006	0.3880

CSCR seem to have a reduced sympathetic reactivity. Tewari et al.,<sup>41</sup> by evaluating their systemic hemodynamic changes during various stressor stimuli, including HGT, reported a low response of the DBP, considered to be a sign of poor sympathetic reactivity. In accordance with these findings, we observed a trend toward a lower percent-increase of DBP in our study patients during the stress test. However, to characterize in detail the autonomic cardiovascular reaction to a stress condition in patients with CSCR is beyond the scope of the present study. Our aim was rather to investigate the end-organ (choroidal) response to the sympathetic stimulation in these patients.

The increased BP consequent to emotional and physical stress situations tends to produce peripheral vascular hyperperfusion that is prevented in normal subjects by vasoconstriction induced by sympathetic stimulation and, if present, by local autoregulatory systems. A series of studies show that choroidal vasculature has intrinsic control mechanisms able to adjust the blood flow reaching the CC when OPP changes.<sup>20-22</sup> Data by Tittl et al.,<sup>23</sup> using the squatting isometric test to increase BP and OPP, and laser doppler flowmetry to measure the CC blood flow, indicate that this regulatory capacity of the choroid fails in patients with CSCR. Using the HGT to produce a hemodynamic stress and quantitative OCT-A to evaluate changes in the CC blood flow, we obtained results leading to the same conclusion, even if several differences between the two studies must be underlined. While the Tittl study<sup>23</sup> concerned the CC strictly corresponding to the foveal avascular zone, our OCT-A analysis extended the evaluation to a larger area of the macular CC (4 × 3 mm), showing the presence of a wide choroidal dysregulation. Moreover, our OCT-A acquisition was obtained during the actual physical effort, whereas in the Tittl report, the laser doppler flowmetry was obtained soon after the isometric exercise. They observed that choroidal blood flow reached a twofold increase in CSCR patients compared to controls.<sup>23</sup> In our study, a mean of 3.2% (4% in terms of relative difference) increase (*P* < 0.05) of CC-VD was detected in CSCR patients, against a non-significant change of CC-VD in controls. The percent of variations of CC blood flow in the two studies are not comparable since they refer to different vascular indicators of blood flow—albeit both methods evaluate changes of blood cells motion in a vascular tissue. With laser doppler flowmetry changes of the CC blood flow velocity were measured with an arbitrary scale. With the OCT-A we used the CC-VD values as indicators of choroidal

blood flow in the examined area. We quantified the percent increase of detectable perfused microvascular network as consequence of increased blood flow velocity. Some areas of non-detectable CC blood flow at baseline in CSCR patients, showed decorrelated signals during the experimentally induced elevation of the OPP, indicating an increased perfusion. This change should not happen in a functionally normal choroid, where a reactive arteriolar vasoconstriction in the Sattler and Haller layers would protect the CC against overperfusion when BP suddenly increases.<sup>20-24</sup> The virtually stable values of CC-VD in the control group when OPP increased confirm the presence of choroidal regulatory mechanisms in healthy subjects. In terms of increase of CC-VD and ratio between baseline and under-stress VD values, the significant difference between controls and a subset of CSCR patients (CC-VD >83%) confirmed the abnormal vascular response in CSCR. Given that perfusion density of the CC necessarily cannot increase beyond a certain threshold, our measurements may be affected by a ceiling effect. Nevertheless, a different behavior in vascular changes between the two groups is evident when comparing the slopes of linear regression analysis without intercepts. These findings are also compatible with a dysregulation in CSCR patients that prevents the CC from reaching the same perfusion observed in normal subjects at rest.

By comparing the effects of the stress test on subgroups for active or inactive CSCR, we observed that variations of MAP and OPP were significantly higher in the latter condition. Moreover, only inactive cases had a positive linear correlation between OPP and CC-VD variations, that should reflect a more severe impairment of choroidal blood flow regulation.<sup>42</sup> The two groups (A and Q) were homogeneous for age and sex, while disease duration was significantly longer in the inactive group. In these patients, the long-standing disease is consistent with a more advanced dysfunction of choroidal circulation and more subjection to hemodynamic variations.

The CC imaged by OCT-A usually shows areas of impaired flow signal whose extension increases with age.<sup>43</sup> “Low-flow signals,” “flow rarefaction areas,” and “flow-voids” at the CC layer on OCT-angiograms have been recently described in CSCR.<sup>44,45</sup> Our OCT angiographic findings at baseline are consistent with the observations of these studies, suggesting slow blood flow or stasis in some districts of the CC in CSCR patients. With OCT-A, Chan et al.<sup>46</sup> conversely observed high signal intensity and dilated CC vessels in most eyes with

**TABLE 4.** Absolute and Relative Differences Between Baseline and Under-Stress Values in Terms of Choriocapillaris Vascular Density in CSCR Patients and Healthy Controls

	CSCR Patients		Healthy Controls		<i>P</i> Value CSCR vs. Controls ± (Δ)	<i>P</i> Value CSCR vs. Controls ± (Δr)
	Absolute Difference (Δ), Mean ± SD	Relative Difference (Δr), Mean ± SD	Absolute Difference (Δ), Mean ± SD	Relative Difference (Δr), Mean ± SD		
CC vascular density	0.03 ± 0.03	4.0% ± 3.6%	0.00 ± 0.01	−0.1% ± 0.7%	<0.0001	<0.0001

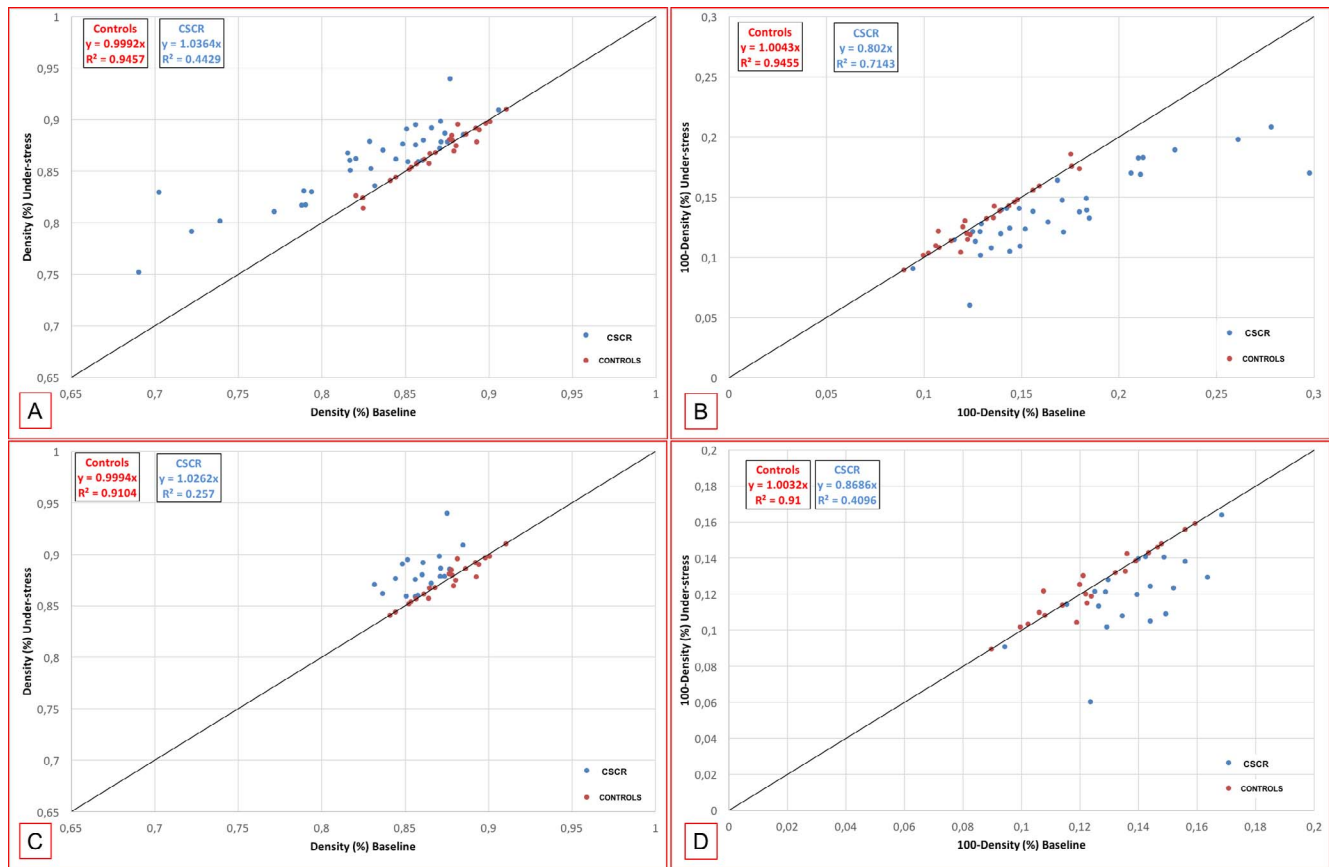


FIGURE 1. (A–D) relationship between baseline (x-axis) and under-stress (y-axis) vascular density (VD) values and its inverse (100-VD) in CSCR patients and healthy controls. (A, B) VD values of CSCR patients are referred to the entire sample. (C, D) VD values of CSCR patients are referred to a baseline VD comparable with controls (CC-VD >83%).

clinically diagnosed CSCR; however, the images of their cases also showed flow void areas in the CC. Ultimately, a blood flow impairment that could be segmentary and different in various districts seems to characterize the CC in CSCR.

Previous studies have investigated the choroidal response to stress tests in healthy subjects and in CSCR patients by measuring the choroidal thickness with Spectral Domain OCT and enhanced depth imaging.<sup>47,48</sup> Alwassia et al.<sup>47</sup> did not obtain any significant change in choroidal thickness during an acute increase of systolic BP in healthy subjects. Roybal et al.<sup>48</sup> observed an increase of choroidal thickness as a response to increased BP in patients with CSCR but not in healthy controls. These observations converge with our findings, supporting the hypothesis of a compromised regulatory mechanism of choroidal blood flow in CSCR.

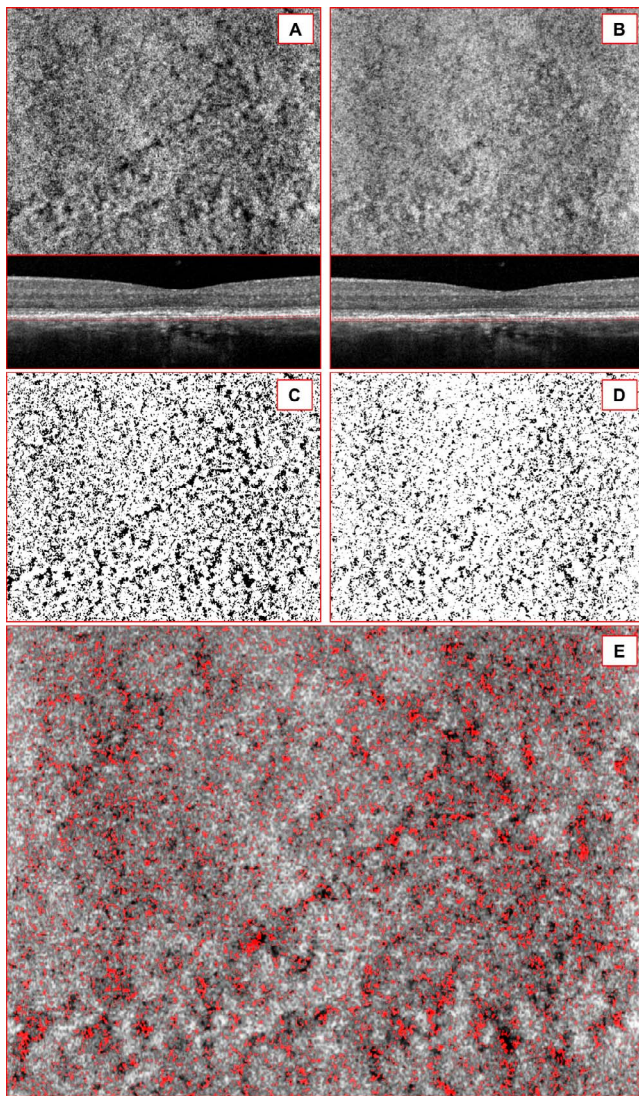
It has been hypothesized that in patients with CSCR, psychological stress and abnormal sympathetic activity may interfere with choroidal blood flow through a local neural dysregulation or by inducing dysfunction of the endothelial related autoregulation.<sup>24</sup> A failure of myogenic regulatory mechanisms could be also involved since they seem to have a major role in the instantaneous vascular response to BP changes.<sup>37</sup> In fact, only a prompt compensatory choroidal reaction can explain insignificant blood flow changes detected in the CC of our healthy subjects during physical effort.

Activities involving isometric muscle stress, such as the HGT used in the present study, are performed daily by people in the age range in which CSCR usually manifests itself. We can speculate that the hemodynamic consequences of these activities, when repetitive and prolonged, may not be

negligible in patients with CSCR. For these patients, the impact of sustained isometric efforts on the circulatory system and organ hemodynamics could be accentuated.<sup>49</sup> Furthermore, tendency to BP variability and episodic hypertension seems to have worse cardiovascular consequences and end-organ damage than does stable hypertension.<sup>50</sup> Accordingly, the choroidal vascular system could suffer from continuous changes of the systemic BP and OPP in absence of the corresponding adjustments of blood flow by well-functioning regulatory mechanisms.

Our observations suggest consideration of a pathological model of CSCR where various risk factors for this disease may have the common denominator of a significant impact on the systemic or local choroidal hemodynamics. In this model, an increased BP and OPP would not find adequate mechanisms of vascular response and organ protection in the choroid. That said, the hemodynamic changes could produce, in the long run, a progressive choroidal vascular dysregulation. Low values of IOP, a trend observed in CSCR cases of the present study, have been already called in cause by one of us (FCP) as a favoring factor for active CSCR.<sup>51</sup> In a hemodynamic pathogenetic model of CSCR, low IOP may have a role by contributing to elevation of OPP, as well as by increasing the transmural pressure that drives fluid out of the CC.

A sizable amount of literature has associated the use of corticosteroids and endogenous hypercortisolism with CSCR.<sup>17,18</sup> How corticosteroids induce exudative manifestation or exacerbation of the disease is still unclear. Recently, Daruich et al., supported by therapeutic results using antagonists of mineralocorticoid receptors, hypothesized a key role of over-



**FIGURE 2.** (A–E) “En-face” OCT-Angiography in a CSCR case. OCT-angiogram of the choriocapillaris (CC) at baseline and during the handgrip test (HGT). (A, B) the top images show the high-resolution OCT-angiograms of the CC in resting conditions (A) and during the HGT (B). On the bottom images the b-scans show the corresponding segmentation level (red dashed lines). (C, D) automatic local thresholding done with the Phansalkar method using a radius of 15 pixels produces thresholded image at baseline (C) and during the HGT (D). (E) differential OCT-angiogram: the red component of the image represents the increase of blood flow during the HGT.

activation of this vascular receptor's pathway in the pathogenesis of CSCR.<sup>52</sup> Mineralocorticoids, as well as glucocorticoids, may promote the rise of BP,<sup>53</sup> contributing to hemodynamic changes that favor CSCR. However, their major impact on this disease suggests a direct action on the choroid, with a site-specific response that has the potential for both vasoconstriction and vasodilation.<sup>54</sup> On this matter, little information can be drawn from our study since it did not include patients who were assuming corticosteroids or had endogenous hypercortisolism. We have not observed a different behavior of CC blood flow in those who had been previously exposed to these hormones with respect to the rest of the sample.

Limitations of the present study include the use of a prototype device. VD measurements are used to evaluate the extension of a vascular network on a given area and at a certain

depth. Nevertheless, we are aware that the lateral resolution (6  $\mu\text{m}$ ) and sampling intervals of the  $15^\circ \times 10^\circ$  area (11  $\mu\text{m}$ ) associated with the maximum intensity projection algorithm, might result a potential overestimation of the VD.<sup>54</sup> Other limitations may be related to the inhomogeneity of the study patients, some of whom had actual subretinal exudation (even if outside the analyzed area) while others had only history of active disease. Furthermore, some of them had been treated in the past with PDT or had taken corticosteroids. We assumed that a basic disturbance of choroidal circulation could characterize these patients in any case, as indeed it was detected. Moreover, the subgroup evaluation excluded conditioning the results by those factors. The quantitative analysis of the blood flow in the CC performed in the present study was aimed to investigate if there was a different response of CSCR patients and healthy subjects to an episodic elevation of blood pressure. This was significantly detected, showing that choroidal blood flow is dysregulated in CSCR. However, defining the degree of this dysregulation, and its relationship to clinical variables, may need further investigation that include repeatability and variability evaluations. More defined disease stages without factors of potential bias should be also considered in future studies. Then again, investigation on the choroidal vascular reactivity to hemodynamic stress—and consequently on the efficiency of choroidal blood flow regulation—could be extended to other clinical conditions having pachychoroid as common characteristic.<sup>55</sup>

In conclusion, we used OCTA to evaluate the real-time choroidal vascular reactivity to a systemic hemodynamic stress in patients with CSCR as compared with normal subjects. In this study, isometric exercise experimentally reproduced hypertensive episodes that frequently occur in everyday life, particularly in individuals with a higher sympathetic tone such as those affected by CSCR. Our results indicate that mechanisms regulating blood flow in the choroidal vessels might be, or progressively become, inefficient in CSCR, leaving this vascular district not sufficiently protected from sudden and repeated hemodynamic stresses. Using a new technology to analyze choroidal blood flow and a classic stress test to experimentally increase BP, this study confirms the role of a choroidal vascular dysregulation in the pathophysiology of CSCR. We suggest that the choroid of patients with this disease may have a peculiar vulnerability to systemic hemodynamic changes and represent a target-organ for damage by hypertension.

### Acknowledgments

Supported by Fondazione per la Macula Onlus, Genova, Italy.

Disclosure: **F. Cardillo Piccolino**, None; **M. Lupidi**, None; **C. Cagini**, None; **D. Fruttini**, None; **M. Nicolò**, None; **C.M. Eandi**, None; **S. Tito**, None

### References

- Gass JDM. Pathogenesis of disciform detachment of the neuroepithelium. II. Idiopathic central serous choroidopathy. *Am J Ophthalmol*. 1960;63:587–615.
- Yannuzzi LA, Gitter KA, Shatz H. *The Macula: A Comprehensive Text and Atlas*. Baltimore, MD: Williams & Wilkins; 1982: 145–165.
- Gilbert CM, Owens SL, Smith PD, et al. Long-term follow-up of central serous chorioretinopathy. *Br J Ophthalmol*. 1984;68: 815–820.
- Yannuzzi LA, Shakin JL, Fisher YL, et al. Peripheral detachments and retinal pigment epithelial atrophic tracts secondary to central serous pigment epitheliopathy. *Ophthalmology*. 1984;91:9.

5. Castro-correia J, Coutinho MF, Rosas V, et al. Long-term follow-up of central serous retinopathy in 150 patients. *Doc Ophthalmol*. 1992;81:379-386.
6. Cardillo Piccolino F, Rigault de la Longrais R, Ravera G, et al. The foveal photoreceptor layer and visual acuity loss in central serous chorioretinopathy. *Am J Ophthalmol*. 2005;139:87-99.
7. Eandi CM, Chung JE, Cardillo Piccolino F, et al. Optical coherence tomography in unilateral resolved central serous chorioretinopathy. *Retina*. 2005;25:417-421.
8. Guyer DR, Yannuzzi LA, Slakter JS, et al. Indocyanine green videoangiography of central serous chorioretinopathy. *Arch Ophthalmol*. 1994;112:1057-1062.
9. Cardillo Piccolino FC, Borgia L. Central serous chorioretinopathy and indocyanine green angiography. *Retina*. 1994;14:231-242.
10. Imamura Y, Fujiwara T, Margolis R, et al. Enhanced depth imaging optical coherence tomography of the choroid in central serous chorioretinopathy. *Retina*. 2009;29:1469-1473.
11. Scheider A, Nasemann JE, Lund OE. Fluorescein and indocyanine green angiographies of central serous chorioretinopathy by scanning laser ophthalmoscopy. *Am J Ophthalmol*. 1993;115:50-56.
12. Prunte C, Flammer J. Choroidal capillary and venous congestion in central serous chorioretinopathy. *Am J Ophthalmol*. 1996;121:26-34.
13. Cardillo Piccolino FC, Borgia L, Zinicola E, et al. Indocyanine green angiographic findings in central serous chorioretinopathy. *Eye*. 1995;9:324-332.
14. Yang L, Jonas JB, Wei W. Choroidal vessel diameter in central serous chorioretinopathy. *Acta Ophthalmol*. 2013;91:358-362.
15. Ferrara D, Mohler KJ, Waheed N, et al. En face enhanced-depth swept-source optical coherence tomography features of chronic central serous chorioretinopathy. *Ophthalmology*. 2014;121:719-726.
16. Sun J, Tan J, Wang Z, et al. Effect of catecholamines on central serous chorioretinopathy. *J Huazhong Univ Sci Technolog Med Sci*. 2003;23:313-316.
17. Carvalho-Recchia CA, Yannuzzi LA, Negrao S, et al. Corticosteroids and central serous chorioretinopathy. *Ophthalmology*. 2002;109:1834-1837.
18. Haimovici R, Rumelt S, Melby J. Endocrine abnormalities in patients with central serous chorioretinopathy. *Ophthalmology*. 2003;110:698-703.
19. Nikla DL, Wallman J. The multifunctional choroid. *Prog Retin Eye Res*. 2010;29:144-168.
20. Riva CE, Titze P, Hero M, et al. Choroidal blood flow during isometric exercises. *Invest Ophthalmol Vis Sci*. 1997;38:2338-2343.
21. Lovasik JV, Kergoat H, Riva CE, et al. Choroidal blood flow during exercise-induced changes in the ocular perfusion pressure. *Invest Ophthalmol Vis Sci*. 2003;44:2126-2132.
22. Polska E, Simader C, Weigert G, et al. Regulation of choroidal blood flow during combined changes in intraocular pressure and arterial pressure. *Invest Ophthalmol Vis Sci*. 2007;48:3768-3774.
23. Tittl M, Maar N, Polska E, et al. Choroidal hemodynamic changes during isometric exercise in patients with inactive central serous chorioretinopathy. *Invest Ophthalmol Vis Sci*. 2005;46:4717-4721.
24. Tittl MK, Spaide RF, Wong D, et al. Systemic findings associated with central serous chorioretinopathy. *Am J Ophthalmol*. 1999;128:63-68.
25. Eom Y, Oh J, Kim SW, et al. Systemic factors associated with central serous chorioretinopathy in Koreans. *Korean J Ophthalmol*. 2012;26:260-264.
26. Yannuzzi LA. Type A behavior and central serous chorioretinopathy. *Trans Am Ophthalmol Soc*. 1986;84:799-845.
27. Bernasconi P, Messmer E, Bernasconi A, et al. Assessment of the sympatho-vagal interaction in central serous chorioretinopathy measured by power spectral analysis of heart rate variability. *Graefes Arch Clin Exp Ophthalmol*. 1998;236:571-576.
28. Ferrara N, Waheed NK, Duker JS. Investigating the choriocapillaris and choroidal vasculature with new optical coherence tomography technologies. *Prog Retin Eye Res*. 2016;52:130-155.
29. Branchini L, Regatieri CV, Flores-Moreno I, et al. Reproducibility of choroidal thickness measurements across three spectral domain optical coherence tomography systems. *Ophthalmology*. 2012;119:119-123.
30. Choi W, Mohler KJ, Potsaid B, Lu CD, et al. Choriocapillaris and choroidal microvasculature imaging with ultrahigh speed OCT angiography. *PLoS One*. 2013;8:e81499.
31. Coscas GJ, Lupidi M, Coscas F, et al. Optical coherence tomography angiography versus traditional multimodal imaging in assessing the activity of exudative age-related macular degeneration: a new diagnostic challenge. *Retina*. 2015;35:2219-2228.
32. Mathiowetz V, Weber K, Volland G, et al. Reliability and validity of grip and pinch strength evaluations. *J Hand Surg Am*. 1984;9A:22-26.
33. Robinson F, Riva CE, Grunwald JE, et al. Retinal blood flow autoregulation in response to an acute increase in blood pressure. *Invest Ophthalmol Vis Sci*. 1986;27:722-726.
34. Lupidi M, Coscas F, Cagini C, et al. Automated quantitative analysis of retinal microvasculature in normal eyes on optical coherence tomography angiography. *Am J Ophthalmol*. 2016;169:9-23.
35. Phansalkar N, More S, Sabale A, et al. Paper ID 154: adaptive local thresholding for detection of nuclei in diversely stained cytology images. *Proc International Conf Commun Signal Process*. 2011;218-220.
36. Spaide RF. Ising model of choriocapillaris flow. *Retina*. 2018;38:79-83.
37. Hietanen E. Cardiovascular responses to static exercise. *Scand J Work Environ Health*. 1984;10:379-402.
38. Riendl AM, Gotshall RW, Reinke JA, et al. Cardiovascular response of human subjects to isometric contractions of large and small muscle groups. *Proc Soc Exp Biol Med*. 1977;154:171-174.
39. Krzeminski K, Cybulski A, Ziemia A, et al. Cardiovascular and hormonal responses to static handgrip in young and older healthy men. *Eur J Appl Physiol*. 2012;112:1315-1325.
40. Lucini D, Norbiato G, Clerici M, Pagani M. Hemodynamic and autonomic adjustments to real life stress conditions in humans. *Hypertension*. 2002;39:184-188.
41. Tewari HK, Gadia R, Kumar D, Venkatesh P, Garg SP. Sympathetic-parasympathetic activity and reactivity in central serous chorioretinopathy: a case-control study. *Invest Ophthalmol Vis Sci*. 2006;47:3474-3478.
42. Lovasik JV, Kergoat H. Systemic determinants. In: Schmetter L, Kiel J, eds. *Ocular Blood Flow*. Heidelberg, Germany: Springer-Verlag; 2012:173-210.
43. Spaide RF. Choriocapillaris flow features follow a power law distribution: implications for characterization and mechanisms for disease progression. *Am J Ophthalmol*. 2016;170:58-67.
44. Costanzo E, Cohen SY, Miere A, et al. Optical coherence tomography angiography in central serous chorioretinopathy. *J Ophthalmol*. 2015;2015:134783.



45. Shinjima A, Kawamura A, Mori R, et al. Findings of optical coherence tomographic angiography at the choriocapillaris level in central serous chorioretinopathy. *Ophthalmologica*. 2018;236:108-113.
46. Chan SY, Wang Q, Wei WB, et al. Optical coherence tomographic angiography in central serous chorioretinopathy. *Retina*. 2016;36:2051-2058.
47. Alwassia AA, Adhi M, Zhang JY, et al. Exercise-induced acute changes in systolic blood pressure do not alter choroidal thickness as measured by a portable spectral-domain optical coherence tomography device. *Retina*. 2013;33:160-165.
48. Roybal CN, Sledz E, Elshatory E, et al. Dysfunctional autonomic regulation of the choroid in central serous chorioretinopathy. *Retina*. 2018;38:1205-1210.
49. Chrysant SG. The value of grip test as index of autonomic function in hypertension. *Clin Cardiol*. 1982;5:139-143.
50. Rothwell PM, Howard SC, Dolan E, et al. Prognostic significance of visit-to-visit variability, maximum systolic blood pressure, and episodic hypertension. *Lancet*. 2010;375:895-905.
51. Piccolino FC. Central serous chorioretinopathy: some considerations on the pathogenesis. *Ophthalmologica*. 1981;182:204-210.
52. Daruich A, Matet A, Dirani A, et al. Central serous chorioretinopathy: recent findings and new physiopathology hypothesis. *Prog Retin Eye Res*. 2015;48:82-118.
53. Ullian ME. The role of corticosteroids in the regulation of vascular tone. *Cardiovasc Res*. 1999;41:55-64.
54. Walker BR, Williams BC. Corticosteroids and vascular tone: mapping the messenger maze. *Clin Sci (Lond)*. 1992;82:597-605.
55. Dansingani KK, Balaratnasingam C, Naysan J, et al. En face imaging of pachychoroid spectrum disorders with swept-source optical coherence tomography. *Retina*. 2016;36:499-516.