

Maxillo-mandibular osteoradionecrosis following C-ion radiotherapy: Clinical notes and review of literature

European Journal of Inflammation
Volume 18: 1–6
© The Author(s) 2020
Article reuse guidelines:
sagepub.com/journals-permissions
DOI: 10.1177/2058739220934562
journals.sagepub.com/home/eji



Valeria Dell'Era,¹  Paolo Aluffi Valletti,¹ Giacomo Garzaro² and Massimiliano Garzaro¹

Abstract

Osteoradionecrosis (ORN) is one of the most feared complications after head and neck radiotherapy. Among head and neck sites, the mandible is the most commonly involved bone. Heavy ion radiotherapy delivers high-dose distribution focused to the target while simultaneously sparing of the adjacent organs but there are anyway some reported cases of ORN. Cases in literature reported well-known risk factors for its developing (e.g. tobacco and alcohol abuse, diabetes), but other are still debated (e.g. teeth extraction during radiotherapy). Prevention is mandatory but multimodal care may be required, tailoring all treatments on the patient needs. This study, after a brief revision of the literature, reports and a case of maxillo-mandibular ORN following carbon-ion (C-ion) radiotherapy and its treatment.

Keywords

adverse effects, heavy ion radiotherapy, osteoradionecrosis

Date received: 21 May 2019; accepted: 26 May 2020

Introduction

Osteoradionecrosis (ORN) is a late and persistent condition of non-vital bone in an irradiated site; most often ORN occurs between 4 months and 2 years after radiotherapy (RT) and continues more than 3 months.^{1,2}

The severity of ORN is usually classified in three grades of disease:³ the first (I) with simple exposition of the alveolar bone; the second (II), as a process unresponsive to medical and hyperbaric oxygen therapy (HBOT), requiring surgery. Grade III is characterized by a complete involvement of the bone, with or without pathologic fracture.

Smoking, alcohol abuse, diabetes, and dental treatment are the most relevant risk factors for grade III ORN, as described by Chronopoulos et al. in a study on 115 patients (153 lesions).⁴

ORN is a rare complication (<6%) in patients who receive less than 60 Gray (Gy) and the

association of RT with chemotherapy seems to increase the risk to develop it, as reported by Delanian and Lefaix⁵

Among head and neck bones, the mandible is the most affected subsite, with a reported incidence between 2% and 22%.⁶

Nowadays, a large number of patients affected by head and neck tumors underwent heavy ion (HI) RT; such therapy allows optimal dose distribution at a specific depth, reducing the involvement of the contiguous tissues if compared with intensity modulated radiotherapy (IMRT). The theoretical

¹ENT Division, University of Eastern Piedmont, Novara, Italy

²Department of Public Health Sciences and Pediatrics, University of Turin, Turin, Italy

Corresponding author:

Valeria Dell'Era, ENT Division, University of Eastern Piedmont, Corso Mazzini 18, 28100 Novara, Italy.
Email: valeria.dellera@gmail.com



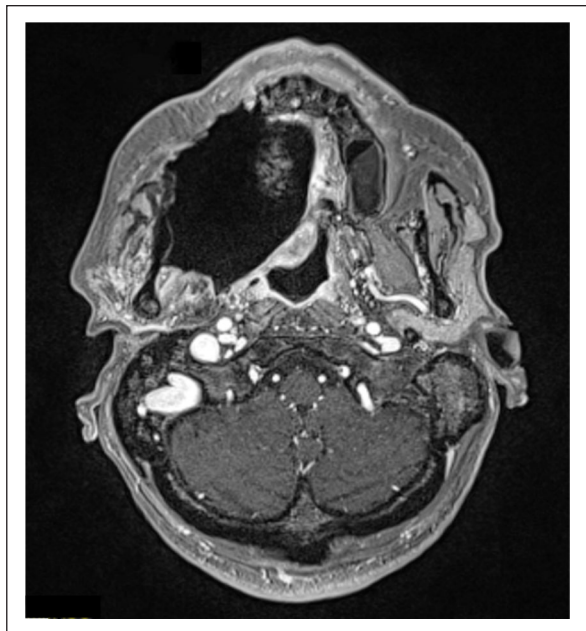


Figure 1. Axial MRI image after resection of the tumor: partial right maxillectomy extended to pterygoid process, vomer and partially to the inferior right turbinate.

advantage of HI is to decrease the probability of late RT-induced side effects, including ORN.

Sasahara et al.⁷ confirm the correlation between photon or heavy ion RT and ORN, suggesting also a correlation with dosimetric parameters.

We report a rare case of grade III ORN arose in a patient affected by oral cavity tumor, who underwent surgery and adjuvant C-ion RT.

Case report

A 51-years-old man underwent partial maxillectomy (right) extended to pterygoid process, vomer and partially to the inferior right turbinate for an adenoid cystic carcinoma of the right posterior part of hard palate (T4b Nx).

Post-surgical outcomes are showed by magnetic resonance imaging (MRI) in Figure 1.

The tumor board suggested adjuvant C-ion RT (68.8–4.3 GyE/day, 4 day/week in 4 weeks), due to histopathologic features (massive bone invasion and deep margins positive). The mean and maximum doses of RT were respectively 43.6 and 69.4 GyE for maxillary bone, 27.2 and 52.4 GyE for mandibular site; no major or minor complications were reported during and after C-ion RT, except for a grade I mucositis.

One year later, the patient developed mild trismus and severe pain. Antibiotics (cephalosporins

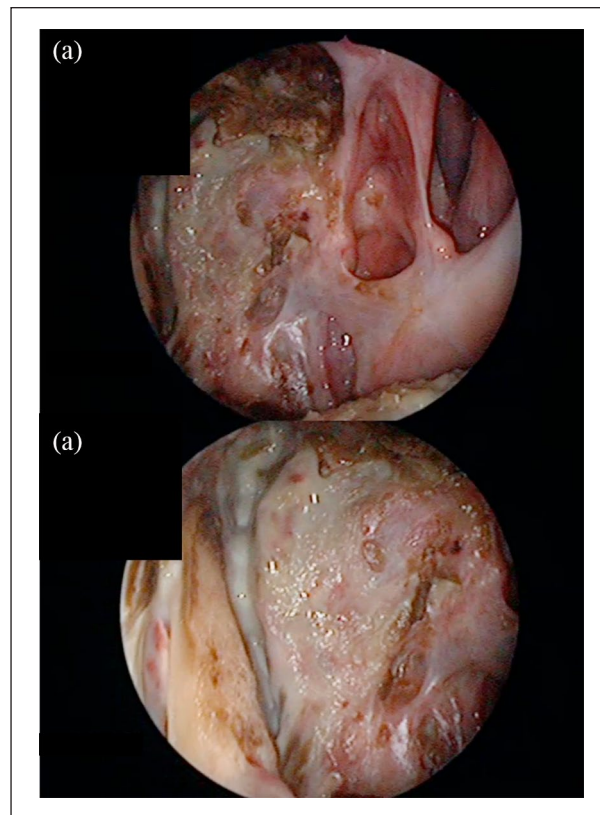


Figure 2. Exposed necrotic bone from right lower retromolar area extended toward midline: upper part (a) with maxillary sinus opened, inferior part (b) with mandibula.

iv) and local medications with chlorhexidine were immediately administered, daily for 10 days.

The patient also had 1.4 dental extraction (that seemed to cause local infection) and section of a right gingival synechia, with normal healing after 10 days.

One month later, the patient complained severe pain again and showed local signs of bone necrosis; a HBOT was precociously suggested.

After a normal course, 3 months later, pain and trismus started again and the necrosis area enlarged.

On extra oral examination, skin on lower right side of cheek showed scar of a healed sinus.

Intra-oral examination was difficult due to limited mouth opening (2 cm maximum), but a diffuse mucositis was detected. Exposed necrotic bone from right lower retromolar area extended toward midline as shown in Figure 2(a) and (b).

Again, antibiotic intravenous therapy was administered associated with oral pentoxifylline; local medications and a sequestrectomy were performed.

Radiological and endoscopic control after 7 months of therapy are shown in Figure 3; contrast

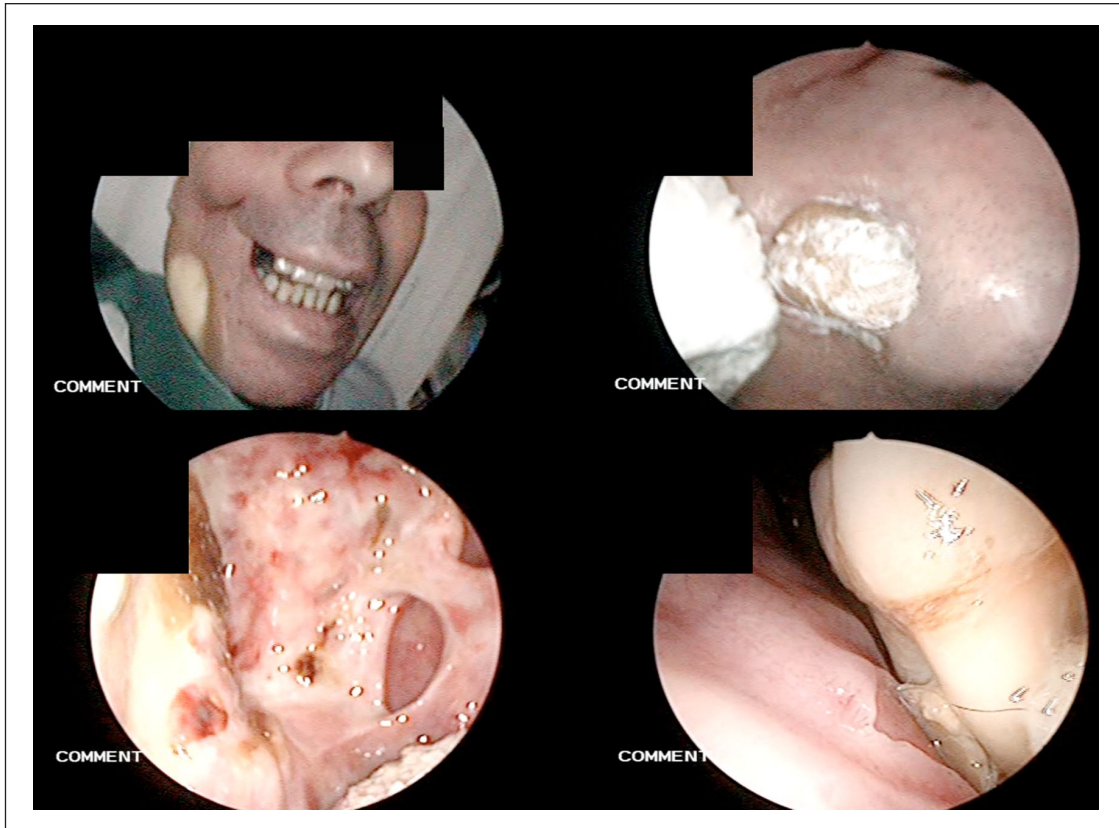


Figure 3. Endoscopic view of necrotic bone, mucosal inflammation, and cutaneous fistula (enlarged) with exposition of 4 cm of the jaw.

MRI and contrast computed tomography (CT)-scan in Figures 4 and 5, respectively. Clinical findings were enlargement of cutaneous fistula and severe osteonecrosis of the jaw.

Currently, with a follow-up of 11 months since the beginning of ORN, the clinical picture is stable; the feasibility of major surgery is going to be evaluated (jaw partial resection and curettage of necrotic tissues).

Discussion

Carbon-ion radiotherapy (C-ion RT) showed excellent results in the treatment of radio-resistant tumors such as adenoid cystic carcinoma, mucosal malignant melanoma, and adenocarcinoma.

Although C-ion RT seems to reduce the risk of ORN in comparison with conventional treatments (e.g. photon-RT), the association of high doses delivered to the mandible with other risk factors (smoking, trauma, or teeth extraction) strongly increases the incidence of such complication.^{8,9}

Well-known risks factor to develop ORN are tobacco and alcohol abuse.¹⁰

Chronopoulos et al.⁴ report that active smoking (OR: 13.542, 95% CI: 2.085–87.947), excessive alcohol consumption (OR: 5.428, 95% CI: 1.622–18.171) and dental treatment and/or local pathological conditions (OR: 0.237, 95% CI: 0.086–0.655) were significant predictors for stage III necrosis.

The correlation between the presence of teeth within the planning target volume (PTV) and ORN in photon-RT has been reported by Morrish et al.¹⁰ in a population of 78 irradiated patients; among the patients, 19 of 78 (24.4%) with in-field teeth developed ORN, whereas only 3 of 22 (13.6%) without in-field teeth experienced the condition.

The presence of teeth within the PTV was indicated as an independent risk factor for ORN after C-ion RT.¹¹

Teeth extraction (<21 days before RT, <2 years after RT) and also local trauma (including biopsy) are generally considered the main risk factors in ORN.¹⁰

Here, we report the case of a radio-resistant tumor (adenoid cystic carcinoma of the palate) in a young active-smoking man (more than 15 cigarettes daily), who underwent C-ion RT.

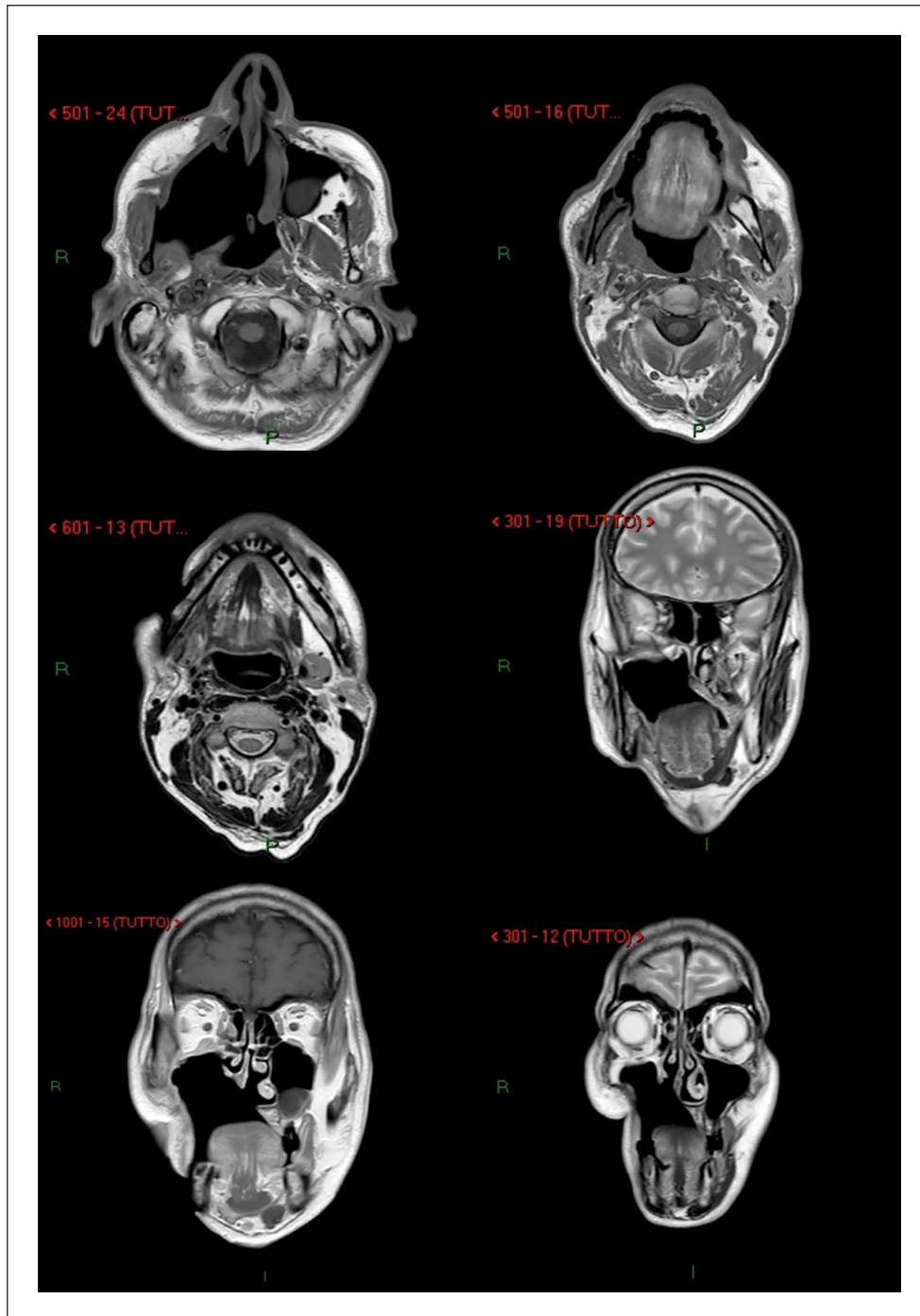


Figure 4. Contrast MRI shows right jaw necrosis and cutaneous fistula.

Less than 1 year after the adjuvant treatment, the patient became symptomatic (pain and trismus) and developed local infection, due to 1.4 tooth extraction and section of a gingival synechia.

According to the literature, he counts three of the main risk factors acting in ORN development: tobacco abuse, tooth extraction less than 1 year after treatment and C-Ion RT > 60 GyE.²

How reported by Oki et al.,¹² ORN can develop until many months after RT. Even if ORN tend to occur in the first 3 years after RT, the patients should be considered at risk for a longer period.

As reported in literature, good management of ORN includes prevention and a multimodal treatment after its developing.

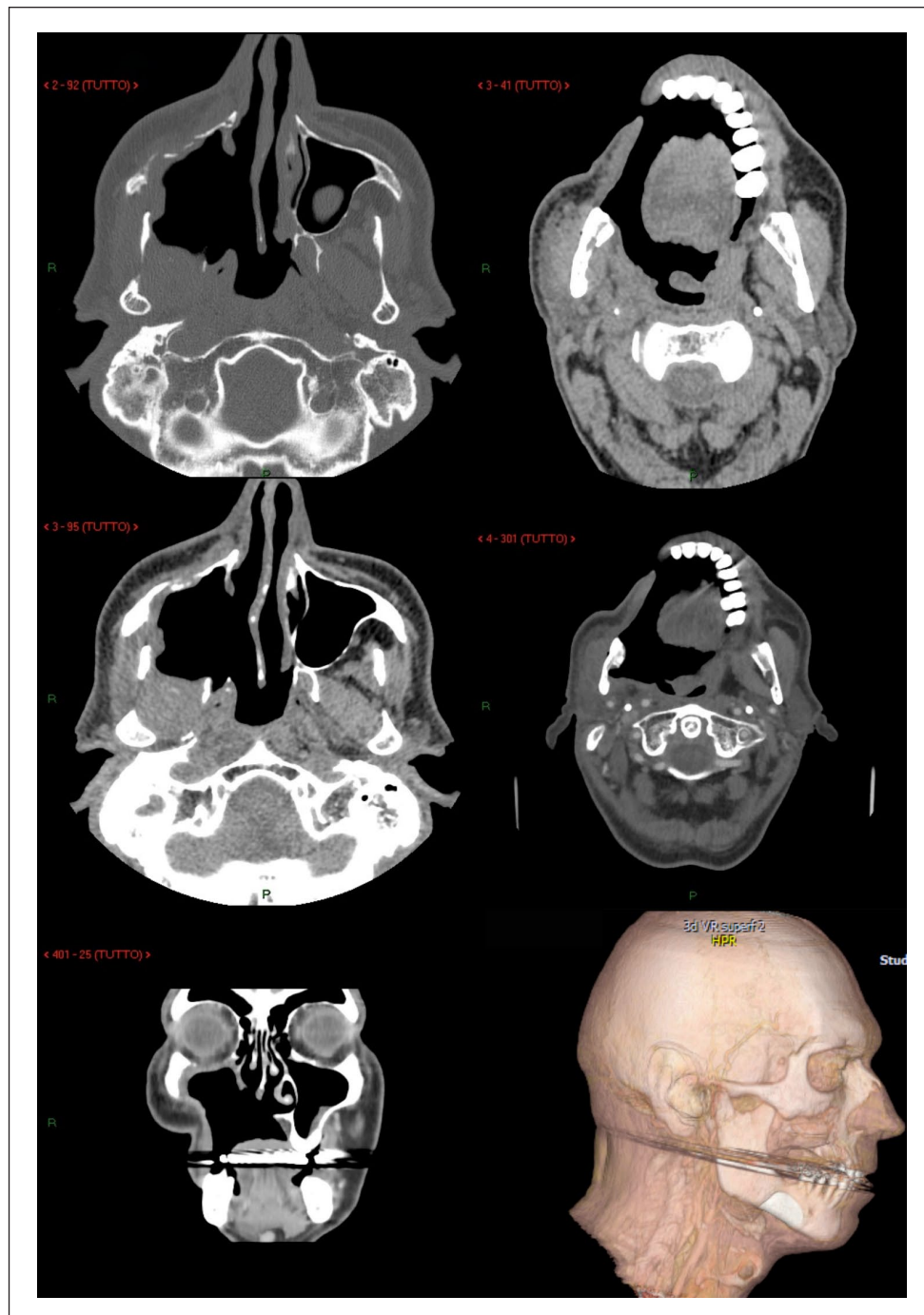


Figure 5. Contrast CT-scan: the necrosis extended to the maxillary anterior wall.

Conservative measures are recommended for early stage while surgical approach should be reserved to the advanced cases. Analgesic and superinfection control are mandatory to avoid major mutilating surgery.

HBOT can be applied because of its role in stimulating peripheral blood volume redistribution, local angiogenesis, re-epithelialization, collagen

synthesis, osteoblastic proliferation and to antagonize local infections. Costa et al.¹³ reported that the inhalation of pure oxygen must be repeated for almost 30 sessions (2.4 ATA, once a day and 5 times/week, for 90 mins).

Medicative therapy includes tocopherols (TCP), an antioxidant which improves clearance of reactive oxygen species (ROS) and pentoxifylline (PTX), an

hemorheologic agent that reduces blood viscosity, decreasing the risk of thrombotic diseases.^{13,14} Costa et al.¹³ suggest to use clodronate (CLO) to reduce number and activity of osteoclasts.

Gold standard in treatment of ORN does not exist, but an association of HBOT, medical therapy, and sequestrectomy as ultimate option seems to be the best approach.¹⁰

In conclusion, the therapy of stage III ORN must be tailored on the patients' characteristics and often the results are partial and disappointing.

Even if the literature seems to suggest a lower rate of ORN with HI therapy, the present report points out the need to avoid, if possible, dental treatment close to the end of C-ion therapy and the importance of prevention measures, reducing smoking, and alcohol use.

Declaration of conflicting interests

The author(s) declared the following potential conflicts of interest with respect to the research, authorship, and/or publication of this article: All the authors disclosed the absence of a funding source from the National Institutes of Health, Welcome Trust, Howard Hughes Medical Institute, or any other, and all authors disclosed conflicts of interests.

Ethics approval

Our institution does not require ethical approval for reporting individual cases or case series.

Funding

The author(s) received no financial support for the research, authorship, and/or publication of this article.

Informed consent

Written informed consent was obtained from the patient(s) for their anonymized information to be published in this article.

ORCID iD

Valeria Dell'Era  <https://orcid.org/0000-0002-2171-4120>

References

1. Chronopoulos A, Zarra T, Ehrenfeld M et al. (2018) Osteoradionecrosis of the jaws: Definition, epidemiology, staging and clinical and radiological findings. A concise review. *International Dental Journal* 68(1): 22–30.
2. Rayatt SS, Mureau MA and Hofer SO (2007) Osteoradionecrosis of mandible: Etiology, prevention, diagnosis and treatment. *Indian Journal of Plastic Surgery* 40: 65–71.
3. Notani K, Yamazaki Y, Kitada H et al. (2003) Management of mandibular osteoradionecrosis corresponding to the severity of osteoradionecrosis and the method of radiotherapy. *Head & Neck* 25(3): 181–186.
4. Chronopoulos A, Zarra T, Troltzsch M et al. (2015) Osteoradionecrosis of the mandible: A ten year single-center retrospective study. *Journal of Cranio-Maxillo-Facial Surgery* 43(6): 837–846.
5. Delanian S and Lefaix JL (2004) The radiation-induced fibroatrophic process: Therapeutic perspective via the antioxidant pathway. *Radiotherapy and Oncology: Journal of the European Society for Therapeutic Radiology and Oncology* 73(2): 119–131.
6. Caparrotti F, Huang SH, Lu L et al. (2017) Osteoradionecrosis of the mandible in patients with oropharyngeal carcinoma treated with intensity-modulated radiotherapy. *Cancer* 123(19): 3691–3700.
7. Sasahara G, Kot M, Ikawa H et al. (2014) Effects of the dose-volume relationship on and risk factors for maxillary osteoradionecrosis after carbon ion radiotherapy. *Radiation Oncology* 9(1): 92.
8. Zhang W, Zhang X, Yang P et al. (2017) Intensity-modulated proton therapy and osteoradionecrosis in oropharyngeal cancer. *Radiotherapy and Oncology: Journal of the European Society for Therapeutic Radiology and Oncology* 123(3): 401–405.
9. van de Water TA, Bijl HP, Schilstra C et al. (2011) The potential benefit of radiotherapy with protons in head and neck cancer with respect to normal tissue sparing: A systematic review of literature. *The Oncologist* 16(3): 366–377.
10. Morrish RB Jr, Chan E, Silverman S et al. (1981) Osteonecrosis in patients irradiated for head and neck carcinoma. *Cancer* 47(8): 1980–1983.
11. Chang DT, Sandow PR, Morris CG et al. (2007) Do pre-irradiation dental extractions reduce the risk of osteoradionecrosis of the mandible? *Head & Neck* 29(6): 528–536.
12. Oki M, Kanazaki A and Taniguchi H (2016) Osteoradionecrosis following carbon ion radiotherapy: Case history report of a soft palate defect. *The International Journal of Prosthodontics* 29(5): 448–450.
13. Costa DA, Costa TP, Netto EC et al. (2016) New perspectives on the conservative management of osteoradionecrosis of the mandible: A literature review. *Head & Neck* 38(11): 1708–1716.
14. Seo MH, Eo MY, Myoung H et al. (2020) The effects of pentoxifylline and tocopherol in jaw osteomyelitis. *Journal of the Korean Association of Oral and Maxillofacial Surgeons* 46(1): 19–27.