

SPECIAL ARTICLE

Adrenocortical carcinomas and malignant pheochromocytomas: ESMO—EURACAN Clinical Practice Guidelines for diagnosis, treatment and follow-up[†]

M. Fassnacht^{1,2}, G. Assie^{3,4}, E. Baudin⁵, G. Eisenhofer⁶, C. de la Fouchardiere⁷, H. R. Haak^{8,9,10}, R. de Krijger^{11,12}, F. Porpiglia^{13,14}, M. Terzolo¹⁵ & A. Berruti¹⁶, on behalf of the ESMO Guidelines Committee*

¹Department of Internal Medicine I, Division of Endocrinology and Diabetes, University Hospital, University of Würzburg, Würzburg; ²Comprehensive Cancer Center Mainfranken, University of Würzburg, Würzburg, Germany; ³Department of Endocrinology, Reference Centre for Rare Adrenal Diseases, Reference Centre for Rare Adrenal Cancers, Hôpital Cochin, Assistance Publique Hôpitaux de Paris, Paris; ⁴Institut Cochin, Institut National de la Santé et de la Recherche Médicale U1016, Centre National de la Recherche Scientifique UMR8104, Université Paris Descartes, Sorbonne Paris Cité, Paris; ⁵Department of Endocrine Oncology and Nuclear Medicine, Gustave Roussy, Villejuif, France; ⁶Department of Medicine III and Institute of Clinical Chemistry and Laboratory Medicine, Technische Universität Dresden, Dresden, Germany; ⁷Department of Medical Oncology, Centre Léon Bérard, University Claude Bernard Lyon I, Lyon, France; ⁸Department of Internal Medicine Máxima Medisch Centrum, Eindhoven; ⁹Department of Internal Medicine, Division of General Internal Medicine, Maastricht University Medical Centre, Maastricht; ¹⁰Maastricht University, CAPRI School for Public Health and Primary Care, Ageing and Long-Term Care, Maastricht; ¹¹Department of Pathology, University Medical Center Utrecht, Utrecht; ¹²Princess Maxima Center for Pediatric Oncology, Utrecht, The Netherlands; ¹³Division of Urology, San Luigi Hospital — Orbassano, Turin; ¹⁴Department of Oncology, University of Turin, Turin; ¹⁵Internal Medicine, Department of Clinical and Biological Sciences, San Luigi Hospital, University of Turin, Turin; ¹⁶Department of Medical and Surgical Specialties, Radiological Sciences and Public Health, Medical Oncology, University of Brescia, ASST-Spedali Civili, Brescia, Italy



Available online 27 August 2020

Key words: Clinical Practice Guidelines, adrenal cancer, diagnosis, treatment, follow-up

INCIDENCE AND EPIDEMIOLOGY

Two different primary malignancies can arise from the adrenal gland: adrenocortical carcinoma (ACC) from the adrenal cortex and malignant pheochromocytoma from the adrenal medulla. Both malignancies are rare. ACC has an estimated incidence of ~0.5-2 new cases per million people per year.^{1,2} Pheochromocytomas are catecholamine-producing neuroendocrine tumours arising from chromaffin cells of the adrenal medulla or extra-adrenal paraganglia. The latter are usually called paraganglioma, leading to the combined term pheochromocytomas and paragangliomas (PPGLs). The detected incidence of PPGLs is commonly reported at 2-8 per million per year³ (supplementary information, available at <https://doi.org/10.1016/j.annonc.2020.08.2099>).

All patients with suspected and proven ACC or PPGL should be discussed in a multidisciplinary expert team meeting, at least at the time of initial diagnosis (ideally before surgery) and in case of progressive disease.

*Correspondence to: ESMO Guidelines Committee, ESMO Head Office, Via Ginevra 4, 6900 Lugano, Switzerland
E-mail: clinicalguidelines@esmo.org (ESMO Guidelines Committee).

[†] Approved by the ESMO Guidelines Committee: June 2020. This publication supersedes the previously published version—*Ann Oncol.* 2012;23(suppl_7): vii131-vii138.

0923-7534/© 2020 European Society for Medical Oncology. Published by Elsevier Ltd. All rights reserved.

DIAGNOSIS AND PATHOLOGY/MOLECULAR BIOLOGY

Every patient with (suspected) ACC or PPGL should undergo careful clinical assessment, including case history, clinical examination for symptoms and signs of adrenal hormone excess. For more details on this topic, we refer to more comprehensive guidelines and reviews.³⁻⁸

Hormonal evaluation

The aims of hormonal evaluation are multiple: (i) hormone assays provide orientation to the nature of the adrenal mass and can be useful to assess presence of malignancy; (ii) a pheochromocytoma should always be ruled out, because these tumours can induce life-threatening crises, requiring specific management before any intervention; (iii) massive adrenocortical steroid excess can impact short-term survival and quality of life (QoL), requiring specific treatments to block impacts of hormonal excess; (iv) abnormal hormone secretions may serve as biological markers for the follow-up of patients; (v) in case of large bilateral adrenal masses, a systematic assessment of adrenal function is recommended to rule out adrenal insufficiency. Precise hormone assays have been detailed in recent guideline statements,^{4,5,9,10} and are summarised in Table 1.

For all adrenal masses, the diagnosis of pheochromocytoma should be systematically assessed by

measuring plasma-free or urinary-fractionated metanephrines [V, A].^{5,10} Additional measurements of plasma methoxytyramine, a biomarker now increasingly available, provide useful information to assess the likelihood of malignancy.¹¹ In cases of suspected ACC, an extensive steroid hormone work-up is recommended, assessing gluco-, mineralo-, sex- and precursor-steroids ([V, B] (Table 1)).¹²⁻¹⁶

Imaging

For best patient care, adequate visualisation of the tumour and potential metastases is essential. For differential diagnosis of an adrenal mass, computed tomography (CT) and magnetic resonance imaging (MRI) are both effective [IV, A]. Although these methods cannot determine the exact entity of the mass, both are able to correctly diagnose a subset of benign tumours—at least when carried out according to state-of-the-art criteria. The single best criterion to diagnose a benign tumour (e.g. adenoma) remains Hounsfield units ≤ 10 in an unenhanced CT.¹⁷ However, other imaging criteria, such as rapid washout in 10- or 15-min delayed contrast-enhanced CT, signal intensity loss using opposed-phase MRI, and low 2-fluorine-18 [¹⁸F]fluoro-2-deoxy-D-glucose (FDG) uptake in [¹⁸F]FDG-positron electron tomography (PET)/CT are also suggestive of a benign tumour. Most ACCs show an inhomogeneous appearance in CT or MRI with irregular margins and irregular enhancement of solid components after intravenous injection of contrasted agent. Detection of local invasion or tumour extension into the inferior vena cava, as well as lymph node or other metastases—including lung and liver—is mandatory before planning any surgery. Therefore, cross-sectional imaging of the chest, abdomen and pelvis is required preoperatively [V, A].

For PPGLs, conventional radiological imaging can be important to determine the presence of metastases. However, neither CT nor MRI can be used to determine whether PPGLs are benign or malignant. Malignancy can only be determined from the presence of metastatic lesions at sites where chromaffin cells are normally absent. Without such evidence, all PPGLs should be considered potentially malignant, with risk dependent on several factors as outlined below.

There are a number of functional imaging modalities available for patients with PPGLs (supplementary File, available at <https://doi.org/10.1016/j.annonc.2020.08.2099>). The indication is twofold: (i) best tumour staging in patients with suspected metastases (e.g. by conventional imaging) or with presumably high risk for metastases; (ii) to evaluate the option of a radionuclide-based therapy in patients with nonresectable PPGL. For assessments of metastatic risk for the first indication the authors suggest the presence of one or more of the following criteria:

- tumour size ≥ 5 cm;
- any extra-adrenal paraganglioma;
- known succinate dehydrogenase complex iron sulfur subunit B (*SDHB*) germline mutation; or

- plasma methoxytyramine more than threefold above the upper cut-offs of reference intervals.

For imaging-based diagnosis of metastatic PPGLs, it is important to avoid confusing metastases with multiple primary tumours that often occur in patients with hereditary PPGL syndromes. Additionally, local recurrences should not be misdiagnosed as metastases.

Pathology

Biopsy of adrenal tumours is usually contraindicated because of the risk of tumour spillage, poor diagnostic power to discriminate benign from malignant adrenocortical tumours and risk of hypertensive crises in pheochromocytoma. However, a biopsy might be indicated in an adrenal mass without any hormone excess in patients with a history of extra-adrenal cancers to exclude or prove an adrenal metastasis of an extra-adrenal malignancy, and in patients in whom tumour sequencing is desired.

The pathological differential diagnosis of adrenal neoplasias in both biopsied and resected specimens is primarily based on morphological features requiring an experienced pathologist [IV, A]. Preferably, a panel of immunohistochemical markers should be applied to aid diagnosis; for example, steroidogenesis factor 1 (SF1) or, alternatively, inhibin- α , calretinin and melan-A for identification of adrenocortical tumours and chromogranin A for identification of PPGL [IV, A]. Staining for tyrosine hydroxylase and synaptophysin may also be helpful to highlight PPGL, but positive results for synaptophysin are also possible in adrenocortical tumours. The differential diagnosis between ACC and adenoma may be challenging as no single marker indicates malignancy. The most widely used diagnostic score has been introduced by Weiss^{18,19} and includes nine parameters (supplementary Table S1, available at <https://doi.org/10.1016/j.annonc.2020.08.2099>) [IV, A]. A score of ≥ 3 suggests malignancy. In addition, the Ki-67 labelling index, as a marker of proliferative activity, may be useful and is very helpful for prognostic purposes (supplementary Tables S2 and S3, available at <https://doi.org/10.1016/j.annonc.2020.08.2099>).

For pheochromocytomas, the situation is similarly demanding. Tumour size, *SDHB* mutation status, extra-adrenal location and plasma methoxytyramine may all be used to indicate risk of metastasis. However, there is no single histological or immunohistochemical parameter that can predict the clinical behaviour of PPGL. Nevertheless, several histological scoring systems have been developed.²⁰⁻²³ All these scores have value but none of them has reached general acceptance. Therefore, according to the current World Health Organization (WHO) classification, all PPGLs should be considered to have some malignant potential.²⁴ A definitive diagnosis of malignancy can only be made by the presence of metastases at sites where chromaffin tissue is normally absent (e.g. liver, bone, lungs or lymph nodes), assessed by pathology or imaging, in particular functional imaging.

Table 1. Diagnostic work-up of (suspected) adrenal- or paraganglioma-related malignancies

Specific question	Assays	Indication
(Suspected) ACC		
Exclusion of glucocorticoid excess?	1 mg dexamethasone suppression test	All adrenal masses with no overt Cushing (clinically)
Characterisation of glucocorticoid excess?	1 mg dexamethasone suppression test Free cortisol in 24-h urine Basal ACTH (plasma)	Adrenal masses with clinical signs of Cushing or pathological 1 mg dexamethasone test
Sex steroids and steroid precursors excess?	DHEA-S 17-OH progesterone Androstenedione Testosterone (only in women) 17-beta-oestradiol (only in men and postmenopausal women) 11-deoxycortisol (if available)	Any adrenal mass suspected to be an ACC
Mineralocorticoid excess?	Potassium Aldosterone/renin ratio	Any adrenal masses with hypertension and/or hypokalaemia
Extension of the adrenal tumour and evidence for metastases?	CT or MRI of abdomen, pelvis and chest (or FDG-PET/CT including full-dose CT)	All suspected ACCs
Evidence of cerebral metastases?	Cerebral MRT	Only if cerebral metastases are suspected
Evidence of bone metastases	FDG-PET/CT, bone scan, bone CT or bone MRI	Only if skeletal metastases are suspected
(Suspected) PPGL		
Catecholamine excess?	Fractionated metanephrines in 24-h urine or plasma-free metanephrines and methoxytyramine	All adrenal masses and all paraganglioma
Extension of the adrenal tumour?	CT or MRI of abdomen	All biochemically confirmed phaeochromocytoma
Evidence of thoracic metastases?	Chest CT (or PET/CT including full-dose CT)	All PPGL patients with a 'high risk of metastases' ^a
Evidence of cerebral metastases?	Cerebral MRT	Only if cerebral metastases are suspected
Evidence of bone metastases	FDG-PET/CT, DOTATATE-PET/CT, bone scan, bone CT or bone MRI	Only if skeletal metastases are suspected ^b
Additional functional imaging?	At least one functional whole-body imaging (i.e. FDG-PET, DOTATATE-PET, MIBG scintigraphy)	In all PPGL patients with a 'high risk of metastases' ^a
Radionuclide therapy possible?	MIBG scintigraphy and somatostatin-based imaging (e.g. DOTATATE-PET/CT)	In all PPGL patients with evidence for metastases

17-OH, 17-hydroxy; ACC, adrenocortical carcinoma; ACTH, adrenocorticotropic hormone; CT, computed tomography; DHEA-S, dehydroepiandrosterone sulfate; FDG-PET, 2-fluoro-2-deoxy-D-glucose-positron electron tomography; MIBG, meta-iodobenzylguanidine; MRI, magnetic resonance imaging; MRT, magnetic resonance tomography; PPGL, phaeochromocytoma and paraganglioma; SDHB, succinate dehydrogenase complex iron sulfur subunit B.

^a The authors suggest being at a 'high risk of metastases' applies to all patients who fulfil one or more of the following criteria: adrenal phaeochromocytoma ≥ 5 cm or any extra-adrenal paraganglioma or known *SDHB* germline mutation or plasma methoxytyramine more than threefold above the upper reference limit.

^b Some authors are in favour of carrying out functional imaging to detect bone metastases in all PPGL patients.

Molecular biology

Molecular characterisation of ACC (supplementary File, available at <https://doi.org/10.1016/j.annonc.2020.08.2099>) and PPGL is an active area of ongoing research. The gene encoding subunit B of the SDHB complex is by far the most important molecular contributor to malignant PPGL, with at least 40% of all cases of metastatic PPGLs carrying mutations of this gene.²⁵ Inactivation of *SDHB* reduces function of the succinate dehydrogenase complex, leading to activation of the hypoxia-inducible pathway and a pseudohypoxic state characterised by increased angiogenesis, growth and expression of mitogenic factors,²⁶ but also to DNA hypermethylation, which is believed to provide a further drive to metastatic progression.²⁷

At least 35% of PPGLs result from germline mutations of over 18 tumour-susceptibility genes identified to date,²⁸⁻³³ with those resulting in stabilisation of hypoxia-inducible factors 1α and 2α (*HIF1\alpha* and *HIF2\alpha*) carrying a higher risk of metastatic disease than those due to other mutations (supplementary Table S4, available at <https://doi.org/10.1016/j.annonc.2020.08.2099>). Risk is particularly high, reaching 70% in patients with PPGL due to mutations in the *SDHB* gene.³⁴ The vast majority of all metastatic PPGLs, including

disease due to *SDHB* mutations, develop from noradrenergic or dopaminergic PPGLs with poorly developed secretory pathways. Nevertheless, a small minority of about 10% of metastatic PPGLs develop from adrenal adrenergic tumours that are characterised by production of epinephrine, as manifested by increased plasma or urinary metanephrine.³⁵

Of note, metastatic disease may only become apparent many years after the primary tumour is resected. This and later development in some patients of locally recurrent disease underscore the importance of recommendations for follow-up of all patients with previously resected PPGLs.⁹

Recommendations

- All patients with an adrenal tumour suspected to be an ACC or a phaeochromocytoma should undergo careful clinical assessment for signs of adrenal hormone excess.
- All patients with suspected and proven ACC or PPGL should be discussed in a multidisciplinary expert team meeting, at least at the time of initial diagnosis and in case of progressive disease.
- All patients with suspected ACC require a comprehensive endocrine work-up to identify potential autonomous excess

of glucocorticoids, sex hormones, mineralocorticoids and adrenocortical steroid hormone precursors [IV, A].

- Standard imaging for patients with suspected ACC includes at least abdominal CT or MRI and chest CT (or [¹⁸F]FDG-PET/CT) [IV, A].
- Biopsies of suspected ACC are usually not informative and should be avoided.
- Histopathologically, ACC is defined by a Weiss score ≥ 3 [IV, A]. Histological diagnosis should be carried out by an experienced endocrine pathologist. Ki-67 index helps to stratify the risk of recurrence.
- All patients with suspected PPGL require the measurement of plasma or urinary metanephrines [V, A]. Suspicion of disease is primarily based on (i) the presence of signs, symptoms or other manifestations of presumed catecholamine excess; (ii) incidental adrenal mass; or (iii) routine screening due to high risk associated with hereditary predisposition or history of PPGLs.
- In all patients with 'high risk of metastases' (see definition above), a chest CT and at least one functional whole-body imaging [e.g. FDG-PET, DOTATATE-PET, iodine-123 meta-iodobenzylguanidine ([¹²³I]MIBG) scintigraphy] is recommended in addition to abdominal imaging.
- Biopsies of suspected PPGL are contraindicated in most circumstances.
- Malignant PPGLs are defined by the presence of metastasis. However, all PPGLs are considered to have some malignant potential.

STAGING AND RISK ASSESSMENT

ACC

In the assessment of disease stage, the authors recommend the tumour, node, metastasis (TNM) classification proposed by the European Network for the Study of Adrenal Tumours (ENSAT) (supplementary Table S5, available at <https://doi.org/10.1016/j.annonc.2020.08.2099>) [IV, A],³⁶ because this system seems to be superior to other staging systems and is adapted by the Union for International Cancer Control (UICC) and WHO.²⁴ As indicated above for correct staging, at least a CT of the chest, abdomen and pelvis (or FDG-PET/CT including full-dose CT) is required. Recent data suggest that lymph node involvement correlates with stage IV rather than stage III behaviour.³⁷

Overall, the prognosis of ACC is limited. However, prospective data suggest that in patients with complete resection of a localised stage II tumour 5-year overall survival (OS) can be as high as 90%.³⁸ In metastatic ACC, median survival is about 15 months. However, even in this group, there is a subgroup of patients with long-term survival.^{36,37}

It is well established that disease stage and margin-free resection are currently the most important prognostic factors in ACC. For the European Society of Endocrinology (ESE)—ENSAT guidelines, a comprehensive literature search for prognostic factors has been carried out and only the

proliferation marker Ki-67 and glucocorticoid excess showed a robust association with prognosis [IV, A] (supplementary Table S2, available at <https://doi.org/10.1016/j.annonc.2020.08.2099>).^{4,39} Many other (molecular) markers for aggressiveness and survival have been recently proposed, but their clinical use requires validation.

PPGL

In 2017, the WHO proposed a tumour staging system for PPGL (supplementary Table S6, available at <https://doi.org/10.1016/j.annonc.2020.08.2099>).²⁴ Although this staging classification remains to be validated, the authors recommend using this system to harmonise disease classification.

Despite limitations, the authors suggest assessing the risk of metastatic disease in an individualised manner, taking into account previous history of disease and the presence or absence of a germline mutation of a tumour-susceptibility gene (supplementary Table S4, available at <https://doi.org/10.1016/j.annonc.2020.08.2099>). For first-time patients without any history of disease or known mutation, size and location of the primary tumour, and when available, any elevations of plasma methoxytyramine during biochemical testing seem important to consider when evaluating risk for malignancy. As described above, the authors suggest establishing 'high risk of metastases' when any patient presents with one or more of the following criteria: (i) adrenal pheochromocytoma ≥ 5 cm; (ii) an extra-adrenal paraganglioma; (iii) a known *SDHB* germline mutation; or (iv) plasma methoxytyramine more than threefold above the upper limit of reference intervals. In these patients, whole-body functional imaging may be justified, particularly for cases involving more than one of those four criteria.

Recommendations

- The ENSAT TNM system should be used for initial staging of ACC [IV, A].
- Genetic counselling should be offered to all patients with PPGL.

MANAGEMENT OF LOCOREGIONAL DISEASE

Surgery

Surgery is essential for treatment of both ACC and pheochromocytoma. Adrenal surgery should be carried out only by surgeons with appropriate expertise and experience. The lack of consensus on what is defined as appropriate experience and the absence of evidence that a specific experience in adrenal surgery translates into improved outcomes limit any recommendations concerning this issue.⁴⁰⁻⁴² The recent ESE—ENSAT guidelines on ACC suggest a minimal annual workload of six adrenalectomies per year, but with a preference for >20 surgeries per year. In addition to expertise in adrenal surgery, sufficient experience in oncological surgery is essential [V, B].⁴ For best clinical outcome, the entire operative team (including anaesthesiologists) should be well-trained in adrenal surgery.

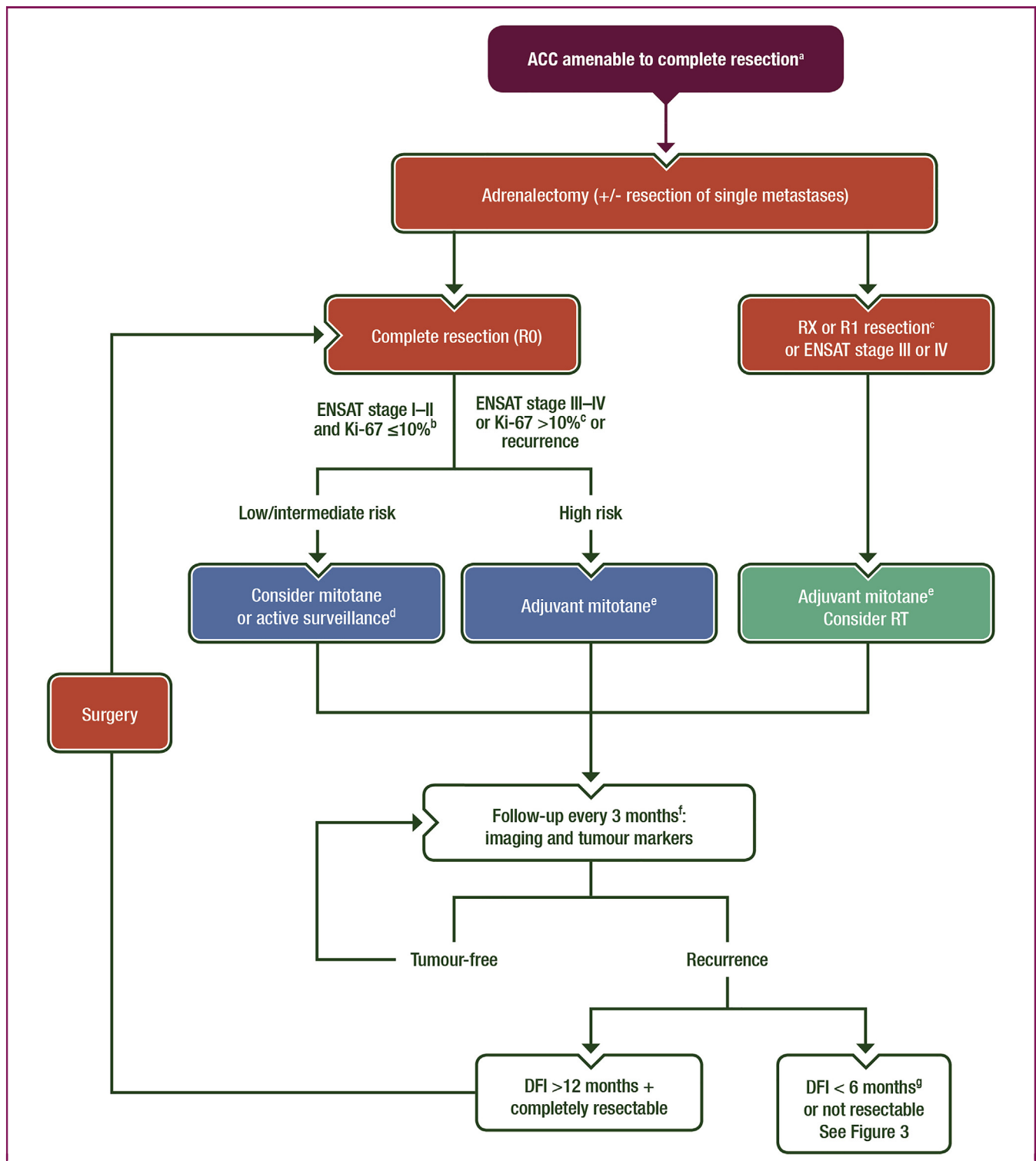


Figure 1. Treatment of ACC amenable to complete resection.

ACC, adrenocortical carcinoma; DFI, disease-free interval between complete resection and recurrence; EDP, etoposide, doxorubicin and cisplatin; ENSAT, European Network for the Study of Adrenal Tumours; HPF, high-power field; R0, no tumour at the margin; R1, microscopic tumour at the margin; R2, macroscopic tumour at the margin; RT, radiotherapy; RX, status of resection margins unknown.

Always consider clinical trials.

^a All patients with ENSAT stage I-II and most patients with stage III should be amenable to radical resection. If complete resection is not feasible, consider neoadjuvant treatment (e.g. mitotane plus cisplatin or EDP). In selected patients with single metastases, complete resection might be possible as well.

^b In patients with R2 resection, consider resurgery by an expert surgeon or see Figure 3.

^c If Ki-67 staining is not available, a low (<20 mitoses/50 HPF) or a high mitotic rate (>20 mitoses/50 HPF) may be used for risk stratification.

^d Individual decision.

^e In some patients (e.g. Ki-67 index >30%, large tumour thrombus in the vena cava, stage IV or R1 resection), consider additional cytotoxic therapy (e.g. 4 cycles of cisplatin plus etoposide).

^f After 2 years, the time intervals are gradually extended.

^g If the DFI is between 6 and 12 months, or in patients with DFI >12 months, in whom complete resection is not possible, an individual approach is required.

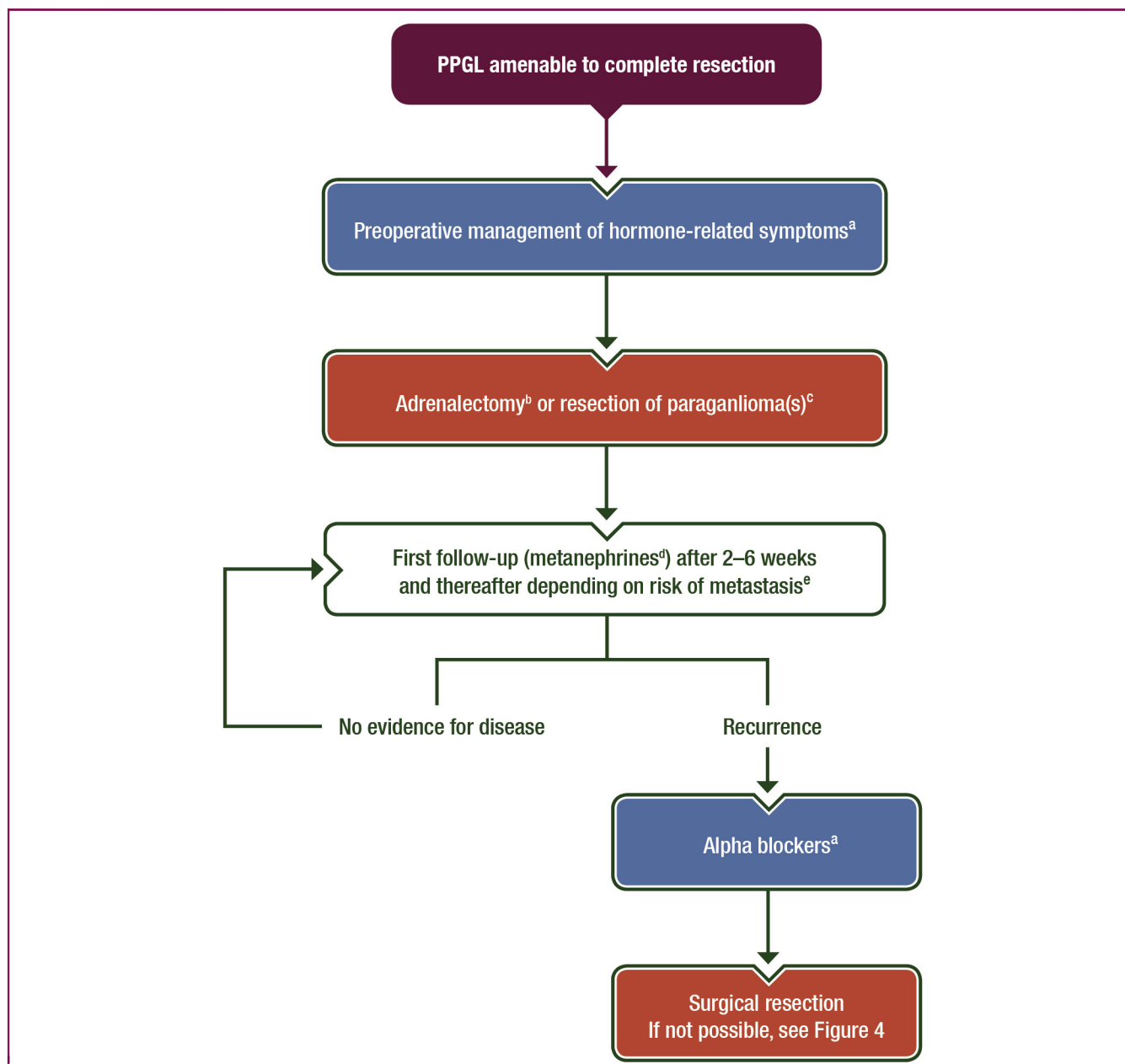


Figure 2. Treatment of PPGL amenable to complete resection.

PPGL, phaeochromocytoma and paraganglioma.

^a Usually 10–14 days of pretreatment with alpha blockers is recommended; alternatively, treatment with calcium antagonists is an option. In addition, constipation should be treated (or prevented).

^b In most cases, laparoscopic adrenalectomy is feasible.

^c Specific anaesthetic considerations are required (see text).

^d Biochemical testing repeated ~2–6 weeks following surgery should exclude remaining disease.

^e The majority of authors recommend carrying out annual measurement of metanephrines and performing imaging only if one of these parameters is elevated. However, some authors recommend carrying out additional regular imaging (see text for details).

ACC. Open surgery with transperitoneal access is the standard treatment for all patients with localised (stage I–II) and locally advanced (stage III) ACC when complete resection can be achieved (Figure 1).^{4,43} Resection status (R0, R1, R2) is a major predictor of prognosis for ACC. Therefore, a margin-free complete resection (R0 resection) is key to achieving long-term survival [V, A].^{2,44} In order to obtain an R0 resection of a locally advanced ACC, it may be necessary to resect (parts of) adjacent organs such as the wall of the

vena cava, liver, spleen, colon, pancreas and/or stomach [V, B]. Complete *en bloc* resection of the tumoural mass, including perirenal fat and adjacent organs if necessary, is mandatory to avoid tumour rupture or spillage that portends an adverse outcome.⁴⁵ Locoregional lymphadenectomy improves tumour staging and seems to lead to a favourable oncological outcome.⁴⁶

Routine lymphadenectomy should include at least the perirenal and hilar nodes [IV, A], although the best extent

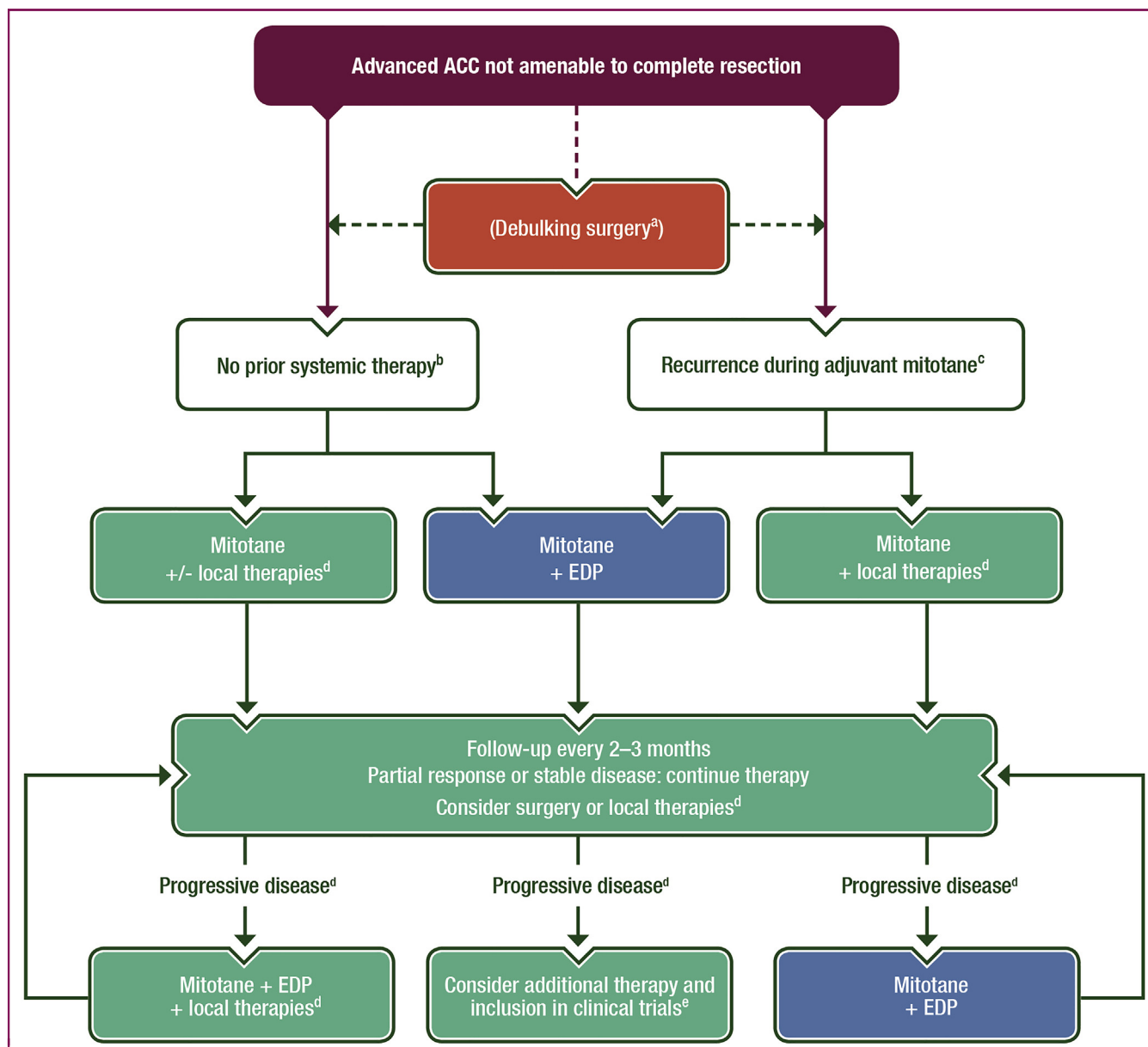


Figure 3. Treatment of advanced ACC.

ACC, adrenocortical carcinoma; EDP, etoposide, doxorubicin, cisplatin; RFA, radiofrequency ablation; RT, radiotherapy.

Always consider clinical trials.

^a Only in selected patients (e.g. with severe hormone excess).

^b The following factors might guide the decision: site of disease involvement, tumour burden, symptoms, tumour grade/Ki-67 index.

^c The following factors might guide the decision: site of disease involvement, tumour burden, symptoms, tumour grade/Ki-67 index, and importantly kinetics of tumour growth.

^d RT, RFA, cryoablation, microwave ablation, (chemo-)embolisation.

^e For the currently available cytotoxic regimens, see [Supplementary Table S8](https://doi.org/10.1016/j.annonc.2020.08.2099), available at <https://doi.org/10.1016/j.annonc.2020.08.2099>, and contact a specialised centre.

of lymphadenectomy is still unknown.⁴⁷ For ACC tumours not invading the kidney, concomitant nephrectomy does not seem to improve disease-free survival and OS⁴⁸ and can be avoided, although additional data are needed [V, B].

In experienced hands, laparoscopic adrenalectomy seems to be a safe and effective procedure in a selected group of patients with small ACC without evidence for local invasiveness,^{4,43} although this is still a matter of debate because prospective comparative studies are scarce. In current practice, adrenal masses (e.g. incidentalomas) that are

judged as only potentially malignant are often approached by laparoscopic adrenalectomy. However, this technique must be carried out only in centres with consolidated experience in laparoscopic adrenal surgery, in which the principles of oncological surgical treatment are strictly respected and prospective registration of cases is organised [IV, C].^{4,43} There is no evidence for the superiority of the transperitoneal over the retroperitoneal approach in the literature. If during laparoscopic surgery, an involvement of the surrounding tissues is discovered, or there is a risk of

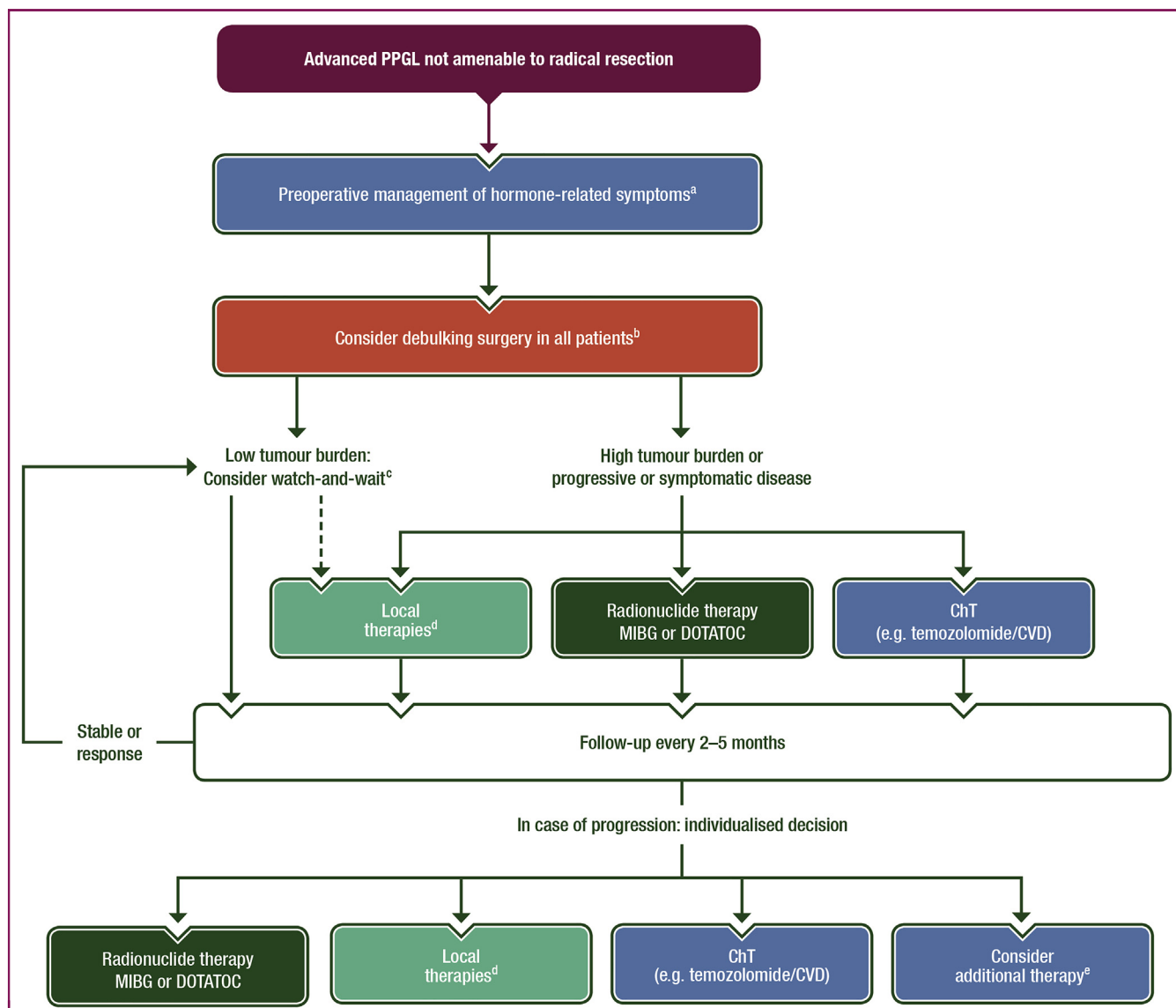


Figure 4. Treatment of advanced PPGL.

ChT, chemotherapy; CVD, cyclophosphamide, vincristine, doxorubicin; MIBG, meta-iodobenzylguanidine; PPGL, pheochromocytoma and paraganglioma; RFA, radiofrequency ablation; RT, radiotherapy.

Always consider clinical trials.

^a Usually, the first-choice treatment is therapy with alpha blockers; alternatively, treatment with calcium antagonists is an option. In addition, constipation should be treated (or prevented).

^b In PPGL, debulking surgery is frequently able to control symptoms much easier and should always be considered.

^c A subset of PPGLs behave very indolent and might be stable for many months/years. Blood pressure should be controlled by alpha blocker (if required).

^d RT, RFA, cryoablation, microwave ablation, (chemo)embolisation, palliative surgery.

^e Contact a specialised centre.

spillage, capsule injury or incomplete resection, immediate conversion to an open approach is required.⁴³

As hormonal hypersecretion can increase the risk of perioperative complications, it is important to adopt measures to prevent postoperative adrenal crisis or insufficiency. In all patients with glucocorticoid excess, either overt or 'subclinical', hydrocortisone must be administered during surgery (e.g. 150 mg/day) and postoperatively [V, A].⁴ Hormone hypersecretion, in particular cortisol excess, may portend an increased risk of recurrence after complete tumour removal.^{39,49}

Adjuvant treatment

More than half of the ACC patients who have undergone complete removal of the tumour have a relapse risk, often with metastases. This aggressive behaviour provides the rationale for the use of adjuvant therapy. Mitotane has been the reference drug for the management of ACC for decades and is increasingly used also in adjuvant settings following surgical removal of ACC. However, the value of this approach remains a matter of controversy because only a few studies have compared sufficiently large cohorts of treated and control patients.⁴ All were retrospective and

potentially confounded by treatment choice based on prognosis, thereby introducing imbalance in prognostic factors among groups. One study with 207 patients (including 88 with mitotane) found that adjuvant mitotane was associated with worse recurrence-free survival (RFS)⁵⁰; however, the mitotane group was likely selected for a higher risk of recurrence, a bias that cannot be fully adjusted for in multivariate analysis.

Probably, the best evidence supporting adjuvant mitotane use comes from a multicentre, case-control study that circumvented confounders by comparing patient groups treated at centres adopting two different treatment strategies. The study involved 177 patients, of whom 47 were followed in Italian reference centres that systematically adopted adjuvant mitotane to all radically operated ACC. Fifty-five Italian patients and 75 German patients were followed in institutions not administering adjuvant mitotane therapy.⁵¹ The outcome of this cohort has been recently updated, confirming that the mitotane-treated patients have prolonged RFS compared with patients left untreated after surgery.⁵²

Two recent meta-analyses have reported that adjuvant mitotane treatment reduces the risk of recurrence and death.^{4,53} In both analyses, the benefit associated with mitotane was significant for OS, whereas it was significant for RFS in only one study.⁵³ Another retrospective multicentre study demonstrated that blood mitotane concentrations ≥ 14 mg/l were associated with a prolonged RFS in patients treated with adjuvant mitotane following macroscopically radical surgery.⁵⁴ On these bases, the recent ESE–ENSAT guidelines on the management of ACC suggest that patients at high risk of recurrence (stage III, or R1-RX resection, and/or Ki-67 index $>10\%$) should be offered adjuvant mitotane [IV, B].⁴ By contrast, adjuvant therapy has to be discussed on an individual basis in patients fulfilling all the following criteria: stage I or II disease, histologically proven R0 resection and Ki-67 expressed in $\leq 10\%$ of neoplastic cells, which define the category of low risk of recurrence [V, B] (Figure 1).⁴ For these patients, the results of the still ongoing randomised ADIUVO trial⁵⁵ testing the efficacy of adjuvant mitotane therapy are awaited.

There are no data regarding the optimal duration of adjuvant mitotane; however, the authors recommend that adjuvant mitotane should be administered for at least 2 years [V, B], because the greatest frequency of disease recurrence is expected within this time frame. However, it is not advised to continue adjuvant mitotane beyond 5 years, due to the low number of ACC recurrences occurring after this time [V, B].⁴

Adjuvant radiotherapy (RT) is able to reduce the risk of local recurrence but does not prevent distant recurrences and, as a consequence, does not impact OS.⁴ Therefore, it is reasonable to associate mitotane with RT in selected patients with stage III ACC and/or R1 or RX resection, although the combination carries increased toxicity [IV, B].⁴

The adjuvant use of cytotoxic drugs is not well established in ACC. Nevertheless, some centres are beginning to apply cytotoxic drugs (e.g. cisplatin plus etoposide) in selected patients with very high risk of recurrence and this approach is being investigated in a randomised trial (NCT03583710).

Special considerations on mitotane. Mitotane is a difficult drug to manage, with a long half-life, dose-limiting toxicity and a narrow therapeutic window. Supplementary Table S7, available at <https://doi.org/10.1016/j.annonc.2020.08.2099> summarises the key features of mitotane therapy.

PPGL. As in ACC, the surgical excision of the tumour is the first-line treatment of PPGLs (Figure 2). However, laparoscopic/minimal invasive surgery is commonly the technique of first choice for resection adrenal and extra-adrenal PPGLs [V, A], because local invasion is rare and the likelihood of rupture of the capsule seems less common than in ACC. It is obvious, however, that the resection should be complete and if there is any risk that this cannot be achieved by laparoscopic surgery, an open approach should be carried out. In patients with PPGL, exposure to high levels of circulating catecholamines during surgery could cause hypertensive crises and arrhythmias. Therefore, all patients with PPGL should receive preoperative preparation at least 10–14 days before surgery [V, A].⁵ Blood pressure targets for the treatment are $<130/80$ mmHg in the supine position, and a systolic blood pressure preferably >90 mmHg in the upright position. The noncompetitive α -adrenoreceptor antagonist, phenoxybenzamine, is traditionally the most frequently used adrenergic blocking agent. A standard starting dose is 10 mg twice daily with adjustments over the following days. Alternatively, doxazosin, a competitive and selective α_1 -adrenoreceptor antagonist, can be similarly effective. If the target blood pressure is not reached, calcium antagonists (slow-release nifedipine) or metyrosine may be used. Blockade of β -adrenergic receptors is indicated in patients developing tachyarrhythmias but should never be started before blockade of α -receptors.

Given the likelihood of rapid intraoperative haemodynamic lability, continuous monitoring of arterial and central venous pressures is essential throughout surgery. Although today's volatile anaesthetics are not inductive of hypertensive crisis, such crises can be induced by other manipulations during surgical procedure (e.g. intubation, insufflation of peritoneum, direct palpation of the PPGL) or administration of certain drugs (e.g. opioids, benzodiazepines).⁵⁶ Therefore, it is strongly recommended that anaesthesia is supervised by an experienced anaesthesiologist alert to the diagnosis of a catecholamine-producing tumour. Hypertension during surgery may be treated with magnesium sulfate, intravenous α -adrenoreceptor antagonists (e.g. phentolamine), calcium antagonists and/or nitroprusside or nitroglycerine. Tachycardia can be treated with intravenous β -adrenergic receptor blockers (e.g. esmolol). Postoperative hypotension should be prevented by saline infusion the day before surgery. If this adverse event occurs, it should be treated aggressively. In general, sufficient rehydration and treatment of constipation are important parts of the preoperative management. Postoperative care should also focus on glucose levels because hypoglycaemia may occur after reduction of catecholamine levels. Cytoreductive debulking surgery (R2) in malignant pheochromocytoma may improve QoL and survival by reducing tumour burden and controlling hormonal hypersecretion [V, B].³

Despite a recurrence risk, there is no established indication of adjuvant treatment in PPGLs. In one series of 171 patients followed up after surgical resection, 29 patients (17%) had recurrent or new tumours which were malignant in 15 cases (9%).⁶

Recommendations

ACC

- Complete *en bloc* resection of all adrenal tumours suspected to be ACC by a surgeon experienced in adrenal and oncological surgery is the mainstay of a potentially curative approach. Open surgery is the standard treatment but in tumours <6 cm without evidence of local invasion, laparoscopic adrenalectomy is reasonable, if the surgeon has sufficient experience.
- Additionally, a locoregional lymphadenectomy is suggested.
- Perioperative hydrocortisone replacement is required in all patients with autonomous cortisol secretion [V, A].
- Adjuvant mitotane is recommended in patients at high risk of recurrence (stage III, or R1-RX resection, and/or Ki-67 index >10%) [IV, B].
- Adjuvant therapy has to be discussed on an individual basis in patients with low risk of recurrence (stage I/II, R0 resection and Ki-67 index ≤10%) [V, B].
- Adjuvant RT is only suggested on an individualised basis (in addition to mitotane) in patients with R1 or RX resection or in stage III [IV, B].
- After complete resection, radiological imaging every 3 months for 2 years, then every 3-6 months for at least another 3 years is recommended [V, B].

PPGL

- Most PPGLs can be safely removed laparoscopically by an experienced surgeon [V, A].
- Preoperatively, patients should be treated for 10-14 days with an alpha blocker (e.g. phenoxybenzamine) [V, A].
- Meticulous perioperative management of hormonal, glucose, electrolytes, cardiac and fluid/blood pressure abnormalities is a critical component of patient care.
- Patients with resected PPGL should be followed at regular intervals for at least 10 years (lifelong for patients with a germline mutation). Most authors recommend only annual measurement of metanephrines in most patients, but some authors carry out additionally regular imaging.

MANAGEMENT OF ADVANCED/METASTATIC DISEASE

ACC

Prognosis of advanced ACC patients is limited, the 5-year OS being <15%. However, several studies have highlighted considerable heterogeneity in survival. Indeed, prolonged survival has been reported especially in patients with

resectable oligometastatic disease, with long intervals between recurrences.^{57,58}

In general, first-line therapy in patients with advanced/metastatic disease is mitotane alone or mitotane plus chemotherapy (ChT). Surgery and locoregional therapies should be adopted in addition to systemic therapy in selected patient populations (Figure 3). The goal of the therapy is to control tumour growth, hypersecretion-related symptoms and prolong survival.

A study of the ENSAT network recently identified the prognostic factors in patients with advanced disease. Accordingly the stage, as redefined by a modified ENSAT (mENSAT) classification,³⁷ which takes into account the number of tumoural organs, has a major prognostic role together with the following four parameters grouped under the label GRAS: (i) tumour Grade, (ii) Resection status of the primary tumour, (iii) Age, and (iv) tumour-related or hormone-related Symptoms. Based on these results, a risk stratification was introduced.⁵⁹ Although this new risk classification looks interesting, it needs confirmation in other studies before being fully applicable in clinics.

Mitotane monotherapy. Mitotane is the only drug approved by the European Medicines Agency (EMA) in locally advanced inoperable and metastatic patients (supplementary Table S8, available at <https://doi.org/10.1016/j.annonc.2020.08.2099>); nevertheless, randomised controlled prospective trials are lacking. Response rates in metastatic ACC vary between 13% and 35% but much of these data are derived from retrospective series, including studies in 1960s with overall variability in response criteria.⁴ For details on mitotane management, see above and supplementary Table S7, available at <https://doi.org/10.1016/j.annonc.2020.08.2099>. Owing to the latency of mitotane to attain the therapeutic range, mitotane monotherapy is indicated in the management of patients with a low tumour burden and/or more indolent disease (i.e. patients with favourable prognostic parameters). At disease progression, ChT with etoposide, doxorubicin and cisplatin (EDP) should be added to mitotane monotherapy [I, A].

Cytotoxic ChT. The combination of EDP and mitotane (EDP-M) is recommended in first-line settings based on the FIRM-ACT trial results [I, A] (supplementary Table S8, available at <https://doi.org/10.1016/j.annonc.2020.08.2099> and Figure 3). In the phase III randomised trial including 304 patients, progression-free survival (PFS) was clearly superior in patients treated with EDP-M compared with patients treated with streptozocin plus mitotane [5.0 versus 2.1 months, hazard ratio (HR) 0.55, 95% confidence interval (CI) 0.43-0.69, $P < 0.001$].⁶⁰ However, the difference in OS was not significant (14.8 versus 12.0 months, HR 0.79, 95% CI 0.61-1.02, $P = 0.07$), presumably due to the crossover and presence of mitotane in both arms. Interestingly, a survival advantage of the EDP-M arm was observed in patients, who could not receive the second-line therapy. In patients unsuitable for EDP-M, mitotane in combination with etoposide and cisplatin [V, B],⁶¹ or mitotane plus cisplatin, is an option [V, B].⁶²

In second-line settings, after failure of EDP-M, the treatment options are limited⁶³ and enrolment of patients into clinical trials should be considered first. Most patients with advanced ACC remain in good clinical condition but urgently seek therapy. In the absence of trials, possible options are the association of gemcitabine plus capecitabine^{64,65} or streptozocin (supplementary Table S8, available at <https://doi.org/10.1016/j.annonc.2020.08.2099>).⁶⁰ With both treatments, the median PFS is short, between 2 and 4 months. Mitotane therapy is sometimes continued in association with second-line therapies. However, this must be discussed with the patient according to tolerance to the drug and its effect on hormonal secretion. The optimal timing to discontinue mitotane is debated and could be discussed with the patient individually in cases of progressive disease despite 'therapeutic' drug levels or highest tolerated doses assessed at two distinct evaluations.

Surgery and local therapies. Surgery, including surgery of the primary tumour, may be recommended in all patients with oligometastatic ACC if a complete resection of all tumoural lesions is feasible [V, B].⁴ Additionally, patients with an indolent disease course or under therapeutic control might be eligible for surgery. It is also worthwhile to consider surgery or other local therapies in all patients in whom systemic therapy led to an objective response or long-term stable disease [V, B].^{66,67} A cytoreductive resection may also be indicated in rare cases of severe symptomatic hormone excess, after attempts to control the symptoms with a combination of fast-acting anti-secretory agents (i.e. metyrapone) and mitotane⁶⁸ and local therapies [V, B]. In these patients, postoperative mitotane is clearly advised [V, A]. Local therapies [e.g. RT, chemoembolisation, radiofrequency ablation (RFA)] should also be discussed in all patients with advanced oligometastatic ACC [V, B].⁴

In case of a recurrence following ACC surgery, two critical questions must be addressed: (i) What is the time interval since the resection? and (ii) Did recurrence occur during ongoing mitotane therapy (with effective blood levels)? If the disease-free interval is at least 12 months and another complete R0 resection/ablation seems feasible, then surgery or, alternatively, other local therapies are clearly recommended [IV, A].^{69,70} However, if this time interval is <6 months or if complete resection/ablation is not feasible, then, the EDP-M provides the treatment of choice, especially if the recurrence occurred during ongoing mitotane treatment at therapeutic levels [IV, A].

Molecular-targeted therapies and immunotherapy. Several tyrosine kinase inhibitors (TKIs) have been investigated as second-line approaches in small phase II trials involving advanced ACC (for review, see^{4,71}). Results, however, have failed to show significant therapeutic efficacy. In addition, the insulin-like growth factor 1 receptor (IGF1R) inhibitor linsitinib was tested in a multicentre placebo-controlled phase III trial (GALACTIC trial) and failed to improve either PFS or OS of advanced ACC patients who had already received systemic antineoplastic therapies.⁷²

The results of the first (small) trials with immune checkpoint inhibitors in ACC were heterogeneous, with median PFS times of 1.8, 2.1, 2.6 and 6.75 months, respectively.⁷³⁻⁷⁶ However, in one study with 39 patients, disease control rate was 52% and median OS reached almost 25 months, clearly suggesting that a least a subset of patients benefits from this therapeutic approach.⁷⁶

Management of hormone excess. In addition to sequelae of the malignant disease, patients with overt hypercortisolism suffer from immunosuppression, diabetes and muscle weakness, which can significantly impact QoL. Similarly, severe androgen excess may dramatically impair well-being in women. Therefore, medical therapy to control hormonal excess is recommended [V, A]. Mitotane is frequently able to diminish steroid excess, but its efficacy is often delayed by several weeks. In these circumstances, steroidogenic enzyme inhibitors, such as metyrapone or ketoconazole, can be useful [V, B]. Metyrapone is a well-tolerated drug and its metabolism and elimination are not altered by concomitant mitotane. Therefore, it can be safely administered in association with mitotane and cytotoxic ChT.⁶⁸ Local therapies including liver embolisation may also be discussed. All patients with clinically overt hormone excess should be managed by physicians experienced with these endocrine problems.

PPGLs

The therapeutic strategy for metastatic PPGL primarily aims to control excessive catecholamine secretion and tumour burden, as there are no curative treatment options. Choices for treatment include a watch-and-wait policy (including alpha blocker to control hypertension), locoregional therapies, radiopharmaceutical agents, systemic ChT and molecular-targeted therapies (Figure 4, supplementary Table S9, available at <https://doi.org/10.1016/j.annonc.2020.08.2099>). Such choices should be discussed case by case in a multidisciplinary specialised setting. In the absence of any published randomised trials and demonstrated impact on survival, QoL for patients should always be considered in any justification for a specific therapeutic intervention. Indeed, due to the indolent course of disease in some patients,⁷⁷ an active surveillance policy may be indicated for those who are asymptomatic, have a low-to-intermediate tumour burden and absence of localised complications of any mass. In these patients, treatment-related adverse events may exceed any benefit of therapy.

Surgery. Although there is little possibility of a cure for metastatic PPGLs, surgical resection of the primary tumour or metastatic lesions should be considered on a case-by-case basis. Debulking surgery can improve symptoms and potentially prognosis by reducing secretion of catecholamines.⁷⁸ Other local therapies are available for patients with metastases, such as RT, RFA or chemoembolisation. Local measures are also important to prevent bone-related events.⁷⁹ However, as with any invasive procedure, local ablation may induce massive tumoural catecholamine

release, leading to hypertensive complications; thus, the same medical preparation is required as for surgical interventions (see above).⁸⁰

Radionuclide therapy. Radionuclide therapy is an effective treatment and [¹³¹I]MIBG is one of the most frequent approaches with radionuclide doses ranging widely from 5.5 to 38 GBq (150–1000 mCi). Approximately 50% of patients are eligible for [¹³¹I]MIBG therapy based on uptake from diagnostic scans. Several studies have been published on the efficacy of [¹³¹I]MIBG treatment,³ mostly retrospective and only two prospective phase II trials.^{81,82} In both trials, objective responses were observed in 23% of cases according to Response Evaluation Criteria in Solid Tumours. Long-term survival of responders of over 6 years has been reported but progression at study entry was not a prerequisite for most studies. Objective responses were mainly observed in patients with soft tissue metastases. Grade 3–4 toxicity was reported in 16%–83% of patients, mainly haematological including myelodysplastic syndrome especially with high activity doses.^{3,82} [¹³¹I]MIBG therapy could be considered as first-line approach in patients displaying avid uptake of [¹²³I]MIBG in all tumoural lesions who have unresectable, progressive PPGL or high tumour burden [III, A].

An alternative approach is a peptide receptor radioligand therapy using somatostatin analogues labelled with isotopes delivering a cytotoxic radionuclide. More than 80% of PPGLs are detectable by somatostatin-based imaging.⁸³ In patients with high uptake of PET tracers, such as gallium-68 (⁶⁸Ga)-labelled somatostatin analogues (e.g. [⁶⁸Ga]DOTA-TATE or DOTATOC or DOTANOC), treatment with yttrium-90-labelled [⁹⁰Y]DOTATOC or lutetium-177-labelled [¹⁷⁷Lu]DOTATATE could be similarly effective as MIBG-based therapy, although the number of published studies/case series is limited [V, B].⁸⁴ Both radionuclide approaches can be applied repeatedly (with a minimum time interval of 3–4 months). However, toxicity frequently becomes a limiting factor over time and benefit should be re-evaluated after every second therapy.

Systemic ChT. Systemic ChT might be considered as a first-line treatment in patients with PPGL who have no significant uptake of radiotracers or that are also rapidly progressing and associated with high tumour burden or are highly symptomatic [IV, B]. ChT with cyclophosphamide- and dacarbazine-based regimens combined with vincristine (CVD) and/or doxorubicin (CVDD or CDD) are the most studied regimens.⁸⁵ In the largest published study to date ($n = 52$ patients), 40% of patients treated with CVD, CDD or CVDD experienced clinical benefit, including reduction in tumour size in 25% of cases.⁸⁶ Based on retrospective data, temozolomide, an oral alternative to dacarbazine, seems to be as effective as the previous polyChT regimens.⁸⁷ These studies suggest that patients with *SDHB* mutations are especially sensitive to temozolomide due to the association with hypermethylation of the promoter for O6-methylguanine-DNA methyltransferase (MGMT). Furthermore, recent case

reports provide limited evidence that metronomic temozolomide is also effective as a second-line therapy.⁸⁸

Targeted therapies. There is a rationale and some evidence on the potential efficacy of antiangiogenic drugs in malignant pheochromocytomas, especially those bearing *SDHB* gene mutations.⁸⁹ Sunitinib is a potent TKI, including vascular endothelial growth factor receptors (VEGFRs) 1 and 2, platelet-derived growth factor receptor (PDGFR) beta, KIT, FLT3 and RET, and has been the most-studied targeted therapy in PPGL. In addition to several impressive case reports involving sunitinib, there is one retrospective series with 17 patients with progressive metastatic PPGL.⁹⁰ Of 14 evaluable patients, three had a partial response (21%) and five had stable disease (36%). Median PFS was 4.1 months and OS 27 months. As hypertension is a key feature of PPGL and a major adverse event of sunitinib, special attention is required to deal with this issue. There are currently several ongoing trials on sunitinib including a randomised, placebo-controlled trial testing sunitinib in patients with malignant PPGL, now closed for recruitment (FIRST-MAPPP trial, NCT01371201).

A phase II study with pazopanib involving seven patients (study closed because of poor accrual) reported one confirmed partial response (17%, duration 2.4 years) and median PFS and OS of 6.5 and 14.8 months, respectively.⁹¹

Recommendations

ACC

- In most patients with metastatic ACC, first-line therapy with mitotane alone or mitotane plus ChT is recommended; EDP-M is the first-line treatment of choice [I, A].
- In selected patients (e.g. low tumour burden and/or more indolent disease), mitotane monotherapy is reasonable.
- Surgery and locoregional therapies should be adopted in addition to systemic therapy in selected patient populations.
- Surgery is the treatment of choice only if all tumoural lesions can be removed [V, B].
- Local therapies (e.g. RT, RFA, cryoablation, microwave ablation, chemoembolisation) are of value for therapy in advanced ACC, and an individualised treatment approach is required [V, B].

PPGL

- Although there are no curative treatment options, treatment choices include watch-and-wait, locoregional therapies, radiopharmaceutical agents, systemic ChT and molecular-targeted therapies.
- In selected patients (e.g. with low tumour burden without relevant symptoms), a watch-and-wait policy (including alpha blocker to control hypertension) is preferred.
- In all patients with metastatic PPGL (debulking) surgery should be considered.

- In patients with relevant symptoms, high tumour burden or progressive disease, locoregional therapies, radiopharmaceutical agents (e.g. [¹²³I]MIBG [III, A] or radiolabelled somatostatin analogues [V, B]) or systemic ChT [IV, B] should be applied in a case-by-case manner. The follow-up of patients with inoperable disease should be carried out every 3-6 months during the first year (imaging plus metanephrines) and then adjusted afterward.

FOLLOW-UP, LONG-TERM IMPLICATIONS AND SURVIVORSHIP

Studies focusing on strategies for surveillance are lacking for ACC and PPGL. In these guidelines, we follow the recommendations provided recently by other groups.^{4,9} For locally advanced or metastatic disease, OS and time-to-progression are the most important end points, response rate and treatment toxicity providing secondary end points. Time-to-progression, ORR and treatment toxicity guide clinical decision making in individual patients; they should be evaluated at regular intervals during treatment using CT scans and/or MRI and laboratory results (supplementary File, available at <https://doi.org/10.1016/j.annonc.2020.08.2099>). For patients opting for entirely palliative management, no systematic imaging is advised. Information on long-term implications, patient experience, psychological implications and effect of rehabilitation is lacking for ACC and PPGL. At least, specific management of survivors should be based on individual needs and preferences.

METHODOLOGY

These Clinical Practice Guidelines have been produced by ESMO in partnership with EURACAN, the European Reference Network for rare adult solid cancers. These Clinical Practice Guidelines were developed in accordance with the ESMO standard operating procedures for Clinical Practice Guidelines development (<http://www.esmo.org/Guidelines/ESMO-Guidelines-Methodology>). They are conceived to provide the standard approach to diagnosis, treatment and survivorship on ACC and PPGL. Recommended interventions are intended to correspond to the 'standard' approaches, according to current consensus among the European multidisciplinary experts in the management of these extremely rare diseases. These are represented by the members of the ESMO Faculty and experts belonging to the Endocrine Tumour domain of EURACAN, the ENSAT and the European Reference Network on Rare Endocrine Conditions (Endo-ERN).

Experimental interventions considered to be beneficial are labelled as 'investigational'. Other nonstandard approaches may be proposed to the single patient as 'options' for a shared patient—physician decision in conditions of uncertainty, as long as some supporting evidence (though not conclusive) is available. Algorithms accompany the text, covering the main typical presentations of disease, and are meant to guide the user throughout the text. The relevant

literature has been selected by the expert authors. Levels of evidence and grades of recommendation have been applied using the system shown in supplementary Table S10, available at <https://doi.org/10.1016/j.annonc.2020.08.2099>.⁹² Statements without grading were considered justified standard clinical practice by the experts. This manuscript has been subjected to an anonymous peer review process.

ACKNOWLEDGEMENTS

The ESMO Guidelines Committee thank the ESMO Faculty and other experts who provided critical reviews of these ESMO Clinical Practice Guidelines. They also thank the European Cancer Patient Coalition and the following patient organisations for their review: BijnierNET/AdrenalNET.

FUNDING

No external funding has been received for the preparation of these guidelines. Production costs have been covered by ESMO from central funds.

DISCLOSURE

MF has declared conducting research sponsored by HRA Pharma, Millendo Therapeutics and Astellas Pharma; EB has declared participation as expert board and has received grants from HRA Pharma; HRH has received research support from HRA Pharma; MT has received honoraria and research grants from HRA Pharma; AB is currently conducting research sponsored by Ipsen and is a member of the speakers' bureau for Ipsen, Novartis and Advanced Accelerator Applications. GA, CdIF, GE, FP and Rdk have declared no potential conflicts of interest.

REFERENCES

1. Kerkhofs TM, Verhoeven RH, Van der Zwan JM, et al. Adrenocortical carcinoma: a population-based study on incidence and survival in the Netherlands since 1993. *Eur J Cancer*. 2013;49:2579-2586.
2. Kebebew E, Reiff E, Duh QY, et al. Extent of disease at presentation and outcome for adrenocortical carcinoma: have we made progress? *World J Surg*. 2006;30:872-878.
3. Pacak K, Eisenhofer G, Ahlman H, et al. Pheochromocytoma: recommendations for clinical practice from the First International Symposium. October 2005. *Nat Clin Pract Endocrinol Metab*. 2007;3:92-102.
4. Fassnacht M, Dekkers OM, Else T, et al. European Society of Endocrinology Clinical Practice Guidelines on the management of adrenocortical carcinoma in adults, in collaboration with the European Network for the Study of Adrenal Tumors. *Eur J Endocrinol*. 2018;179:G1-G46.
5. Lenders JW, Duh QY, Eisenhofer G, et al. Pheochromocytoma and paraganglioma: an endocrine society clinical practice guideline. *J Clin Endocrinol Metab*. 2014;99:1915-1942.
6. Amar L, Servais A, Gimenez-Roqueplo AP, et al. Year of diagnosis, features at presentation, and risk of recurrence in patients with pheochromocytoma or secreting paraganglioma. *J Clin Endocrinol Metab*. 2005;90:2110-2116.
7. Fassnacht M, Libe R, Kroiss M, Allolio B. Adrenocortical carcinoma: a clinician's update. *Nat Rev Endocrinol*. 2011;7:323-335.
8. Mansmann G, Lau J, Balk E, et al. The clinically inapparent adrenal mass: update in diagnosis and management. *Endocr Rev*. 2004;25:309-340.

9. Plouin PF, Amar L, Dekkers OM, et al. European Society of Endocrinology Clinical Practice Guideline for long-term follow-up of patients operated on for a pheochromocytoma or a paraganglioma. *Eur J Endocrinol.* 2016;174:G1-G10.
10. Fassnacht M, Arlt W, Bancos I, et al. Management of adrenal incidentalomas: European Society of Endocrinology Clinical Practice Guideline in collaboration with the European Network for the Study of Adrenal Tumors. *Eur J Endocrinol.* 2016;175:G1-G34.
11. Eisenhofer G, Lenders JW, Siegert G, et al. Plasma methoxytyramine: a novel biomarker of metastatic pheochromocytoma and paraganglioma in relation to established risk factors of tumour size, location and SDHB mutation status. *Eur J Cancer.* 2012;48:1739-1749.
12. Arlt W, Biehl M, Taylor AE, et al. Urine steroid metabolomics as a biomarker tool for detecting malignancy in adrenal tumors. *J Clin Endocrinol Metab.* 2011;96:3775-3784.
13. Taylor DR, Ghataore L, Couchman L, et al. A 13-steroid serum panel based on LC-MS/MS: use in detection of adrenocortical carcinoma. *Clin Chem.* 2017;63:1836-1846.
14. Hines JM, Bancos I, Bancos C, et al. High-resolution, accurate-mass (HRAM) mass spectrometry urine steroid profiling in the diagnosis of adrenal disorders. *Clin Chem.* 2017;63:1824-1835.
15. Schweitzer S, Kunz M, Kurlbaum M, et al. Plasma steroid metabolome profiling for the diagnosis of adrenocortical carcinoma. *Eur J Endocrinol.* 2018;180:117-125.
16. Kerkhofs TM, Kerstens MN, Kema IP, et al. Diagnostic value of urinary steroid profiling in the evaluation of adrenal tumors. *Horm Cancer.* 2015;6:168-175.
17. Dinnes J, Bancos I, Ferrante di Ruffano L, et al. Management of endocrine disease: imaging for the diagnosis of malignancy in incidentally discovered adrenal masses: a systematic review and meta-analysis. *Eur J Endocrinol.* 2016;175:R51-R64.
18. Weiss LM. Comparative histologic study of 43 metastasizing and non-metastasizing adrenocortical tumors. *Am J Surg Pathol.* 1984;8:163-169.
19. Weiss LM, Medeiros LJ, Vickery Jr AL. Pathologic features of prognostic significance in adrenocortical carcinoma. *Am J Surg Pathol.* 1989;13:202-206.
20. Thompson LD. Pheochromocytoma of the Adrenal gland Scaled Score (PASS) to separate benign from malignant neoplasms: a clinicopathologic and immunophenotypic study of 100 cases. *Am J Surg Pathol.* 2002;26:551-566.
21. Kimura N, Takayanagi R, Takizawa N, et al. Pathological grading for predicting metastasis in pheochromocytoma and paraganglioma. *Endocr Relat Cancer.* 2014;21:405-414.
22. Koh JM, Ahn SH, Kim H, et al. Validation of pathological grading systems for predicting metastatic potential in pheochromocytoma and paraganglioma. *PLoS One.* 2017;12:e0187398.
23. Pierre C, Agopianz M, Brunaud L, et al. COPPS, a composite score integrating pathological features, PS100 and SDHB losses, predicts the risk of metastasis and progression-free survival in pheochromocytomas/paragangliomas. *Virchows Arch.* 2019;474:721-734.
24. Lloyd RV, Osamura RY, Klöppel G, Rosai J. *WHO Classification of Tumours of Endocrine Organs.* Lyon, France: IARC; 2017.
25. Brouwers FM, Eisenhofer G, Tao JJ, et al. High frequency of SDHB germline mutations in patients with malignant catecholamine-producing paragangliomas: implications for genetic testing. *J Clin Endocrinol Metab.* 2006;91:4505-4509.
26. Jochmanova I, Yang C, Zhuang Z, Pacak K. Hypoxia-inducible factor signaling in pheochromocytoma: turning the rudder in the right direction. *J Natl Cancer Inst.* 2013;105:1270-1283.
27. Letouze E, Martinelli C, Loriot C, et al. SDH mutations establish a hypermethylator phenotype in paraganglioma. *Cancer Cell.* 2013;23:739-752.
28. Dahia PL. Pheochromocytoma and paraganglioma pathogenesis: learning from genetic heterogeneity. *Nat Rev Cancer.* 2014;14:108-119.
29. Neumann HP, Young Jr WF, Krauss T, et al. 65 years of the double helix: genetics informs precision practice in the diagnosis and management of pheochromocytoma. *Endocr Relat Cancer.* 2018;25:T201-T219.
30. Crona J, Taieb D, Pacak K. New perspectives on pheochromocytoma and paraganglioma: toward a molecular classification. *Endocr Rev.* 2017;38:489-515.
31. Toledo RA, Burnichon N, Cascon A, et al. Consensus statement on next-generation-sequencing-based diagnostic testing of hereditary pheochromocytomas and paragangliomas. *Nat Rev Endocrinol.* 2017;13:233-247.
32. Oudijk L, Gaal J, Koopman K, de Krijger RR. An update on the histology of pheochromocytomas: how does it relate to genetics? *Horm Metab Res.* 2019;51:403-413.
33. Crona J, Lamarca A, Ghosal S, et al. Genotype-phenotype correlations in pheochromocytoma and paraganglioma. *Endocr Relat Cancer.* 2019;26:539-550.
34. Amar L, Bertherat J, Baudin E, et al. Genetic testing in pheochromocytoma or functional paraganglioma. *J Clin Oncol.* 2005;23:8812-8818.
35. Sue M, Martucci V, Frey F, et al. Lack of utility of SDHB mutation testing in adrenergic metastatic pheochromocytoma. *Eur J Endocrinol.* 2015;172:89-95.
36. Fassnacht M, Johanssen S, Quinkler M, et al. Limited prognostic value of the 2004 International Union Against Cancer staging classification for adrenocortical carcinoma: proposal for a revised TNM classification. *Cancer.* 2009;115:243-250.
37. Libe R, Borget I, Ronchi CL, et al. Prognostic factors in stage III-IV adrenocortical carcinomas (ACC): an European Network for the Study of Adrenal Tumor (ENSAT) study. *Ann Oncol.* 2015;26:2119-2125.
38. Fassnacht M, Johanssen S, Fenske W, et al. Improved survival in patients with stage II adrenocortical carcinoma followed up prospectively by specialized centers. *J Clin Endocrinol Metab.* 2010;95:4925-4932.
39. Vanbrabant T, Fassnacht M, Assie G, Dekkers OM. Influence of hormonal functional status on survival in adrenocortical carcinoma: systematic review and meta-analysis. *Eur J Endocrinol.* 2018;179:429-436.
40. Park HS, Roman SA, Sosa JA. Outcomes from 3144 adrenalectomies in the United States: which matters more, surgeon volume or specialty? *Arch Surg.* 2009;144:1060-1067.
41. Kerkhofs TM, Verhoeven RH, Bonjer HJ, et al. Surgery for adrenocortical carcinoma in The Netherlands: analysis of the national cancer registry data. *Eur J Endocrinol.* 2013;169:83-89.
42. Lombardi CP, Raffaelli M, Boniardi M, et al. Adrenocortical carcinoma: effect of hospital volume on patient outcome. *Langenbecks Arch Surg.* 2012;397:201-207.
43. Gaujoux S, Mihai R. European Society of Endocrine Surgeons (ESES) and European Network for the Study of Adrenal Tumours (ENSAT) recommendations for the surgical management of adrenocortical carcinoma. *Br J Surg.* 2017;104:358-376.
44. Johanssen S, Hahner S, Saeger W, et al. Deficits in the management of patients with adrenocortical carcinoma in Germany. *Dtsch Arztebl Int.* 2010;107:U885-U889.
45. Bilimoria KY, Shen WT, Elaraj D, et al. Adrenocortical carcinoma in the United States: treatment utilization and prognostic factors. *Cancer.* 2008;113:3130-3136.
46. Reibetanz J, Jurowich C, Erdogan I, et al. Impact of lymphadenectomy on the oncologic outcome of patients with adrenocortical carcinoma. *Ann Surg.* 2012;255:363-369.
47. Reibetanz J, Rinn B, Kunz AS, et al. Patterns of lymph node recurrence in adrenocortical carcinoma: possible implications for primary surgical treatment. *Ann Surg Oncol.* 2019;26:531-538.
48. Porpiglia F, Fiori C, Daffara FC, et al. Does nephrectomy during radical adrenalectomy for stage II adrenocortical cancer affect patient outcome? *J Endocrinol Invest.* 2016;39:465-471.
49. Berruti A, Fassnacht M, Haak H, et al. Prognostic role of overt hypercortisolism in completely operated patients with adrenocortical cancer. *Eur Urol.* 2014;65:832-838.
50. Postlewait LM, Ethun CG, Tran TB, et al. Outcomes of adjuvant mitotane after resection of adrenocortical carcinoma: a 13-institution study by the US Adrenocortical Carcinoma Group. *J Am Coll Surg.* 2016;222:480-490.

51. Terzolo M, Angeli A, Fassnacht M, et al. Adjuvant mitotane treatment for adrenocortical carcinoma. *N Engl J Med*. 2007;356:2372-2380.
52. Berruti A, Grisanti S, Pulzer A, et al. Long-term outcomes of adjuvant mitotane therapy in patients with radically resected adrenocortical carcinoma. *J Clin Endocrinol Metab*. 2017;102:1358-1365.
53. Tang Y, Liu Z, Zou Z, et al. Benefits of adjuvant mitotane after resection of adrenocortical carcinoma: a systematic review and meta-analysis. *Biomed Res Int*. 2018;2018:9362108.
54. Terzolo M, Baudin AE, Ardito A, et al. Mitotane levels predict the outcome of patients with adrenocortical carcinoma treated adjuvantly following radical resection. *Eur J Endocrinol*. 2013;169:263-270.
55. Available at: <https://clinicaltrials.gov/ct2/show/NCT0077244>. Accessed August 31, 2020.
56. Eisenhofer G, Rivers G, Rosas AL, et al. Adverse drug reactions in patients with pheochromocytoma: incidence, prevention and management. *Drug Saf*. 2007;30:1031-1062.
57. Hermsen IGC, Gelderblom H, Kievit J, et al. Extremely long survival in six patients despite recurrent and metastatic adrenal carcinoma. *Eur J Endocrinol*. 2008;158:911-919.
58. Baudin E, Leboulleux S, Al Ghuzlan A, et al. Therapeutic management of advanced adrenocortical carcinoma: what do we know in 2011? *Horm Cancer*. 2011;2:363-371.
59. Baudin E, Endocrine Tumor Board of Gustave Roussy. Adrenocortical carcinoma. *Endocrinol Metab Clin North Am*. 2015;44:411-434.
60. Fassnacht M, Terzolo M, Allolio B, et al. Combination chemotherapy in advanced adrenocortical carcinoma. *N Engl J Med*. 2012;366:2189-2197.
61. Williamson SK, Lew D, Miller GJ, et al. Phase II evaluation of cisplatin and etoposide followed by mitotane at disease progression in patients with locally advanced or metastatic adrenocortical carcinoma — a Southwest Oncology Group study. *Cancer*. 2000;88:1159-1165.
62. Bukowski RM, Wolfe M, Levine HS, et al. Phase II trial of mitotane and cisplatin in patients with adrenal carcinoma: a Southwest Oncology Group study. *J Clin Oncol*. 1993;11:161-165.
63. Megerle F, Kroiss M, Hahner S, Fassnacht M. Advanced adrenocortical carcinoma — what to do when first-line therapy fails? *Exp Clin Endocrinol Diab*. 2019;127:109-116.
64. Sperone P, Ferrero A, Daffara F, et al. Gemcitabine plus metronomic 5-fluorouracil or capecitabine as a second-/third-line chemotherapy in advanced adrenocortical carcinoma: a multicenter phase II study. *Endocr Relat Cancer*. 2010;17:445-453.
65. Henning JEK, Deutschbein T, Altieri B, et al. Gemcitabine-based chemotherapy in adrenocortical carcinoma: a multicenter study of efficacy and predictive factors. *J Clin Endocrinol Metab*. 2017;102:4323-4332.
66. Berruti A, Terzolo M, Sperone P, et al. Etoposide, doxorubicin and cisplatin plus mitotane in the treatment of advanced adrenocortical carcinoma: a large prospective phase II trial. *Endocr Relat Cancer*. 2005;12:657-666.
67. Bednarski BK, Habra MA, Phan A, et al. Borderline resectable adrenal cortical carcinoma: a potential role for preoperative chemotherapy. *World J Surg*. 2014;38:1318-1327.
68. Claps M, Cerri S, Grisanti S, et al. Adding metyrapone to chemotherapy plus mitotane for Cushing's syndrome due to advanced adrenocortical carcinoma. *Endocrine*. 2018;61(1):169-172.
69. Datrice NM, Langan RC, Ripley RT, et al. Operative management for recurrent and metastatic adrenocortical carcinoma. *J Surg Oncol*. 2012;105:709-713.
70. Erdogan I, Deutschbein T, Jurowich C, et al. The role of surgery in the management of recurrent adrenocortical carcinoma. *J Clin Endocrinol Metab*. 2013;98:181-191.
71. Else T, Kim AC, Sabolch A, et al. Adrenocortical carcinoma. *Endocr Rev*. 2014;35:282-326.
72. Fassnacht M, Berruti A, Baudin E, et al. Linsitinib (OSI-906) versus placebo for patients with locally advanced or metastatic adrenocortical carcinoma: a double-blind, randomised, phase 3 study. *Lancet Oncol*. 2015;16:426-435.
73. Carneiro BA, Konda B, Costa RB, et al. Nivolumab in metastatic adrenocortical carcinoma: results of a phase 2 trial. *J Clin Endocrinol Metab*. 2019;104:6193-6200.
74. Habra MA, Stephen B, Campbell M, et al. Phase II clinical trial of pembrolizumab efficacy and safety in advanced adrenocortical carcinoma. *J Immunother Cancer*. 2019;7:253.
75. Le Tourneau C, Hoimes C, Zarwan C, et al. Avelumab in patients with previously treated metastatic adrenocortical carcinoma: phase 1b results from the JAVELIN solid tumor trial. *J Immunother Cancer*. 2018;6:111.
76. Raj N, Zheng Y, Kelly V, et al. PD-1 blockade in advanced adrenocortical carcinoma. *J Clin Oncol*. 2020;38:71-80.
77. Hescot S, Leboulleux S, Amar L, et al. One-year progression-free survival of therapy-naïve patients with malignant pheochromocytoma and paraganglioma. *J Clin Endocrinol Metab*. 2013;98:4006-4012.
78. Roman-Gonzalez A, Zhou S, Ayala-Ramirez M, et al. Impact of surgical resection of the primary tumor on overall survival in patients with metastatic pheochromocytoma or sympathetic paraganglioma. *Ann Surg*. 2018;268:172-178.
79. Ayala-Ramirez M, Palmer JL, Hofmann MC, et al. Bone metastases and skeletal-related events in patients with malignant pheochromocytoma and sympathetic paraganglioma. *J Clin Endocrinol Metab*. 2013;98:1492-1497.
80. Gravel G, Leboulleux S, Tselikas L, et al. Prevention of serious skeletal-related events by interventional radiology techniques in patients with malignant paraganglioma and pheochromocytoma. *Endocrine*. 2018;59:547-554.
81. Gonias S, Goldsby R, Matthay KK, et al. Phase II study of high-dose [¹³¹I] metaiodobenzylguanidine therapy for patients with metastatic pheochromocytoma and paraganglioma. *J Clin Oncol*. 2009;27:4162-4168.
82. Pryma DA, Chin BB, Noto RB, et al. Efficacy and safety of high-specific-activity I-131 MIBG therapy in patients with advanced pheochromocytoma or paraganglioma. *J Nucl Med*. 2019;60:623-630.
83. Han S, Suh CH, Woo S, et al. Performance of ⁶⁸Ga-DOTA-conjugated somatostatin receptor targeting peptide PET in detection of pheochromocytoma and paraganglioma: a systematic review and meta-analysis. *J Nucl Med*. 2019;60:369-376.
84. Kong G, Grozinsky-Glasberg S, Hofman MS, et al. Efficacy of peptide receptor radionuclide therapy for functional metastatic paraganglioma and pheochromocytoma. *J Clin Endocrinol Metab*. 2017;102:3278-3287.
85. Niemeijer ND, Alblas G, van Hulsteijn LT, et al. Chemotherapy with cyclophosphamide, vincristine and dacarbazine for malignant paraganglioma and pheochromocytoma: systematic review and meta-analysis. *Clin Endocrinol (Oxf)*. 2014;81:642-651.
86. Ayala-Ramirez M, Feng L, Habra MA, et al. Clinical benefits of systemic chemotherapy for patients with metastatic pheochromocytomas or sympathetic extra-adrenal paragangliomas: insights from the largest single-institutional experience. *Cancer*. 2012;118:2804-2812.
87. Hadoux J, Favier J, Scoazec JY, et al. SDHB mutations are associated with response to temozolomide in patients with metastatic pheochromocytoma or paraganglioma. *Int J Cancer*. 2014;135:2711-2720.
88. Tena I, Gupta G, Tajahuerce M, et al. Successful second-line metronomic temozolomide in metastatic paraganglioma: case reports and review of the literature. *Clin Med Insights Oncol*. 2018;12, 1179554918763367.
89. Favier J, Igaz P, Burnichon N, et al. Rationale for anti-angiogenic therapy in pheochromocytoma and paraganglioma. *Endocr Pathol*. 2012;23:34-42.
90. Ayala-Ramirez M, Chougnat CN, Habra MA, et al. Treatment with sunitinib for patients with progressive metastatic pheochromocytomas and sympathetic paragangliomas. *J Clin Endocrinol Metab*. 2012;97:4040-4050.
91. Jasim S, Suman VJ, Jimenez C, et al. Phase II trial of pazopanib in advanced/progressive malignant pheochromocytoma and paraganglioma. *Endocrine*. 2017;57:220-225.
92. Dykewicz CA. Summary of the guidelines for preventing opportunistic infections among hematopoietic stem cell transplant recipients. *Clin Infect Dis*. 2001;33:139-144.