Immunohistochemistry patterns of SARS-CoV-2 Deaths in Forensic Autopsies

Journal Pre-proofs

Case Report

Immunohistochemistry patterns of SARS-CoV-2 Deaths in Forensic Autopsies

Francesco Lupariello, Laura Godio, Giancarlo Di Vella

PII: S1344-6223(21)00058-4
DOI: https://doi.org/10.1016/j.legalmed.2021.101894
Reference: LEGMED 101894

To appear in: *Legal Medicine*

Received Date: 29 January 2021
Revised Date: 22 February 2021
Accepted Date: 11 April 2021

Please cite this article as: Lupariello, F., Godio, L., Di Vella, G., Immunohistochemistry patterns of SARS-CoV-2 Deaths in Forensic Autopsies, *Legal Medicine* (2021), doi: https://doi.org/10.1016/j.legalmed.2021.101894

Title: Immunohistochemistry patterns of SARS-CoV-2 Deaths in Forensic Autopsies

Authors

Francesco Lupariello[1], MD, Laura Godio[2], MD, and Giancarlo Di Vella[1], MD, PhD

Authors' affiliations

1) Dipartimento di Scienze della Sanità Pubblica e Pediatriche - Sezione di Medicina Legale - "Università degli Studi di Torino"; address: corso Galileo Galilei 22, 10126 Torino, Italy;

2) A.O.U. Città della Salute e della Scienza – Anatomia Patologica U; address: corso Bramante 88, 10126 Torino, Italy.

Corresponding author

Francesco Lupariello, MD, phone: +393806373629, francesco.lupariello@gmail.com, address: corso Galileo Galilei 22, 10126 Turin, Italy, ORCID iD: 0000-0003-2264-8521.

Acknowledgement

We have no acknowledgement statements.

Word count: 1440.

Declarations of interest: none.

Funding: this research did not receive any specific grant from funding agencies in the public, commercial, or not-for-profit sectors.

Title: Immunohistochemistry patterns of SARS-CoV-2 Deaths in Forensic Autopsies

Abstract

SARS-CoV-2 infection was a leading cause of death in 2020 worldwide. It can evolve determining sudden dyspnea and death without hospitalization and/or a nasopharyngeal swab. These cases can need the intervention of forensic pathologists in order to identify causes of death and to clarify malpractice claims. For these reasons, it would be useful to identify immunohistochemistry patterns of SARS-CoV-2 deaths. Thus, the authors described immunohistochemistry findings of two Patients: perivascular recruitment of T-cells in lung parenchyma, massive activation of cytotoxic cells (especially in spleen's parenchyma), and diffuse platelet aggregation in medium/small vessels. In addition, they analyzed these data in the light of the scientific literature, pointing out meaningful immunohistochemistry patterns in order to better understand SARS-CoV-2 pathophysiology process and to clearly identify causes/contributing factors of death in forensic routine.

Key Words: SARS-CoV-2; immunohistochemistry; forensic pathology; immunology; lymphocytes; cytotoxic cells

1. Introduction

SARS-CoV-2 infection was a leading cause of death in 2020 worldwide (and it is predictable that this will also last in 2021) [1]. The virus can be responsible for a brief period of flu-like signs and/or symptoms that – especially in patients with multiple comorbidities – can evolve determining sudden

dyspnea and death without hospitalization and/or a nasopharyngeal swab. These cases can need the intervention of forensic pathologists in order to identify causes of death and to clarify malpractice claims [2].

In the light of the above, the authors described immunohistochemistry (IHC) microscopic findings of two autopsies of patients acutely deceased by SARS-CoV-2 infection. The latter findings were not altered by effects of intensive care therapy (i.e. mechanical ventilation and drug administration). Their aim was also to identify new IHC insights of SARS-CoV-2 infection in order to better understand SARS-CoV-2 pathophysiology process and to facilitate the identification of causes/contributing factors of death in forensic routine.

2. Case Report

Patient 1 was a 66-year-old-man. His medical history was positive for alcohol abuse, multiple cerebral ischemic events, and dementia. Patient 2 was an 83-year-old-woman affected by obesity and senile dementia. Both patients resided in the same nursing home. They showed fever (> 38°C) respectively for five and seven days, and they suddenly died despite antibiotics and paracetamol administration. They underwent neither ante-mortem SARS-CoV-2 tests nor intensive care procedures. Other information about their clinical course was not available. Post-mortem SARS-CoV-2 real time reverse transcriptase polymerase chain reaction was positive in both cases. Forensic autopsies were requested by the Judicial Authority in order to clarify causes of death and malpractice claims. Autopsies revealed intensive lungs' congestion. In both cases, at histology lungs' hematoxylin and eosin stain yielded common signs of SARS-CoV-2 infection (diffuse alveolar damage, pneumocyte hyperplasia, intra-alveolar fibrinous exudates, dense hyaline membranes). For these reasons, forensic pathologists signed as cause of death acute respiratory distress syndrome (ARDS) by SARS-CoV-2 infection (Coronavirus Disease 2019 – COVID19). In both cases, medical malpractice claims were excluded because the deaths occurred during the first weeks of the pandemic, when useful indications about COVID19 therapy were not yet available.

In addition, immunohistochemistry (IHC) was performed yielding the following results (IHC was conducted in accordance with the indication of the scientific literature [3,4]; in particular, antibodies against CD3 (CD3 Monoclonal Antibody - LN10 - from Leica Biosystems), TIA1 (TIA1 Monoclonal Antibody - 2G9A10F5 - from Beckman Coulter), CD20 (CD20 Monoclonal Antibody - L26 - Leica Biosystems), and CD61 (CD61 Monoclonal Antibody - 2F2 - from Beckman Coulter) were used. They were applied on formalin-fixed and paraffin-embedded samples after proper deparaffinization, rehydration, and heating. In the negative control reactions, the antibodies resulted in complete absence of staining).

2.1 Immunohistochemistry: CD3

CD3 is a protein complex expressed on T-lymphocytes' surface [5]. In both cases, IHM for CD3 identified T-lymphocytes' diffuse perivascular recruitment in lungs (Figure 1).

2.2 Immunohistochemistry: TIA1

TIA1 is a molecule – stored in cytotoxic granules of natural killer (NK) cells and cytotoxic T CD8 lymphocytes – that possesses nucleolytic activity. [6]. In the reported cases, IHM for TIA1 showed cytotoxic cell focal infiltration in vessels and in perivascular spaces. In addition, this IMH reaction revealed massive and diffuse presence of cytotoxic cells in spleen's parenchyma of Patient 2 (Figure 1).

2.3 Immunohistochemistry: CD20

CD20 is a surface protein which is expressed by B-lymphocytes [7]. In both Patients, IMH for CD20 did not revealed specific recruitment of B-lymphocytes in lungs, heart, spleen, and kidneys.

2.4 Immunohistochemistry: CD61

CD61 is a molecule stored in α-granules of platelets. Its function is to constitute the most abundant platelet adhesion receptor (glycoprotein IIb/IIIa integrin) of this cell population [8]. In the reported cases, IHC for CD61 revealed diffuse platelet aggregation in medium/small vessels of pulmonary parenchyma. In addition, the same finding was focally present in myocardium and kidneys of Patient 2. In Patients 1, diffuse platelet aggregates were pointed out in small vessels of lungs' hilar lymph nodes (Figure 2 and 3).

Comparative images of lungs, heart, spleen, and kidneys at histology (hematoxylin and eosin stain) are available in Figure 4.

3. Discussion

Until now, the immunology of SARS-CoV-2 infection is not yet completely understood. For example, multiple studies tried to identify virus' impact on lymphocytes' activity highlighting "the occurrence of lymphopenia with drastically reduced numbers of both CD4 and CD8 T cells in moderate and severe COVID-19 cases" [9]. This reduction (especially for CD8 T cells) also seems to correlate with severity and mortality of SARS-CoV-2 disease. Even if this occurrence was already reported for other viral infections, its causes remain elusive (direct SARS-CoV-2 infection of T cells was not demonstrated) [9]. Some authors suggested that T cell reduction in peripheral blood may depend on their extensive recruitment in the site of the infection, contributing to SARS-CoV-2 infection's pathophysiologic progression. Talking about B-lymphocytes in SARS-CoV-2 infection, it is known that the virus triggers a significant B cell response characterized by the rapid increase of virus-specific IgM, IgG and IgA, and neutralizing IgG antibodies, even if their kinetics are not yet completely understood [9,10]. In addition, until now it is not clear if antibodies towards the virus can contribute to determine pathology progression [9,11].

Regarding lymphocytes' role in SARS-CoV-2 infection, in the scientific literature histologic evaluations of autopsies' samples and biopsies of infected patients demonstrated extensive

lymphocyte infiltration in the lungs [12]. In particular, Dettmeyer and colleagues recently described this infiltration as localized near lungs' capillaries (lymphocytic capillaritis), adding meaningful insights to the scientific literature [13]. This manuscript allowed to identify that the aforementioned infiltration was principally determined by T cells which were diffusely recruited in perivascular areas of lungs. Thus, these findings seem to suggest a predominant role of T- lymphocytes in lungs' SARS-CoV-2 pathophysiology, supporting the abovementioned hypothesis (i.e. T cell reduction in peripheral blood may depend on their extensive recruitment in the site of the infection, contributing to SARS-CoV-2 infection's pathophysiologic progression). On the contrary, even if B-lymphocytes' activation has been extensively reported in the scientific literature, the present report does not point out accumulation/recruitment of B cells in lungs, heart, spleen, and kidneys of both Patients.

Previous studies about cytotoxic cells' activity in SARS-CoV-2 infection identified a significant reduction in peripheral blood of NKs and T CD8 lymphocytes [14]. In particular, the scientific literature pointed out that the activation of specific molecular pathway may induce their extensive recruitment in lungs from peripheral blood, causing their progressive consumption in moderate and severe forms of SARS-CoV-2 disease [9]. Indeed, it is well known that cytotoxic cells are fundamental mediators of the immune response in viral infections [9,14]. These statements are confirmed by the present manuscript. Indeed, in both Patients cytotoxic cell infiltration in lungs was focally present in vessels and in perivascular spaces. In addition, in Patient 2's spleen it was highlighted a meaningful finding: massive and diffuse presence of cytotoxic cells. The latter microscopic finding is uncommon, because TIA1 positive cells are difficultly distinguishable in spleen's physiologic parenchyma. This peculiar microscopic feature seems to concord with the scientific literature [14]. Indeed, it can be suggested that this phenomenon was caused by the massive consumption of cytotoxic cells in SARS-CoV-2 infected patients.

SARS-CoV-2 ability to alter coagulation homeostasis (especially in medium/small vessels: micro-thrombosis) has been reported in the scientific literature, pointing out that severe parenchymal

injury can be determined by microvasculature's involvement. The latter was early identified as responsible for disease's progression [15,16], observing that infected patients were characterized by "profound hypoxia which was out of proportion to the preserved lung mechanics suggestive of significant pulmonary shunting, raising the possibility of a lung injury mechanism different from that of traditional ARDS" [17]. This statement was confirmed by Ackerman and colleagues. They compared lungs of influenza A infected patients against SARS-CoV-2 ones, revealing as micro-thrombi were more prevalent in SARS-CoV-2 disease [18]. In the literature, the reasons of micro-thrombosis are not completely understood, even if direct and/or indirect endothelial damage seems to be the trigger of this phenomenon. This manuscript confirmed the abovementioned data. Indeed, at IHC microscopic evaluations of Patients' organs, impressive finding was the occurrence of diffuse platelet aggregation in medium/small vessels of pulmonary parenchyma. Similar findings were present: focally in myocardium and kidneys of Patient 2; diffusely in Patient 1's small vessels of lungs' hilar lymph nodes.

In conclusion, IHC findings induce to identify SARS-CoV-2 like a virus with ability to deeply alter immune system's functions and coagulation homeostasis. The abovementioned IHC features of lymphocytes, cytotoxic cells, and platelets should be taken into account by pathologists who approaches autopsies of SARS-CoV-2 infected individuals in order to better understand SARS-CoV-2 pathophysiology process and to correctly identify causes/contributing factors of death in forensic routine.

References

1. Wu D, Wu T, Liu Q, Yang Z. The SARS-CoV-2 outbreak: What we know. Int J Infect Dis. 2020;94:44-48.

2. Tombolini A, Scendoni R. SARS-CoV-2-related deaths in routine forensic autopsy practice: histopathological patterns. Int J Legal Med. 2020;134(6):2205-2208.

3. Ramos-Vara JA. Principles and methods of immunohistochemistry. Methods Mol Biol. 2017;1641:115-128.

4. Van Nederveen FH, Gaal J, Favier J, et al. An immunohistochemical procedure to detect patients with paraganglioma and phaeochromocytoma with germline SDHB, SDHC, or SDHD gene mutations: a retrospective and prospective analysis. Lancet Oncol. 2009;10(8):764-771.

5. Alcover A, Alarcón B, Di Bartolo V. Cell biology of t cell receptor expression and regulation. Annu Rev Immunol. 2018;36:103-125.

6. Kawakami A, Tian Q, Duan X, Streuli M, Schlossman SF, Anderson P. Identification and functional characterization of a TIA-1-related nucleolysin. Proc Natl Acad Sci U S A. 1992;89(18):8681-8685.

7. Shanehbandi D, Majidi J, Kazemi T, Baradaran B, Aghebati-Maleki L. Cd20-based immunotherapy of b-cell derived hematologic malignancies. Curr Cancer Drug Targets. 2017;17(5):423-444.

8. Zarbock A, Polanowska-Grabowska RK, Ley K. Platelet-neutrophil-interactions: linking hemostasis and inflammation. Blood Rev. 2007;21(2):99-111.

9. Vabret N, Britton GJ, Gruber C, et al. Immunology of covid-19: current state of the science. Immunity. 2020;52(6):910-941.

10. Huang AT, Garcia-Carreras B, Hitchings MDT, et al. A systematic review of antibody mediated immunity to coronaviruses: antibody kinetics, correlates of protection, and association of antibody responses with severity of disease. medRxiv. Published online April 17, 2020.

11. Cao X. COVID-19: immunopathology and its implications for therapy. Nat Rev Immunol. 2020;20(5):269-270.

12. Varga Z, Flammer AJ, Steiger P, et al. Endothelial cell infection and endotheliitis in COVID-19. Lancet. 2020;395(10234):1417-1418.

13. Dettmeyer R, Lasczkowski G, Weber A, Wolter T, Kernbach-Wighton G. Histopathological findings following SARS-CoV-2 infection with and without treatment-Report of three autopsies. Rechtsmedizin (Berl). 2020;30:336-344.

14. Jiang Y, Wei X, Guan J, et al. COVID-19 pneumonia: CD8+ T and NK cells are decreased in number but compensatory increased in cytotoxic potential. Clin Immunol. 2020;218:108516.

15. Leisman DE, Deutschman CS, Legrand M. Facing COVID-19 in the ICU: vascular dysfunction, thrombosis, and dysregulated inflammation. Intensive Care Med. 2020;46(6):1105-1108.

16. Gattinoni L, Coppola S, Cressoni M, Busana M, Rossi S, Chiumello D. COVID-19 does not lead to a “typical” acute respiratory distress syndrome. Am J Respir Crit Care Med. 2020;201(10):1299-1300.

17. Kamel MH, Yin W, Zavaro C, Francis JM, Chitalia VC. Hyperthrombotic Milieu in COVID-19 Patients. Cells. 2020;9(11).

18. Ackermann M, Verleden SE, Kuehnel M, et al. Pulmonary Vascular Endothelialitis, Thrombosis, and Angiogenesis in Covid-19. *N Engl J Med*. 2020;383(2):120-128.

Figures

Fig. 1 - IHC images of cytotoxic cell and T-lymphocyte recruitment.

A. Patient 2, IHC for TIA1 molecule (190x) – Massive recruitment of cytotoxic cells in spleen red pulp; B. Patient 2, IHC for CD3 molecule (90x) – Extensive perivascular recruitment of T-cells in lung parenchyma; C. Patient 1, IHC for TIA1 molecule (170x) – peri/intra-vascular recruitment of cytotoxic cells in lung parenchyma.

Fig. 2 - IHC images of platelet aggregates in vessels

A. Patient 1, IHC for CD61 molecule (120x) – diffuse platelet aggregation all along the internal endothelial layer of lung small vessel walls; B. Patient 2, IHC for CD61 molecule (60x) – platelet aggregation all along the internal endothelial layer of a small lung vessel; C. Patient 2, IHC for CD61 molecule (180x) – platelet aggregation all along the internal endothelial layer of a myocardial small vessel; D. Patient 2, IHC for CD61 molecule (190x) – platelet aggregation which nearly occludes the lumen of a renal small vessel.

Fig. 3 - IHC images of diffuse platelet aggregates in small vessels of a lymph node of pulmonary hilum

Patient 1, IHC for CD61 molecule (50x) – diffuse platelet aggregates in multiple small vessels

Fig. 4 - Comparative images of lungs, heart, spleen, and kidneys at histology (hematoxylin and eosin stain)

A. Patient 2, spleen (40x); B. Patient 2, heart (100x); C. Patient 2, kidney (90x); D. Patient 1, lung (50x)

Highlights

- SARS-CoV-2 infection can evolve determining sudden dyspnea and death without hospitalization and/or a nasopharyngeal swab

- These cases can need the intervention of forensic pathologists in order to identify causes of death and to clarify malpractice claims

- It would be useful to identify immunohistochemistry patterns of SARS-CoV-2 deaths

- The authors described immunohistochemistry findings of two Patients: perivascular recruitment of T-cells in lung parenchyma, massive activation of cytotoxic cells (especially in spleen's parenchyma), and diffuse platelet aggregation in medium/small vessels

- They analyzed these data in the light of the scientific literature, pointing out meaningful immunohistochemistry patterns

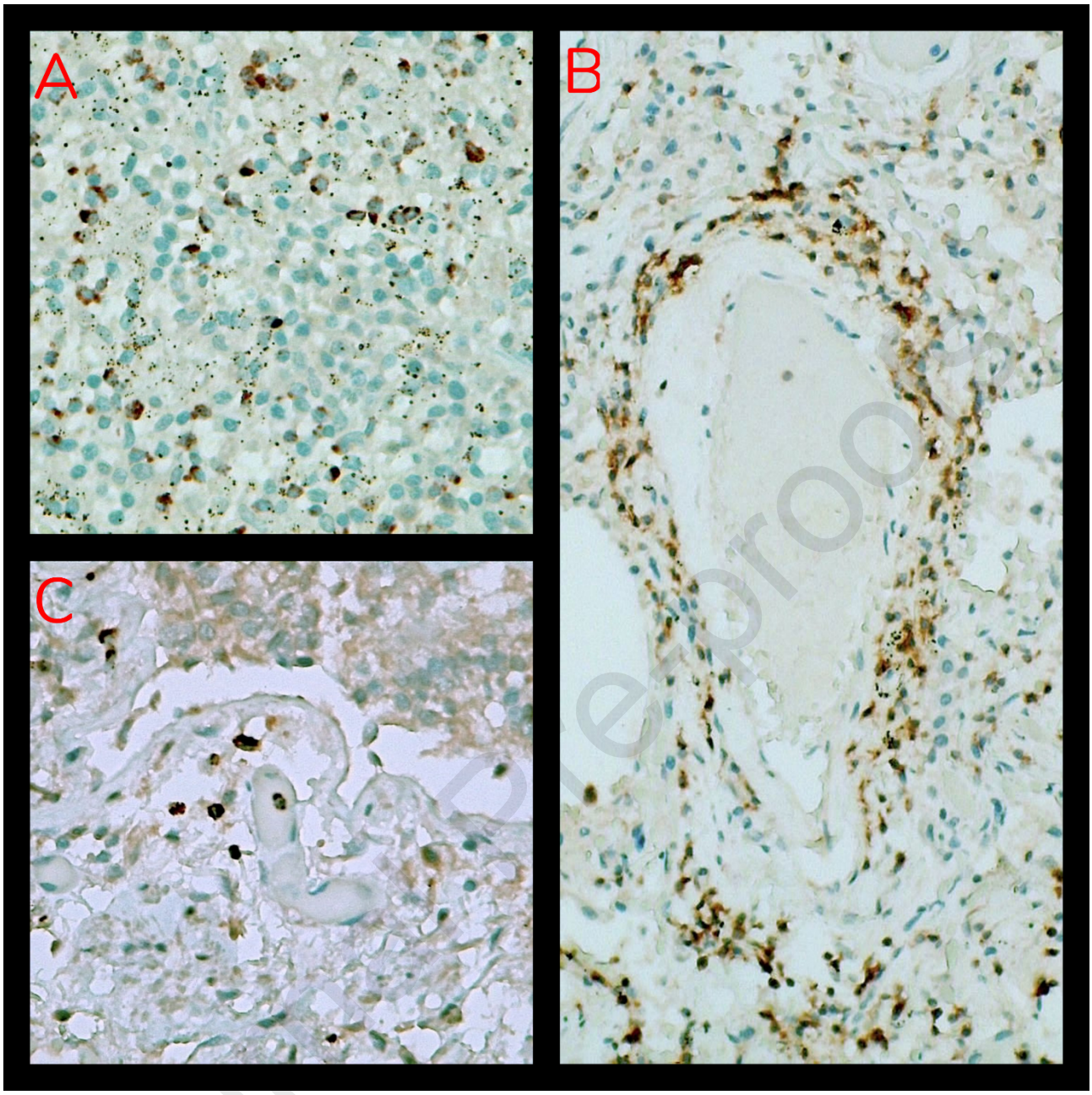

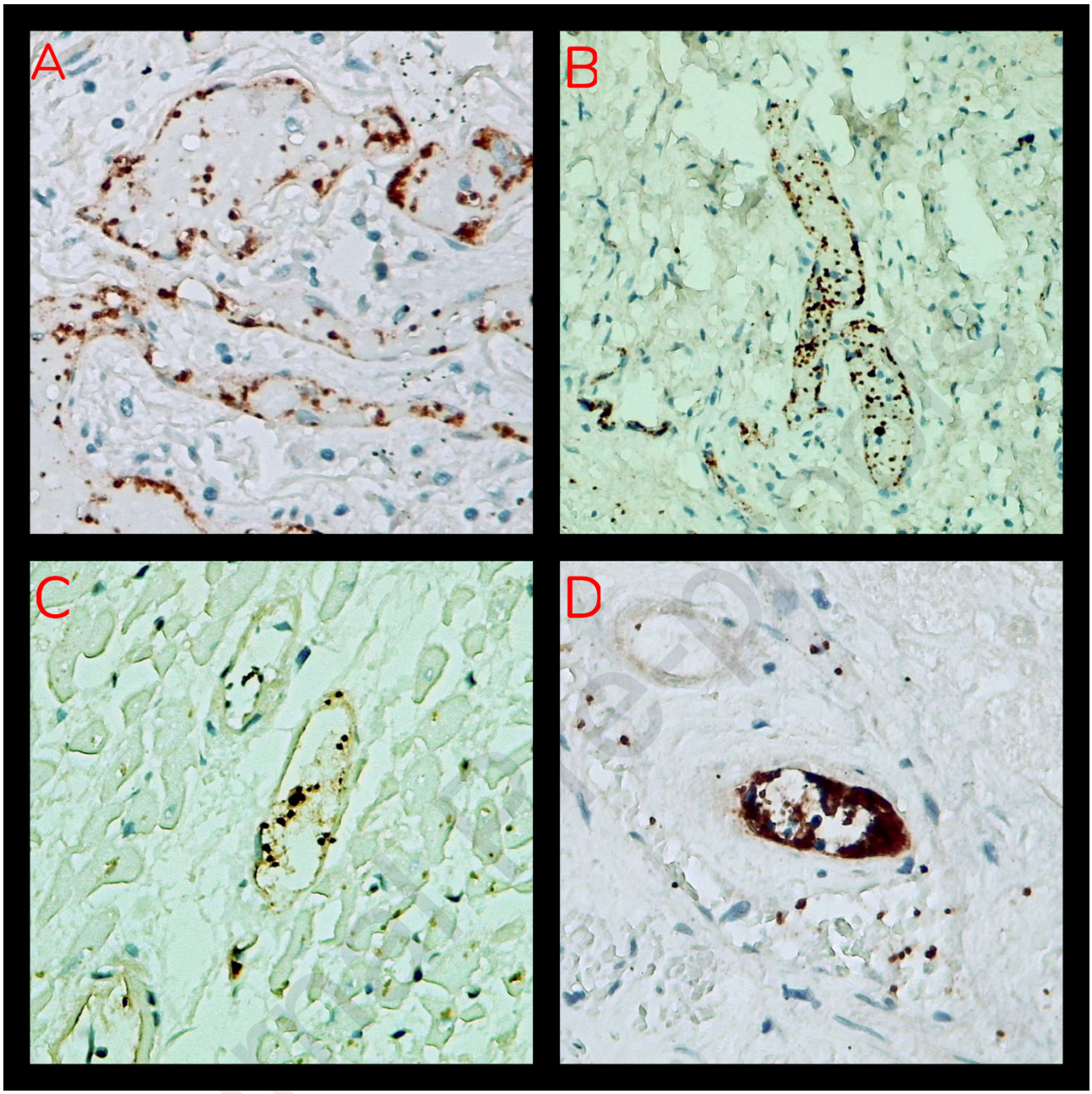
A
B
C
D