Surgical therapy of single peri-implantitis intrabony defects, by means of deproteinized bovine bone mineral with 10% collagen

Surgical therapy of single peri- implantitis intrabony defects, by means of deproteinized bovine bone mineral with 10% collagen

Authors:

Mario Roccuzzo: Private practice, Torino;

University of Torino, Department of Maxillo-facial Surgery.

Luigi Gaudioso: Private practice, Torino.

Marco Lungo: Private practice, Torino.

Paola Dalmasso; University of Torino, Department of Public Health and Paediatrics,

University of Torino

Running header of the manuscript: Surgical treatment of peri-implantitis

Corresponding author:

Mario Roccuzzo, D.D.S.

Corso Tassoni, 14

10143 Torino

Italy

mroccuzzo@iol.it

Conflict of interest and source of funding statement

The authors declare no potential conflict of interests with respect to this study. Mario Roccuzzo received grants and travel funds from Institut Straumann AG, Dentsply Implants, Geistlich Pharma AG, and Sunstar SA, outside the submitted work. The study was self-funded; no external funding was available for this research.

Clinical Relevance: Scientific rationale for the study: Previous studies have shown that the reconstructive procedures for treating peri-implantitis are influenced by the surface characteristics of the implant. Limited preliminary information has shown that defect configuration may have an impact on the regenerative possibilities in infrabony lesions. The objective of this clinical trial is to evaluate the efficacy of a surgical protocol, around a single tissue-level implant type, in defects of different configuration.

Principal findings: The results of this study confirm that the application of DBBMC at Class I defects is associated with improvements in local BOP, mean PD and number of sites with deep pockets. Complete clinical successful treatment was found in about 50% of the cases. There is lack of evidence of whether or not the resolution of the peri-implant disease is associated with the defect configuration.

Practical implications: Successful treatment of peri-implantitis defect is possible in a significant percentage of cases, but it seems not to be a predictable outcome. The decision on whether to conserve or extract a compromised implant depends on several factors, but most of all on the expectations regarding the final possible not perfect outcome.

Implications for research: There is a need of well design controlled clini- cal trials, using a larger number of patients that present peri-implanti- tis defects around implants of one type only, with the same surface and with similar prosthetic recon- structions, in order to assess the effect of only one variable of interest, i.e. defect characteristics.

ABSTRACT

Aim: To evaluate the efficacy of a reconstructive surgical procedure in single peri-implantitis infrabony defects.

Methods: Seventy-five patients with one peri-implantitis crater-like lesion with pocket depth (PD) ≥ 6 mm, were included. Each defect was assigned to one characteristic class, by an independent examiner. After implant decontamination, defects were filled with deproteinized bovine bone mineral with 10% collagen.

Results: At 1-year follow-up, four patients were lost and six implants removed. Treatment success, PD ≤5 mm and absence of suppuration/bleeding on probing (BOP), was obtained in 37 (52.1%) of the 71 implants examined. PD was significantly reduced by 2.92 ± 1.73 mm ($p < 0.0001$). BOP decreased from 71.5 ± 34.4% to 18.3 ± 28.6% ($p < 0.0001$). The mean number of deep pockets (≥6 mm) decreased from 3.00 ± 0.93 to 0.85 ± 1.35 ($p < 0.0001$).

Conclusions: These results confirm the possibility to successfully treat peri- implantitis lesions. There is lack of evidence of whether or not the resolution of the peri-implant disease is associated with the defect configuration. Due to the fact that complete resolution does not seem a predictable outcome, the clinical decision on whether implants should be treated should be based on several patient related elements.

INTRODUCTION

Biological complications are common and peri-implantitis, in particular, is an emerging public health issue (AAP 2013, Atieh et al. 2013, Tonetti et al. 2015). According to Consensus Reports of the 7th and the 8th European Workshop on Periodontology (EWP), a complication can be defined as peri-implantitis when "changes in the level of crestal bone, presence of bleeding on probing and/or suppuration with or with- out concomitant deepening of peri-implant pockets" is found (Lang & Berglundh 2011, Sanz & Chapple 2012). During the last years, several reviews on the treatment of biological complications around dental implants have been published (Lindhe & Meyle 2008, Sahrmann et al. 2011, Esposito et al. 2012, Klinge & Meyle 2012, Renvert et al. 2012, 2013, Khoshkam et al. 2013, Chan et al. 2014, Figuero et al. 2014, Heitz-Mayfield et al. 2014, Renvert & Polyzois 2015). Even though, the primary objective of surgical treatment in peri-implantitis is to get access to the implant surface for debridement and decontamination, in order to achieve resolution of the inflammatory lesion, it seems useful, in crater formed defects, to correct the anatomical conditions for improving plaque control. Since the 6th EWP (Lindhe & Meyle 2008), that indicated that there was no evidence that so-called regenerative procedures had additional beneficial effects on treatment outcome, several authors have published different protocols with various degrees of success in the treatment of peri-implantitis by means of bone regenerative procedures (Schwarz et al. 2009, 2010, 2014, Wiltfang et al. 2010, Roccuzzo et al. 2011, Wohlfahrt et al. 2012, Roos-Jansaker et al. 2014).

Regarding the anatomy of the residual bone, Schwarz et al. (2010) suggested that defect configuration is an important factor for a predictable outcome following regenerative treatment, and encouraged researchers, investigating any type of surgical treatment of peri-implantitis, to properly report on the specific configuration of the included defects.

The aim of this prospective study was to evaluate the efficacy of a reconstructive surgical procedure in peri-implantitis infrabony defects of various configurations.

MATERIALS AND METHODS

Patient population

From January 2010 to September 2014, 75 patients (39 males and 36 females; mean age: 57.8 ± 8.5 years; 11 smokers), who presented a peri-implantitis crater-like lesion with a probing depth (PD) ≥6 mm and no implant mobility, were consecutively enrolled from those attending the principle investigator's private practice. Twenty-one patients with multiple affected implants and/or with defects characterized by consistent horizontal bone loss (Class II) were not included. Exclusion criteria were:

1. PD < 6 mm;
2. Class II defects (characterized by consistent horizontal bone loss);
3. Multiple defects;
4. Implant mobility;
5. No interest in participating in the study;
6. Implants placed by other clinicians.

Patients had been treated, in the previous years, for periodontitis and subsequently had received therapy by means of non-submerged tissue level dental implants (Straumann Dental Implant System, Straumann AG, Basel, Switzerland). All implants supported either a single crown or a fixed dental prosthesis. Patients had been recalled at various intervals, depending on the initial diagnosis and the results of the therapy, for supporting periodontal therapy (SPT). Motivation, reinstruction, instrumentation and treatment of re-infected sites were performed as needed. Patients had been placed on an individually tailored maintenance care programme, including continuous evaluation of the occurrence and the risk of dis- ease progression.

All patients had complied with the recall programme until evaluation of the peri-implantitis. Only one implant defect per patient was included in the study. The demo- graphic and clinical characteristics of the patients, with the exception of 4 dropouts, are represented in Table 1. Each patient was given a detailed description of the procedure. They were also informed that their data would be used for statistical analysis and gave their informed consent to the treatment. No ethical committee approval was sought to start up this observational study, as it was not required by national law or by ordinance of local inspective authority. The prospective study was performed in accordance with the principles stated in the Declaration of Helsinki and the Good Clinical Practice Guidelines.

Surgical procedures

The surgical procedure is described in a previous article (Roccuzzo et al. 2011) (Figs. 1–4). Briefly, each patient underwent scaling and root planing of teeth and cleaning of implants shoulders, after receiving personalized oral hygiene instruc- tions to reach full-mouth plaque score (FMPS) <20% and full-mouth bleeding score (FMBS) <20%.

All surgeries were performed by one surgeon (MR) with 20 years of experience in periodontal surgery. The area selected for surgery was anaesthetized with mepivacaine plus epinephrine 1:100,000. Full thick- ness, mucoperiosteal flaps were raised by means of intracrevicular incisions. Subsequently, all granulation tissue was completely removed from the defect area and the implant surfaces were thoroughly debrided using titanium curettes. Whenever necessary, especially in deep narrow defects, the implant surfaces were instrumented with a titanium brush (Tigran Peribrush, Tigran Technologies AB, Malmo, Sweden) at 300 rpm under irrigation.

Implant surface was treated with EDTA 24% (Prefgel Straumann AG, Basel, Switzerland) for 2 min. and chlorhexidine 1% gel (Corsodyl dental gel, GlaxoSmithKline, Baranzate, Italy) for 2 min. Then the implant and bony surfaces were thoroughly rinsed with sterile physiologic saline. Deproteinized bovine bone mineral with 10% collagen (DBBMC) (BioOss® Collagen, Geistlich, Wolhusen, Switzerland) was applied in a way as to homogeneously fill the intrabony defect component. Before its application, the graft material was moistened in sterile saline. If the area presented no keratinized tissue, following grafting, a connective tissue graft was excised by a gingivectomy from the tuberosity area (Jung et al. 2008), trimmed and adapted over the entire defect so as to cover 2–3 mm of the surrounding alveolar bone and to ensure stability of the graft material.

Finally, the flap was repositioned coronally and fixed with sutures to ensure a non-submerged healing procedure.

Postsurgical care

Patients were instructed to take 1 g of amoxicillin and clavulanic acid twice a day for 6 days, starting at least 1 h prior to surgery, and non-steroidal analgesics, as needed. Immediately after surgery, the patients applied ice packs at the treated area, and it was recommended that these be kept in place for at least 4 h. Patients were advised to discontinue tooth brushing and to avoid trauma at the site of surgery for 3 weeks. They were also instructed to use 0.2% chlorhexidine digluconate rinse for 1 min three times a day for the same period of time. Patients were seen after 7 days and then weekly for the first month to monitor healing. The sutures were removed after 14 days. After the healing phase, patients were placed on an individually tailored maintenance care

programme. Motivation, reinstruction, supragingival instrumentation and antiseptic therapy were performed as needed.

Clinical assessments

During surgery, each defect was assigned to one of the five character- istic classes, by an independent examiner (ML), on the basis of the circumferential and intrabony components of the lesion according to the classification by Schwarz et al. (2007):

Ia: buccal dehiscence;

Ib: buccal dehiscence + semicircumferential;

Ic: buccal dehiscence + circumferential;

Id: buccal and lingual dehiscence + circumferential;

Ie: circumferential only;

Immediately before surgery and after 12 months, an examiner (SG) with more than a dozen years of experience as hygienist, blinded to the classification of the patients, recorded, for each test implant, probing depth (PD) measured at four sites (mesial, buccal, distal and lingual) by means of a periodontal probe (XP23/UNC 15; Hu-Friedy). At the same time and sites the presence of dental plaque (Pl), of bleeding on probing (BOP), of pus and the mid-facial keratinized tissue width were recorded. All figures were rounded off to the nearest millimeter.

STATISTICAL ANALYSIS

Each patient contributed with one peri-implantitis defect and was, therefore, regarded as the statistical unit. Data were expressed as mean ± SD or counts and percentages. As the statistical distribution of the quantitative parameters was found to be non-Gaussian (test by Shapiro–Wilk test) non-parametric tests were used to assess between- group differences (Kruskal–Wallis rank test), the pairwise comparisons of the groups pre- and post-treatment (Mann–Whitney U-test, with Bonferroni's adjustment for multiple comparisons) and the pre-post intra- group comparisons (Wilcoxon matched-pairs signed-rank test). For categorical variables, the groups were compared using Fisher's exact test and the pre-post evaluations were tested by McNemar test. Logistic regression models were used to evaluate the likelihood of a successful treatment (PD ≤ 5 mm and absence of bleeding/suppuration on probing) in relation to baseline probing depth. A two-sided p value of less than 0.05 was considered to indicate statistical significance. With five groups and a type I error = 0.05, we considered individual statistical tests statistically significant at $p < 0.005$.

RESULTS

In all patients, surgery and immediate healing proceeded without complications and with minimal postoperative discomfort. Four patients did not complete the entire period of observation and were considered dropouts. The clinical parameters around all implants at baseline and at 1-year evaluation are summarized in Table 2. Mean probing depth was significantly reduced by 2.92 ± 1.73 mm from 7.17 ± 1.61 mm to 4.24 ± 1.36 mm ($p < 0.0001$). The mean number of deep pockets (≥6 mm) decreased from 3.00 ± 0.93 to 0.85 ± 1.35 ($p < 0.0001$). Bleeding on probing around the test implants decreased from 71.5 ± 34.4% to 18.3 ± 28.6% ($p < 0.0001$). Plaque was found around 15.5 ± 25.8% of the surfaces before treatment and 11.3 ± 21.0% after 1 year, with no significant difference. Before treatment, pus was present around 34 out of 75 implants (45.3%), while at the end of the observation period, on 7 out of 71 (9.8%). After SPT, at the 1-year examination, six of these implants presented deep pockets with pus and were subsequently removed after a thoroughly discussion with the patients.

The clinical parameters around implants according to the defect configuration are listed in Table 3 (pre-op) and Table 4 (post-op). Initial presence of pus, plaque and BOP did not significantly differ among the groups. On the other hand, due to the different configuration of the intrabony lesions, mean PD and the number of sites with deep pockets were significantly lower in Class Ia group than in Ic and in Ie groups. No implants were lost in Class Ia and Ic. One implant out of 22 (4.5%) and 2 out of 13 (15.3%) were lost, respectively, in Class Ib and Id. Progression of peri-implantitis caused the removal of 3 out 13 implants (23%) in Class Ie. A summary of the clinical differences between the pre- and post-op parameters for the groups are listed in Table 5.

DISCUSSION

The aim of this prospective study was to evaluate the results of reconstructive procedure by means of DBBMC in peri-implantitis Class I defects. The results of this study confirm the preliminary positive outcomes from a previous study (Roccuzzo et al. 2011). The proposed approach is overall effective in the treatment of moderate to advanced peri-implantitis. Indeed, it was possible to maintain in function 65 out 71 implants in the patients that completed the 1-year SPT, even though complete resolution of the disease was not found to be a predictable result. Nevertheless, it must be noted that mean probing depth was reduced by almost 3 mm and the percentage of bleeding on probing around the test implants decreased by more than 70%.

When successful therapy was defined as PD ≤ 5 mm and absence of bleeding/suppuration on probing, 49.3% (37/75) of the implants were successfully treated. If PD ≤ 6 mm and no concomitant bleeding on probing were considered acceptable, 56% (42/75) of the implants were successfully

treated. These results are in accordance with two recent papers by Roos-Jansaer et al. (2014) and Carcuac et al. (2016).

Successful treatment outcome was not statistically related to baseline probing depth, even though a minor probability of success was observed with the increase of mean pre-op PD (OR = 0.72, p = 0.07). Moreover, successful treatment is more frequent in case of shallow pockets (PD ≤ 5 mm) at baseline (OR = 1.61, p = 0.14). At the end of the observation period, no deep pockets (PD ≥ 6 mm) were detected in the Ia group only, which can be explained by the assumption that resolution of the disease is more frequent for those implants with minor bone loss (Table 6). From a clinical point of view, this result seems quite interesting, even though the differences among the groups did not reach a statistically significant level, probably due to the small sample size of the groups. It is not possible to draw definitive conclusions, but these positive preliminary results encourage further investigation with a similar protocol. It has been reported that naturally occurring human peri-implantitis lesions most commonly feature a combined defect configuration including a supracrestal as well as an intrabony aspect (Schwarz et al. 2007). It must be emphasized that all selected individuals presented defects with a negligible supracrestal component. In particular, patients exhibited buccal dehiscence defects with a semicircular bone resorption to the middle of the implant body (i.e. Class Ib) in more than a third of the cases (35.7%). This is in contrast to what Schwarz et al. (2007) found in their study. The reason for this is far from been completely understood. One possible explanation, of the different distribution of lesion types, is that Class Ie defects appear most likely in the presence of a wide crest. If the buccal bone crest is thin, as it is frequently found in the maxilla, vestibular bone lesions are the first, and therefore the most common, to be formed. Moreover, the anatomy of the peri-implantitis defects depends on a wide variety of factors, including the implant diameter/position/angulation, and the local efficacy of patient-administered mechanical and/or chemical plaque control (Salvi & Ramseier 2015). It was not possible to confirm the clinical impression by Schwarz et al. (2010) that there appears to be a major benefit of using bone substitutes in the saucershaped defects (Class Ie). On the other hand, the results of this study seems in accordance with a recent review (Renvert & Polyzois 2015) that stated that a number of experimental studies have demonstrated that even where the defect is circumferential, the amount of regeneration achieved is limited. One of the possible reasons to explain the relatively modest results in a favourable anatomical configuration may be that both radiographic early diagnosis and effective debridement are very difficult in class Ie defects.

The importance of optimal plaque control before and after surgical therapy of peri-implantitis has been described extensively (Roccuzzo et al. 2011, Heitz-Mayfield et al. 2012, Serino et al. 2015, Renvert & Polyzois 2015) and has been confirmed in this study where both FMPS and local plaque

score were kept at a low level during the entire observation period. Nervertheless, the question about which regimen can be considered sufficient to obtain an adequate plaque control is open. The present research is, to the best of our knowledge, the only prospective study that presents the results on the treatment of peri-implantitis on a relatively large number of patients, recruited from a private clinic. The benefit, in accordance with the Consensus Report of 6th EWP (Lindhe & Meyle 2008), is that subjects recruited from private or public dental clinics, rather than university clinics, provide information on the "effectiveness" rather than "efficacy" in implant therapy. On that respect, patients were placed on an individually tailored SPT, based on the fact that pre-op plaque at implant site was 16.9 ± 27.4%, which must be considered an evidence of their ability to perform sufficient to excellent plaque control. It is interesting to note that at 1-year evaluation, both local Pl and BOP were reduced to an acceptable level with no statistical difference between the groups. This may indeed suggest that the study outcome is not directly related to the defect configuration even though shallow defects (Ia) presented lower baseline values.

The hypothesis that the length of time between implant placement and peri-implantitis treatment could influence the results was investigated, but no significant correlation was found, with no difference between the groups.

It has been reported that smoking seems to be a negative factor for treatment success (de Waal et al. 2015). In this study, the number of smokers was so limited (11 out of 75 patients) to draw any statistical conclusion.

The question if submerged healing and/or the application of a membrane may have resulted in more pronounced bone defect fill is still open. No sufficient data are present to leap to definitive conclusions on this matter. In this study, it was decided not to use the membrane in order to keep the procedure as simple as possible, in accordance with Chan et al. (2014) and Figuero et al. (2014) that concluded that the application of a membrane is costly, time consuming, technique sensitive and its application did not provided clear added value. Moreover, the spongy consistency of DBBMC, due to the collagen coating, after moistening in sterile saline, allowed easy adaptation and physical stabilization of the material even in non-containing defects, particularly important in the absence of a real GBR procedure (Roccuzzo et al. 2014). It must be said, however, that this surgical protocol is based on the assumption that a minimal amount of keratinized tissue is necessary for the formation of an effective seal around the implant. Therefore, in areas with no keratinized mucosa, a connective tissue graft was trimmed and adapted to ensure stability of the graft material. The rationale was to create clinical conditions as similar as possible among all patients. Nevertheless, the surgical procedure produced a small, but significant KT reduction, i.e. from 3.2 ± 1.4 mm to 2.6 ± 1.3 mm ($p = 0.001$). The question

if the absence of KT may have resulted in less pronounced bone defect fill is still open. Well-designed Randomized Controlled Trials (RCTs) with this aim are needed.

The question about the ideal protocol for bactericidal effect against adhering bacteria is also still open. (Schwarz et al. 2011). Lindhe & Meyle (2008) indicated that no single method of surface decontamination was found to be superior. The results of this study seem to confirm data from a recent research on mandibles of dogs (Parlar et al. 2009), where the treatment of peri-implantitis with decontamination method resulted in considerable bone fill around SLA implants.

According to Figuero et al. (2014) the literature does not clearly indicate superiority of a specific decontamination protocol. The 2 step procedure (EDTA + chlorhexidine gel) employed in this research has been described before (Roccuzzo et al. 2011) and has been selected because it presents the advantage of low cost and easy use. It must be noted that, according to Carcuac et al. (2016), the local use of chlorhexidine has no overall effect on treatment outcomes, even though the aim of their surgical procedure was implant surface decontamination only.

de Waal et al. (2015) have published data of 74 patients after resective surgical treatment. Peri-implantitis treatment was unsuccessful in 106 implants (57%) and 48 patients (67%) after 12 months. Low rate of success maybe due to the fact that each patient presented an average of 2.5 implants to treat and that 30% of the patients were smokers. On the contrary, in our study treatment was limited to one implant per patient and the percentage of smokers was limited.

In this study, decontamination of the implant surface was initiated with rotating brushes with titanium bristles as they offer easier access to narrow spaces and may adapt closely to the architecture of the implant (John et al. 2014). A recent in vitro study (Park et al. 2015) showed that the treatment with the titanium brush did not significantly change the roughness parameters in SLA surfaces.

For every patient, the deepest site was correlated to the outcome. None of the correlations were found statistically significant, even though the comparison between the initial depth of the defect in the patients with or without implant loss showed a possible clinical difference, but it did not reach a significant level, probably due to the limited number of lost implants. Ideally, this should be established on long-term RCTs (Esposito et al. 2012). Practical and ethical reasons, however, make effective RCTs in this field virtually impossible (Faggion et al. 2010).

Unlike other studies (Schwarz et al. 2007, 2009, 2010, Heitz-May- field et al. 2012, de Waal et al. 2015) where several implant types were pooled, this research evaluated the outcome in the same implants, placed by the same operator, under similar circumstances that differ by only one variable of interest, i.e. defect characteristics. As Carcuac et al. (2016) found that treatment success was higher in implants with a non-modified surface (79%) than those with a modified

surface (34%), future well-designed controlled clinical trials should present data on peri-implantitis defects around implants of one type only.

In conclusion, the technique described resulted in a clinical healthier situation around most implants. Within the limitations of this study, the preliminary data presented here support the regenerative treatment of all types of Class I defects. Nevertheless, due to the fact the complete resolution does not seem a predictable outcome, the clinical decision on whether implants should be removed or treated should be based on several patient related elements. Moreover, future years of observation are necessary to verify whether an incomplete osseous defect fill is adequate to ensure favourable long-term maintenance.

REFERENCES

American Academy of Periodontology (AAP). (2013) Peri-implant mucositis and peri-implantitis: a current understanding of their diagnoses and clinical implications. Journal of Periodontology 84, 436–443.

Atieh, M. A., Alsabeeha, N. H., Faggion, C. M. Jr & Duncan, W. J. (2013) The frequency of peri-implant diseases: a systematic review and meta-analysis. Journal of Periodontology 84, 1586–1598.

Carcuac, O., Derks, J., Charalampakis, G., Abrahamsson, I., Wennstrom, J. & Berglundh, T. (2016) Adjunctive systemic and local antimicrobial therapy in the surgical treatment of peri-implantitis: a randomized controlled clinical trial. Journal of Dental Research 95, 50–7.

Chan, H. L., Lin, G. H., Suarez, F., MacEachern, M. & Wang, H. L. (2014) Surgical management of peri-implantitis: a systematic review and meta-analysis of treatment outcomes. Journal of Periodontology 85, 1027–1041.

Esposito, M., Grusovin, M. G. & Worthington, H. V. (2012) Interventions for replacing missing teeth: treatment of perimplantitis. Cochrane Database of Systematic Reviews 6, Art. No.: CD004970.

Faggion, C. M., Listl, S. & Tu, Y. K. (2010) Assessment of endpoints in studies on peri-implantitis treatment. systematic review. Journal of Dentistry 38, 443–450.

Figuero, E., Graziani, F., Sanz, I., Herrera, D. & Sanz, M. (2014) Management of peri-implant mucositis and peri-implantitis. Periodontology 2000 66, 255–273.

Heitz-Mayfield, L. J. A., Salvi, G. E., Mombelli, A., Faddy, M. & Lang, N. P. (2012) Anti-infective surgical therapy of peri-implantitis. A 12- month prospective clinical study. Clinical Oral Implants Research 23, 205–210.

Heitz-Mayfield, L. J., Needleman, I., Salvi, G. E.& Pjetursson, B. E. (2014) Consensus statements and clinical recommendations for prevention and management of biologic and technical implant complications. International Journal of Oral & Maxillofacial Implants 29 (Suppl.), 346–350.

John, G., Becker, J. & Schwarz, F. (2014) Rotating titanium brush for plaque removal from rough titanium surfaces-an in vitro study. Clinical Oral Implants Research 25, 838–842.

Jung, U. W., Um, Y. J. & Choi, S. H. (2008) Histologic observation of soft tissue acquired from maxillary tuberosity area for root coverage. Journal of Periodontology 879, 934–940.

Khoshkam, V., Chan, H. L., Lin, G. H., MacEachern, M. P., Monje, A., Suarez, F., Giannobile, W. V. & Wang, H. L. (2013) Reconstructive procedures for treating peri-implantitis: a systematic review. Journal of Dental Research 92 (Suppl. 2), 131–138.

Klinge, B. & Meyle, J. (2012) EAO consensus report: peri-implant tissue destruction. the third EAO consensus conference 2012. Clinical Oral Implants Research 23 (Suppl. 6), 108–110.

Lang, N. P. & Berglundh, T. (2011) Working Group 4 of Seventh European Workshop on Periodontology. Periimplant diseases: where are we now? Consensus of the Seventh European Workshop on Periodontology. Journal of Clinical Periodontology 38 (Suppl. 11), 178–181.

Lindhe, J. & Meyle, J. (2008) Peri-implant dis- eases: consensus report of the Sixth European Workshop on Periodontology. Journal of Clinical Periodontology 35 (Suppl. 8), 282–285.

Park, J. B., Jeon, Y. & Ko, Y. (2015) Effects of titanium brush on machined and sand-blasted/ acidetched titanium disc using confocal microscopy and contact profilometry. Clinical Oral Implants Research 26, 130–136.

Parlar, A., Bosshardt, D. D., Cetiner, D., Schafroth, D., Unsal, B., Haytac, C. & Lang, N. P. (2009) Effects of decontamination and implant surface characteristics on re-osseointegration following treatment of peri-implantitis. Clinical Oral Implants Research 20, 391–399.

Renvert, S. & Polyzois, I. (2015) Clinical approaches to treat peri-implant mucositis and peri-implantitis. Periodontology 2000 68, 369–404.

Renvert, S., Polyzois, I. & Claffey, N. (2012) Surgical therapy for the control of peri-implantitis. Clinical Oral Implant Research 23 (Suppl. 6), 84–94.

Renvert, S., Polyzois, I. & Persson, G. R. (2013) Treatment modalities for peri-implant mucositis and peri-implantitis. American Journal of Dentistry 26, 313–318.

Roccuzzo, M., Bonino, F., Bonino, L. & Dalmasso, P. (2011) Surgical therapy of peri-implantitis lesions by means of a bovine- derived xenograft: comparative results of a prospective study on two different implant sur-faces. Journal of Clinical Periodontology 38, 738–745.

Roccuzzo, M., Gaudioso, L., Bunino, M. & Dalmasso, P. (2014) Long-term stability of soft tis-sues following alveolar ridge preservation: 10- year results of a prospective study around non-submerged implants. International Journal of Periodontics & Restorative Dentistry 34, 795–804.

Roos-Jansaker, A. M., Persson, G. R., Lindahl,C. & Renvert, S. (2014) Surgical treatment of peri-implantitis using a bone substitute with or without a resorbable membrane: a 5-year follow-up. Journal of Clinical Periodontology 41, 1108–1114.

Sahrmann, P., Attin, T. & Schmidlin, P. R. (2011) Regenerative treatment of peri-implantitis using bone substitutes and membrane: a systematic review. Clinical Implant Dentistry and Related Research 13, 46–57.

Salvi, G. & Ramseier, C. M. (2015) Efficacy of patient-administered mechanical and/or chemical plaque control protocols in the management of peri-implant mucositis. A systematic review. Journal of Clinical Periodontology 42 (Suppl. 16), 187–201.

Sanz, M. & Chapple, I. L. (2012) Clinical research on peri-implant diseases: consensus report of working group 4. Journal of Clinical Periodontology 39 (Suppl. 12), 202–206.

Schwarz, F., Herten, M., Sager, M., Bieling, K., Sculean, A. & Becker, J. (2007) Comparison of naturally occurring and ligature-induced peri-implantitis bone defects in humans and dogs. Clinical Oral Implants Research 18 (Suppl. 2), 161–170.

Schwarz, F., Sahm, N. & Becker, J. (2014) Combined surgical therapy of advanced peri-implantitis lesions with concomitant soft tissue volume augmentation. A case series. Clinical Oral Implants Research 25 (Suppl. 1), 132–136.

Schwarz, F., Sahm, N., Bieling, K. & Becker, J. (2009) Surgical regenerative treatment of peri-implantitis lesions using a nanocrystalline hydroxyapatite or a natural bone mineral in combination with a collagen membrane: a four- year clinical follow-up report. Journal of Clinical Periodontology 36, 807–814.

Schwarz, F., Sahm, N., Iglhaut, G. & Becker, J. (2011) Impact of the method of surface debridement and decontamination on the clinical outcome following combined surgical therapy of peri-implantitis: a randomized controlled clinical study. Journal of Clinical Periodontology 38, 276–284.

Schwarz, F., Sahm, N., Schwarz, K. & Becker, J. (2010) Impact of defect configuration on the clinical outcome following surgical regenerative therapy of peri-implantitis. Journal of Clinical Periodontology 37, 449–455.

Serino, G., Turri, A. & Lang, N. P. (2015) Maintenance therapy in patients following the surgical treatment of peri-implantitis: a 5-year follow-up study. Clinical Oral Implants Research 26, 950–956. [epub ahaed of print].

Tonetti, M., Iain, L. C., Søren, J. & Sanz, M. (2015) Primary and secondary prevention of periodontal and peri-implant diseases. Introduction to, and objectives of the 11th European Workshop on Periodontology consensus conference. Journal of Clinical Periodontology 42 (Suppl. 16), S1–S4.

de Waal, Y. C. M., Raghoebar, G. M., Meijer,H. J. A., Winkel, E. G. & van Winkelhoff, A.J. (2015) Prognostic indicators for surgical peri-implantitis treatment. Clinical Oral Implants Research 29. [Epub ahead of print].

Wiltfang, J., Zernial, O., Behrens, E., Schlegel, A., Warnke, P. H. & Becker, S. T. (2010) Regenerative treatment of peri-implantitis bone defects with a combination of autologous bone

and a demineralized xenogenic bone graft: a series of 36 defects. Clinical Implants Dentistry and Related Research 14 (Suppl. 3), 421–427.
Wohlfahrt, J. C., Lyngstadaas, S. P., Rønold, H. J., Saxegaard, E., Ellingsen, J. E., Karlsson, S. & Aass, A. M. (2012) Porous titanium granules in the surgical treatment of peri-implant osseous defects: a randomized clinical trial. International Journal of Oral & Maxillofacial Implants 27, 401–410.

Table 1. Demographic and clinical parameters (means ± SD) of patients according to the defect configuration

Defect configuration	Ia (*n* = 9)	Ib (*n* = 22)	Ic (*n* = 14)	Id (*n* = 13)	Ie (*n* = 13)	*p*
Male (%)	7 (77.8)	10 (45.5)	7 (50.0)	7 (53.9)	8 (61.5)	0.56
Age	51.7 ± 5.03	58.0 ± 9.8	57.1 ± 9.6	62.8 ± 6.8	57.8 ± 6.8	0.02*
Smoke	1 (11.1)	4 (18.2)	2 (14.3)	2 (15.4)	2 (15.4)	0.99
Function time†	55.1 ± 31.0	83.0 ± 47.9	73.0 ± 33.9	79.2 ± 61.7	57.7 ± 34.4	0.36

*Group Ia versus group Id (p = 0.003).
†Time in months from implant placement to treatment of peri-implantitis

Table 2. Overall results of treatment after 12 months (means ± SD)

	Baseline	Post-op	Difference	*p*
PD (mm)	7.17 ± 1.61	4.24 ± 1.36	2.92 ± 1.73	<0.0001
PD ≥ 6 mm*	3.00 ± 0.93	0.85 ± 1.35	2.15 ± 1.45	<0.0001
KT (mm)	3.21 ± 1.43	2.63 ± 1.34	0.58 ± 1.24	0.001
BOP (%)†	71.5 ± 34.4	18.3 ± 28.6	53.2 ± 39.4	<0.0001
PI (%)+	15.5 ± 25.8	11.3 ± 21.0	4.2 ± 26.4	0.15

*Number of sites per patient with PD ≥ 6 mm.
†Bleeding on probing at the implant site.
+Plaque at the implant site.

Table 3. Clinical parameters around the implants before treatment in the various groups (means ± SD)

Defect configuration	Ia (*n* = 9)	Ib (*n* = 22)	Ic (*n* = 14)	Id (*n* = 13)	Ie (*n* = 13)	*p*
PUS	3 (33.3%)	6 (27.3%)	6 (42.9%)	7 (53.9%)	7 (53.9%)	0.44
PD (mm)	5.83 ± 0.49	6.85 ± 1.52	7.75 ± 1.44	7.42 ± 1.54	7.73 ± 1.98	0.007*
PD ≥ 6 mm†	2.22 ± 0.44	2.68 ± 0.89	3.50 ± 0.76	3.23 ± 1.17	3.31 ± 0.63	0.001‡
KT (mm)	3.33 ± 0.71	3.09 ± 1.48	3.50 ± 1.09	3.08 ± 2.02	3.15 ± 1.52	0.98
BOP (%)§	58.3 ± 30.6	77.3 ± 28.8	75.0 ± 36.7	76.9 ± 37.4	61.5 ± 40.3	0.44
PI (%)¶	8.3 ± 17.7	14.8 ± 28.5	8.9 ± 21.0	23.1 ± 25.9	21.2 ± 30.6	0.32

*For PD (mm): group Ia versus group Ic (p = 0.002) & group Ia versus group Ie (p = 0.003).
†Number of sites per patient with PD ≥ 6 mm.
‡For PD ≥ 6 mm: group Ia versus group Ic (p = 0.0009) & group Ia versus group Ie (p = 0.001).
§Bleeding on probing at the implant site.
–Plaque at the implant site.

Table 4. Clinical parameters around the implants 1 year after treatment in the groups (means ± SD)

Defect configuration	Ia (*n* = 9)	Ib (*n* = 22)	Ic (*n* = 14)	Id (*n* = 13)	Ie (*n* = 13)	*p*
PUS	0	1 (4.6%)	0	2 (15.4%)	4 (30.8%)	0.04
PD (mm)	3.56 ± 0.51	4.25 ± 1.56	4.30 ± 1.34	4.25 ± 1.40	4.63 ± 1.42	0.42
PD ≥ 6 mm*	0	1.00 ± 1.27	0.93 ± 1.50	0.69 ± 1.49	1.23 ± 1.54	0.11
KT (mm)	2.33 ± 1.12	2.55 ± 1.22	3.29 ± 1.27	2.31 ± 1.49	2.62 ± 1.56	0.26
BOP (%)†	8.33 ± 12.5	18.2 ± 32.0	16.1 ± 28.8	23.1 ± 33.0	23.1 ± 27.9	0.70
PI (%)‡	11.1 ± 18.2	12.5 ± 22.8	7.1 ± 18.2	11.5 ± 19.4	13.5 ± 26.3	0.91
REC	0.89 ± 0.78	0.68 ± 0.78	0.50 ± 0.76	0.77 ± 0.73	0.69 ± 0.75	0.73
Implants removed	0	1 (4.6%)	0	2 (15.4%)	3 (23.1%)	0.13

*Number of sites per patient with PD ≥ 6 mm.
†Bleeding on probing at the implant site.
‡Plaque at the implant site.

Table 5. Differences pre-post-treatment among the groups (means ± SD)

Defect configuration	Ia (*n* = 9)	Ib (*n* = 22)	Ic (*n* = 14)	Id (*n* = 13)	Ie (*n* = 13)	*p*
PUS	3/3 (100%)	5/6 (83%)	6/6 (100%)	5/7 (71%)	4/7 (57%)	0.43
PD (mm)	2.28 ± 0.75	2.60 ± 1.50	3.45 ± 1.74	3.17 ± 1.34	3.10 ± 2.69	0.41
PD ≥ 6 mm*	2.22 ± 0.44	1.68 ± 1.21	2.57 ± 1.74	2.54 ± 1.56	2.08 ± 1.75	0.16
KT (mm)	1.00 ± 1.00	0.55 ± 1.53	0.21 ± 1.12	0.77 ± 1.36	0.54 ± 0.78	0.38
BOP (%)†	50.0 ± 35.4	59.1 ± 35.8	58.9 ± 41.1	53.8 ± 44.3	38.5 ± 42.8	0.66
PI (%)‡	-2.8 ± 8.3	2.3 ± 26.6	1.8 ± 30.2	11.5 ± 30.0	7.7 ± 27.7	0.53

*Number of sites per patient with PD ≥6 mm.
†Bleeding on probing at the implant site.
‡Plaque at the implant site.

Table 6. Statistical differences (p) of the intra-group treatment effects (pre- versus post-)

Defect configuration	Ia (*n* = 9)	Ib (*n* = 22)	Ic (*n* = 14)	Id (*n* = 13)	Ie (*n* = 13)
PUS elimination	0.08	0.06	0.03	0.06	0.38
PD (mm)	0.008	<0.0001	0.001	0.002	0.002
PD ≥ 6 mm*	0.005	0.0001	0.002	0.003	0.006
KT (mm)	0.02	0.07	0.44	0.06	0.03
BOP (%)	0.01	<0.0001	0.002	0.005	0.01
PI (%)‡	0.32	0.71	0.71	0.12	0.28

*Number of sites per patient with PD ≥ 6 mm.
†Bleeding on probing at the implant site.
‡Plaque at the implant site.

Fig. 1. (a) Lower left premolar ceramic crown on an implant, placed 9 years before, showing excessive probing depth, marginal soft tissue recession, absence of keratinized tissue and pus. (b) Periapical radiograph, taken 9 years after implant placement, reveals a crater-like defect.

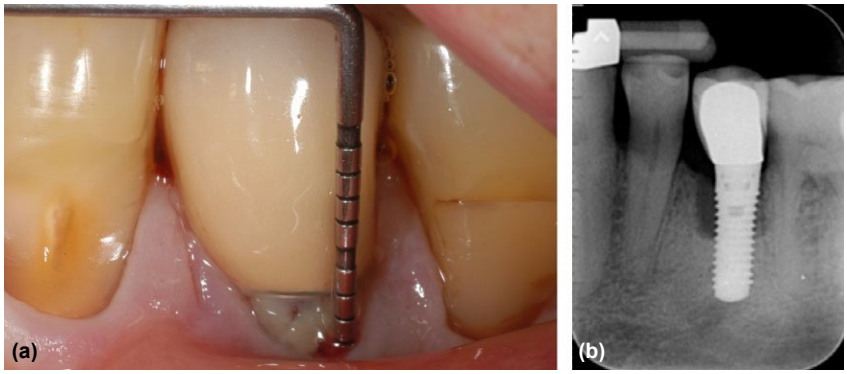

Fig. 2. (a) After raising a full thickness flap, the granulation tissue is removed by means of a titanium brush. (b) Application of 24% EDTA for 2 min. (c) Application of 1% Chlorhexidine gel for 2 min. (d) Class Ic peri-implantitis lesion after the decon-tamination of the implant surface.