

AperTO - Archivio Istituzionale Open Access dell'Università di Torino

**Management of Paprosky type three B acetabular defects by custom-made components: early results**

**This is the author's manuscript**

*Original Citation:*

*Availability:*

This version is available <http://hdl.handle.net/2318/1737477> since 2020-04-27T16:52:30Z

*Published version:*

DOI:10.1007/s00264-018-4203-5

*Terms of use:*

Open Access

Anyone can freely access the full text of works made available as "Open Access". Works made available under a Creative Commons license can be used according to the terms and conditions of said license. Use of all other works requires consent of the right holder (author or publisher) if not exempted from copyright protection by the applicable law.

(Article begins on next page)

# Management of Paprosky type three B acetabular defects by custom-made components: early results

Alessandro Aprato, Matteo Giachino, Paolo Bedino, Danilo Mellano, Raimondo Piana & Alessandro Massè

Orthopaedic Department, Città della Salute e della Scienza, University of Turin, Viale 25 Aprile 137 int 6, 10133, Turin, Italy

Corresponding author: Alessandro Aprato [ale\\_aprato@hotmail.com](mailto:ale_aprato@hotmail.com)

## Abstract

### Purpose

Our study aims at the evaluation of the recently introduced Lima Promade custom-made acetabular device for the treatment of complex acetabular Paprosky 3B defects.

### Methods

Between 2016 and 2018, eight patients with major acetabular osteolysis and multiple revisions history were treated with a custom-made implant in a single centre and by a single surgeon. We assessed patients' demographics, peri-operative data, and complications and a specific questionnaire was submitted to the surgeon after each procedure.

### Results

All the devices were correctly positioned. In two over eight cases, a post-operative dislocation occurred, where extensive soft tissue impairment was present. The questionnaire showed a good pre-operative and intra-operative experience of the surgeon.

### Conclusions

The Promade custom-made acetabular system showed encouraging results for complex defects and the entire procedure was positively rated. Further analysis with a higher number of cases and a longer follow-up should be performed for a complete clinical and cost-effective evaluation.

**Keywords:** Hip . Revision . THA . Custom-made . Acetabular defect . Paprosky

## Introduction

The number of primary total hip arthroplasty (THA) over the last decades increased constantly; therefore, the number of revisions will grow considerably in the very next years [1, 2]. The necessity for revision comes from the failure of the primary implant, which can lead to multiple factors: Aseptic loosening (55.2%), recurrent dislocations (11.8%), septic loosening (7.5%), and periprosthetic fractures (6%) are the most common causes [2]. Revisions are often a demanding procedure and they become more challenging when further subsequent revisions are required. The issue in hip revision is usually the bone loss management. The first hit to the bone stock is invariably produced to implant the first cup, and then several mechanical and biological factors act to reduce either the volume or the quality of the periprosthetic bone. A revision procedure is thus often associated with a condition of mild or advanced bone loss, and re-revisions may enhance this concern to the critical line (Figs. 1, 2, 3, and 4).

Surgical issues come often from the acetabular side and two specific aspects are responsible for it. On the one hand, there is the difficulty of osteolysis assessment on standard radiographs that often lead to underestimation or failure to recognise periacetabular defects; on the other hand, the weight bearing load on a small surface is a mechanical and biological issue for stability [3].

The correct identification, classification, and comprehension of the bone loss are currently essential to achieve the best results in revision surgery [4]. Paprosky classification is the most known and gives the surgeon the bases for implant choice in revisions. Paprosky 3B lesions consist of a severe osteolysis of the medial wall, a complete disruption of the anterior column, a severe involvement of the posterior column, and a proximalization and medialization of the hip centre. The remaining bone bed is extremely limited, and pelvic discontinuity could be either observed or not. The ultimate aim of the revision surgery is to provide a stable fixation of the prosthetic component while trying to restore an appropriate centre of rotation of the hip, which in this case should be distalized and lateralized [5]. Several solutions have been proposed ranging from impaction grafts, metal meshes, cages, rings, structural bone grafts, augments, and patient-specific implants [6,7,8]. Literature shows that every solution has its own pros and cons and a definitive fulfilling option has yet to come [9,10,11,12]. In the last 20 years, a different approach to massive acetabular defects has been introduced and it is represented by custom-made implants. The rationale of patient-specific devices is the chance of modeling the prosthetic component on the altered anatomy of a multiple revised hip, instead of adapting standard elements. Some encouraging results of the concept have been shown, but a considerable variability in methodology, implants design, and indications suggests that further examinations are necessary [13, 14].

Our aim is to show the early results of a sample population with a story of multiple revisions and complex acetabular defects treated with custom-made implants designed and manufactured by LimaCorporate, through their Promade program. These cups have the distinctive characteristic of being designed starting from a central core, usually the selected centre of rotation, from which an osteointegrative trabecular titanium structure grows, in order to fill the defects and to provide a good fitting for structural stability. Furthermore, screws positioning could be completely personalized.

## **Material and methods**

Between June 2016 and August 2018, our patients with a Paprosky 3B acetabular defect were presented as candidates for a Promade custom-made acetabular component.

The diagnostic protocol followed by every patient was standardized and consisted of a CT scan (with metal suppression algorithm applied), followed by virtual 3D reconstructions and 3D model printing. Cases were then defined eligible for custom-made implants on the basis of the complexity of the bone defect, particularly if the bone gap appeared to be insufficiently filled by standard or advanced devices (e.g., augments or grafts) either for dimension or geometry. Patients with pelvic discontinuity were excluded.

Once selected, each case was included into the manufacturer's own workflow: the patient-specific implant proposal was discussed between surgeons and engineers for biomechanical and clinical implications in a multi-stage dialog that led to the definitive design of the device. The custom-made implant was then 3D printed and prepared for surgery. Demographic and clinical data were collected from patients' medical records. A specific questionnaire was submitted to the chief surgeon for testing the usefulness of the 3D-printed model for the initial assessment, the planning accordance with the clinical findings, the design process, the ease of bone preparation and implant, the final position and stability of the components, and the overall experience of the case. Every item was rated from 0 to 5. All the procedures were performed in a single centre and by a single expert surgeon.

## Results

Over the 26 months of observation, a total of eight patients were treated with a Promade acetabular implant. Seven patients were diagnosed for aseptic loosening of a multiple revised THA, one patient presented a post-traumatic massive bone resorption in an inveterate acetabular fracture with chronic femoral head dislocation. Although technically the latter was a first implant, the severe osteolysis and the lack of bone stock could have been compared to a Paprosky 3B lesion.

Patients' demographics and data from previous surgeries are shown in Table 1.

In each case, some modifications to the initial design proposed by the engineers were realized.

A mean surgical time of 173 minutes was found with a wide range of 90–278 minutes. In one case, a procedure of femoral osteotomy and adductor tenotomy was associated. In two over eight cases (25%), a peri-operative blood transfusion was required.

All the devices were implanted in a satisfying final position with correct orientation of the cup. Full weight bearing was allowed at a mean time of 46.5 days post-operatively (range 40–60).

Complications are summarized in Table 2. Both cases of early post-operative dislocations were secondary to a serious gluteal insufficiency reported during the procedure. One patient did not require any further action after closed reduction, while the other underwent a substitution of the liner with a constrained one. The single reported infection consisted of an early supra-fascial hematoma infected with methicillin-susceptible *Staphylococcus aureus*, treated with surgical drainage and antibiotics. The questionnaire results are summarized in Fig. 5.

## Discussion

Massive acetabular osteolysis in revision THA is one of the major issues of contemporary orthopaedic surgery. Paprosky 3B defects represent a challenge for the restoration of proper hip biomechanics with durable results over time. Among the variety of solutions proposed, some are still a valid option, although the surgeon must know the advantages and limits of each one. For smaller defects, good results could be achieved with standard implants or jumbo cups that give good stability and osteointegration but require a significant bone contact. In case of osteolysis of both the anterior and posterior column, this is hard to obtain and the primary stability often results impaired; moreover, a suboptimal positioning of the cup rise the risk for an early loosening [6, 7, 15,16,17,18]. Cages and rings have the peculiarity of bridging the defect respectively with or without osteointegrative qualities and can be positioned independently from the final cup, which is usually cemented into the device after stability is achieved. Impaction bone grafting can be associated and the bone stock may be improved with that. However, good stability for screw fixation has to be available, as the impaction graft gives insufficient support and the shape of the implant can rarely fill the gap [16, 19,20,21,22]. Structural bone allografts could be associated to revision implants for the improvement of primary stability of the components, however concerns on the integration of the graft still exist [21, 23, 24]. Moreover, encouraging results are often obtained with metal augments, which are frequently offered in modular sets with different shapes and dimensions to best fill the gaps. The aid of tantalum or trabecular titanium stimulates osteointegration and stability over time, but for that to happen, a perfect primary stability has to be achieved. Conversely, the risk for early mobilization and failure of the augment is high. The main difficulties to reach a good fit for the augmented cups are to find a favorable matching between the osteolysis area and the implant, and the forced screws direction due to the thickness of the device [25, 26].

The new approach to large acetabular defects by custom-made implants has become a valid solution over the last years [27]. Encouraging results have been shown by previous studies, although no large case-series

still exist [8, 14, 28]. Furthermore, every manufacturer follows its own constructive philosophy and a direct comparison between implants is difficult to produce. Our preliminary study shows an overall favourable performance of the Promade if compared to other systems.

The mean age of the recruited patients appeared to be rather low for a multiple revision history, mainly because we consider higher functional requirements a good criterium for customization. Our workflow also considers the chance of a custom-made implant only after an accurate assessment on the pre-operative 3D-printed model, and only after a complete evaluation of the available conventional solutions has been made. The design of the devices was entrusted to the manufacturer's engineers, which used to propose an initial layout successively discussed and modified in accordance with the surgeons. The main variations to the first proposals were made for the resolution of undesired encumbrances. Furthermore, the screw fixation on the pubic ramus was frequently discussed and erased from the final implant for surgical safety reasons, as well as the poor fixation strength offered.

Among the positive findings, the surgeries were all favourably completed and the operative time never exceeded the expected for a complex revision procedure. Every component also reached its final position with a good orientation of the cup, both for coverage and anteversion. It has to be considered that the complicated spatial geometry of the devices often allows a unique positioning, so if an accurate preparation is produced, the final location of the implant will be correct.

A satisfactory stability of the component was reached with primary fit and screws fixation at the end of every procedure, and after a precautionary period of about six to eight weeks full weight bearing was allowed. This protection was thought to maximize the osteointegrative process and reduce the chance of micro movements at the bone-metal interface.

Our rate of complications is comparable with other similar studies [8, 28]. In particular the risk of dislocations persists, as it is known for being a major concern of revision surgery. As we found intra operatively, the hazard for instability of the prosthesis is much higher if a deficiency of the abductor apparatus is observed. In those cases, further actions for mechanical stability should be taken, as in our case a constrained liner had been positioned. In selected cases, an MRI assessment of the periprosthetic soft tissues could be performed prior to surgery.

The personal experience of the surgeon showed a general satisfaction for the procedures. The 3D-printed model helped in the decision-making process for getting to the custom-made cup. From two years on our protocol for complex hip revisions comprehend a physical print of the case and a successive collegial assessment. In some cases, a surgical simulation with real implants is carried on the model.

The acetabular preparation for the custom-made component sometimes was found to be quite tricky, mainly because of the convoluted geometry of the implant that had to be perfectly fitted into the bone. However, we experienced a significant learning curve for the optimization of both the design of the device and the intra-operative maneuvers to make it more accessible.

We consider the customization of the acetabular component a valid choice for exceptionally complex defects. However, some aspects should still be examined for a complete evaluation of the technique. A substantial issue regarding the costs of the implants is currently of major interest, as the entire process of designing and producing the component is still certainly more expensive than the standard available solutions. Along with the considerations on the economics, the real effectiveness of the procedure has yet to be demonstrated. Although the first preliminary studies carried on the custom-made implants are showing encouraging results, real long-term findings are still missing. Also the significant differences in the implants design and constructive concepts could affect the homogeneity of the results. Once a long-term analysis of custom-made devices survival rate will be available, a real cost-effective study could be produced. A conclusive evaluation should provide an effective assessment of clinical and economical data between standard and custom-made

implants, having the latter the aim of reducing further revision surgery. Our preliminary study has the purpose to lay the basis for a wider analysis of the real effectiveness of this specific procedure. If a significant benefit will be demonstrated, specific codifications and new reimbursements protocols should be proposed.

Current limits of this study are the small number of cases and the short follow-up. Despite that, we are experiencing a slight increase in the indications as we are getting used to the technique.

Our experience suggests an improvement of preparation tools for the acetabular cavity, which is frequently demanding. Modular trials and specific milling machines could be combined for recreating the irregular surface of the implant and facilitate the fitting. Furthermore, specific radiologic protocols for the post-operative assessment of the implant stability should be developed, as the amount of metal combined with the complex geometry often conceals the bone-implant interface and radiolucencies are challenging to interpret.

The new custom-made cup approach proposed by Promade is showing promising results, although the small population and the short follow-up suggest that further analysis should be produced for better comprehend the emerging apparent advantages.

## Compliance with ethical standards

Conflict of interest: The authors declare that they have no conflicts of interest

## References

1. Australian Orthopedic Association (2017) National joint replacement registry. Annual report 2017
2. Kurtz S, Ong K, Lau E, Mowat F, Halpern M (2007) Projections of primary and revision hip and knee arthroplasty in the United States from 2005 to 2030. *J Bone Joint Surg Am* 89(4):780–785
3. Kitamura N, Pappademos PC, Duffy PR 3rd, Stepniewski AS, Hopper RH Jr, Engh CA Jr, Engh CA (2006) The value of anteroposterior pelvic radiographs for evaluating pelvic osteolysis. *Clin Orthop Relat Res* 453:239–245
4. Paprosky WG, Perona PG, Lawrence JM (1994) Acetabular defect classification and surgical reconstruction in revision arthroplasty. A 6-year follow-up evaluation. *J Arthroplast* 9(1):33–44
5. Kim DH, Cho SH, Jeong ST, Park HB, Hwang SC, Park JS (2010) Restoration of the center of rotation in revision total hip arthroplasty. *J Arthroplast* 25(7):1041–1046
6. Shon WY, Santhanam SS, Choi JW (2016) Acetabular reconstruction in total hip arthroplasty. *Hip Pelvis* 28(1):1–14
7. Issack PS, Nousiainen M, Beksac B, Helfet DL, Sculco TP, Buly RL (2009) Acetabular component revision in total hip arthroplasty. Part II: management of major bone loss and pelvic discontinuity. *Am J Orthop* 38(11):550–556
8. Myncke I, van Schaik D, Scheerlinck T (2017) Custom-made triflanged acetabular components in the treatment of major acetabular defects. Short-term results and clinical experience. *Acta Orthop Belg* 83(3):341–350
9. Paprosky WG, Magnus RE (1994) Principles of bone grafting in revision total hip arthroplasty. Acetabular technique. *Clin Orthop Relat Res* 298:147–155

10. Regis D, Sandri A, Bonetti I, Bortolami O, Bartolozzi P (2012) A minimum of 10-year follow-up of the Burch-Schneider cage and bulk allografts for the revision of pelvic discontinuity. *J Arthroplast* 27(6):1057–1063
11. Van Kleunen JP, Lee GC, Lementowski PW, Nelson CL, Garino JP (2009) Acetabular revisions using trabecular metal cups and augments. *J Arthroplast* 24(6):64–68
12. Petrie J, Sassoon A, Haidukewych GJ (2013) Pelvic discontinuity: current solutions. *Bone Joint J* 95-B(11 Suppl A):109–113
13. TauntonMJ, Fehring TK, Edwards P, Bernasek T, Holt GE, Christie MJ (2012) Pelvic discontinuity treated with custom triflange component: a reliable option. *Clin Orthop Relat Res* 470(2):428–434
14. Wyatt MC (2015) Custom 3D-printed acetabular implants in hip surgery: innovative breakthrough or expensive bespoke upgrade? *Hip Int* 25(4):375–379
15. Sheth NP, Nelson CL, Springer BD, Fehring TK, Paprosky WG (2013) Acetabular bone loss in revision total hip arthroplasty: evaluation and management. *J Am Acad Orthop Surg* 21:128–139
16. Brubaker SM, Brown TE, Manaswi A et al (2007) Treatment options and allograft use in revision total hip arthroplasty the acetabulum. *J Arthroplast* 22:52–56
17. Dammerer D, Putzer D, Glodny B, Petersen J, Arrich F, Krismer M, Biedermann R (2018) Occult intra-operative periprosthetic fractures of the acetabulum may affect implant survival. *Int Orthop*. <https://doi.org/10.1007/s00264-018-4084-7>
18. Miettinen SS, Mäkinen TJ, Laaksonen I, Mäkelä K, Huhtala H, Kettunen J, Remes V (2017) Early aseptic loosening of cementless monoblock acetabular components. *Int Orthop* 41(4):715–722
19. Hansen E, Shearer D, Ries MD (2011) Does a cemented cage improve revision THA for severe acetabular defects? *Clin Orthop Relat Res* 469:494–502
20. Schreurs BW, Bolder SB, Gardeniers JW, Verdonschot N, Slooff TJ, Veth RP (2004) Acetabular revision with impacted morsellised cancellous bone grafting and a cemented cup. A 15- to 20-year follow-up. *J Bone Joint Surg (Br)* 86:492–497
21. Zazgyva A, Zuh SG, Roman CO, Gergely I, Pop TS (2016) Acetabular reconstruction with a reinforcement device and bone grafting in revision arthroplasty—a mean five years of follow-up. *Int Orthop* 40(8):1631–1638
22. Mao Y, Xu C, Xu J, Li H, Liu F, Yu D, Zhu Z (2015) The use of customized cages in revision total hip arthroplasty for Paprosky type III acetabular bone defects. *Int Orthop* 39(10):2023–2030
23. Massè A, Aprato A, Turchetto L, Rizzi L, Lasagna G, Arrigoni C, Ganz R (2015) Reconstruction with rib graft for acetabular revision in pelvic discontinuity: an extreme solution? *Tech Orthop* 30(4): 269–274
24. Dewal H, Chen F, Su E, Di Cesare PE (2003) Use of structural bone graft with cementless acetabular cups in total hip arthroplasty. *J Arthroplast* 18:23–28
25. Flecher X, Appy B, Parratte S, Ollivier M, Argenson JN (2017) Use of porous tantalum components in Paprosky two and three acetabular revision. A minimum five-year follow-up of fifty one hips. *Int Orthop* 41(5):911–916
26. Ballester Alfaro JJ, Sueiro Fernández J (2010) Trabecular metal buttress augment and the trabecular metal cup-cage construct in revision hip arthroplasty for severe acetabular bone loss and pelvic discontinuity. *Hip Int* 20(Suppl 7):S119–S127

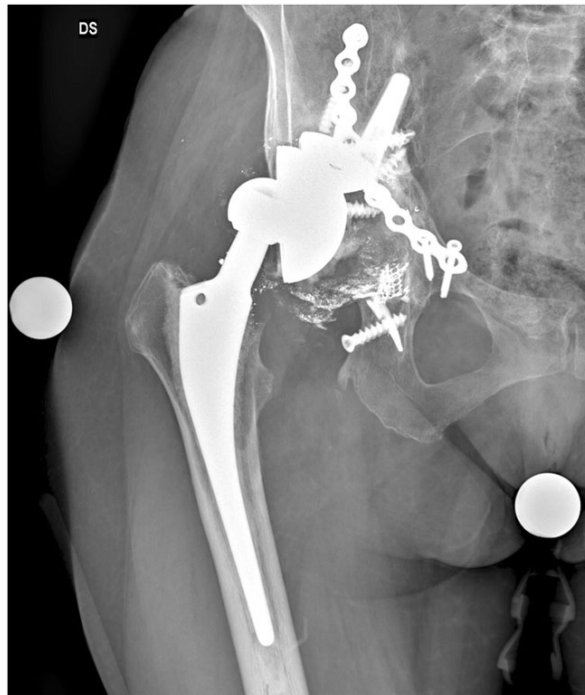27. Aprato A, D'Amelio A, Marra F, FavutoMM,Mellano D, Massè A (2017) 3D customizing in revision hip replacement. In: Aprato A (ed) 3d applications in hip surgery, 1st edn. Nova biomedical, New York, pp 162–163

28. Holt GE, Dennis DA (2004) Use of custom triflanged acetabular components in revision total hip arthroplasty. Clin Orthop Relat Res 429:209–214



## Figures

**Fig. 1**



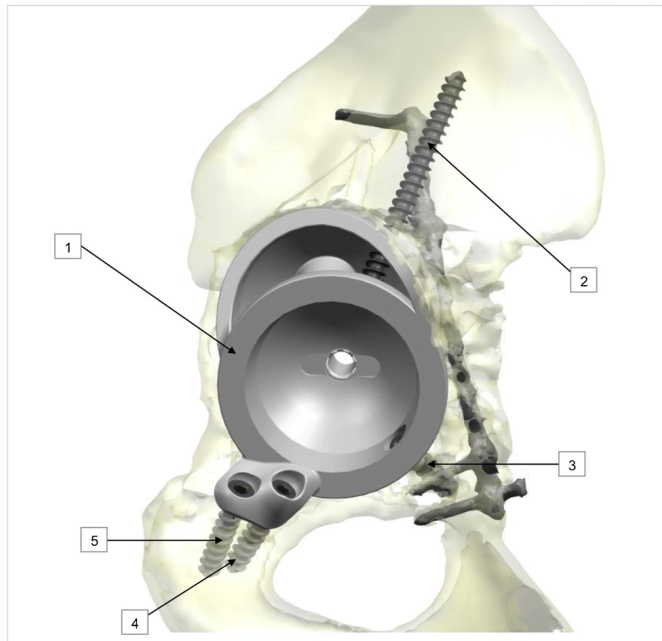
A multiple revision case with massive periacetabular resorption and poor bone stock

**Fig. 2**



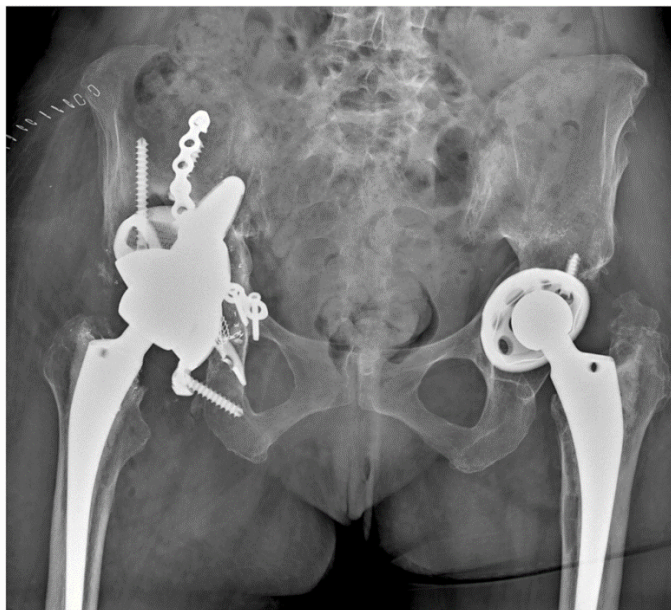
The custom-made implant is designed in close collaboration with the engineers. Both the design and screws position are discussed together

**Fig. 3**



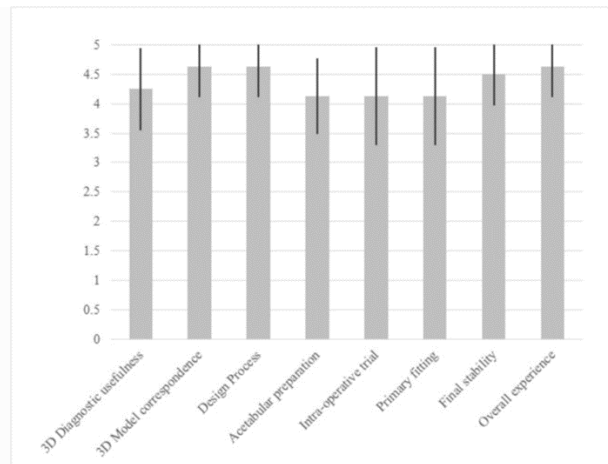
Both the design and screws position are customizable

**Fig. 4**



Post-operative control of the same case, a good stability was achieved and the defect filled

**Fig. 5**



Questionnaire results

## Tables

**Table 1 Patients demographics**

	Number of patients ( <i>n</i> = 8)
Mean age in years	62 (SD 10.4, range 32)
Males (%)	3 (37.5%)
Females (%)	5 (62.5%)
Mean BMI	27 (SD 5, range 12.3)
Mean follow-up in months	13.5 (SD 9.3, range 25)
	Number of patients ( <i>n</i> = 7)
Mean time from first THA, years	17.3 (SD 6.7, range 22)
Mean time from last revision, years	2.4 (SD 1.2, range 3)
Mean number of previous revisions	3.3 (SD 0.7, range 2)

**Table 2 Major complications**

	<b>Patients (<i>n</i> = 8)</b>
Dislocations (%)	2 (25%)
Infections (%)	1 (12.5%)
Loosening (%)	0
Hyatrogenic fractures (%)	0
Vascular or nervous injuries (%)	0