In vitro evaluation of a closed-bowel technique for one-layer hand-sewn inverting end-to-end jejunojejunosotomy in the horse

In Vitro Evaluation of a Closed-Bowel Technique for One-Layer Hand-Sewn Inverting End-to-End Jejunojejunosotomy in the Horse

MARCO GANDINI medvet

Abstract

Objective— To report a technique for closed-bowel 1-layer inverting end-to-end jejunojejunal anastomosis in horses.

Study Design— Experimental study.

Sample population— Fresh cadaveric jejunal segments from 12 horses.

Methods— For each bowel segment a 1-layer closed and a 2-layer inverting end-to-end jejunojejunosotomy was created. Anastomosis construction time and anastomotic bursting pressure were measured and compared.

Results— Closed-bowel anastomosis was significantly faster to create than a 2-layer technique. Luminal narrowing (<30%) was similar with both techniques and comparable with other inverting techniques. Bursting pressure was significantly higher for the 2-layer technique, although all anastomoses resisted pressures higher than those reported for other jejunojejunal anastomosis techniques.

Conclusions— A 1-layer hand-sewn, closed, inverting jejunojejunosotomy using a modified Doyen clamp was easy and faster to perform, and resulted in functional characteristics similar to, a 2-layer hand-sewn inverting technique.

Clinical Relevance— A closed, 1-layer inverting technique could be considered for equine jejunal anastomosis but requires in vivo evaluation before recommendation for clinical use.

INTRODUCTION

IN HUMAN AND small animal intestinal surgery apposing 1-layer suture patterns are preferred for anastomoses,[1] whereas in equine surgery an inverting 2-layer is more popular.[2] Recently, some authors have questioned the superiority of the 2-layer technique.[3, 4] A 2-layer inverting pattern has been favored to minimize adhesion formation, whereas in other species serosal patching or omentalization of the anastomosis have been used to reduce adhesion formation, these techniques are not applicable to horses. Similarly, minimizing manipulation and contamination during surgery to decrease bowel inflammation and risk of complication is considered important. In part, these issues have been addressed through use of intestinal stapling devices, although their dimensions sometimes limit their use in horses,[2] especially for end-to-end anastomosis.

Our purpose was to describe a closed, 1-layer inverting technique for jejunojejunosotomy that avoids open bowel ends and therefore minimizes the likelihood of intraoperative contamination. We compared functional characteristics of this technique with those of a hand-sewn 2-layer jejunojejunal anastomosis using equine jejunal specimens. We hypothesized that a closed, 1-layer hand-sewn anastomosis could be constructed more quickly, would have a similar lumen, and would be as strong as a hand-sewn 2-layer inverting anastomosis. To test this we constructed end-to-end anastomoses in fresh jejunal specimens and measured anastomotic construction time, luminal diameter, and bursting pressure, and evaluated failure mode.

MATERIALS AND METHODS

Jejunal Specimens

Jejunal segments were collected from 12 slaughtered horses. Specimens were harvested at least 2 m proximal to the ileocecal valve and transported and stored at room temperature in lactated Ringer's solution. Each segment was used to create 2 end-to-end jejunal anastomoses: a 1-layer hand-sewn inverting end-to-end and a 2-layer inverting end-to-end anastomoses. All anastomoses were created, stored in lactated Ringer's solution at room temperature and tested within 4 hours after death of the horse.

Surgical Technique

Closed End-to-End Technique. The jejunal segment to be resected was identified and the mesenteric vessels supplying the segment were isolated, double ligated, and transected. The regions to be anastomosed were apposed side to side in an antiperistaltic fashion. Two seromuscular stay sutures (2-0 polyglactin 910) were inserted through both segments on the mesenteric and antimesenteric borders, respectively, to stabilize the position of the segments relative to each other (1, 2). To mimic the conventional angle of bowel transection, the sutures were positioned to create an ~60° angle to the longitudinal axis of the bowel from the mesenteric edge. A straight Doyen intestinal clamp, modified by narrowing the jaws to 3 mm, was placed across both segments at the same 60° angle just distal (i.e., away from the loop to be resected) to the stay sutures (Fig 2B). A metal ring was slid over the jaws of the bowel clamp and moved proximally until it was secure, locking the jaws to prevent inadvertent release of the bowel and to apply even pressure over the surface of both segments (Fig 2B).

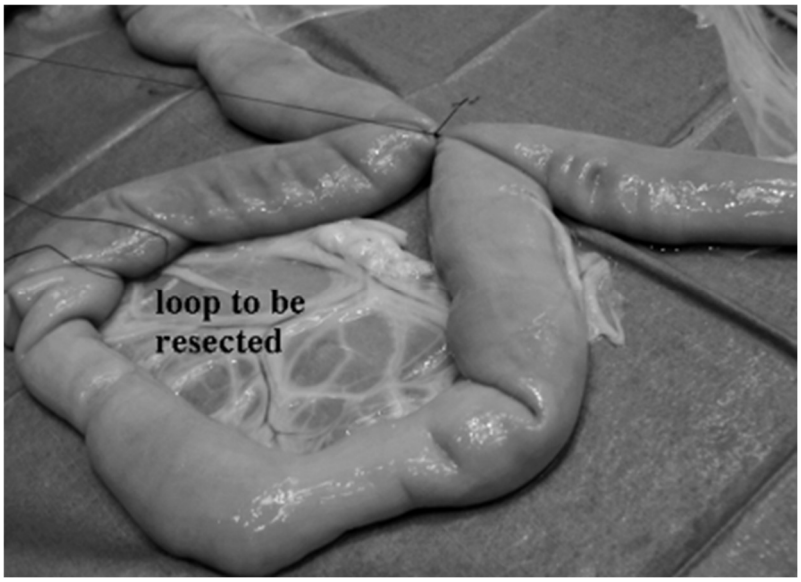

Figure 1

Open in figure viewerPowerPoint

Location of stay sutures.

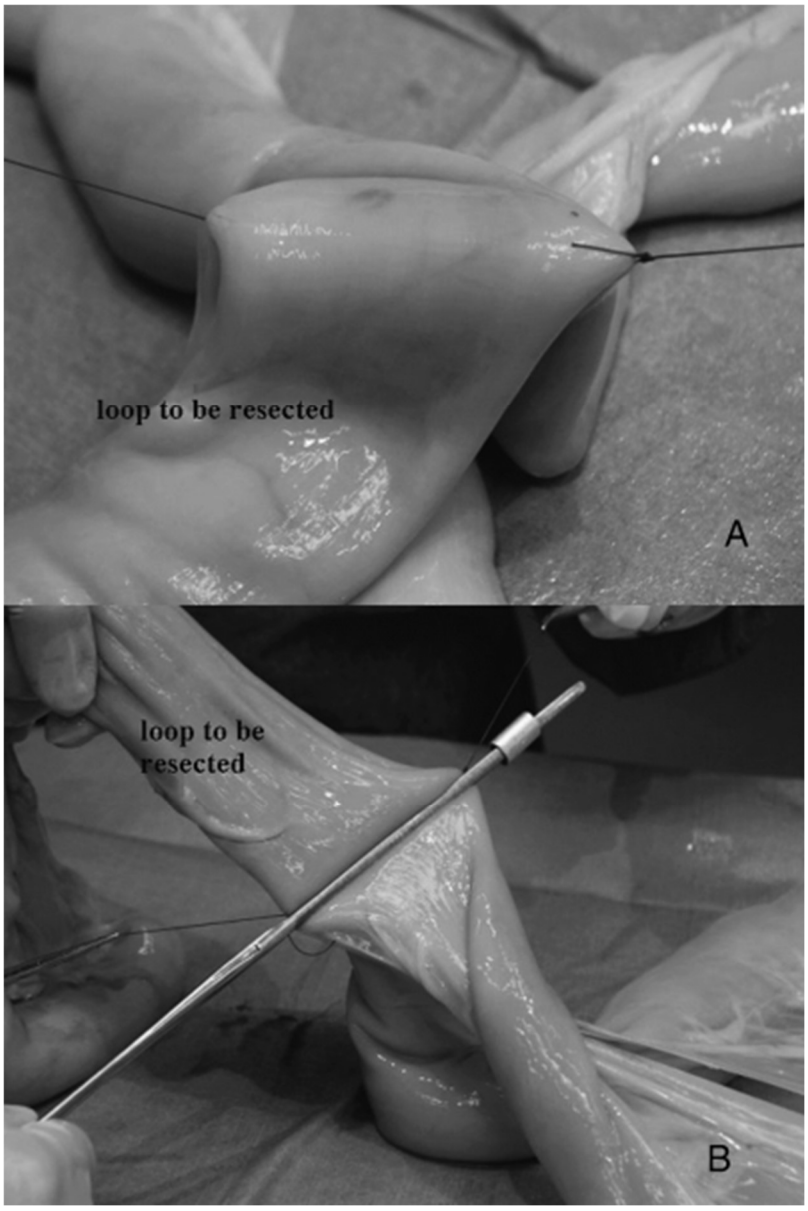

Figure 2

Open in figure viewerPowerPoint

(A)Applying tension on the stay sutures allows alignment of the 2 bowel segments to be anastomosed. (B) A modified Doyen clamp is placed adjacent the 2 stay sutures toward the portion of bowel to be anastomosed.

Then, the bowel clamp was rotated so that the opposite side of the segments was visible and both segments were draped over the clamp to expose the initial surfaces to be sutured (Fig 3A). A 2-0 polyglactin 910 continuous Cushing suture pattern was started at the mesenteric edge and advanced to the antimesenteric edge where it was tied (Fig 3B). Particular care was taken to place the bites as close to the jaws of the clamp and as deep within the space between the bowel segments (Fig 3B) as possible to minimize inversion. The suture ends were left long to serve as stay sutures. The bowel clamp was rotated so that bowel surfaces were repositioned to expose the unsutured side. A straight Hartmann crushing clamp was placed parallel and ~1 cm proximal to (i.e., toward the loop to be resected) the Doyen clamp. The intestine was transected with a scalpel as close as possible to the

Doyen clamp to remove the bowel loop and original 2 stay sutures. The security of the locking ring on the Doyen clamp jaws was rechecked and care was taken handling the Doyen clamp to minimize the likelihood of the transected ends slipping out of the clamp.

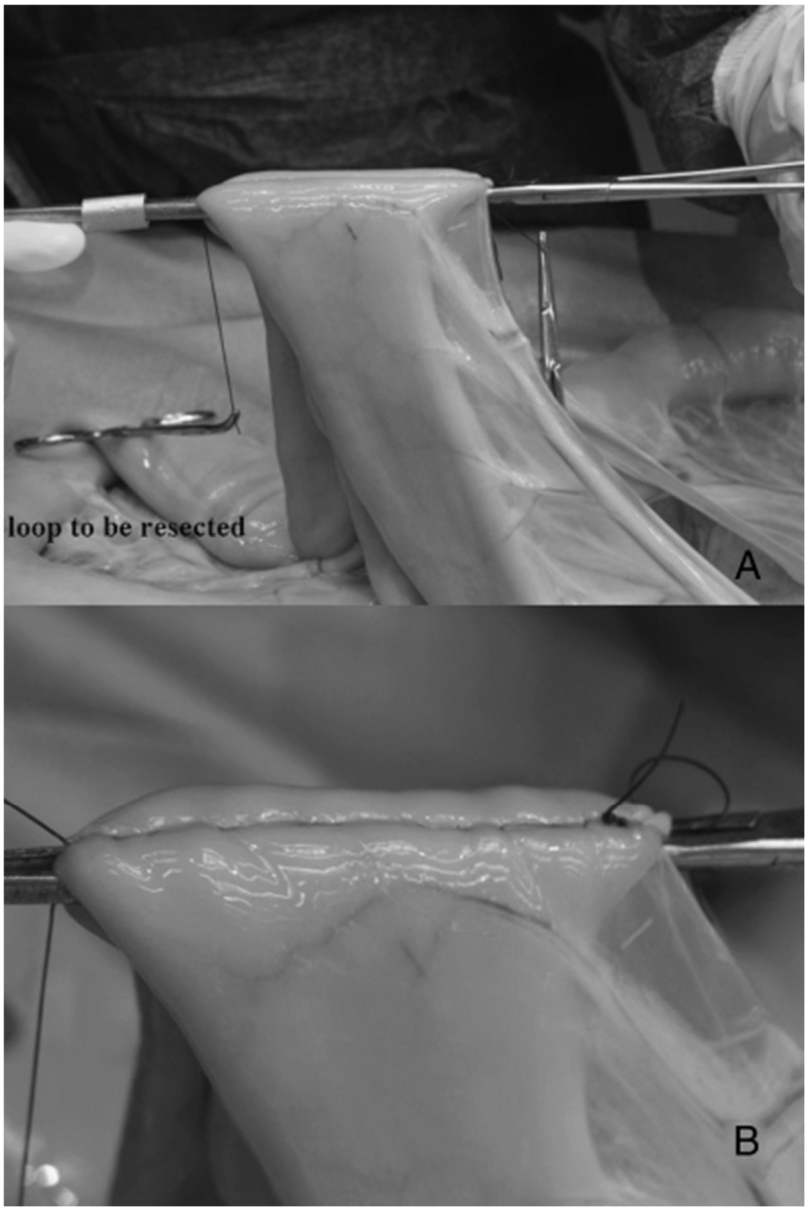

Figure 3

Open in figure viewerPowerPoint

(A) The bowel clamp is rotated to reveal the 2 adjacent bowel walls to be anastomosed. (B) The 2 intestinal walls are sutured together with a Cushing suture pattern.

A Parker–Kerr suture (2-0 polyglactin 910) was placed over the Doyen clamp (Fig 4A) starting with the initial bite as close as possible to the end of the previous suture and advancing toward the opposite side. Care was taken to penetrate to the level of the submucosa but avoiding deep bites that would engage the opposite bowel wall. The suture ends were grasped with hemostats and kept under traction as the Doyen clamp was removed to complete the oversew. These ends were then tied to the respective stay suture ends. This technique thus permitted complete anastomosis without exposure of the lumen of each segment and thus minimized the likelihood of contamination (4, 5).

If after clamp removal there was sufficient space between the suture ends that leakage might occur, additional single interrupted sutures were placed.

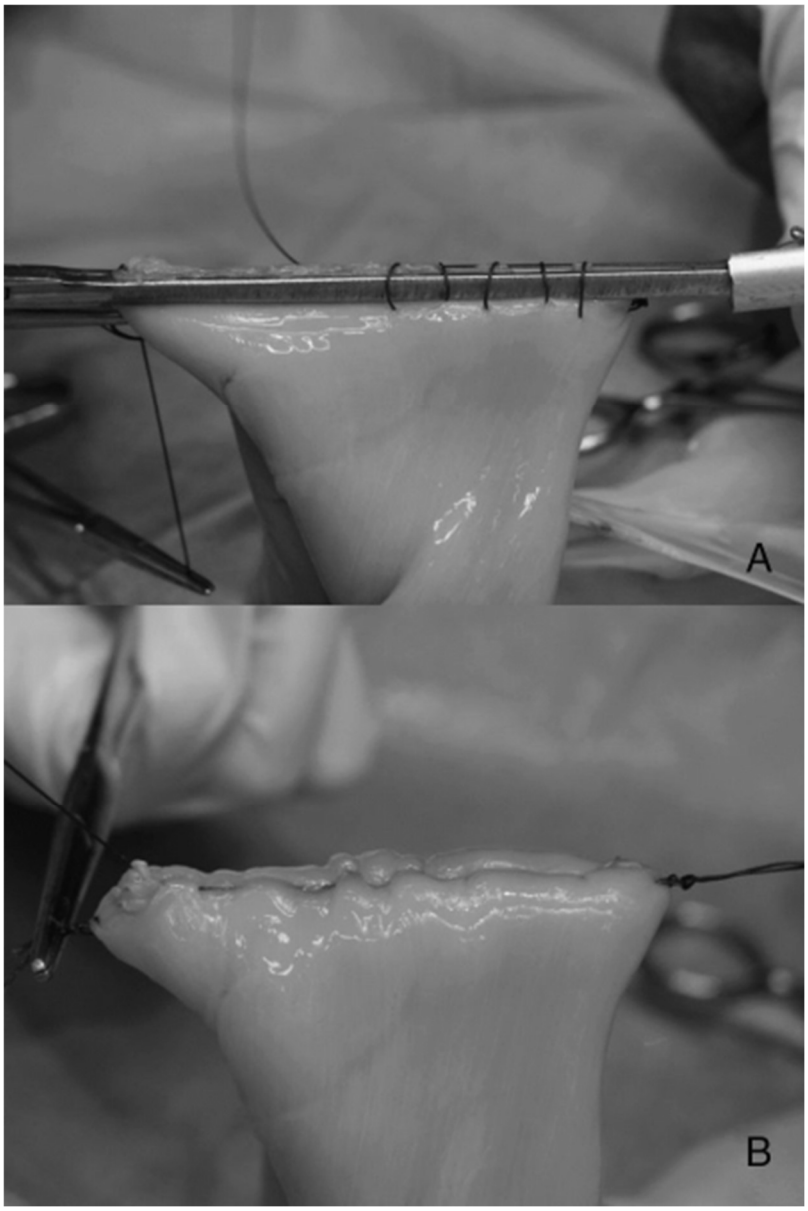

Figure 4

Open in figure viewerPowerPoint

(A) After reversing the bowel clamp and resecting the discard bowel loop, a second Cushing suture is started on the opposite side. (B) Second Cushing suture completed, just before tying on the free end of the first knot of the first suture on the opposite side.

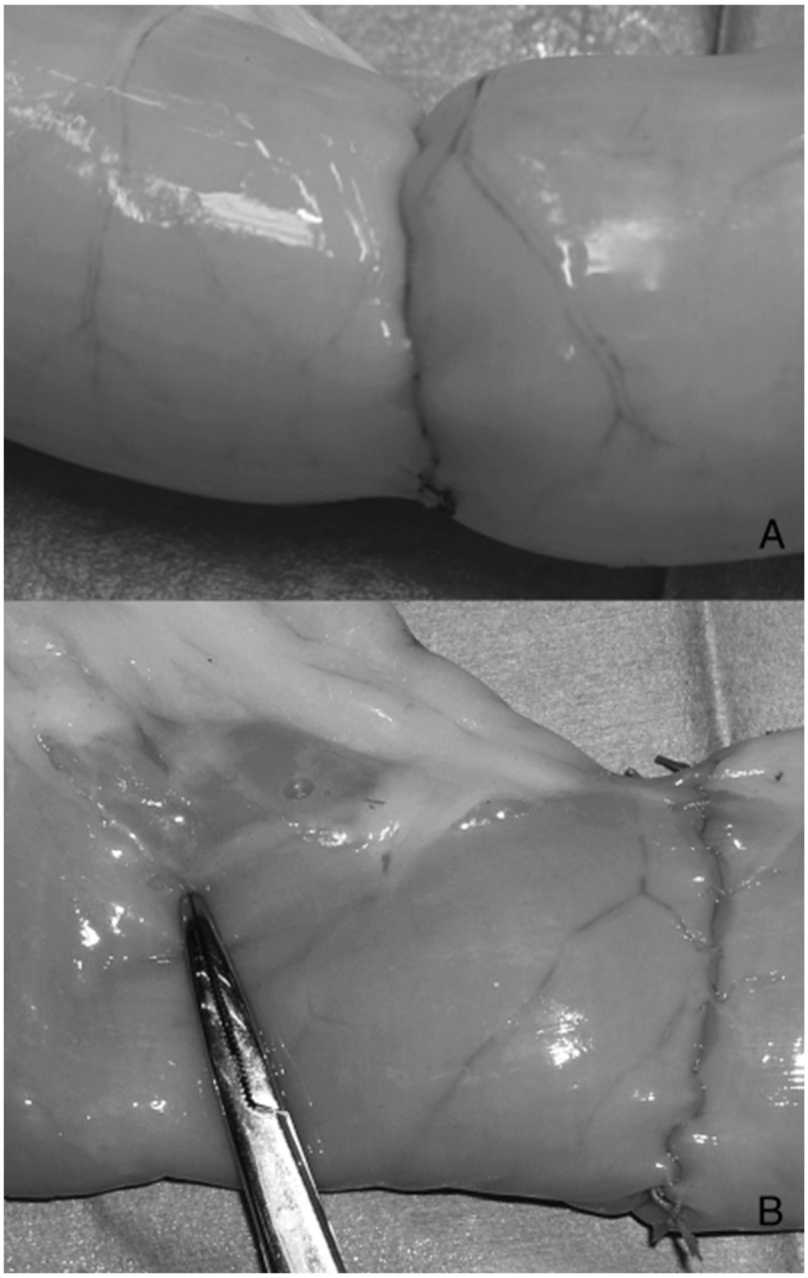

Figure 5

Open in figure viewerPowerPoint

(A) Completed anastomosis, slightly inflated. (B) Rupture of the bowel wall on the mesenteric side at a distant site from the anastomosis.

Hand-Sewn 2-Layer Anastomosis. After conventional preparation of the transected segment ends and placement of mesenteric and antimesenteric stay sutures anchored through both segments, a 2-0 polyglactin 910 simple continuous suture was used to oppose the mucosal–submucosal edges. Then a second layer continuous seromuscular Cushing pattern (2-0 polyglactin 910) was used to complete the anastomosis. Both suture lines were interrupted at the mesenteric and antimesenteric borders to avoid a purse-string effect and traction on the stay sutures by an assistant was maintained to optimize luminal size.

Construction Time

Time (minutes) of anastomosis construction was defined as time from first suture bite to suture completion. If additional sutures were placed to avoid leakage, this time was included in the total construction time. Mean (±SEM) time for each anastomosis was calculated. After anastomosis completion, each bowel segment was transected ~15 cm proximal and distal to the anastomosis and stored in lactated Ringer's solution at room temperature before testing. Mechanical testing was conducted on all specimens within 1 hour of completion of the anastomosis.

Lumen Diameter and Anastomotic Index

Before biomechanical testing, each jejunal segment was rinsed with 0.9% saline solution. Then the lumen was filled with a saline solution containing 10% of barium sulfate cream 113% (Prontobario esofago, Bracco s.p.a, Milano, Italy), for 1 minute after which the fluid was milked out of the specimen. The segment ends were closed with plastic self-locking bands and the lumen filled with air to an intraluminal pressure of 14 mm Hg. Specimens were radiographed with a digital system (Agfa Mimosa Vips 1206, Agfa-Gevaert N.V/S.A 96, Munich, Germany) and lumen diameter at the anastomotic site and at 2 sites each 5 cm distant from the anastomosis were measured on the radiographic images.

To account for interindividual horse variation, an anastomotic index was calculated with the formula: Index=2 × anastomotic lumen diameter (cm)/[distal lumen diameter (cm)+proximal lumen diameter (cm)]. This value is the ratio between the lumen diameter at the anastomotic site and the mean lumen diameter of proximal and distal sites.

Biomechanical Testing

Anastomoses were tested for leakage by immersion of air filled specimens in a water tank. Bursting strength was tested using a modified gas inflation tank test. A metal cannula connected to a compressed air tank was inserted into the lumen at one end of the specimen and a similar cannula inserted at the other end was connected to a calibrated mercury sphygmomanometer. The specimen was submerged in water, inflated with air at 1 L/min until gas leaked from the bowel. Luminal pressures were continuously measured and recorded by digital camera. Review of recordings allowed evaluation of the peak pressure at specimen failure, which was confirmed by observation of leaking gas bubbles coincident with a decline in luminal pressure.

Statistical Analysis

Construction time and anastomotic index of anastomosis types were compared using a paired Student's t-test. Bursting pressure values were compared between techniques by using a Wilcoxon matched pair test. All statistical analyses were performed with commercially available software (Graphpad InStat® version 3.05 for Windows 95/NT, GraphPad Software, San Diego CA) with significance set at $P \leq .05$. Results are reported as mean±SEM.

RESULTS

Both anastomosis types had similar external appearance and both techniques caused luminal narrowing of inflated specimens at 14 mm Hg intraluminal pressure (**Fig 5A**). One 2-layer and 3 closed technique anastomoses leaked just after completion. The 2-layer anastomosis leaked at the mesenteric edge, whereas all 3 closed technique specimens leaked where suture lines joined either at the antimesenteric (n=1) or mesenteric border (n=2). Use of additional single interrupted sutures (maximum, 2) prevented further leakage. Mean (±SEM) construction time for the closed technique (10.85±0.42 minutes) was significantly faster than for the 2-layer technique (17.12±0.49 minutes; $P<.0001$). Mean bursting pressure for 2-layer anastomoses (178.75±3.86 mm Hg) was significantly higher than for closed technique anastomoses (109.6±8.49 mm Hg; $P<.0001$), although some of the latter type resisted pressures >180 mm Hg until the bowel wall distant to the anastomosis ruptured (**Fig 4B**). Mean anastomotic index was not significantly different between techniques (2 layer, 72±1; closed technique, 70±1).

Most (n=10) closed technique anastomoses failed at the anastomotic site either at the mesenteric (3) or antimesenteric (2) edges or around the circumference (5). The anastomosis that leaked just after completion at the mesenteric site and 1 of 2 that leaked at the antimesenteric site subsequently burst at different sites around the circumference. The other 2 anastomosis resisted pressures that subsequently caused failure of the bowel wall at a distant site from the anastomosis (**Fig 5B**).

The 2-layer anastomoses generally resisted pressures until intact bowel wall distant from the anastomosis failed; 3 failed at the anastomotic site (1 mesenteric, 2 around the circumference).

DISCUSSION

We found that an end-to-end jejunojejunal anastomosis could be created using a closed technique more rapidly than a 2-layer hand-sewn anastomosis, with similar reduction in luminal size but lower bursting strength. However, the recorded bursting pressures for both anastomosis types were higher than intraluminal pressures recorded in horses with bowel distention. Failure occurred mostly at the anastomotic site, although 2 closed technique anastomoses resisted pressures until bowel wall at a distant site failed.

Preventing or minimizing contamination of the operative field with ingesta or sequestered intestinal fluid is a fundamental tenet of gastrointestinal surgery. Others have reported anastomotic techniques that reduce contamination during resection and anastomosis of the bowel,[5-7] although they are not commonly used in clinical practice. The technique we report was technically easy, and permits construction of an end-to-end jejunal anastomosis without having the intestinal lumen open during anastomosis. Recognizing that the dimensions of the intestinal clamp would influence the degree of inversion, we reduced the width of the jaws of a commercially available Doyen clamp to 3 mm. Whereas further reduction in jaw size might cause less inversion, the ability of the finer clamp jaws to securely hold the segments would likely become a limiting factor. Although there was no

difference in luminal dimensions between the 2 techniques, the reduction in lumen diameter was <30% which is comparable to other inverting techniques.[8, 7]

Selection of a Cushing pattern for the anastomosis was directed the need to perform a Parker–Kerr pattern over the clamp. Use of a Parker–Kerr pattern even over a narrow jawed clamp will cause greater inversion than suture bites placed at an exposed, free bowel edge. Although not tested in this study, we believe that the combined Cushing and Parker–Kerr technique we used resulted in more inversion that would occur with a classical Cushing pattern but likely similar to that occurring with a Lembert pattern, which is also considered acceptable.[3, 4] Mean bursting pressure for the closed technique although significantly less than that of the 2-layer technique was well above values reported for stapled side-to-side anastomosis,[9] suggesting that this technique may be as safe as other 1-layer techniques.[3, 4] One plausible reason that the closed technique resulted in lower bursting strength than a 2-layer technique could be that some suture threads may not have incorporated the submucosa. Initial leakage at completion of the anastomosis in 3 specimens reflects the need for technique improvement and attention to detail at the junction of the suture lines. Use of additional sutures at these sites prevented further initial leakage. Notwithstanding this technical detail, we believe that the completed anastomoses are sufficiently strong to withstand likely postoperative intraluminal pressures. Indeed, some (n=2) of the anastomoses failed at a site remote from the anastomosis at intraluminal pressures >180 mm Hg (**Fig 5B**).

We were unable to identify a sufficiently narrow-jawed pair of intestinal clamps so chose to modify a commercially available straight Doyen clamp. In preliminary work, we attempted to use Payr pyloric clamps but they are relatively wide (6 mm) in their smallest available size. Narrowing these clamps resulted in inadequate jaw closure to secure the thickness of the bowel ends, so we resorted to modification of the more robust Doyen clamps. The locking ring was made from an appropriately sized metal cylinder that was slightly flattened to ensure that it remained in a secure position when seated on the clamp. As noted earlier, attention to the secure position of this clamp during bowel manipulation and anastomosis is important to prevent inadvertent bowel release.

Clamping of the transected bowel ends between the jaws of this modified non-traumatic clamp should effectively reduce hemorrhage from the intestinal wall which has been reported as an intraoperative complication.[10] The force exerted by the locking ring and the relatively long time the 2 jaws are clamped on the tissue may contribute to tissue necrosis but it is unlikely that this would impair suture holding strength because the sutures are distant to this zone. After clamp removal, it is likely that the crushed tissue will necrose and slough contributing to a slightly larger luminal diameter. Inflammation after edge necrosis was seemingly not a problem with a similar technique described in humans.[11]

The closed anastomotic technique we report for end-to-end anastomosis of equine jejunum can be performed more rapidly that a conventionally used hand-sewn 2-layer anastomosis with seemingly similar in vitro characteristics. Although the method requires some instrument modification, this is

relatively easy to accomplish and sufficiently inexpensive to a potential alternative method for equine jejunal anastomosis. In vivo evaluation of the method should be undertaken before general clinical use.

References:

1 Coolman BR, Ehrart N, Marretta SM: Historical perspective of intestinal anastomosis in veterinary surgery. *Compend Contin Educ Pract Vet* **22**: 232– 237, 2000

2 Freeman DE: Surgery of the small intestine. *Vet Clin North Am Equine Practice* **13**: 280– 299, 1997

3 Freeman DE, Schaeffer DJ: A comparison of two single-layer patterns for jejunojejunostomy in horses with colic, in *Proceedings of the, 8th International Equine Colic Research Symposium*, Quebec City, Quebec, Canada, 2005; 134

4 Nieto JE, Snyder JR: Comparison of a single versus a double layer hand sewn end-to-end anastomosis in the jejunum of horses; in *Proceedings of the 8th International Equine Colic Research Symposium*, Quebec City, Quebec, Canada, 2005; 192–193

5 Sandh G: Modification of the cutting thread technique for intestinal anastomosis using diathermy. *J Vet Med A* **38**: 115– 125, 1991

6 Huskamp B: Diagnosis of gastroduodenojejunitis and its surgical treatment by a temporary duodenocaecostomy. *Equine Vet J* **17**: 314– 316, 1985

7 Baxter GM, Hunt RJ, Tyler DE, *et al*: Sutured end-to-end and stapled side-to-side jejunal anastomoses in the horse. *Vet Surg* **21**: 47– 55, 1992

8 Dean PW, Robertson JT, Jacobs RM: Comparison of suture materials and suture patterns for inverting intestinal anastomosis of the jejunum in the horse. *Am J Vet Res* **46**: 2072– 2077, 1985

9 Bickers RJ, Blackford JT, Eiler H, *et al*: A comparison of the mechanical strength of two stapled anastomosis techniques for equine small intestine. *Vet Surg* **31**: 104– 110, 2002

10 Doyle AJ, Freeman DE, Rapp H, *et al*: Life-threatening hemorrhage from enterotomies and anastomosis in 7 horses. *Vet Surg* **32**: 553– 558, 2003

11 Gorog D, Peter A, Szabo J, *et al*: Single-layer continuous suturing for end-to-end colonic anastomosis using a modified closed-bowel technique. *Surg Today* **34**: 642– 644, 2004