

# Histological Alterations in the Internal Organs of Wistar Han Rats (*Rattus norvegicus*) Euthanized by Five Different Methods

Cícero Júlio Silva Costa,<sup>1,2</sup> Danilo Wadt,<sup>1</sup> Luiza Cesar Conti,<sup>1</sup> Marina Frota de Albuquerque Landi,<sup>1</sup> Luciana Cintra,<sup>1,2</sup> Fernando Anselmo de Oliveira,<sup>2</sup> and Claudia Madalena Cabrera Mori<sup>1,\*</sup>

Selecting a method of euthanasia is an important step in designing research studies that use animals; euthanasia methods must be humane, cause minimal pain and suffering to the animal, and preserve the tissue architecture of the organs of interest. In this study, we evaluated the histomorphology of the internal organs (lung, spleen, heart, kidney, liver, brain, and adrenal gland) of rats submitted to five different methods of euthanasia, with the goal of determining which protocol caused the least alteration of histomorphology. Twenty adult Wistar Han rats (*Rattus norvegicus*) were divided into 5 groups of 4 rats each (2 females and 2 males) and were euthanized by CO<sub>2</sub> or isoflurane inhalation, sodium thiopental or xylazine plus ketamine overdose, or decapitation. All euthanasia was performed in accordance with published guidelines and local legal requirements. Necropsy was performed immediately after euthanasia. Specific internal organs were removed and placed in formalin and submitted for routine histologic processing. Histomorphological examination of hematoxylin and eosin-stained tissues revealed circulatory alterations in multiple organs, predominantly congestion in multiple tissues, pulmonary hemorrhage, and hepatic degeneration. The euthanasia methods that induced the most severe alterations were exposure to CO<sub>2</sub> and anesthetic overdose with xylazine plus ketamine or sodium thiopental. Euthanasia by overexposure to isoflurane caused less damage, and the alterations were of minimal severity. Decapitation resulted in the lowest incidence of lesions in multiple organs but due its traumatic nature, it caused the highest incidence of pulmonary hemorrhage. In selecting a method of euthanasia, factors to consider are the species of animal, the purpose of the research, and the practical ability to perform the procedure to achieve maximal animal welfare without iatrogenic changes that could compromise the outcome and reproducibility of the study.

**Abbreviations and Acronyms:** H and E, hematoxylin and eosin; FMVZ-USP, School of Veterinary Medicine and Animal Science, University of São Paulo; CONCEA, National Council for the Control of Animal Experimentation; KX, ketamine plus xylazine

DOI: [10.30802/AALAS-JAALAS-23-000007](https://doi.org/10.30802/AALAS-JAALAS-23-000007)

## Introduction

Rats and mice are the mammals most commonly used in biomedical research,<sup>2,26</sup> with approximately 120 million rodents used annually for scientific purposes worldwide.<sup>6,8</sup> Despite the technological development of experimental models designed to reduce the number of animals used in research,<sup>3</sup> animals are still needed to investigate how living organisms respond to diseases and to elucidate aspects of pharmacokinetics and pharmacodynamics of new drugs and genetic manipulations.<sup>20</sup> The facile maintenance and handling of rats and mice, along with their short lifespan and certain similarities with humans, are all factors that support their use for studying diseases in the long term and in different generations.<sup>2,26</sup> In this context, the anatomic, physiologic, and genetic characteristics of these rodent species justify their use in scientific studies, and data collection from animals can revolutionize therapeutic and diagnostic approaches and promote the development of future translational research.<sup>2,26</sup>

Most experimental studies involving animals require the collection of tissue from internal organs for subsequent

morphologic and biomolecular analysis<sup>4,15</sup>; in such cases, the animals must undergo a form of euthanasia that guarantees total loss of consciousness without pain or suffering. Moreover, for experiments that involve the interpretation of histopathologic findings, the effects of a particular euthanasia method on cellular architecture must be considered.<sup>16</sup> To ensure accurate analysis and avoid misleading interpretations that could affect research outcomes, high-quality tissue samples that preserve the histologic architecture and minimize iatrogenic alterations induced by the euthanasia procedure are essential.<sup>4,17</sup> Various methods of physical or chemical euthanasia are generally acceptable; the choice depends primarily on the purpose of the study, the species of animal, the target organ, and the ability of the investigator to perform the technique.<sup>19</sup>

Some studies require that the extracted tissues remain free of any chemical influence due to the use of drugs; this requirement would exclude the use of barbiturates and anesthetics in the euthanasia procedure.<sup>9</sup> In other investigations, however, the application of an overdose of anesthetic in the performance of euthanasia is acceptable; this option benefits to the researcher due to the ease of application of the drug.<sup>18</sup> While numerous studies delve into the possible postmortem effects of various acceptable and applicable euthanasia methods, little detailed information is available concerning the histomorphological changes that occur in vital organs of rodents after different

Submitted: 23 Jan 2023. Revision requested: 23 Feb 2023. Accepted: 19 Sep 2023.

<sup>1</sup>Department of Pathology, School of Veterinary Medicine and Animal Science, University of São Paulo, São Paulo, Brazil; and <sup>2</sup>Hospital Israelita Albert Einstein, São Paulo, Brazil

\*Corresponding author. Email: [claudiam@usp.br](mailto:claudiam@usp.br)

methods of physical and chemical euthanasia. Such information would be useful for selecting the euthanasia method that would minimize artifacts and iatrogenic alterations that might alter data interpretation.<sup>4</sup> In order to assist researchers in their choice of a legal euthanasia procedure that would do minimal harm to the microscopic architecture of biologic tissues, we investigated the histomorphological injuries to the internal organs of male and female Wistar Han rats (*Rattus norvegicus*) after euthanasia induced by 5 different procedures, namely inhalation of CO<sub>2</sub> or isoflurane, overdose with a barbiturate (sodium thiopental) or with the combination of xylazine and ketamine (KX), and decapitation.

## Materials and Methods

**Animals.** This study was approved by the Ethics Committee on the Use of Animals of the School of Veterinary Medicine and Animal Science, University of São Paulo (FMVZ-USP), Brazil, under protocol numbers 1362120819 and 3317270521. Rats received humane care according to the criteria outlined in the *Guide for the Care and Use of Laboratory Animals* issued by the National Research Council.<sup>27</sup> Ten female and 10 male adult Wistar Han rats between the ages of 11 and 13 wk were used in this study. The primary aim of this study was to provide a detailed description of histopathological findings associated with various euthanasia methods. Adhering to the principles of the 3Rs, we made the choice to refrain from euthanizing a larger number of rats in order to perform statistical analyses, although we acknowledge the importance of such data in supporting our findings. Instead, we prioritized producing a comprehensive description of the histopathological findings associated with different euthanasia methods by using a low but reasonable number of rats. This approach allowed us to provide detailed descriptive data on tissue artifacts resulting from euthanasia, which is of paramount importance for experimental studies.

Rats were obtained from the animal breeding facility of the Institute of Biomedical Sciences, University of São Paulo, Brazil, and were maintained in the animal facility of FMVZ-USP for at least one month before euthanasia. The health status of the rats was monitored in accordance with FELASA guidelines<sup>23</sup>; rats were free of the following pathogens: Kilham rat virus, murine pneumonia virus, reovirus, and the ectoparasites and endoparasites *Mycoplasma pulmonis*, *Pasteurella pneumotropica*, *Bordetella bronchiseptica*, *Helicobacter* spp., *Klebsiella oxytoca*, *Klebsiella pneumoniae*, *Pasteurella Ratsmultocida*, *Pseudomonas aeruginosa*, *Staphylococcus aureus*, *Streptococcus β-hemolytic* spp., *Streptococcus pneumoniae*, and *Salmonella* spp.

Rats were maintained in the animal facility of the Department of Pathology, FMVZ-USP, Brazil, in open-top polypropylene cages (41 × 34 × 16 cm; 2 or 3 rats per cage) containing autoclaved wood shavings as bedding (Granja RG, Suzano, São Paulo, Brazil) and paper towels for nesting material. The environmental conditions at the animal facility were 22 ± 2 °C; 55 ± 10% relative humidity; 12-h photoperiod; and continuous air exhaustion throughout the experimental period. Irradiated pelleted feed (Nuvilab CR1, Quimtia, Colombo, Paraná, Brazil) and filtered/autoclaved drinking water were provided ad libitum. Cages were cleaned and the body weights of the rats were recorded once a week.

**Methods of euthanasia.** The euthanasia methods used in this study were those outlined in the Euthanasia Practice Guidelines issued in Brazil by the National Council for the Control of Animal Experimentation (CONCEA; normative resolution #37),<sup>13</sup> which are based on the AVMA Guidelines for the

Euthanasia of Animals<sup>1</sup> and other international guidelines and recommendations.<sup>7,10,11</sup> Five different protocols were selected and performed by a team of veterinarians trained to carry out these types of euthanasia. The methods used were inhalation of CO<sub>2</sub> or an anesthetic agent (isoflurane), injection of anesthetics (barbiturate or injectable dissociative agent plus α2-adrenergic receptor agonist), and the physical method of decapitation. Each form of euthanasia was performed on a group of 4 rats (2 females and 2 males). Rats were euthanized individually, and necropsy was performed promptly to reduce tissue artifacts that develop due to the cascade of biotic and abiotic alterations that occur in the cadaver immediately after death.

**Carbon dioxide inhalation.** Euthanasia by inhalation of CO<sub>2</sub> was performed in the animal facility of the Pathology Department, FMVZ-USP, Brazil, using a chamber for small rodents (RED Indústria e Comércio, Caieiras, São Paulo, Brazil). The rat was placed in the euthanasia chamber, which was filled at a flow rate of 20% of the total chamber volume/min until the chamber reached 100%. This euthanasia cycle required 7 min, including continuing the flow of CO<sub>2</sub> into the chamber for a minimum of 1 min after the rat showed respiratory arrest. Gas was exchanged between consecutive euthanasia procedures.

**Isoflurane inhalation.** In accordance with euthanasia guidelines issued by CONCEA, rats were transferred to a hermetic chamber measuring 16 × 16 × 18 cm before receiving anesthetic isoflurane (Isoforine, CRISTÁLIA - Produtos Químicos Farmacêuticos, Itapira, SP, Brazil). To prevent direct contact of the rat with the anesthetic, a cotton wool ball soaked with isoflurane was placed inside a 15-mL conical tube that was subsequently placed in the chamber. Rats were kept in the chamber for a minimum of 2 min after they stopped breathing to ensure cardiac arrest.

**Xylazine plus ketamine (KX).** A 300-mg/kg dose of a sterile solution containing 100 mg/mL of ketamine (Dopalen, Ceva Saúde Animal, Paulínia, São Paulo, Brazil) and a 30-mg/kg dose of a solution containing 20 mg/mL of xylazine (Anasedan, Ceva Saúde Animal, Paulínia, São Paulo, Brazil) were injected into the peritoneal cavity in the lower right quadrant of the abdominal region as recommended in the literature.<sup>14,33</sup>

**Sodium thiopental.** A 150-mg/kg dose of a solution containing 20 mg/mL of sodium thiopental (Thiopentax, CRISTÁLIA - Produtos Químicos Farmacêuticos, Itapira, SP, Brazil) was administered intravenously through the lateral tail vein. To facilitate administration, rats were restrained manually in sternal recumbency with a surgical pad, and their tails were exposed to a heat lamp to promote vasodilation of the lateral vein.

**Decapitation.** According to CONCEA guidelines, when pharmacological exposure does not interfere with the research results, administering a sedative before decapitation guarantees better restraint of the animal and avoids execution errors and operational accidents. In the present study, a 1-mg/kg dose of a solution containing 5 mg/mL of diazepam (Compaz, CRISTÁLIA - Produtos Químicos Farmacêuticos, Itapira, SP, Brazil) was administered subcutaneously 10 min before decapitation. The decapitation procedure was performed using a guillotine designed for small rodents (Bonther Produtos e Equipamentos para Laboratorio, Riberão Preto, São Paulo, Brazil).

**Sampling and microscopic evaluation.** Prior to necropsy, rats were checked carefully to ensure that death had occurred. Representative tissue samples of the lung, spleen, heart, kidney, liver, brain, and adrenal gland were promptly collected and submitted for fixation in 10% buffered formalin (pH, 7.0) for 24 h or until fixation was complete. Tissues of interest were then soaked in absolute alcohol and subjected to the histologic



processes of dehydration, diaphanization, paraffin embedding, sectioning, and staining with hematoxylin and eosin (H and E) for subsequent micromorphological evaluation. During H and E staining, slides were immersed in an alcoholic ammonium hydroxide solution to reduce artifacts caused by formalin pigments that could impair the quality of the material for microscopic evaluation.

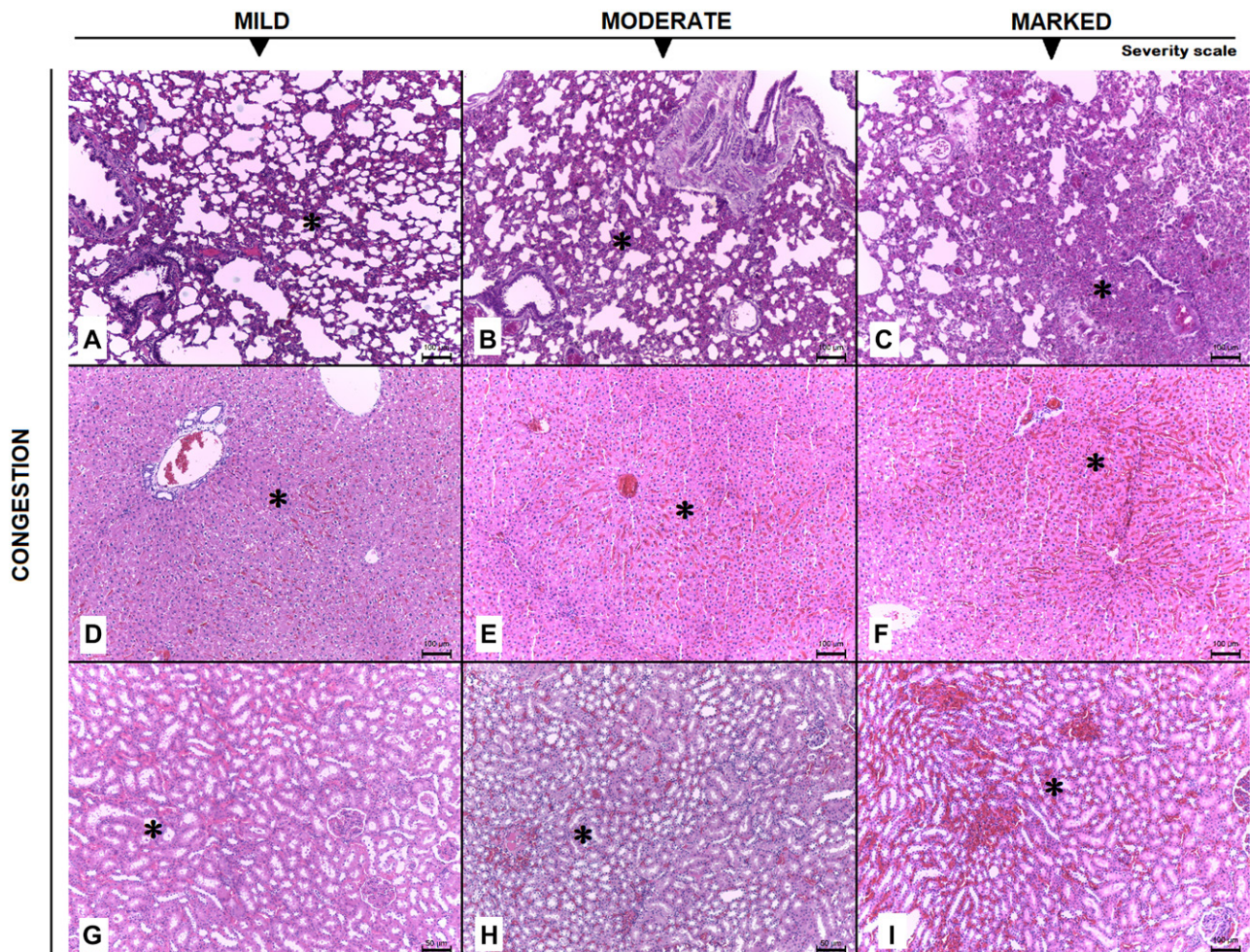
Histologic lesions were evaluated by a veterinary pathologist who had at least 2 y of training in a veterinary anatomic pathology residency program recognized by the Brazilian Ministry of Education. This pathologist responsible for the analysis was blind with respect to the type of euthanasia that the rat had experienced. Lesions were classified using a scale according to the intensity of alteration<sup>29</sup> as follows: 0 = absence of lesions, 1 = minimal, 2 = mild, 3 = moderate, 4 = marked, and 5 = severe.

## Results

To assure that the euthanasia procedure caused total loss of consciousness and termination of vital signs, the chemical-based methods required a minimum exposure time of 7 min for CO<sub>2</sub> inhalation, 4 to 10 min for isoflurane inhalation, 30 min for KX overdose, and less than 1 min for sodium thiopental overdose. Performing euthanasia by decapitation caused immediate loss of consciousness.

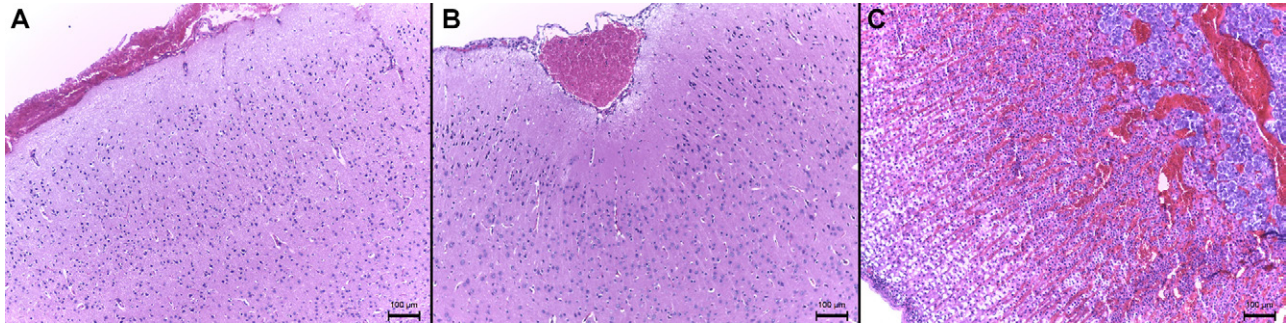
All methods preserved the macroscopic appearance of the internal organs after euthanasia, with no visible gross changes detected. Histomorphological analyses of the tissues revealed the circulatory lesions in most organs, regardless of sex. Thus, no alterations were observed in heart or spleen of any of the rats, and the characteristics of these organs were well within the physiologic limits. However, tissue from the pulmonary, renal, hepatic, and nervous systems had different morphological alterations after euthanasia. These alterations ranged from mild to marked in intensity and were characterized in lung by areas of alveolar congestion (multifocal or diffuse) (Figure 1A to 1C), in liver by congestion in the sinusoid capillaries, with distribution mainly in the periportal and centrilobular areas (Figure 1D to 1F), and in kidney by congestion (multifocal to coalescent) of the corticomedullary areas (Figure 1G to 1I). Nerve tissue showed vascular congestion, mainly in the subarachnoid space (Figure 2A and 2B). Congestion in the zona fasciculata, reticulata, and medulla was observed in the adrenal glands (Figure 2C).

Among the organs evaluated, inhalation of CO<sub>2</sub> was associated with the most frequent occurrence of lesions (Table 1). CO<sub>2</sub> inhalation was associated moderate histopathologic changes in most tissues (Figure 3) and produced the only cases in which hepatic degeneration was observed (Figure 4A and 4B). In contrast to the rats exposed to CO<sub>2</sub>, rats euthanized with a KX overdose



**Figure 1.** Photomicrographs of H and E-stained tissues showing congestion in the internal organs of euthanized Wistar Han rats, distributed according to grade of severity. (A–C) Congestion of alveolar capillaries (\*) in lung tissue; (D–F) sinusoid capillary congestion in periportal and centrilobular areas (\*) of liver tissue; and (G–I) multifocal corticomedullary congestion (\*) in kidney tissue. Scale bars, 100 μm (A–F, I) and 50 μm (G, H).





**Figure 2.** Photomicrographs of H and E-stained tissues of euthanized Wistar Han rats showing (A, B) mild subarachnoidal vascular congestion (\*) in nervous tissue and (C) marked congestion (\*) of the zona fasciculata, reticulata, and medulla of adrenal gland. Scale bars, 100  $\mu$ m.

had predominantly mild lesions, even though this method resulting in lesions in multiple organs (Figure 3). Intravenous administration of sodium thiopental caused minimal lesions in the majority of examined organs. However, this method was associated with a high degree of pulmonary congestion (Figure 3). Rats euthanized with isoflurane had minimal morphologic lesions, limited to lung, kidney, and adrenal gland (Table 1; Figure 3). Euthanasia by decapitation was associated with minimal occurrence of lesions in most of the examined organs (Table 1), and any detected alterations were of low intensity (Figure 3). However, rats euthanized by decapitation often displayed pulmonary hemorrhage that varied in intensity from minimal to severe (Figure 5). Low-grade pulmonary hemorrhage was also seen in rats euthanized by exposure to CO<sub>2</sub> or by administration of KX but not in rats that underwent euthanasia by isoflurane or thiopental.

## Discussion

This study has provided a comprehensive description of examination of tissue changes in Wistar Han rats that had been euthanized by one of 5 methods. Histologic analysis of the internal organs of these rats showed pathology that was characterized predominantly by areas of congestion in multiple

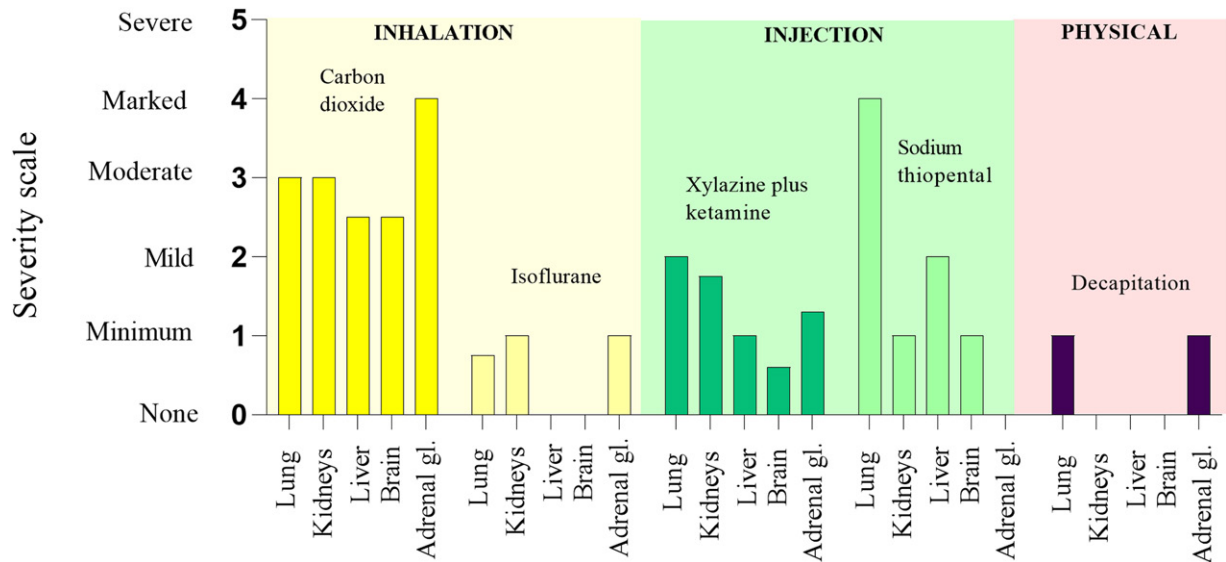
organs, pulmonary hemorrhage, and hepatic degeneration, with lesion severity ranging from mild to severe depending on the euthanasia technique. Furthermore, our observations are supported by photomicrographs that enhance the scientific community's understanding of these findings.

Euthanasia by CO<sub>2</sub> inhalation is commonly used after experimental or in breeding programs because it allows the euthanasia of a large number of animals at the same time.<sup>9</sup> However, in the present study, the method was notable for its high occurrence of relatively high-grade tissue alterations, mainly in the form of hemorrhage and alveolar congestion in the lungs and systemic congestion in other internal organs, including the kidneys, liver, brain, and adrenal glands. In our study, using CO<sub>2</sub> inhalation as the euthanasia method resulted in lung lesions similar to those reported previously,<sup>5</sup> however, that investigation did not report congestion in the brain or adrenal gland, unlike the present study. Another study reported histologic damage in the lungs of CO<sub>2</sub>-euthanized mice, typically characterized by mild to moderate perivascular and peribronchial edema.<sup>4</sup> In another study, hyperventilation caused by exposure to high or low concentrations of CO<sub>2</sub> affected the respiratory, circulatory, and nervous systems.<sup>31</sup> In addition, animals subjected to high levels of CO<sub>2</sub> can develop bradycardia, hypertension, and increased activity of the hypothalamic-pituitary-adrenal axis.<sup>31</sup>

**Table 1.** Frequency of the main histologic alterations in the internal organs of Wistar Han rats euthanized by 5 different methods

Euthanasia Method	Histologic Alteration	Number of Rats with Lesions in these Organs					Total Number of Lesions in the 4 Rats	Overall Total Number of Lesions
		Lung	Kidney	Liver	Brain	Adrenal Gland		
CO <sub>2</sub> chamber	Congestion	4	4	4	4	2	18	22
	Hemorrhage	2	0	0	0	0	2	
	Degeneration	0	0	2	0	0	2	
Isoflurane	Congestion	2	4	0	0	1	7	7
	Hemorrhage	0	0	0	0	0	0	
	Degeneration	0	0	0	0	0	0	
Xylazine plus ketamine	Congestion	4	3	1	2	2	12	14
	Hemorrhage	2	0	0	0	0	2	
	Degeneration	0	0	0	0	0	0	
Sodium thiopental	Congestion	2	2	2	2	0	8	8
	Hemorrhage	0	0	0	0	0	0	
	Degeneration	0	0	0	0	0	0	
Decapitation	Congestion	1	0	0	0	1	2	5
	Hemorrhage	3	0	0	0	0	3	
	Degeneration	0	0	0	0	0	0	

Data expressed as the number of rats ( $n = 4$ ) that were euthanized by each method. Heart and spleen tissue were evaluated but are not included in the table because no histologic alterations were detected in those organs after euthanasia by any of the methods investigated.



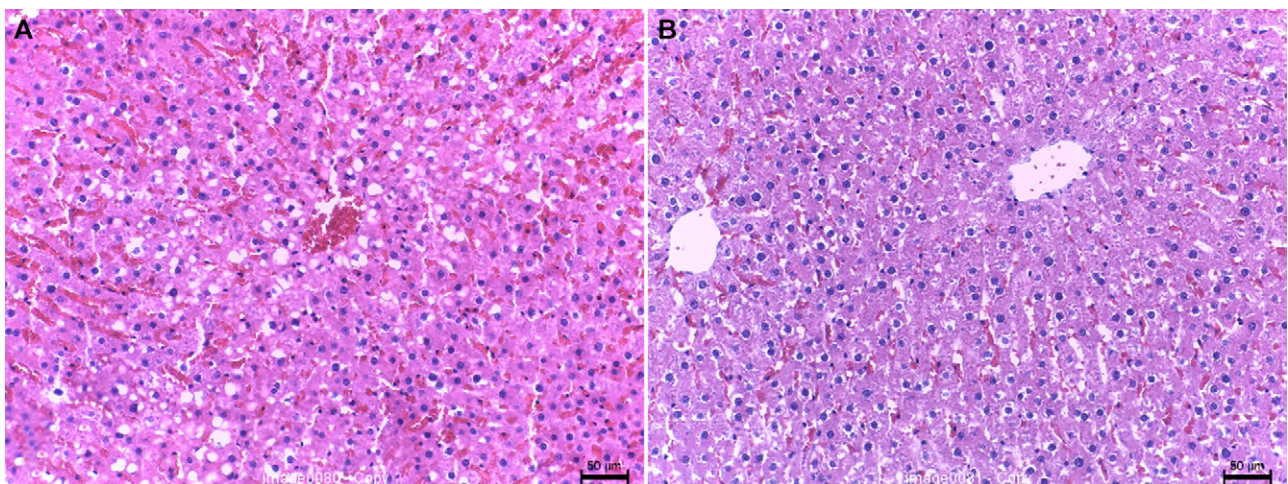
**Figure 3.** Graphical representation of the severity of histologic changes induced in lung, kidney, liver, brain, and adrenal gland tissues of Wistar Han rats by the 5 methods of euthanasia investigated.

Such conditions generate the sensations of pain, fear, anxiety, and respiratory distress, all of which affect animal welfare in relation to this method of euthanasia.<sup>9,12</sup> As is the case for all inhaled substances, the time required to achieve unconsciousness through CO<sub>2</sub> inhalation depends on the displacement rate, the container volume, and the concentration of the agent. In rats, exposure to 80 to 100% CO<sub>2</sub> induces unconsciousness within approximately 12 to 33 s, whereas exposure to 70% CO<sub>2</sub> typically requires around 40 to 50 s to produce the same effect.<sup>1</sup> To minimize the possibility of pain resulting from the activation of nociceptors by carbonic acid before unconsciousness, rodents should be exposed to CO<sub>2</sub> using a gradual-fill method with a displacement rate of 20 to 70% of the chamber volume per minute.<sup>1</sup>

In experimental situations, the choice of CO<sub>2</sub> inhalation as a method of euthanasia is acceptable with restrictions, and researchers must be aware of the possibility of pulmonary and circulatory alterations that could influence data in studies that have these systems as the main pathways of interest.<sup>30</sup> For example, an analysis of the central nervous system has revealed that, in comparison with methods of euthanasia

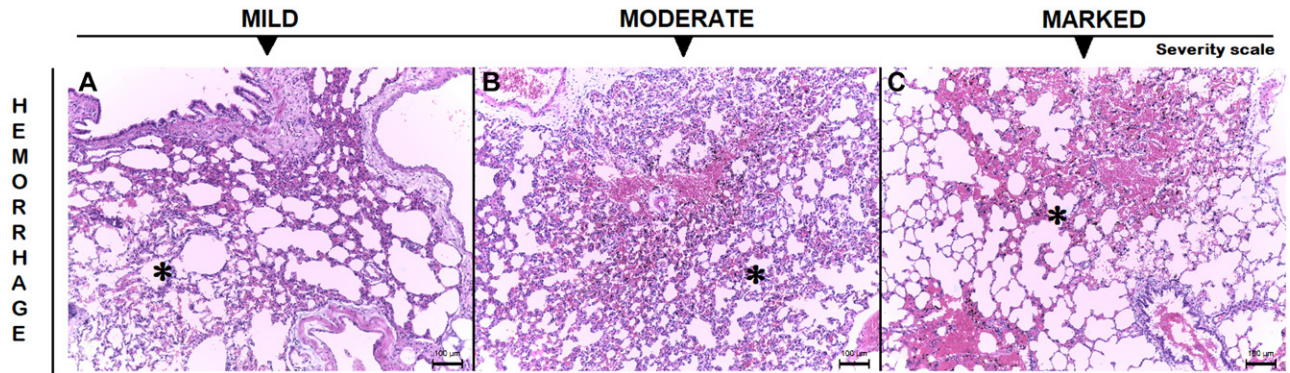
involving isoflurane or KX, rats euthanized by CO<sub>2</sub> inhalation had less phosphorylation of a protein belonging to the family of mitogen-activated protein kinases responsible for the proliferation, differentiation, and apoptosis of neurons.<sup>21</sup> This discovery underscores the benefits of using CO<sub>2</sub> euthanasia, which is less detrimental to neural tissue analysis and mitigates challenges in distinguishing pharmacological alterations (induced by chemical euthanasia) from pathogenic changes in mitogen-activated protein kinase activity.<sup>21</sup>

The administration of an overdose of the anesthetic isoflurane may be a more humane method of euthanasia than CO<sub>2</sub> in rats if the animals have not been previously exposed to the anesthetic. Previous reports have indicated that rats, especially females, with a prior history of isoflurane exposure exhibit a heightened aversion to euthanasia by isoflurane.<sup>35</sup> Although male Wistar Han rats reportedly show some aversion to isoflurane, the anesthetic is less aversive than CO<sub>2</sub>.<sup>1</sup> However, to avoid hypoxia, an adequate supply of air or oxygen is essential during the induction period. Thus, in our study, rats were placed in a large container with sufficient oxygen. Our results show that euthanasia by isoflurane is associated with a lower occurrence



**Figure 4.** Photomicrographs of H and E-stained liver tissues of euthanized Wistar Han rats showing (A) multiple well-defined and intracytoplasmic microvacuoles in centrilobular hepatocytes, suggestive of lipid degeneration and (B) multiple poorly defined microvacuoles, with indistinct limits and intracytoplasmic in centrilobular hepatocytes, suggestive of hydropic degeneration. Scale bars, 50 μm.





**Figure 5.** Photomicrographs of H and E-stained lung tissues of euthanized Wistar Han rats showing (A–C) alveolar space filled with red blood cells (\*) at mild, moderate, and marked intensity, respectively. Scale bars, 100 µm.

of lesions in internal organs and with minimal severity as compared with those found in rats that were euthanized by CO<sub>2</sub> inhalation. This finding indicates that euthanasia by isoflurane inhalation is a less damaging alternative than CO<sub>2</sub> and affords a higher capacity for tissue preservation. An earlier study<sup>24</sup> demonstrated that mice euthanized by exposure to CO<sub>2</sub> had higher levels of plasma adrenaline and noradrenaline than did mice euthanized by using isoflurane. In this context, our study found that euthanasia by CO<sub>2</sub> induced the highest intensity of alterations in the adrenal glands. On this basis, euthanasia by isoflurane can be advantageous for research that requires minimal tissue alteration and hormonal imbalance, especially in male rats that had not been previously exposed to this anesthetic.

Although intraperitoneal injection of a KX overdose is sometimes used for rodent euthanasia, iatrogenic injuries of a traumatic nature to the internal organs of the abdominal cavity can occur.<sup>28</sup> For example, a previous study<sup>14</sup> found that 8 of a group of 127 rats that had received intraperitoneal injections had lesions in the abdominal cavity, most frequently in the cecum. This organ, which is the largest in the cavity, is usually dilated due to the presence of gas and fecal material. Accidental puncture of this organ may release its contents into the abdomen, possibly generating local inflammation or even peritonitis. In the present study, a single trained operator performed all intraperitoneal injections in the lower right quadrant of the abdomen, as recommended.<sup>14,33</sup> With this protocol, no operational errors occurred, and no macroscopic injuries to the abdominal viscera were observed in any of the rats.

Microscopic evaluation of rats euthanized by intraperitoneal administration of KX revealed a low occurrence of low-grade lung lesions, thereby indicating better tissue preservation with this method. Moreover, other organs, such as the liver, brain, and kidneys, showed low occurrences of circulatory alterations. However, this method of euthanasia was the most time-consuming, with more than 30 min required for respiratory arrest. A previous publication tried to document the adequacy of KX for euthanasia by investigating how different administration protocols affected pulmonary pharmacokinetics.<sup>30</sup> That study showed that administration of KX via retro-orbital or intravenous caused death more rapidly than did the intraperitoneal injection; retro-orbital application was particularly promising because it was fast, reproducible, and had a low risk of execution errors and operational accidents. The study concluded that the retro-orbital administration would be an appropriate choice in studies that cannot use intraperitoneal administration in order to ensure protection to the abdominal organs.<sup>30</sup>

As with other barbiturates, thiopental induces central nervous system depression with minimal discomfort, particularly

after rapid administration. After the onset of unconsciousness, apnea and asystole typically ensue due to hypoxia resulting from the suppression of the cerebral cortical, respiratory, and vasomotor functions.<sup>22</sup> Administration of sodium pentobarbital by intraperitoneal injection is reported to damage local tissue, causing histologic alterations in organs distant from the site of administration, including focal congestion of the intestinal serosa, pulmonary vein congestion, subcapsular necrosis in the liver and pancreas, lung emphysema and edema, and renal hyperemia.<sup>22</sup> Moreover, the drug is highly alkaline, with pH levels ranging from 10 to 11, and intraperitoneal administration can irritate the peritoneum and surfaces of visceral organs, potentially causing discomfort and pain.<sup>22</sup> Considering the disadvantages associated with intraperitoneal administration of barbiturates, we administered thiopental intravenously via the lateral tail vein in our study. However, if the drug is administered extravascularly, it may lead to pain and necrosis, mandating that intravenous administration be performed only by fully qualified personnel.<sup>13</sup> In contrast to our study, a previous study examined the histologic and molecular impacts of euthanasia performed by using various doses of intraperitoneal sodium pentobarbital at varying doses and followed by exsanguination.<sup>25</sup> That study primarily identified vascular congestion and tissue degeneration in the liver and kidney, with the severity of these effects correlating with the administered dosage.<sup>25</sup> In our study, sodium thiopental caused a notably higher degree of pulmonary congestion, and similar to the other study, hepatic and renal congestion were also observed despite our use of the intravenous route to minimize local effects on abdominal organs.

Decapitation is the most invasive of the euthanasia protocols investigated in this study and requires preparation to ensure adequate performance and desensitization of the animal.<sup>34</sup> In our study, a low dose of diazepam was administered prior to euthanasia to promote mild sedation and to facilitate animal restraint, thereby reducing procedural failures and eliminating unnecessary suffering or stress. Based on the comparisons of various euthanasia methods reported in this study, the administration of diazepam before decapitation did not appear to induce histopathologic changes. However, our study did not investigate the potential for diazepam to have a protective effect, which might result in fewer histologic alterations. In particular, the rats euthanized by this method had relatively few histologic alterations in most of the internal organs analyzed, with the exception of pulmonary hemorrhage. Decapitation can be useful as an alternative method of euthanasia, especially in areas of research that require the least possible influence of chemical agents administered by intravenous, intraperitoneal, or inhalational routes. However, traumatic injury during the decapitation

process can be contraindicated for studies that target tissues adjacent to the decapitation site, such as the upper respiratory tract, because of potential hemorrhage.<sup>30</sup> Although some researchers opt for euthanasia methods such as decapitation or cervical dislocation that do not involve anesthesia, these methods also induce cardiac arrest, resulting in biochemical and physiologic changes.<sup>32</sup>

In agreement with the literature,<sup>16</sup> the present study showed that lungs were affected to some extent by all of the euthanasia methods we studied, with alterations ranging from mild congestion of alveolar capillaries to significant intramural edema of pulmonary arteries. In addition, lesions resulting from specific euthanasia methods were consistent in male and female rats.

In conclusion, careful consideration and meticulous planning are necessary when selecting an appropriate euthanasia method for rodents to ensure compatibility with the experimental goals. Although the selection of the euthanasia method should be based on the tissue of interest to the investigator, the procedure must be performed in a manner that minimizes exposure of the animal to unnecessary pain and suffering. Histologic alterations resulting from physical, chemical, or inhalation methods of euthanasia, when not evaluated in pilot experiments, can compromise the quality and reproducibility of data and invalidate study outcomes. Moreover, euthanasia by CO<sub>2</sub> inhalation causes histopathologic changes of moderate to marked intensity in all internal organs, indicating that alternative euthanasia techniques may be more appropriate for studies that require such analysis. Our results indicate that euthanasia of rats by decapitation or overexposure to isoflurane may be most suitable for avoiding pathologic changes in internal organs. However, as evidenced in previous studies, when selecting these euthanasia methods, one should always consider their specific applications, such as avoiding the use of euthanasia by isoflurane in female rats with a history of exposure to this anesthetic. A properly trained professional should be involved in the use of decapitation, and any protective or adverse effects associated with prior sedative use in this technique should be examined in the relevant tissue.

## Acknowledgments

We thank the staff of the Graduate Program in Experimental and Comparative Pathology, FMVZ-USP, Brazil, Mr. Mauro de Mattos (histology technician) and Mrs. Luciana Bandini (responsible for animal care and husbandry).

## Funding

This work was supported by the Coordenação de Aperfeiçoamento de Pessoal de Nível Superior (CAPES, finance code 001).

## References

1. **American Veterinary Medical Association.** 2020. AVMA Guidelines for the Euthanasia of Animals: 2020 Edition. Schaumburg (IL): AVMA. <https://www.avma.org/sites/default/files/2020-02/Guidelines-on-Euthanasia-2020.pdf>
2. **Andersen ML, Winter LMF.** 2019. Animal models in biological and biomedical research - Experimental and ethical concerns. *An Acad Bras Cienc* **91**:e20170238. <https://doi.org/10.1590/0001-3765201720170238>
3. **Bédard P, Gauvin S, Ferland K, Caneparo C, Pellerin E, Chabaud S, Bolduc S.** 2020. Innovative human three-dimensional tissue-engineered models as an alternative to animal testing. *Bioengineering (Basel)* **7**:115. <https://doi.org/10.3390/bioengineering7030115>
4. **Boivin GP, Bottomley MA, Schiml PA, Goss L, Grobe N.** 2017. Physiologic, behavioral, and histologic responses to various euthanasia methods in C57BL/6NTac male mice. *J Am Assoc Lab Anim Sci* **56**:69–78.
5. **Burkholder TH, Niel L, Weed JL, Brinster LR, Bacher JD, Foltz CJ.** 2010. Comparison of carbon dioxide and argon euthanasia: Effects on behavior, heart rate, and respiratory lesions in rats. *J Am Assoc Lab Anim Sci* **49**:448–453.
6. **Cait J, Cait A, Scott RW, Winder CB, Mason GJ.** 2022. Conventional laboratory housing increases morbidity and mortality in research rodents: results of a meta-analysis. *BMC Biol* **20**:15. <https://doi.org/10.1186/s12915-021-01184-0>
7. **Canadian Council of Animal Care.** 2010. Guidelines on Euthanasia of Animals Used in Science. Ottawa (ON): CCAC. <https://ccac.ca/Documents/Standards/Guidelines/Euthanasia.pdf>
8. **Carbone L.** 2021. Estimating mouse and rat use in American laboratories by extrapolation from Animal Welfare Act-regulated species. *Sci Rep* **11**:493. <https://doi.org/10.1038/s41598-020-79961-0>
9. **Clarkson JM, Martin JE, McKeegan DEF.** 2022. A review of methods used to kill laboratory rodents: Issues and opportunities. *Lab Anim* **56**:419–436. <https://doi.org/10.1177/00236772221097472>
10. **Close B, Banister K, Baumann V, Bernoth EM, Bromage N, Bunyan J, Erhardt W, Flecknell P, Gregory N, Hackbarth H, Morton D, Warwick C.** 1996. Recommendations for euthanasia of experimental animals: Part 1. DGXI of the European Commission. *Lab Anim* **30**:293–316. <https://doi.org/10.1258/002367796780739871>
11. **Close B, Banister K, Baumann V, Bernoth E-M, Bromage N, Bunyan J, Erhardt W, Flecknell P, Gregory N, Hackbarth H, Morton D, Warwick C.** 1997. Recommendations for euthanasia of experimental animals: Part 2. DGXI of the European Commission. *Lab Anim* **31**:1–32. <https://doi.org/10.1258/002367797780600297>
12. **Conlee KM, Stephens ML, Rowan AN, King LA.** 2005. Carbon dioxide for euthanasia: Concerns regarding pain and distress, with special reference to mice and rats. *Lab Anim* **39**:137–161. <https://doi.org/10.1258/0023677053739747>
13. **Conselho Nacional de Controle de Experimentação Animal.** 2018. Resolução normativa n° 37, de 15 de fevereiro de 2018. Anexo: Diretriz da prática de eutanásia do CONCEA. Brasília, DF: Ministério da Ciência, Tecnologia e Inovação, CONCEA. <https://www.gov.br/mcti/pt-br/composicao/conselhos/concea/arquivos/arquivo/legislacao/anexo-da-resolucao-normativa-no-37-de-15-de-fevereiro-de-2018.pdf>
14. **Coria-Avila GA, Gavrila AM, Ménard S, Ismail N, Pfaus JG.** 2007. Cecum location in rats and the implications for intraperitoneal injections. *Lab Anim (NY)* **36**:25–30. <https://doi.org/10.1038/labani0707-25>
15. **Ding Y, Zou J, Li Z, Tian J, Abdelalim S, Du F, She R, Wang D, Tan C, Wang H, Chen W, Lv D, Chang L.** 2011. Study of histopathological and molecular changes of rat kidney under simulated weightlessness and resistance training protective effect. *PLoS One* **6**:e20008. <https://doi.org/10.1371/journal.pone.0020008>
16. **Feldman DB, Gupta BN.** 1976. Histopathologic changes in laboratory animals resulting from various methods of euthanasia. *Lab Anim Sci* **26**:218–221.
17. **Gurcan MN, Boucheron LE, Can A, Madabhushi A, Rajpoot NM, Yener B.** 2009. Histopathological image analysis: a review. *IEEE Rev Biomed Eng* **2**:147–171. <https://doi.org/10.1109/RBME.2009.2034865>
18. **Hickman DL, Johnson SW.** 2011. Evaluation of the aesthetics of physical methods of euthanasia of anesthetized rats. *J Am Assoc Lab Anim Sci* **50**:695–701.
19. **Hidayat R, Wulandari P.** 2021. Euthanasia procedure of animal model in biomedical research. *Biosci Med: J Biomed Translat Res* **5**:540–544. <https://doi.org/10.32539/bsm.v5i6.310>
20. **Kafkafi N, Agassi J, Chesler EJ, Crabbe JC, Crusio WE, Eilam D, Gerlai R, Golani I, Gomez-Marin A, Heller R, Iraqi F, Jaljuli I, Karp NA, Morgan H, Nicholson G, Pfaff DW, Richter SH, Stark PB, Stiedl O, Stodden V, Tarantino LM, Tucci V, Valdar W, Williams RW, Würbel H, Benjamini Y.** 2018. Reproducibility and replicability of rodent phenotyping in preclinical studies. *Neurosci Biobehav Rev* **87**:218–232. <https://doi.org/10.1016/j.neubiorev.2018.01.003>
21. **Ko MJ, Mulia GE, van Rijn RM.** 2019. Commonly used anesthesia/euthanasia methods for brain collection differentially impact

- MAPK activity in male and female C57BL/6 mice. *Front Cell Neurosci* **13**:96. <https://doi.org/10.3389/fncel.2019.00096>.
22. **Laferriere CA, Pang DSJ**. 2020. Review of intraperitoneal injection of sodium pentobarbital as a method of euthanasia in laboratory rodents. *J Am Assoc Lab Anim Sci* **59**:254–263. <https://doi.org/10.30802/AALAS-JAALAS-19-000081>.
  23. **Mähler (Convenor) M, Berard M, Feinstein R, Gallagher A, Illgen-Wilcke B, Pritchett-Corning K, Raspa M**. 2014. FELASA recommendations for the health monitoring of mouse, rat, hamster, guinea pig and rabbit colonies in breeding and experimental units. *Lab Anim* **48**:178–192. <https://doi.org/10.1177/0023677213516312>.
  24. **Marquardt N, Feja M, Hünigen H, Plendl J, Menken L, Fink H, Bert B**. 2018. Euthanasia of laboratory mice: Are isoflurane and sevoflurane real alternatives to carbon dioxide? *PLoS One* **13**:e0203793. <https://doi.org/10.1371/journal.pone.0203793>.
  25. **Mohamed AS, Hosney M, Bassiony H, Hassanein SS, Soliman AM, Fahmy SR, Gaafar K**. 2020. Sodium pentobarbital dosages for exsanguination affect biochemical, molecular and histological measurements in rats. *Sci Rep* **10**:378. <https://doi.org/10.1038/s41598-019-57252-7>.
  26. **Mukherjee P, Roy S, Ghosh D, Nandi SK**. 2022. Role of animal models in biomedical research: a review. *Lab Anim Res* **38**:18. <https://doi.org/10.1186/s42826-022-00128-1>.
  27. **National Research Council of the National Academies**. 2011. *Guide for the Care and Use of Laboratory Animals*, 8th ed. Washington (DC): National Academies Press. <https://grants.nih.gov/grants/olaw/guide-for-the-care-and-use-of-laboratory-animals.pdf>
  28. **Ritschl LM, Fichter AM, Häberle S, von Bomhard A, Mitchell DA, Wolff KD, Mücke T**. 2015. Ketamine-xylazine anesthesia in rats: intraperitoneal versus intravenous administration using a microsurgical femoral vein access. *J Reconstr Microsurg* **31**:343–347. <https://doi.org/10.1055/s-0035-1546291>.
  29. **Schafer KA, Eighmy J, Fikes JD, Halpern WG, Hukkanen RR, Long GG, Meseck EK, Patrick DJ, Thibodeau MS, Wood CE, Francke S**. 2018. Use of severity grades to characterize histopathologic changes. *Toxicol Pathol* **46**:256–265. <https://doi.org/10.1177/0192623318761348>.
  30. **Schoell AR, Heyde BR, Weir DE, Chiang PC, Hu Y, Tung DK**. 2009. Euthanasia method for mice in rapid time-course pulmonary pharmacokinetic studies. *J Am Assoc Lab Anim Sci* **48**:506–511.
  31. **Shomer NH, Allen-Worthington KH, Hickman DL, Jonnalagadda M, Newsome JT, Slate AR, Valentine H, Williams AM, Wilkinson M**. 2020. Review of rodent euthanasia methods. *J Am Assoc Lab Anim Sci* **59**:242–253. <https://doi.org/10.30802/AALAS-JAALAS-19-000084>.
  32. **Tobar Leitão SA, Soares DS, Carvas-Junior N, Zimmer R, Ludwig NF, Andrades M**. 2021. Study of anesthetics for euthanasia in rats and mice: A systematic review and meta-analysis on the impact upon biological outcomes (SAFE-RM). *Life Sci* **284**:119916. <https://doi.org/10.1016/j.lfs.2021.119916>.
  33. **Uysal M, Gül SS, Karaman S, Tas U, Sapmaz HI, Uysal F, Aytakin K, Tümer MK**. 2017. Caecum location in laboratory rats and mice: an anatomical and radiological study. *Lab Anim* **51**:245–255. <https://doi.org/10.1177/0023677216658916>.
  34. **van Rijn CM, Krijnen H, Menting-Hermeling S, Coenen AML**. 2011. Decapitation in rats: latency to unconsciousness and the “wave of death”. *PLoS One* **6**:e16514. <https://doi.org/10.1371/journal.pone.0016514>.
  35. **Wong D, Makowska IJ, Weary DM**. 2013. Rat aversion to isoflurane versus carbon dioxide. *Biol Lett* **9**:20121000. <https://doi.org/10.1098/rsbl.2012.1000>.