

AperTO - Archivio Istituzionale Open Access dell'Università di Torino

**Superpulsed laser therapy on healing process after tooth extraction in patients waiting for liver transplantation**

**This is the author's manuscript**

*Original Citation:*

*Availability:*

This version is available <http://hdl.handle.net/2318/131808> since 2019-04-30T09:41:30Z

*Published version:*

DOI:10.1007/s10103-010-0880-z

*Terms of use:*

Open Access

Anyone can freely access the full text of works made available as "Open Access". Works made available under a Creative Commons license can be used according to the terms and conditions of said license. Use of all other works requires consent of the right holder (author or publisher) if not exempted from copyright protection by the applicable law.

(Article begins on next page)



UNIVERSITÀ DEGLI STUDI DI TORINO

This is an author version of the contribution published on:

Mozzati M, Martinasso G, Cocero N, Pol R, Maggiora M, Muzio G, Canuto  
RA

Superpulsed laser therapy on healing process after tooth extraction in patients  
waiting for liver transplantation

LASERS IN MEDICAL SCIENCE (2012) 27

DOI: 10.1007/s10103-010-0880-z

The definitive version is available at:

<http://www.springerlink.com/index/pdf/10.1007/s10103-010-0880-z>

Superpulsed Laser Therapy on Healing Process after Tooth Extraction in Patients Waiting for Liver Transplantation.

M Mozzati<sup>1</sup>, G Martinasso<sup>2</sup>, N Cocero<sup>1</sup>, R Pol<sup>1</sup>, M Maggiora<sup>2</sup>, G Muzio<sup>2</sup>, RA Canuto<sup>2,3</sup>

<sup>1</sup>Oral Surgery Unit, Dentistry Section, Department of Biomedical Sciences and Human Oncology, University of Turin, Italy.

<sup>2</sup>Department of Experimental Medicine and Oncology, University of Turin, Italy

<sup>3</sup>Corresponding author:

Prof. Rosa Angela Canuto

Dipartimento di Medicina ed Oncologia Sperimentale

Università di Torino

Corso Raffaello 30

10125 TORINO (ITALY)

tel. n. +39 011 6707781, fax n. +39 011 6707753

e-mail [rosangela.canuto@unito.it](mailto:rosangela.canuto@unito.it)

## ABSTRACT

Alveolar healing following tooth extraction is a complex repair process involving different tissues, including epithelium and bone.

This research aimed to study the effect of laser therapy on alveolar healing process in patients waiting for liver transplantation, evaluating some inflammation, osteogenesis and clinical parameters.

Twelve patients with hepatic failure waiting for liver transplantation, with indications to bilateral extraction, entered the split-mouth study. One post-extractive defect was treated with laser while the other was left without treatment. Specimens of soft tissues were removed from around the tooth before extraction and after 7 days.

Superpulsed laser irradiation prevented IL-1 $\beta$  increase and induced IL-6, IL-10 and collagen III increase at 7 days in comparison with their level before extraction, whereas the other parameters were unmodified. Moreover, the epithelial regeneration evidenced a positive result of laser therapy, and the patients reported a lower pain in the site treated with laser.

In conclusions, laser therapy appears to be a treatment of choice for patients, providing clinical efficacy, being safe, well tolerated and able to prevent inflammation.

**KEY WORDS:** laser, cytokines, collagen, pain, laser therapy, tooth extraction

## INTRODUCTION

Alveolar healing following tooth extraction is a complex repair process involving different types of tissues, including epithelium and bone. In healthy subjects, epithelial cells start to migrate early during the first day post-extraction and their proliferation is already marked by day four; bone production begins at 10 days after extraction [1] and is no longer evident at 20 weeks [2].

Patients with liver disease could have an high risk of post-operative hemorrhages and augmentation of fibrin cloth stabilization time in the first period of healing process, since liver is responsible for the production of main coagulation factors [3]. Therefore, it is important to accelerate wound healing process, in order to reduce healing delay and the possible post-operative complications.

Synthetic bone substitutes can be used to accelerate bone repair in tooth extraction; these include various types of hydroxyapatite and synthetic glasses [4]. Since these substitutes especially target bone repair, other techniques could be tested.

Various studies have addressed the application of laser therapy to dental practice [5,6]. In general, low-level laser therapy (LLLT) has been used for several years, and no adverse effects have been demonstrated [5,7]. It is thought to reduce pain [8,9], accelerate wound healing and reduce the inflammatory process, it also enhances bone remodelling and repair [5,10]. A literature review of studies regarding wound healing in general identified 47 relevant studies in rodents. Findings from these consistently demonstrated the ability of laser or monochromatic light therapy to stimulate wound healing processes in experimental wounds in rats and mice, and strongly support the case for further controlled research in humans [11-13].

As regards healing of bone defects and fractures, and the osseointegration of biomaterial, some studies are available, including those using cell cultures, animal models and clinical studies; these have reported a positive effect of LLLT on bone healing. The use of LLLT for biostimulation of alveolar bone repair has thus been steadily increasing. As a bone attachment stimulating factor, LLLT could be used by dentists in cases in which negative factors are present that are predictive of poor osseointegration; it represents an important improvement in dental practice [5].

Little evidence is available concerning the influence of monochromatic light on either periodontal or peri-implant wound healing, derived from experimental animal studies and randomized controlled clinical trials [14], and the benefit over conventional treatment procedures is in doubt. Moreover, no studies concern the use of laser therapy to improve healing processes following tooth extraction in patients with pathological problems, such as those waiting for liver transplantation.

To examine the effect of laser in healing processes following tooth extraction, it is appropriate to evaluate some inflammatory and osteogenesis parameters.

Inflammation is a very complex and finely orchestrated process involving many cell types and molecules [15-17]. Among inflammatory factors, interleukin-1 $\beta$  (IL-1 $\beta$ ), IL-6 and prostaglandin-E2 (PGE2) are factors present in the gingival crevicular fluid involved in the establishment of inflammatory processes in the oral cavity [18,19], whereas IL-10 and transforming growth factor (TGF)- $\beta$ 2 can be involved in the healing processes.

IL-1 $\beta$ , a strong pro-inflammatory protein, is responsible for the mediation of prostaglandin and leukotriene production and the platelet-activating factor in several cell types, and it plays a major role in both acute and chronic periodontal inflammation [16,17,20]. Moreover, it promotes osteoclast formation and bone resorption [21]. In fact, it has been demonstrated that inhibition of IL-1 $\beta$  reduces tissue destruction and the progression of inflammation in experimental periodontitis [15,22].

IL-6 has pro- and anti-inflammatory functions and controls regenerative processes including wound healing and liver regeneration [23].

IL-10 is a pleiotropic cytokine that regulates a variety of functions of hemopoietic cells. Its principal everyday function appears to be one of containment and eventually termination of inflammatory responses. Thus IL-10 facilitates elimination of infectious organisms while causing minimal damage to host tissues. Early clinical trials suggest that IL-10 has a good safety profile and may be of use in treating autoimmune and inflammatory conditions. IL-10 potently inhibits

production of several cytokines by activated monocytes/macrophages. Moreover, IL-10 has been found to inhibit production of PGE<sub>2</sub>, through down-regulation of COX-2 expression [24].

The present study examined the effects of laser therapy on healing process following tooth extraction in patients waiting for liver transplantation, evaluating some inflammation, osteogenesis and clinical parameters.

## PATIENTS AND METHODS

### **Patients**

Twelve patients with hepatic failure waiting for liver transplantation, with indications to bilateral extraction, entered the study. Informed consent was obtained from all patients. The study protocol was approved by the Ethics Committee of Turin University. This was a split-mouth study, in which the patient becomes his/her own control, thus eliminating all individual differences in response to laser treatment.

### **Surgical Protocol**

Two extractions were performed in the same surgical session. After locoregional anaesthesia (mepivacaine 2% with adrenaline 1:100000), tooth extraction was achieved through luxation and avulsion with clamp. In each patient, one post-extraction site was treated with laser irradiation, while the other was left untreated as control. Left and right sites were assigned randomly. This provided the best possible control group, because both treatments were carried out in the same patient, with the same surgical procedure and in identical microbiologic conditions, and by the same surgeon. In all cases, 3-0 silk sutures were used to suture the alveolar mucosa; they were removed after 7 days. Patients were given antibiotic (1 g amoxicillin every 12 hours for 6 days) and oral anti-inflammatory treatment (400 mg Ibuprofen every 12 hours for 3 days), since these patients need this therapy.

Specimens of soft tissue were removed from control and treated with laser sites at the following times: before tooth extraction (T0) and after seven days (T7). All specimens were placed in RNA Later solution (Qiagen, Milan, Italy), and maintained at  $-80^{\circ}\text{C}$  until use.

### **Laser Treatment**

In each patient, one post-extraction site was treated with super-pulsed laser irradiation, immediately after molar extraction and at days 3 and 5. A Lumix 2 HFPL Dental device IR (904–910 nm) Gallium Arsenide laser (Fisioline s.n.c., Verduno, Cuneo, Italy) was used, with the following experimental parameters: pulse width 200 nanoseconds, minimum peak power 33 W, average out power 200 mW (measured by absolute measurer), illuminated area  $1\text{ cm}^2$ , irradiance  $200\text{ mW/cm}^2$ , frequency 30 kHz, exposure time 15 minutes, total energy 180 J. The dose administered was  $180\text{ J/cm}^2$ . The laser probe was placed in contact with the mucosa, to cover the alveolar socket without moving. The patient was not aware of the side that was being treated with the laser, since a non-working laser was used for the untreated site. Specimens of soft tissue were removed as above (Figure 1).

### **Biological factor analysis**

The specimens removed from control site and from site treated with laser irradiation were processed to determine expression of inflammatory and osteogenesis parameters, using Real-time polymerase chain reaction (PCR). Interleukin (IL)- $1\beta$ , IL-6, IL-10, transforming growth factor (TGF)- $\beta$ 2, cyclooxygenase-2 (COX-2), bone morphogenetics protein (BMP)-4 and BMP-7, peroxisome proliferator-activated receptor (PPAR)- $\beta$ , collagen type I and type III were examined.

Total RNA was extracted from the specimens using the NucleoSpin RNA II Kit (Macherey-Nagel GmbH & Co. KG, Düren, Germany). Real-time PCR was performed with single-stranded cDNA prepared from total RNA ( $1\text{ }\mu\text{g}$ ) using a High-Capacity cDNA Archive kit (Applied Bio Systems, Foster City, CA).



The forward (FW) and reverse (RV) primers shown in Table 1 were designed using the Beacon Designer® program (Bio-Rad, Hercules, CA). Twenty-five microliters of a PCR mixture containing cDNA template equivalent 40 ng of total RNA, 5 pmoles each of forward and reverse primers, and 2  $\mu$ l IQ SYBR Green SuperMix (Bio-Rad, Hercules, CA) were amplified using an iCycler PCR instrument (Bio-Rad, Hercules, CA) with an initial melt at 95°C for 10 min, followed by 35-40 cycles at 95°C for 40 s, annealing temperature for each primer set for 40 s, and 72°C for 40 s. A final extension of 7 min at 72°C was applied. Each sample was tested in duplicate, and threshold cycle (Ct) values were averaged from each reaction. For both specimens derived from control site and from site treated with laser irradiation, the change in expression was defined as that detected in the specimen taken at T7 versus that detected at T0, calculated as  $2^{-\Delta\Delta Ct}$ , where  $\Delta Ct = Ct_{\text{sample}} - Ct_{\text{GAPDH}}$  and  $\Delta\Delta Ct = \Delta Ct_{\text{T7 sample}} - \Delta Ct_{\text{T0 sample}}$ .

### **Clinical evaluation**

As regard clinical examinations, the epithelial regeneration was evaluated at each experimental time by the operator (Figure 1), and each patient was asked to score subjective pain on a 10 cm visual analog scale (VAS), with 0 cm indicating no pain and 10 cm indicating the worst possible pain. Pain was evaluated each day at the same time from 2 hours after extraction (T1) to day 7 (T7) post-extraction.

### **Statistical analysis**

Statistical analyses were performed using the InStat3 software package. All data are expressed as means  $\pm$  SD. The significance of differences between control and specimens treated with laser irradiation mean values was assessed by the non-parametric Wilcoxon matched-pairs signed-ranks test. Data were taken as being statistically significant for  $p < 0.05$ .

## **RESULTS**

### **Biological factor analysis in patients waiting liver transplantation**

Analysis of biological factors involved in inflammation process and in the healing after tooth extraction is shown in the Figures 2-4. Figure 2 shows the inflammatory factors, namely IL-1 $\beta$ , IL-6 and IL-10. At 7 days from the surgical procedure, in the specimens of soft tissues removed from the sites treated with superpulsed laser irradiation, the values of IL-1 $\beta$  and IL-10 were not statistically different from control specimens, whereas IL-6 increased significantly. Comparing the values of cytokines between T7 and T0, it was observed that IL-1 $\beta$  and IL-10 increased significantly in the specimens treated with laser irradiation and not in the control, whereas IL-6 increased in both control and in the specimens treated with laser irradiation. Figure 3 panel A shows that the two biological factors involved in the healing process, TGF- $\beta$ 2 and PPAR- $\beta$ , did not show any variation. Figure 3 panel B reports the biological factors involved in the bone healing, BMP4 and 7. These factors did not show any variation, probably because 7 days is a very short time to evidence bone healing. As regards collagen, significant modification was evident for collagen III in the specimens removed at T7 from the sites treated with laser irradiation in comparison with those at T0, and a trend of increase was present in the same specimens removed from sites treated with laser irradiation in comparison with controls (Figure 4). On the contrary, significant modification was not evident for collagen I (Figure 4).

### **Clinical evaluation in patients waiting liver transplantation**

For the clinical examination, at 7 days the operator observed that the process of epithelial regeneration appeared to be more rapid (complete) in laser-treated sites in comparison with control sites (Figure 1, panel F). The patients, asked to score their feeling of pain on a 10 cm visual analog scale (VAS), with 0 cm reflecting no pain and 10 cm reflecting worst pain possible, reported less pain at the site treated with laser irradiation than they did at the control site (Figure 5).

## DISCUSSION

This research comprises the first split-mouth study of the effect of laser irradiation on tooth-extraction site healing. The patient becomes his/her own control, which eliminates all individual differences in response to laser treatment.

It is also the first study examining the healing process following tooth extraction in patients waiting for liver transplantation, evaluating biological factors rather than simply clinical aspects. These patients, before the transplantation, have necessary to eliminate each potential infective focus, for this each not healthy tooth must to be removed [3]. To improve the healing and to reduce the pain is an important goal for the patients.

These two points combine to make the study unique of its kind, and it offers significant information for future research on patients with other pathological conditions.

The number of patients is limited to 12, as the particular type of patients and the necessity to have an indication for bilateral extraction. Moreover, the patients had to receive antibiotic and anti-inflammatory therapy, but these drugs did not influence the results, being both sites treated or not exposed to drugs.

Laser treatment is an innovative approach, and it is increasingly used in medicine. It has been shown to produce several different effects, including pain relief, wound healing and nerve regeneration. It has potential antimicrobial and biostimulating effects when applied to oral tissues, for example improving wound healing, enhancing epithelization after periodontal surgery, minimizing oedema after third-molar surgery, and preventing oral mucositis [25-30].

It has been demonstrated that laser therapy stimulates cell proliferation and the formation of lymphatic and blood vessels [31,32], and it may improve bone mineralization [10,33,34]. The effect of laser therapy on bone regeneration has been the focus of recent researches, including in dentistry. Studies have investigated the ability of this irradiation to stimulate both bone production and bone-implant interaction [10,35].

As regards biological factors involved in the healing process following tooth extraction, these factors will be analyzed in the specimens of soft tissues removed from the sites treated or not with

superpulsed laser irradiation. The majority of the papers regarding oral problems evaluated the content of cytokines in the crevicular fluid [16,18,20], whereas, here the ability of the mucosa cells to synthesize the cytokines involved in the inflammatory process and the factors involved in the osteogenesis has been evaluated.

The superpulsed laser irradiation used in this research acts on pro-inflammatory cytokines, preventing the increase of level of IL-1 $\beta$ , but not that of IL-6.

This unexpected result can be explained with two possible explanations, as also reported in previous paper for the treatment with PRGF to favour the healing wound [36]: 1) IL-6 could facilitate wound healing, because it also shows slight anti-inflammatory activity [37], inducing keratinocyte proliferation and inhibiting pro-inflammatory cytokines [38]. Thus the involvement of IL-6 on facilitating wound healing must be also considered as a possibility, based on their stimulation of keratinocyte proliferation. It has also been evidenced that IL-6 favours the liver regeneration [23]. 2) At the laser treatment sites, the increase of IL-6 was also accompanied by the increase in IL-10, a cytokine possessing anti-inflammatory activity [39]. Therefore, IL-10 can counterbalance the pro-inflammatory properties of IL-6, favouring the healing process.

As regards the other parameters evaluated in this research, involved in healing process and in osteogenesis, only collagen III was found increased at T7 in the specimens from sites treated with laser. For the other osteogenesis parameters, probably the observation time was too short, and specimens of the mucosa from the healing site would need to be taken on the subsequent days. Differently, the observation of epithelial regeneration evidenced a positive result of laser therapy also in the early times.

The clinical parameter of pain was reported by patients to be lesser at the site treated with laser therapy than at the control site. Since the patient was not aware of the side that was being treated with the laser, because a non-working laser was used for the untreated site, the different sensation of the pain was valid.

Our findings might have a significant clinical impact, since laser treatment is easy to perform, do not increase morbidity and has no side effects. Moreover, the results obtained from this research may stimulate the use of laser treatment for patients with systemic diseases that may not be compatible with drug treatment.

In conclusion, this study suggests that superpulsed laser irradiation currently appears to be a treatment of choice, providing clinical efficacy, being safe and well tolerated, especially for those patients who requires conservative treatment.

#### ACKNOWLEDGMENTS

The work was supported by grants from Regione Piemonte and University of Turin, Italy.

#### REFERENCES

- [1] Boyne PJ (1966) Osseous repair of the postextraction alveolus in man. *Oral Surg Oral Med Oral Pathol* 21:805–813.
- [2] Ahn JJ, Shin HI (2008) Bone tissue formation in extraction sockets from sites with advanced periodontal disease: a histomorphometric study in humans. *Int J Oral Maxillofac Implant* 23:1133-1138.
- [3] Douglas LR, Douglas JB, Sieck JO, Smith PJ. (1998) Oral management of the patients with end-stage liver disease and liver transplant patient. *Oral surg Oral Med Oral patol Oral Radiol and Od* 86: 55-64.
- [4] Chiapasco M, Casentini P, Zaniboni M (2009) Bone augmentation procedures in implant dentistry. *Int J Oral Maxillofac Implants* 24:237-259.
- [5] Obradović RR, Kesić LG, Pesevska S (2009) Influence of low-level laser therapy on biomaterial osseointegration: a mini-review. *Lasers Med Sci* 24:447-451.

- [6] Walsh LJ (2003) The current status of laser applications in dentistry. *Aust Dent J* 48:146-155.
- [7] Qadri T, Miranda L, Tunér J, Gustafsson A (2005) The short-term effects of low-level lasers as adjunct therapy in the treatment of periodontal inflammation. *J Clin Periodontol* 32:714-719.
- [8] Chukwunke F, Onyejiaka N (2007) Management of postoperative morbidity after third molar surgery: a review of the literature. *Niger J Med* 16:107-112.
- [9] Sun G, Tunér J (2004) Low-level laser therapy in dentistry. *Dent Clin North Am* 48:1061-1076.
- [10] Saracino S, Mozzati M, Martinasso G, Pol R, Canuto RA, Muzio G (2009) Superpulsed laser irradiation increases osteoblast activity via modulation of bone morphogenetic factors. *Lasers Surg Med* 41:298-304.
- [11] Peplow PV, Chung TY, Baxter GD (2009) Laser Photobiomodulation of Wound Healing: A Review of Experimental Studies in Mouse and Rat Animal Models. *Photomed Laser Surg* [Epub ahead of print]
- [12] Gonzaga Ribeiro MA, Cavalcanti de Albuquerque RL, Santos Barreto AL, Moreno de Oliveira VG, Santos TB, Freitas Dantas CD (2009) Morphological analysis of second-intention wound healing in rats submitted to 16 J/cm<sup>2</sup> lambda 660-nm laser irradiation. *Indian J Dent Res* 20:390-396.
- [13] Medeiros JL, Nicolau RA, Nicola EM, Dos Santos JN, Pinheiro AL (2009) Healing of Surgical Wounds Made with lambda970-nm Diode Laser Associated or Not with Laser Phototherapy (lambda655 nm) or Polarized Light (lambda400-2000 nm). *Photomed Laser Surg* [Epub ahead of print]
- [14] Schwarz F, Aoki A, Sculean A, Becker J (2009) The impact of laser application on periodontal and peri-implant wound healing. *Periodontol* 2000 51:79-108.
- [15] Delaleu N, Bickel M (2004) Interleukin-1 $\beta$  and interleukin-18: regulation and activity in local inflammation. *Periodontol* 2000 35:42-52.

- [16] Orozco A, Gemmel E, Bickel M, Seymour GJ (2006) Interleukin 1 $\beta$ , interleukin-12 and interleukin-18 levels in gingival fluid and serum of patients with gingivitis and periodontitis. *Oral Microb Immunol* 21:256–260.
- [17] Schierano G, Pejrone G, Roana J, Scalas D, Allizond V, Martinasso G, et al. (2010) A split-mouth study on microbiological profile in clinical healthy teeth and implants related to key inflammatory mediators *Int J Immunopathol Pharmacol* 23:279-288.
- [18] Schierano G, Pejrone G, Brusco P, Trombetta A, Martinasso G, Preti G, et al. (2008) TNF- $\alpha$ , TGF- $\beta$ 2 and IL-1 $\beta$  levels in gingival and peri-implant crevicular fluid before and after de novo plaque accumulation. *J Clin Periodontol* 35:532-538.
- [19] Noguchi K, Ishikawa I (2007) The roles of cyclooxygenase-2 and prostaglandin E2 in periodontal disease. *Periodontol* 2000 43:85-101.
- [20] Goutoudi P, Diza E, Arvantidou M (2004) Effect of periodontal therapy on crevicular fluid interleukin-1 $\beta$  and interleukin-10 levels in chronic periodontitis. *J Dent* 32:511–520.
- [21] Lee YM, Fujikado N, Manaka H, Yasuda H, Iwakura Y (2010) IL-1 plays an important role in the bone metabolism under physiological conditions. *Int Immunol* 22:805-816.
- [22] Delima AJ, Oates T, Assuma R, Schwartz Z, Cochran D, Amar S, et al. (2001) Soluble antagonists to interleukin-1 (IL1) and tumor necrosis factor (TNF) inhibits loss of tissue attachment in experimental periodontitis. *J Clin Periodontol* 28:233–240.
- [23] Malchow S, Thaiss W, Jänner N, Gewiese-Rabsch J, Garbers C, Yamamoto K, et al. (2010) Essential Role of Neutrophil Mobilization in Concanavalin A-Induced Hepatitis is based on Classic IL-6 Signaling but not IL-6 Trans-Signaling. *Biochim Biophys Acta* [Epub ahead of print].
- [24] Moore KW, de Waal Malefyt R, Coffman RL and O'Garra A (2001) Interleukin-10 and the interleukin-10 receptor. *Annu Rev Immunol* 19:683–765.
- [25] Gál P, Mokry M, Vidinsky B, Kilik R, Depta F, Harakalová M, et al. (2009) Effect of equal daily doses achieved by different power densities of low-level laser therapy at 635 nm on

open skin wound healing in normal and corticosteroid-treated rats. *Lasers Med Sci* 24:539-547.

- [26] Gál P, Vidinský B, Toporcer T, Mokry M, Mozes S, Longauer F, et al. (2006) Histological assessment of the effect of laser irradiation on skin wound healing in rats. *Photomed Laser Surg* 24:480-448.
- [27] Ozcelik O, Cenk Haytac M, Kunin A, and Seydaoglu G (2008) Improved wound healing by low-level laser irradiation after gingivectomy operations: a controlled clinical pilot study. *J Clin Periodontol* 35:250-254.
- [28] Amorim JC, de Sousa GR, de Barros Silveira L, Prates RA, Pinotti M, and Ribeiro MS (2006) Clinical study of the gingiva healing after gingivectomy and low-level laser therapy. *Photomed Laser Surg* 24:588-594.
- [29] Markovic A, and Todorovic LJ (2007) Effectiveness of dexamethasone and low-power laser in minimizing oedema after third molar surgery: a clinical trial. *Int J Oral Maxillofac Surg* 36:226-229.
- [30] Antunes HS, de Azevedo AM, da Silva Bouzas LF, Adão CA, Pinheiro CT, Mayhe R, et al. (2007) Lowpower laser in the prevention of induced oral mucositis in bone marrow transplantation patients: a randomized trial. *Blood* 109:2250-2255.
- [31] Pourzarandian A, Watanabe H, Aoki A, Ichinose S, Sasaki KM, Nitta H, et al. (2004) Histological and TEM examination of early stages of bone healing after Er:YAG laser irradiation. *Photomed Laser Surg* 22:342-350.
- [32] Polosukhin VV (2000) Ultrastructure of the blood and lymphatic capillaries of the respiratory tissue during inflammation and endobronchial laser therapy. *Ultrastruct Pathol* 24:183-189.
- [33] Pires Oliveira DA, de Oliveira RF, Zangaro RA, and Soares CP (2008) Evaluation of low-level laser therapy of osteoblastic cells. *Photomed Laser Surg* 26:401-404.
- [34] Pinheiro AL, and Gerbi ME (2006) Photoengineering of bone repair processes. *Photomed Laser Surg* 24:169-178.



- [35] Maluf AP, Maluf RP, da Rocha Brito C, França FM, de Brito RB Jr (2010) Mechanical evaluation of the influence of low-level laser therapy in secondary stability of implants in mice shinbones. *Lasers Med Sci* [Epub ahead of print].
- [36] Mozzati M, Martinasso G, Pol R, Polastri C, Cristiano A, Muzio G, et al. (2010) The impact of PRGF on clinical and biological factors involved in healing processes following third molar extraction. *J Biomed Mater Res A* [Epub ahead of print].
- [37] Opal SM, De Palo VA (2000) Anti-inflammatory cytokines *Chest* 117:1162-1172.
- [38] Werner S, Grose R (2003) Regulation of wound healing by growth factors and cytokines *Physiol Rev* 83:835-870.
- [39] Chang HC, Bistrian B (1998) The role of cytokines in the catabolic consequences of infection and injury *J Parenter Enter Nutr* 22:156-166.

## FIGURE CAPTIONS

### Figure 1

Case report: protocol of extraction and laser treatment.

**A:** All patients were referred to undergo a radiological examination, which include a dental panoramic radiograph (OPT). **B:** Two dental extractions were performed in the same surgical session. **C:** Samples of soft tissues were removed from around post-extraction sockets at the following times: before tooth extraction and after seven days. All specimens were placed in RNA Later solution (Qiagen, Milan, Italy), and maintained at  $-80^{\circ}\text{C}$  until use. **D:** 3-0 silk sutures were used to stitch the alveolar mucosa. **E:** After teeth extractions, one post-extractive defect was treated with superpulsed laser irradiation, the third and the fifth day after surgery. A Lumix 2 HFPL Dental device IR (904–910 nm) Gallium Arsenide laser (Fisioline s.n.c., Verduno, Cuneo, Italy) was used. **F:** Sutures were removed after seven days and the degree of epithelial regeneration was evaluated by the surgeon.

### Figure 2

Expression of IL-1 $\beta$ , IL-6 and IL-10 in the specimens of soft tissues removed from the alveolar site untreated (control) and treated with superpulsed laser irradiation at T7 in patients waiting liver transplantation.

Control (Ct) and superpulsed laser irradiation (Lt) values at T7 are referred to their respective T0 values, taken as 1 (white bar). The values are means  $\pm$  S.D. of 12 patients. The significance of differences between Ct and Lt means was assessed by non-parametric Wilcoxon test. \*  $p < 0.05$  Lt versus Ct, a  $p < 0.05$  T7 versus T0.

### Figure 3

Expression of TGF- $\beta$ 2, and PPAR- $\beta$  (panel A), and of BMP-4 and BMP-7 (panel B) in the specimens of soft tissues removed from the site untreated (control) and treated with superpulsed laser irradiation at T7 in patients waiting liver transplantation.

Control (Ct) and superpulsed laser irradiation (Lt) values at T7 are referred to their respective T0 values, taken as 1 (white bar). The values are means  $\pm$  S.D. of 12 patients. The significance of differences between Ct and Lt means was assessed by non-parametric Wilcoxon test. \*  $p < 0.05$  L versus C, a  $p < 0.05$  T7 versus T0.

#### Figure 4

Expression of collagen I (COLL-I) and collagen III (COLL-III) in the specimens of soft tissues removed from the site untreated (control) and treated with superpulsed laser irradiation at T7 in patients waiting liver transplantation.

Control (Ct) and superpulsed laser irradiation (Lt) values at T7 are referred to their respective T0 values, taken as 1 (white bar). The values are means  $\pm$  S.D. of 12 patients. The significance of differences between Ct and Lt means was assessed by non-parametric Wilcoxon test. \*  $p < 0.05$  L versus C, a  $p < 0.05$  T7 versus T0.

#### Figure 5

Visual analog scale (VAS) for pain measurement in untreated (Ct) and treated with superpulsed laser irradiation (Lt) sites for patients waiting liver transplantation.

Values are means  $\pm$  S.D. of 12 patients. The significance of differences between Ct and Lt means was assessed by non-parametric Wilcoxon test. \*  $p < 0.05$  L versus C

Figure 1

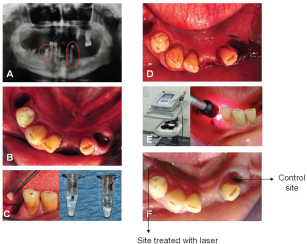


Figure 2

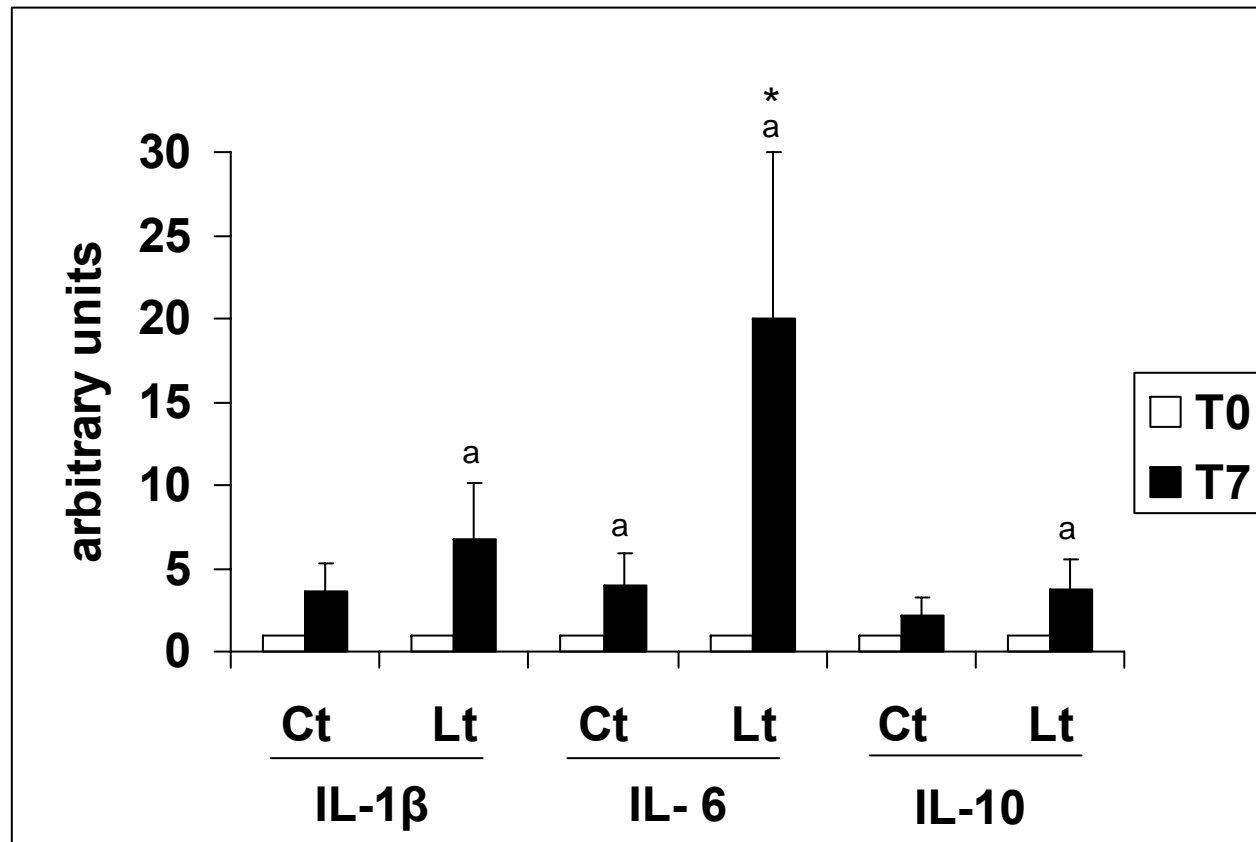


Figure 3

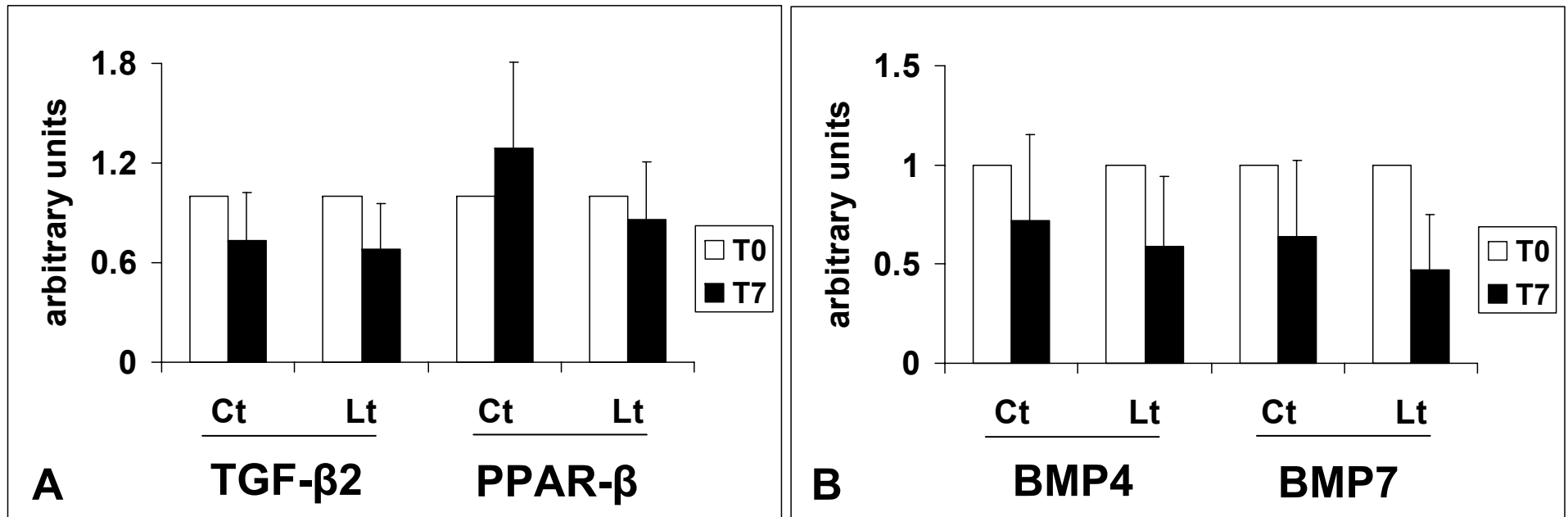


Figure 4

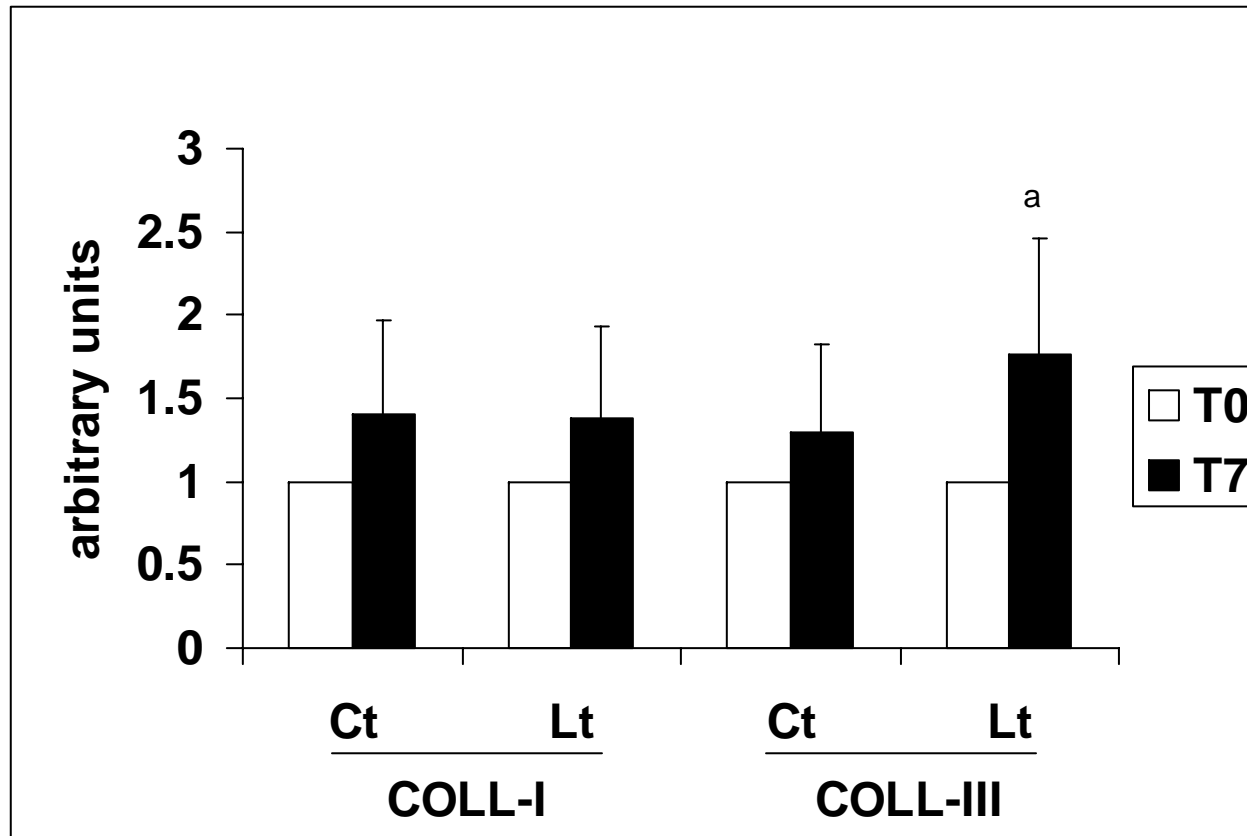


Figure 5

