

AperTO - Archivio Istituzionale Open Access dell'Università di Torino

**Tropical ulcer on a human tibia from 5000 years ago in Northern Italy.**

**This is the author's manuscript**

*Original Citation:*

*Availability:*

This version is available <http://hdl.handle.net/2318/141959> since 2017-05-28T09:49:53Z

*Published version:*

DOI:10.1002/Oa.2356

*Terms of use:*

Open Access

Anyone can freely access the full text of works made available as "Open Access". Works made available under a Creative Commons license can be used according to the terms and conditions of said license. Use of all other works requires consent of the right holder (author or publisher) if not exempted from copyright protection by the applicable law.

(Article begins on next page)



## UNIVERSITÀ DEGLI STUDI DI TORINO

This is an author version of the contribution published on:


Micheletti Cremasco M., Merlo F., Fulcheri E., Rothschild Bruce  
Tropical ulcer on a human tibia from 5000 years ago in Northern Italy.  
INTERNATIONAL JOURNAL OF OSTEOARCHAEOLOGY (2013) -  
DOI: 10.1002/Oa.2356

The definitive version is available at:

<http://doi.wiley.com/10.1002/oa.2356>

**Tropical ulcer on a human tibia from 5000 years ago in Northern Italy**

Journal:	<i>International Journal of Osteoarchaeology</i>
Manuscript ID:	OA-13-0112.R1
Wiley - Manuscript type:	Research Article
Date Submitted by the Author:	20-Oct-2013
Complete List of Authors:	Micheletti Cremasco, Margherita; University of Torino, Life Science and Systems Biology; Civico Museo Federico Eusebio, Anthropology Merlo, Francesco; University of Torino, Life Science and Systems Biology; Civico Museo Federico Eusebio, Anthropology Fulcheri, Ezio; Civico Museo Federico Eusebio, Anthropology; University of Genova, Pathological Anatomy Rothschild, Bruce; Northeast Ohio Medical University, Medicine; University of Kansas, Biodiversity Institute and Department of Anthropology
Keywords:	tropical ulcer, osteomyelitis, Italy, climate, skin, semantic confusion



## Tropical ulcer on a human tibia from 5000 years ago in Northern Italy

Margherita Micheletti Cremasco<sup>1-2</sup>, Francesco Merlo<sup>1-2</sup>, Ezio Fulcheri<sup>2-3</sup> and Bruce M. Rothschild<sup>4-5</sup>

<sup>1</sup> University of Torino, Dept. of Life Science and Systems Biology-via Accademia Albertina 13 -

10123 Torino- Italy. tel +39-011-6704546 fax +39-011-6704508

margherita.micheletti@unito.it

<sup>2</sup> Civico Museo Federico Eusebio, Alba Via Paruzza 1 - 12051 Alba (Cuneo) tel +39-0173-290092

fax +39-0173-362075

<sup>3</sup> University of Genova, Pathological Anatomy - via De Toni 14 - 16132 Genova tel +39-010-

3537816 fax +39-010-3537803 ezio.fulcheri@unige.it

<sup>4</sup> University of Kansas, Biodiversity Institute and Department of Anthropology– Lawrence, Kansas

66045, USA 011-785-615-1523 fax 011-785-294-1691

<sup>5</sup> Northeast Ohio Medical University, Department of Medicine – Rootstown, Ohio 44272, USA

Correspondence to: Bruce Rothschild, Biodiversity Center, University of Kansas, Lawrence,

Kansas, USA. 785-615-1523 fax 785-594-2691 bmr@ku.edu

Running title: Tropical ulcer, an environmental indicator?

Key words: Tropical ulcer, osteomyelitis, Italy, climate, skin, semantic confusion

Abstract

The term tropical ulcer, as applied to bone pathology, describes the specific pathologic phenomenon of the presence of a well defined osteomatous shelf formation on the anteromedial aspect of the tibia. Despite the appellation “tropical,” this pathology is not geographically limited to tropical regions, although it has not previously been reported from continental Europe.

Observations of a 4583 BP burial from the Tanaro River area of Northern Italy represent the first such case. Dating of the site to the time of climate change at the end of the first Glacial suggests

1 that hot-warm, humid conditions may have allowed occurrence of this bone pathology, the first  
2  
3 observed in continental Europe. A second explanation is the possible migration of an individual to  
4  
5 Italy from an area that is more conventionally considered tropical.  
6  
7  
8  
9  
10

## 11 Introduction

12  
13  
14  
15  
16  
17  
18  
19  
20 Semantics and preconceptions often confuse and prematurely limit diagnostic consideration  
21  
22 when bone abnormalities are discovered (Rothschild and Martin, 2006). This is especially true for  
23  
24 the isolated, well-delineated, broad-based, elevated, plaque-like excrescence on the anteromedial  
25  
26 aspect of tibiae, a pathologic phenomenon that has been traditionally termed a tropical ulcer, or an  
27  
28 osteomatous response to a tropical ulcer (Adamson, 1949; Brown and Middlemiss, 1956; Ennis et  
29  
30 al., 1972; Kolawole and Bohrer, 1970; Ngu, 1967; Resnick, 2002). The plaque-like surface is  
31  
32 typically irregular and related to the presence of an overlying skin ulcer. Despite its name, the  
33  
34 pathology referred to as tropical ulcer is not limited geographically to tropical regions (Ngu, 1967).  
35  
36 However, the phenomenon does not appear to have been previously reported from continental  
37  
38 Europe. Observation of the classic pathology in Copper Age Italy stimulated this study and provides  
39  
40 new perspective to climate change.  
41  
42  
43  
44  
45

## 46 Materials

47  
48  
49  
50  
51 Human remains were recognized in a monumental prehistoric tomb in Northern Italy  
52  
53 (Papillon, near Alba, Province of Cuneo) (Fig. 1) (Fulcheri and Micheletti Cremasco, 1998; Merlo  
54  
55 and Micheletti Cremasco, 2004; Merlo, Micheletti Cremasco, and Fulcheri, 2003; Venturino  
56  
57  
58  
59  
60

1  
2  
3  
4  
5  
6  
7  
8  
9  
10  
11  
12  
13  
14  
15  
16  
17  
18  
19  
20  
21  
22  
23  
24  
25  
26  
27  
28  
29  
30  
31  
32  
33  
34  
35  
36  
37  
38  
39  
40  
41  
42  
43  
44  
45  
46  
47  
48  
49  
50  
51  
52  
53  
54  
55  
56  
57  
58  
59  
60

Gambari et al., 1999, 2011b; Zoppi et al., 2001). The site was in an alluvial plain outside the ancient course of the Tanaro River. Archaeological and pedological evidence suggests that the structure could be a mortuary room devised as a definitive closed space that suffered ceiling collapse (Fig. 2).

The tomb contained severely damaged skeletal and dental remains, minute copper plate fragments, and a bone awl (Venturino Gambari et al., 1999). The human remains were found in the mortuary room on the stone floor (arenaria). The pathologic tibia (AB PAP 14/36) was located in the northeast corner (Fig. 3).

The presence of remains of four adult individuals and six children suggests a kind of ancestors' house (Micheletti Cremasco et al., 2011a,b). Dating eight of these remains, sampled from secondary burials, revealed a temporal range from the end of the Neolithic to the Copper Age, from  $4762 \pm 53$  BP calibration  $2\sigma$ : 3646-3499 BC (skull fragment -OZE027) to  $3679 \pm 41$  BP calibration  $2\sigma$ : 2194-2170 BC (coxa fragment-OZF826) (Venturino Gambari et al., 2011a).

Evaluations of burial manner (secondary and synchronic burial of human remains from different earlier grave-places) allow us to identify the later Copper age as a *post quem* end date. We can date use of the monumental tomb use as a secondary burial, but not before the second half III millennium BC latest Copper age (Radiometric Dating ANSTO, Physics Division – Menai – Australia. Venturino Gambari et al., 2011a).

#### Methods

The antiquity of the affected tibia was assessed by radiocarbon dating (ANSTO Physics Division Menai NSW 2234 AUSTRALIA) and corrected dates determined (Venturino Gambari et al., 2011a; Zoppi et al., 2001). Non-destructive investigation methodologies were otherwise employed for the paleopathological assessment. Osteological remains were evaluated only macroscopically and by radiologic examination.

1  
2  
3  
4 The pathologic tibial diaphysis AB\_PAP 14/36 was associated with insufficient other  
5 skeletal elements to determine age or gender. It (AB PAP 36) was assigned by radiocarbon dating  
6 to the mid 5<sup>th</sup> millennium B.P.: conventional age 4583 +/- 62 B.P. (specimen OZE028 - ANSTO  
7 Physics Division Menai NSW 2234 AUSTRALIA) (Venturino Gambari et al., 2011a; Zoppi et al.,  
8 2001) (Table 1.)  
9  
10  
11  
12  
13

14  
15 Macroscopic examination of the bone surface reveals a well-delineated, broad-based  
16 elevated, 4.5 cm oval plaque-like excrescence/bony pad on the anteromedial aspect of tibiae (Fig.  
17 4). A well-defined depressed area is present centrally (Figures 4,5). A post-mortem fracture  
18 permits recognition of thickening of the subjacent compact bone. Radiologic examination (Figures  
19 6,7) reveals apposition of bone on the tibial surface with increased bone density in and around the  
20 lesion.  
21  
22  
23  
24  
25  
26  
27  
28  
29

### 30 Discussion

31  
32 Tropical ulcer is the term utilized to identify a specific pathologic condition of bone that has  
33 been acquired in North, Central and East Africa, South America, Northern Australia, the South  
34 Pacific and Southeast Asia, but which has never been confidently reported in continental Europe  
35 (MacDonald, 2003; Ngu, 1967). It is described as a broad-based excrescence, resembling an  
36 osteoma (region of increased bone density) on the anteromedial aspect of the tibia (Adamson, 1949;  
37 Brown and Middlemiss, 1956; Ennis et al., 1972; Kolawole and Bohrer, 1970; Ngu, 1967; Resnick,  
38 2002). It is caused by a chronic penetrating ulcer, but is not necessarily limited to tropical regions  
39 (Ngu, 1967). It has been alternatively attributed to Vincent's type fusiform bacilli (e.g.,  
40 *Fusobacterium plautivincenti* and *F. fusiformis*), spirochetes (e.g., *Borrelia vincentii*, *Treponema*  
41 *vincenti*, *Spirochaeta schaudinni*) and *Staphylococcal* infections complicating traumatic injuries of  
42 the skin (Adamson, 1949; Adriaans et al., 1987; Kolawole and Bohrer, 1970; MacDonald, 2003;  
43 Ngu, 1967; Resnick, 2002). Malnutrition and poor hygiene have been suggested as contributing  
44  
45  
46  
47  
48  
49  
50  
51  
52  
53  
54  
55  
56  
57  
58  
59  
60

1 factors (Adamson, 1949; Ngu, 1967). A reviewer suggested an alternative pathophysiologic  
2 consideration, that the bone reaction is adaptive to a behavioural activity that puts considerable  
3 sustained pressure on the anterior tibia. It is an interesting consideration, which has not been  
4 previously associated with tropical ulcers. However, sustained pressure usually produces pressure  
5 erosions (indentations of the bone surface), not elevations (Rothschild and Martin, 2006), making  
6 such a pathophysiological contribution less likely.  
7  
8  
9

10  
11  
12  
13  
14  
15 There has been great confusion in application of the term tropical ulcer and distinguishing it  
16 from non-specific skin ulcer disease, which has spread to the adjacent skeleton producing a more  
17 generalized periosteal reaction (Boel and Ortner, 2011). The latter authors suggested tropical ulcers  
18 were present on skeletal elements from the American Civil War (National Museum of health and  
19 Medicine, Walter Reed Army Medical Center, Washington, D.C.), the Terry Human Anatomy and  
20 Huntington Collections (Anthropology Department, Smithsonian Institution, Washington, DC) from  
21 the early part of the 20<sup>th</sup> century, and one each from 3300 BCE Jordan, 1650 Juhle, Maryland and  
22 from Medieval Nordby, Denmark and Malmö, Sweden. These are reviewed in detail below.  
23  
24  
25

26  
27  
28  
29  
30  
31  
32 One of the Civil war cases, the Jordanian case, the Huntington collection case, the Maryland case,  
33 one Terry Collection case, and the Malmö, Sweden cases were reported as having components  
34 characteristic of what has been called a tropical ulcer, but their diagnosis is not confirmed (Table 2).  
35  
36  
37

38  
39  
40  
41  
42  
43  
44  
45  
46  
47  
48  
49  
50  
51  
52  
53  
54  
55  
56  
57  
58  
59  
60  
One of the illustrated Civil War cases is excluded because it actually manifested diffuse  
circumferential expansion, quite different from the elevated excrescence of tropical ulcers. This  
tubular characterization was indistinguishable from the other cases reported by Boel and Ortner  
(2011) and allows their exclusion as examples of tropical ulcer. A second Civil War case had  
fibular involvement, characteristic of generalized osteomyelitis. The illustration of the Terry  
Collection case was actually that of a generalized periosteal reaction of the lower leg and the ulcer  
was actually excavated, not elevated. The Maryland case did have an elevated defined lesion,  
associated with remodeling of the entire tibia to produce a bowed appearance. The Huntington  
Collection case had sequestered bone (but not within the elevated area), characteristic of a bone



1  
2 abscess. The Jordanian case had fibular involvement, suggestive of generalized osteomyelitis. The  
3  
4 un-illustrated Malmö, Sweden case is difficult to assess, as Boel and Ortner (2011) noted neither  
5  
6 smooth, eroded, undulating nor the abnormal surface bone formation, as are found in tropical ulcers.  
7  
8 Thus, only three of the reported cases (Civil War, Maryland and Malmö, Sweden, the latter  
9  
10 unlikely) could represent a tropical ulcer. However, the term ivory osteoma has been applied to  
11  
12 tropical ulcers (Kolawole and Bohrer, 1970), and all reported cases had reduced, not increased  
13  
14 density (Boel and Ortner, 2011).  
15  
16

17  
18 None of these purported cases were from continental Europe. Roberts and Manchester  
19  
20 (2005: 172) illustrate a tibia from 12<sup>th</sup>-16<sup>th</sup> century Chichester, Sussex, England with what they  
21  
22 called “focal new bone formation.” If that case indeed represented a tropical ulcer, could it be the  
23  
24 tibia of a slave infected in their native Africa and therefore not European in origin? Kendall et al  
25  
26 (2013) reported that five of 30 individuals (17%) from an East Smithfield, England cemetery were  
27  
28 not from the local area.  
29

30  
31 Attribution of the derivation of periosteal reaction has been controversial, and is often based  
32  
33 on speculation as to possible manifestations, rather than documented affected cases (e.g., Boel and  
34  
35 Ortner, 2011). Venous stasis has been repeatedly cited as a cause of periosteal reaction, although  
36  
37 documentation has proven elusive in the published record, and a shelf has not been reported  
38  
39 (Rothschild and Martin, 2006). Generalized periosteal reaction does not produce shelves. None  
40  
41 were seen among 300 cases of hypertrophic osteoarthropathy (Rothschild and Rothschild, 1998),  
42  
43 nor in hundreds of cases of treponemal disease (i.e., syphilis, yaws, bejel) (Hershkovitz et al., 1995;  
44  
45 Rothschild and Heathcote, 1993; Rothschild and Rothschild, 1994, 1995, 1996). Hypervitaminosis  
46  
47 A has been incorrectly suggested as a cause of periosteal reaction (e.g., Boel and Ortner, 2011). It  
48  
49 actually caused accentuated bone formation at entheses (Rothschild, Hershkovitz and Rothschild,  
50  
51 1995; Seawright, English and Gartner, 1970), not the shelves seen in tropical ulcer. Sickle cell  
52  
53 disease is associated with bone infarcts and chronic osteomyelitis, but not with the raised shelf  
54  
55 found in the tropical ulcer (Almeida and Roberts, 2005; Resnick, 2002). The Veld sore is a desert  
56  
57  
58  
59  
60

1 ulcer, which usually does not affect bone (Ngu, 1967). Tumors produce a sunburst pattern not seen  
2 here (Kolawole and Bohrer, 1970; Resnick, 2002). The so-called crural ulcers reported by Nemeč,  
3 Kovar and Kachnic (1965) are more extensive examples of osteomyelitis, expanding from the tibia  
4 to the fibula. Tropical ulcers differ from Buruli ulcers, caused by *Mycobacterium ulcerans*. They  
5 produce massive skin and subcutaneous tissue necrosis, but usually without bone alterations, and  
6 the shelf phenomenon has not been reported (Merritt et al., 2010).  
7  
8  
9  
10  
11  
12  
13

14 The osteoma-like shelf of tropical ulcers appears unique to that phenomenon and is  
15 demonstrated in this tibia from the area of Alba, Italy. The specimen site is dated to shortly after the  
16 end of the first Glacial, when the temperature increased (Guidi and Piperno, 1982) and the Tanaro  
17 River location evidenced a warm humid climate. Palynological examination documents the  
18 Neolithic as a period characterized by hot-warm conditions in the Alba area, wherein the tomb was  
19 located (Arobba and Caramiello, 1998). The humidity level might have been significant, owing to  
20 the Tanaro river neighbourhood and presence of residual hygrophilous plants (Arobba and  
21 Caramiello, 1998). Does the current case represent an example of a tropical ulcer in an immigrant  
22 who migrated to Italy from a tropical area, or was it a complication of a local environmental event?  
23 Whichever explanation is accepted, this appears to be the first documentation of a tropical ulcer in  
24 continental Europe, and perhaps in Europe itself.  
25  
26  
27  
28  
29  
30  
31  
32  
33  
34  
35  
36  
37  
38  
39  
40

#### 41 **Acknowledgment**

42 Appreciation is expressed to Dr. Marica Venturino Gambari (Soprintendenza Beni  
43 Archeologici Piemonte and Museo Antichità Egizie-Torino-Italy). This work is part of a more  
44 comprehensive study conducted in collaboration with Civico Museo Federico Eusebio in Alba, the  
45 Universities of Turin and Genoa, and the Archaeological Service of Piedmont. There are no  
46 conflicts of interest.  
47  
48  
49  
50  
51  
52  
53  
54  
55  
56

#### 57 **References**

- 1  
2  
3  
4 Adamson PB. 1949. Tropical ulcer in British Somaliland. *Journal of Tropical Medicine and*  
5  
6 *Hygiene* **52**: 68-75.  
7
- 8 Adriaans, B, Hay R, Lucas S and Robinson DC. 1987. Light and electron microscopic features of  
9  
10 tropical ulcer. *Journal of Clinical Pathology* **40**: 1231-1234.  
11
- 12 Almeida A and Roberts I. 2005. Bone involvement in sickle cell disease. *British Journal of*  
13  
14 *Haematology* **129**: 482-490.  
15
- 16 Arobba D and Caramiello R. 1998. Agricoltura e ambiente dal VI al I millennio a.C.: ricostruzione  
17  
18 su base palinologica. In *Archeologia in Piemonte vol.1 La preistoria*, Mercado L and  
19  
20 Venturino Gambari M (eds). Allemandi: Torino, Italy; 57-73.  
21
- 22 Boel LW and Ortner DJ. 2011. Skeletal manifestations of skin ulcer in the lower leg. *International*  
23  
24 *Journal of Osteoarchaeology* **23**: 303-309.  
25
- 26 Brown JS and Middlemiss JH. 1956. Bone changes in tropical ulcer. *British Journal of Radiology*  
27  
28 **29**: 213-217.  
29
- 30 Ennis JT, Gueri MC and Serjeany GR. 1972. Radiological changes associated with leg ulcers in the  
31  
32 tropics. *British Journal of Radiology* **45**: 8-14.  
33
- 34 Fulcheri E and Micheletti Cremasco M. 1998. Considerazioni Antropologiche e Paleopatologiche  
35  
36 sull'Uomo Pre-Protostorico del Piemonte. In *Archeologia in Piemonte vol.1 La preistoria*,  
37  
38 Mercado L and Venturino Gambari M (eds). Allemandi: Torino, Italy; 217-229.  
39
- 40 Guidi A and Piperno M. 1992. *Italia Preistorica*. Editori Laterza: Bari, Italy.  
41
- 42 Herskovitz I, Rothschild BM, Wish-Baratz S and Rothschild C. 1995. Natural variation and  
43  
44 differential diagnosis of skeletal changes in Bejel (endemic syphilis). In *The Origin of*  
45  
46 *Syphilis in Europe*, Dutour O, Palfi H, Berato J and Brun J-P (eds.). Centre Archeologique  
47  
48 du Var: Toulon, France; 81-87.  
49  
50  
51  
52  
53  
54  
55  
56  
57  
58  
59  
60

- 1 Kendall EJ, Montgomery J, Evans JA, Stantis C and Mueller V. 2013. Mobility, mortality and the  
2 Middle Ages: Identification of migrant individuals in a 14<sup>th</sup> century black death cemetery  
3 population. *American Journal of Physical Anthropology* **150**: 210-222.  
4  
5  
6  
7  
8 Kolawole TM and Bohrer SP. 1970. Ulcer osteoma bone response to tropical ulcer. *American*  
9  
10 *Journal of Roentgenology* **109**: 611-618.  
11  
12 MacDonald P. 2003. Tropical ulcers: A condition still hidden from the Western world. *Journal of*  
13  
14 *Wound Care* **12**: 85-90.  
15  
16  
17 Merlo F, Micheletti Cremasco M and Fulcheri E. 2003. I resti umani di epoca pre-protostorica  
18  
19 rinvenuti ad Alba in via Teodoro Bubbio: a. approfondimenti dello studio in relazione a  
20  
21 indicatori di stress ed evidenze paleopatologiche. *Alba Pompeia* **II**: 25-39.  
22  
23  
24 Merlo F, and Micheletti Cremasco M. 2004. Indicatori scheletrici di stress su reperti di epoca pre-  
25  
26 protostorica di Alba (CN). *Primo Convegno Nazionale degli Studenti di Antropologia,*  
27  
28 *Preistoria e Protostoria* Annali dell'Università di Ferrara. Nuova serie, Sez. Scienze della  
29  
30 Terra **11**: 97.  
31  
32  
33 Merritt RW, Walker ED, Small PL, Wallace JR, Johnson PD, Benbow ME and Boaky DA. 2010.  
34  
35 Ecology and transmission of Buruli ulcer disease: A systematic review. *PLoS Neglected*  
36  
37 *Tropical Diseases* **4 (12)**: e911.  
38  
39  
40 Micheletti Cremasco M, Merlo F, Venturino Gambari M and Chiarenza N. 2011. Approccio  
41  
42 multidisciplinare per l'interpretazione di una sepoltura preistorica di Alba (CN). *XIX*  
43  
44 *Congresso Nazionale Associazione Antropologica Italiana. 1961-2011. Cinquant'anni di*  
45  
46 *Congressi, passato, presente e futuro dell'Antropologia*: 33. Asti: Diffusione Immagine.  
47  
48  
49 Nemeč M, Kovar and Kachnic M. 1965. X-ray changes of the osteoarticular apparatus in ulcus  
50  
51 cruris. *Acta Chirurgicae et Traumatologiae Cechoslovaca* **32**: 254-261.  
52  
53  
54 Ngu A. 1967. Tropical ulcers. *British Medical Journal* **1**: 283-285.  
55  
56  
57 Resnick D. 2002. *Disorders of Bones and Joints*. Saunders: Philadelphia, Pennsylvania, USA.  
58  
59  
60 Roberts C and Manchester K. 2005. *The Archaeology of Disease*. 3<sup>rd</sup> Ed. Cornell University Press:

1 Ithaca-New York.

2  
3  
4 Rothschild BM and Martin LD. 2006. *Skeletal Impact of Disease*. New Mexico Museum of Natural  
5  
6 History Press: Albuquerque, New Mexico, USA.

7  
8 Rothschild BM and Heathcote G. 1993. Characterization of the skeletal manifestations of the  
9  
10 treponemal disease, Yaws, as a population phenomenon. *Clinical Infectious Diseases* **17**:  
11  
12 198-203.

13  
14 Rothschild BM, Hershkovitz I and Rothschild C. 1995. Origin of Yaws in Pleistocene East Africa:  
15  
16 *Homo erectus* KNM-ER 1808. *Nature* **378**:343-344.

17  
18 Rothschild C and Rothschild BM. 1994. Syphilis, Yaws and Bejel: Population distribution in North  
19  
20 America. *American Journal of Physical Anthropology* **94**: 174-175.

21  
22 Rothschild BM and Rothschild C. 1995. Treponemal disease revisited: Skeletal discriminators for  
23  
24 Yaws, Bejel, and venereal syphilis. *Clinical Infectious Diseases* **20**: 1402-1408.

25  
26 Rothschild BM and Rothschild C. 1996. From Poundbury to Spitalfields: 1400 year transition  
27  
28 from null state to syphilis. *American Journal of Physical Anthropology* **Suppl 22**: 204-205.

29  
30 Rothschild BM and Rothschild C. 1998. Recognition of hypertrophic osteoarthropathy in skeletal  
31  
32 remains. *Journal of Rheumatology* **25**: 2221-2227.

33  
34 Seawright AA, English PB and Gartner RJ. 1970. Hypervitaminosis A of the cat. *Advances in*  
35  
36 *Veterinary Science and Comparative Medicine* **14**: 1-27.

37  
38 Venturino Gambari M., Cerrato N, Fulcheri E, Giaretti M, GiomoF, Micheletti Cremasco M,  
39  
40 Ottomano C, Perotto A and Traversone B. 1999. Alba C.so Langhe e C.so Europa. Scavi  
41  
42 nell'area degli insediamenti pre-protostorici. *Quaderni della Soprintendenza Archeologica*  
43  
44 *del Piemonte* (Alessandria: Litografia Viscardi) **16**: 217-230.

45  
46 Venturino Gambari M, Chiarenza N, Merlo F, Fulcheri F and Micheletti Cremasco M. 2011a. La  
47  
48 tomba dell'età del Rame di Alba - corso Europa (residenza Papillon). *Quaderni della*  
49  
50 *Sovrintendenza Archeologica del Piemonte* (Alessandria: Litografia Viscardi) **26**: 24-33.

1  
2 Venturino Gambari M, Ferrero L, Micheletti Cremasco M and Rubat Borel F. 2011b. Alba, Corso  
3  
4 Piave. Nuova piscina comunale. Sepoltura dell'antica età del Bronzo e strutture d'abitato della  
5  
6 prima età del Ferro. *Quaderni della Soprintendenza Archeologica del Piemonte* (Alessandria:  
7  
8 Litografia Viscardi) **26**: 205-214.

9  
10 Zoppi U, Fulcheri F, Gambari FM, Hua Q, Lawson EM, Micheletti Cremasco M and Venturino  
11  
12 Gambari M. 2001. The Copper Age in Northern Italy. *Radiocarbon*. **43(2B)**: 1049-1056.  
13  
14  
15  
16  
17  
18  
19  
20  
21  
22  
23  
24  
25  
26  
27  
28  
29  
30  
31  
32  
33  
34  
35  
36  
37  
38  
39  
40  
41  
42  
43  
44  
45  
46  
47  
48  
49  
50  
51  
52  
53  
54  
55  
56  
57  
58  
59  
60

For Peer Review

1  
2  
3  
4  
5  
6  
7  
8  
9  
10  
11  
12  
13  
14  
15  
16  
17  
18  
19  
20  
21  
22  
23  
24  
25  
26  
27  
28  
29  
30  
31  
32  
33  
34  
35  
36  
37  
38  
39  
40  
41  
42  
43  
44  
45  
46  
47  
48  
49  
50  
51  
52  
53  
54  
55  
56  
57  
58  
59  
60

Figure legends:

Fig. 1. Location map of Papillon-Alba site in northern Italy.

Fig. 2. Papillon monumental tomb (Alba-Cuneo. Northern Italy): on the left of the image you can see the violation damage (south-west corner) (From: Venturino Gambari et al., 2011a photo C.O.R.A. Soc. Coop.).

Fig. 3. Tomb plan: in the center of the structure, there is the rectangular mortuary room with human remains (grey colour) with archaeological code number. The tibia AB\_PAP 14/36 is in the red circle.

Fig. 4. Alba Papillon -Right tibia (Specimen AB\_PAP 14/36): Antero-medial view.

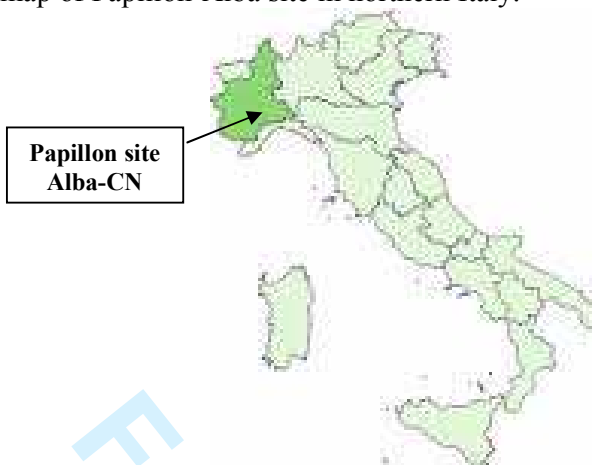
Fig. 5. Alba Papillon - Right tibia (Specimen AB\_PAP 14/36): Detail of the previous view.

Fig. 6. Alba Papillon - Right tibia (Specimen AB\_PAP 14/36): X-ray.

Fig. 7. Alba Papillon - Right tibia (Specimen AB\_PAP 14/36): X-ray: Detail of the previous view.

1  
2  
3  
4  
5  
6  
7  
8  
9  
10  
11  
12  
13  
14  
15  
16  
17  
18  
19  
20  
21  
22  
23  
24  
25  
26  
27  
28  
29  
30  
31  
32  
33  
34  
35  
36  
37  
38  
39  
40  
41  
42  
43  
44  
45  
46  
47  
48  
49  
50  
51  
52  
53  
54  
55  
56  
57  
58  
59  
60

Fig. 1. Location map of Papillon-Alba site in northern Italy.



For Peer Review

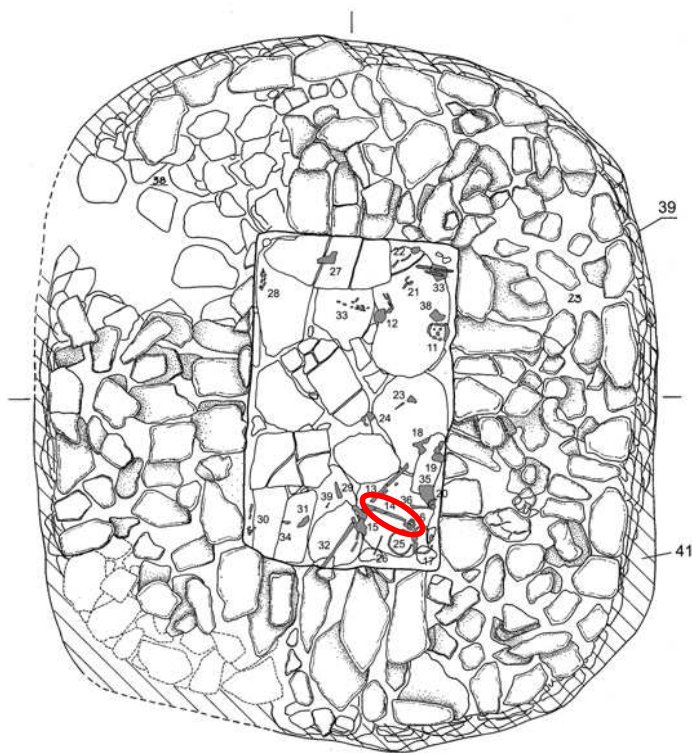


1  
2  
3  
4  
5 Fig. 2 Papillon monumental tomb (Alba-Cuneo. Northern Italy): on the left of the image you can  
6 see the violation damage (sud-west corner) (From: Venturino Gambari *et al.*, 2011a photo CO.R.A.  
7 Soc. Coop.).  
8



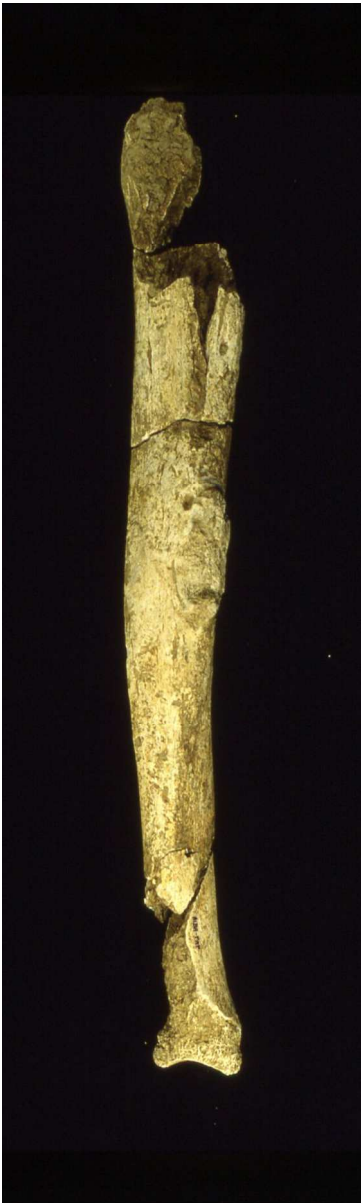Peer Review

Fig. 3. Tomb plan: in the center of the structure there is the rectangular mortuary room with human remains (grey colour) with archaeological code number. In the red circle the tibia AB\_PAP 14/36.



Review

1  
2  
3  
4  
5  
6  
7  
8  
9  
10  
11  
12  
13  
14  
15  
16  
17  
18  
19  
20  
21  
22  
23  
24  
25  
26  
27  
28  
29  
30  
31  
32  
33  
34  
35  
36  
37  
38  
39  
40  
41  
42  
43  
44  
45  
46  
47  
48  
49  
50  
51  
52  
53  
54  
55  
56  
57  
58  
59  
60



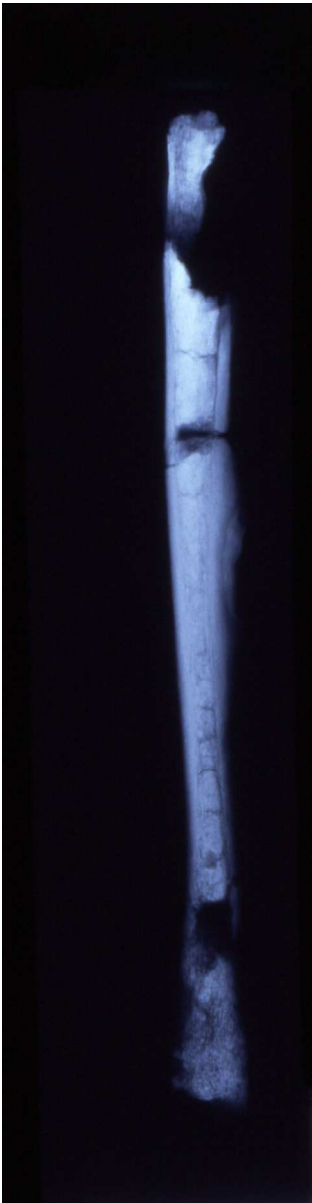Alba Papillon -Right tibia (Specimen AB\_PAP 14/36): Antero-medial view.  
39x131mm (600 x 600 DPI)

1  
2  
3  
4  
5  
6  
7  
8  
9  
10  
11  
12  
13  
14  
15  
16  
17  
18  
19  
20  
21  
22  
23  
24  
25  
26  
27  
28  
29  
30  
31  
32  
33  
34  
35  
36  
37  
38  
39  
40  
41  
42  
43  
44  
45  
46  
47  
48  
49  
50  
51  
52  
53  
54  
55  
56  
57  
58  
59  
60



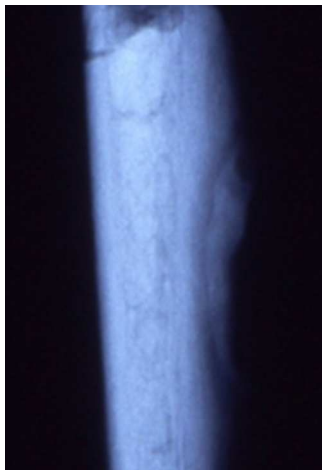Alba Papillon - Right tibia (Specimen AB\_PAP 14/36): Detail of the previous view.  
32x50mm (600 x 600 DPI)

1  
2  
3  
4  
5  
6  
7  
8  
9  
10  
11  
12  
13  
14  
15  
16  
17  
18  
19  
20  
21  
22  
23  
24  
25  
26  
27  
28  
29  
30  
31  
32  
33  
34  
35  
36  
37  
38  
39  
40  
41  
42  
43  
44  
45  
46  
47  
48  
49  
50  
51  
52  
53  
54  
55  
56  
57  
58  
59  
60



Alba Papillon - Right tibia (Specimen AB\_PAP 14/36): X-ray.  
36x141mm (600 x 600 DPI)

1  
2  
3  
4  
5  
6  
7  
8  
9  
10  
11  
12  
13  
14  
15  
16  
17  
18  
19  
20  
21  
22  
23  
24  
25  
26  
27  
28  
29  
30  
31  
32  
33  
34  
35  
36  
37  
38  
39  
40  
41  
42  
43  
44  
45  
46  
47  
48  
49  
50  
51  
52  
53  
54  
55  
56  
57  
58  
59  
60



Alba Papillon - Right tibia (Specimen AB\_PAP 14/36): X-ray: Detail of the previous view.

6x9mm (600 x 600 DPI)

Peer Review

Table 1. The 1  $\sigma$  and 2  $\sigma$  calibrated age ranges of the bone sample collected in Alba. The table also shows the C/N and  $\delta^{13}\text{C}$  values. Papillon. Radiometric Dating (ANSTO, Physics Division - Menai - Australia) Extracted from Venturino Gambari *et al.*, 2011a.

ANSTO code	C/N	$\delta^{13}\text{C}$ (PDB)	1 $\sigma$ cal age ranges		2 $\sigma$ cal age ranges		
			conventional age	relative calibrate age	relative calibrate age	relative probability	
OZE028	3.2	-21.3‰	4583 $\pm$ 62 BP	3499–3455 BC	21.2%	3517–3390 BC	25.6%
tibia				3378–3324 BC	29.6%	3389–3095 BC	74.4%
AB_PAP 14/36				3322–3314 BC	2.9%		
				3229–3172 BC	24.8%		
				3160–3116 BC	20.0%		
				3110–3104 BC	1.5%		

1  
2  
3  
4  
5  
6  
7  
8  
9  
10  
11  
12  
13  
14  
15  
16  
17  
18  
19  
20  
21  
22  
23  
24  
25  
26  
27  
28  
29  
30  
31  
32  
33  
34  
35  
36  
37  
38  
39  
40  
41  
42  
43  
44  
45  
46  
47  
48  
49

Table 2: Re-evaluation of Boel and Ortner’s 2001 report of possible tropical ulcers.

Curation/Locale	Dating	Elevated plaque	Bone excavation	Non-focal expansion	Generalized osteomyelitis	Increased density
True tropical ulcer	not applicable	Yes	No	No	No	Yes
American Civil War*						
Case 1	1860’s	No	No	Yes	No	No
Case 2	1860’s	No	No	No	Yes	No
Terry Collection**	Early 20th century	No	Yes	No	Yes	No
Huntington Collection**	Early 20th century	No	Yes****	No	No	No
Jordan	3300 BCE	Yes	No	No	Yes	No
Juhle, Maryland	1650	Yes	No	Yes***	No	No
Nordby, Denmark	Medieval					
Malmö, Sweden	Medieval	?	?	?	?	No

\* National Museum of health and Medicine, Walter Reed Army Medical Center, Washington, D.C., USA

\*\* Anthropology Department, Smithsonian Institution, Washington, DC, USA

\*\*\* Remodeled and bowed.

\*\*\*\*Sequestered with abscess.