

AperTO - Archivio Istituzionale Open Access dell'Università di Torino

Clinical outcome of 42 dogs with scapular tumors treated by scapulectomy: a Veterinary Society of Surgical Oncology (VSSO) retrospective study (1995-2010)

This is the author's manuscript

Original Citation:

Availability:

This version is available <http://hdl.handle.net/2318/142215> since

Published version:

DOI:10.1111/j.1532-950X.2013.12066.x

Terms of use:

Open Access

Anyone can freely access the full text of works made available as "Open Access". Works made available under a Creative Commons license can be used according to the terms and conditions of said license. Use of all other works requires consent of the right holder (author or publisher) if not exempted from copyright protection by the applicable law.

(Article begins on next page)



UNIVERSITÀ DEGLI STUDI DI TORINO

This is the accepted version of the following article: [Montinaro V., Boston SE, Buracco P., Culp WT, Romanelli G., Straw R, Ryan S. Clinical outcome of 42 dogs with scapular tumors treated by scapulectomy: a Veterinary Society of Surgical Oncology (VSSO) Retrospective Study (1995-2010). *Veterinary Surgery* 42:943-950, 2013. DOI:10.1111/j.1532-950X.2013.12066.x, PMID:24433298],

which has been published in final form at [Link to final article: <http://onlinelibrary.wiley.com/doi/10.1111/j.1532-950X.2013.12066.x/abstract;jsessionid=419D2CA6FD7F2D8ECD9F740A6DF81F3D.f02t01>]

Clinical Outcome of 42 Dogs With Scapular Tumors Treated by Scapulectomy: A Veterinary Society of Surgical Oncology (VSSO) Retrospective Study (1995-2010)

Vincenzo Montinaro¹, DVM, MRCVS, Sarah E. Boston¹, DVM, DVSc Diplomate ACVS, Paolo Buracco², DVM, Diplomate ECVS, William T.N. Culp³, VMD, Diplomate ACVS, Giorgio Romanelli⁴, DVM Diplomate ECVS, Rod Straw⁵, BVSc, Diplomate ACVS, and Stewart Ryan⁶, BVSc, MS, MACVSc, Diplomate ACVS

¹ Department for Clinical Studies, Ontario Veterinary College, University of Guelph, Guelph, Canada, ² Department of Animal Pathology, School of Veterinary Medicine, Grugliasco, Turin, Italy, ³ Department of Surgical and Radiological Sciences, School of Veterinary Medicine, University of California-Davis, Davis, CA, ⁴ Clinica Veterinaria Nerviano, Nerviano, Milan, Italy, ⁵ The Australian Animal Cancer Foundation, Brisbane Veterinary Specialist Centre, Brisbane, Australia and ⁶ Department Clinical Sciences, The Animal Cancer Center, Colorado State University, Fort Collins,

Objective: To report signalment, clinical signs, preoperative staging tests, histologic diagnosis, surgical, and oncologic outcomes including postoperative limb use, in dogs with scapular tumors treated by scapulectomy. **Study Design:** Retrospective case series **Animals:** Dogs (n = 42) with scapular tumors. **Methods:** Medical records (1995-2010) from 6 hospitals were searched for dogs with scapular tumors treated by scapulectomy. Data retrieved were: signalment, weight, percentage of scapula removed, histologic diagnosis, postoperative limb use, adjunctive therapy, disease free interval (DFI), and survival time (ST). Individual variables were modeled with a Cox proportional hazard model accounting for censoring to determine risk factors for decreased DFI and ST. For categorical variables, Kaplan-Meier survival plots as well as mean and median survival times (MSTs) were calculated. **Results:** Subtotal scapulectomy was performed in 18 dogs (42.9%). Osteosarcoma (OSA) was diagnosed in 27 dogs (64.3%). Limb use was evaluated immediately after surgery in 41 dogs. Information on limb use at other times (1, 2, 3, and >3 months) postoperatively was also available for some dogs and was good to excellent overall. Only adjunctive chemotherapy had a positive significant effect on DFI ($P = .00011$) and ST ($P = .0003$). **Conclusion:** Canine scapular tumors can be treated effectively by scapulectomy and limb use is fair to excellent for most dogs. OSA was the most common scapular tumor. Overall prognosis for scapular OSA is similar to appendicular OSA at other sites and use of adjunctive chemotherapy prolonged the overall DFI and MST.

Malignant tumors affecting the scapula are rare in dogs and affected dogs are often treated with forelimb amputation. Limb-sparing surgery is an alternative for tumors affecting the scapula in people, dogs and cats. In 1894, Syme reported scapulectomy for tumor removal in people with minimal complications and maintenance of a functional arm. Limb-sparing using endoprosthetic replacement of the scapula after wide resection of scapular tumors is a surgical technique that is also currently performed in people.⁵ The scapula can also be completely excised, maintaining limb function without an endoprosthesis or allograft replacement in both people and animals.² There are major differences in the structure and function of the shoulder joint in people and dogs, but it appears that both species tolerate this procedure as a method of limb salvage. In people, the shoulder is the third most common site for musculoskeletal neoplasia.⁶ Bone tumors of the shoulder joint in people occur in either the proximal aspect of the humerus, scapula, or clavicle in decreasing order of frequency, with soft tissue tumors being most commonly located in the deltoid or supraspinatus muscles.⁷ In 14 people, it was reported that resection of 80% of the scapula had only a modest effect on arm function. These authors also reported that subtotal scapulectomy provided an excellent functional result if all or part of the glenohumeral joint could be preserved.⁸ Scapulectomy is rarely performed in animals for tumors affecting the scapula, because most dogs

function well after limb amputation. If a mass can be removed with curative intent by scapulectomy, the technique advantage is that wide surgical excision can be achieved with preservation of limb function. There is a paucity of information on scapulectomy in dogs and cats with 4 reports collectively describing this procedure in 14 dogs and 2 cats.^{1-3,9} The surgical technique, described by Trout et al.,³ resulted in good to excellent postoperative limb function in 6/6, 4/5, 3/4, and 1/1 cases.^{1-3,9} Of the 14 dogs, 7 had partial, 6 subtotal, and 1 scapulectomy^{1-3,9}; histologic diagnoses were OSA (n = 5), chondrosarcoma (CSA; 3), hemangiosarcoma (HSA; 3), and soft tissue sarcoma (STS; 3).^{1-3,9} OSA is the most frequently diagnosed primary bone tumor in dogs, accounting for ~85% of skeletal tumors; >75% OSA affect long bones of the appendicular skeleton. 10 Hammer et al. reported 6 (13%) of 45 dogs with OSA of flat and irregular bones had scapular involvement.¹¹ OSA was the most frequently reported primary bone tumor of the scapula in dogs and cats that had scapulectomy.¹⁻³ CSA is the 2nd most common primary bone tumor of dogs.¹⁰ Of 16 scapulectomy procedures in dogs and cats, 3 were for CSA^{1-3,9} despite the scapula being a rare site of CSA.¹² Only 1 case of scapula CSA was identified in Waltman et al.'s 31 non-nasal CSAs¹³ and scapular tumors were excluded by Farese et al.¹⁴ in 25 canine appendicular CSA treated by amputation. Our purpose in this retrospective, multi-institutional Veterinary Society of Surgical Oncology (VSSO) study were: (1) to report signalment and outcome data from a relatively large number of dogs with tumors of the scapula that were treated with partial or total scapulectomy; (2) document presenting clinical signs, preoperative staging, histologic diagnosis, potential prognostic factors, and postoperative limb-use; and (3) define disease free interval (DFI) and survival time (ST). We postulated that scapulectomy can be performed with minimal complications and that it is an effective limb sparing alternative to amputation in dogs with tumors of the scapula.

MATERIALS AND METHODS

This study was initiated by requesting case submissions from VSSO members through the VSSO research committee and list-serve. Medical records (1995-2010) from contributing institutions were searched to identify dogs that had scapulectomy. Inclusion criteria were dogs with histopathologically confirmed tumors of the scapula treated by partial or total scapulectomy. Data retrieved were: sex, breed, age, weight, clinical signs, scapula affected, dates of presentation and surgery, pre- and postoperative serum alkaline phosphate concentrations, clinical staging, preoperative diagnostic tests, approximate percentage of scapula resected (partial, subtotal, or total scapulectomy), histopathologic diagnosis and surgical margin evaluation, postoperative surgical complications (acute <1 month; chronic >1 month), postoperative limb use, adjunctive therapy, whether or not physiotherapy was performed, date of detection of local recurrence or distant metastatic disease, and date and cause of death.

Partial scapulectomy was defined as removal of <75% of the scapula, subtotal scapulectomy as removal of >75% of the scapula, with preservation of the glenoid of the scapula, and total scapulectomy as removal of the entire scapula, including the glenoid. Case contributors were asked to mark the osteotomy or excision site on a diagram used for case accrual. From the diagram, the percentage of the scapula removed, was subjectively classified as 50%, 75%, or 100%. Histopathologic diagnosis was based on the original assessment by the attending pathologist at the time of specimen submission. A complete histologic margin of excision was defined as no neoplastic cells found <5mm from the surgical margins. Clean but close histologic margins were defined as neoplastic cells visible 2— 5mm from the surgical margins. Incomplete margins were defined as neoplastic cells within 2 mm of the surgical margins.

Postoperative limb use, based on subjective evaluation by case contributors, was categorized using a lameness scale¹⁵ as: poor (non-weight bearing lameness), fair (slight to moderate lameness but consistent

weight bearing), good (slight lameness only after extensive exercise), and excellent (normal limb function). Limb use was evaluated within 14 days, within 1, 2, and 3 months and >3 months postoperatively.

Oncologic outcome measures were: DFI and ST. DFI was defined as time from scapulectomy until date of first evidence of distant metastasis or local tumor recurrence. ST was time between scapulectomy and death. Cause of death was classified as either tumor-related or non-tumor related. Dogs with an unknown cause of death were presumed to have died from tumor-related causes. Dogs that died because of non-tumor related causes or were lost to follow up were censored for the survival analysis. Individual dog and surgical variables were modeled with a Cox proportional hazard model, accounting for censoring, to determine risk factors for DFI and ST. For categorical variables, Kaplan-Meier survival plots as well as mean and median STs were calculated. A Spearman correlation analysis was used to test for an association between body weight and limb use. ANOVA was used to determine if mean weights were significantly different between categories of limb use. An exact logistic regression test was used to evaluate the correlation between use of preoperative advanced imaging and completeness of surgical resection.

RESULTS

Signalment

Forty-two dogs (median age, 8.3 years [range, 1.5-13 years]; median weight, 34.8kg [range, 10.5-57.7 kg]) met the inclusion criteria (Table S1). There were 24 males (15 intact, 9 castrated) and 18 females (9 intact, 9 spayed). Affected breeds were: Labrador retrievers (n = 7); Rottweiler (5); 3 each of golden retrievers, border collies and mixed breed dogs; 2 each of boxers, German shepherd dogs, great Pyrenees and malamutes; and 1 each of the giant schnauzer, miniature schnauzer, Doberman, bull mastiff, basset hound, old English sheepdog, beagle, standard poodle, English setter, Australian heeler, Tibetan terrier, Airedale, and great Dane.

Presenting Complaint

Lameness (36 dogs; 86%) was the most common presenting complaint. A visible scapular mass or swelling was observed in 14 dogs (33%) and both lameness and a swelling or mass was noted in 8 dogs (19%). There was no difference in laterality of the scapula affected with 23 (57.5%) tumors in the left scapula and 17 (42.5%) in the right.

Concurrent disease was present in 11 dogs; 8 had concurrent degenerative joint disease and 3 another neoplastic disease, including oral fibrosarcoma (FSA) incompletely removed and a mammary tumor with lymphatic infiltration (dog 8). Dog 30 had a cutaneous basosquamous carcinoma with metastasis to the draining lymph node removed and dog 35 had an oral melanoma of the lower lip, which was removed 1 year earlier and had adjuvant therapy with a melanoma vaccine.

Preoperative Diagnostic Tests

Preoperative imaging for clinical staging purposes included: 3 projection thoracic radiographs (n = 39), long bone survey radiographs (11) and whole body nuclear scintigraphic bone scan (13). Thoracic radiographs were normal in 37 dogs; 2 dogs (5%) (dogs 6 and 36) had pulmonary metastatic disease evident on thoracic radiographs. No additional bone lesions were identified on long bone survey radiographs. Dog 22 had increased radiopharmaceutical uptake in the ipsilateral distal radius; bone metastasis was ruled out on subsequent evaluation. On scintigraphic examination 175 days after scapulectomy, there

was no increased uptake in the ipsilateral radius. Advanced imaging for local staging and surgical planning was performed in 18 dogs; 16 had computed tomography (CT) scans performed and 2 had magnetic resonance imaging (MRI) studies. Absence of an advanced imaging study preoperatively did not increase the risk of incomplete excision. (P = .64).

Cytologic examination of preoperative fine needle aspiration of the mass in 11 dogs identified sarcoma (n = 6), OSA (4) and HSA (1). Preoperative incisional biopsy for histopathology was performed in 27 dogs: OSA (n = 15), CSA (4), FSA (3), STS (2), HSA (1), histiocytic sarcoma (HS; 1), and nondiagnostic (1).

Scapulectomy

Partial scapulectomy was performed in 24 dogs, subtotal scapulectomy (with preservation of the glenoid, Fig 1) in 13, and total scapulectomy (entire scapula removed including glenoid) in 5 dogs (dogs 3, 4, 25, 26, and 28). In 2 total scapulectomy dogs, en bloc resection of the humeral head (dog 28, Fig 2), and a rib (dog 29), respectively, were performed at the time of surgery. The percentage of scapula removed was <50% in 8 dogs, 50-75% in 16 dogs, and >75% in 18 dogs.

Adjuvant Therapy

Thirty-one (73.8%) dogs were administered chemotherapy. Protocols included single agent treatment with doxorubicin, epirubicin or a platinum agent, and alternating agents with doxorubicin or epirubicin and a platinum agent. Nineteen (61.3%) dogs had a complete treatment course of 4-6 cycles of chemotherapy (Table S1). Of dogs administered chemotherapy, 24 had OSA, 3 STS (grade II STS, undifferentiated sarcoma and FSA), and 1 each had CSA, HSA, HS, and skeletal angiomatosis. Dog 24 had metronomic chemotherapy after full course chemotherapy and the chemotherapy protocol used for dog 33 was not recorded. Additional medical treatments were reported. Four dogs were administered nonsteroidal anti-inflammatory drugs (NSAIDs) and 2 dogs (dogs 33 and 36) had radiation therapy. Dog 33 had an incomplete FSA removal and had full course fractionated radiotherapy (3 Gy x 19) started 3 weeks after surgery. Dog 36 had palliative radiotherapy (8 Gy x 2 on consecutive days) before surgery.

Surgical Outcome

Postoperative complications included surgical site complications, impaired limb use, and local recurrence. Fourteen (35%) of 40 dogs had acute complications; 7 dogs developed seroma. A closed-suction drain was placed in dog 11 for 5 days. Dog 34 had suture breakdown between the scapula and the serratus ventralis muscle remnant. Six dogs were very lame with intermittent weight bearing within the first 48 hours after surgery. Six (15%) of 39 dogs developed chronic complications. In 2 dogs (dogs 23 and 39) seroma occurred at the surgical site > 1 month postoperatively. Dog 29 (grade II STS and en bloc rib resection) developed pneumothorax 30 days after surgery. Three dogs were lame 1 month postoperatively; dog 8 had a CT scan twice within 1 month because of lameness. Local recurrence was suspected because of evidence of osteolysis at the site of the scapular osteotomy on CT scan. This dog had an incisional biopsy performed, but recurrence was not confirmed histologically and the dog was lost to follow up 313 days after initial surgery.

Limb Use

Of 41 dogs with limb use information within 14 days of surgery, 15 were considered to have poor limb use, 17 fair; 7 good; and 2 excellent limb use. Forty-one dogs were examined during the 1st month postoperatively. Limb use was poor (n = 8), fair (17), good (12), and excellent (4). Information regarding

limb use up to 2 months postoperatively was available for 14 dogs and limb use was described as poor (1), fair (3), good (4), and excellent (6) in this group of dogs. Information regarding limb use up to 3 months postsurgery was available for 6 dogs and was good in 4 dogs and excellent in 2 dogs. In 9 dogs, information was available regarding limb use >3months (4-10 months) postoperatively and was good in 1 dog and excellent in 8 dogs (Table 1). No correlation between % scapula removed and limb use at 14 days and 1 month was identified. A significant negative association (Spearman correlation analysis) was found between increasing body weight and postoperative limb use in the first 14 days ($P = .0045$; Fig 3) Eight dogs (dogs 14, 23, 25, 32, 33, 34, 40, and 42) had postoperative physiotherapy once weekly and all had subjective improvement in limb use during physiotherapy except for dog 25 that had good use of the limb immediately after surgery and did not show additional signs of improvement during physiotherapy.

Follow up and evaluation was not standardized and was based on the clinical evaluation of each dog. Fifty percent of the dogs with poor limb use at 1 month had improvement in limb use at subsequent rechecks with 2 having good limb use and 2 excellent limb use. The follow up time for the other dogs that had poor limb use ranged from 60 to 1195 days. Although information on ST was available for these dogs, we did not always have information on limb use. Ten of 17 dogs with fair limb use during the 1st month had improvement in limb at subsequent reevaluations; 5 had good limb use and 5 excellent limb use.

Histologic Outcome

Forty-one scapulae were examined; 27 had OSA, 7 STS, 4 CSA, 2 HSA and 1 HS, and 1 skeletal angiomatosis. Of STS cases, 4 were not further subclassified but were diagnosed as grade II STS (2), grade I STS (1) and undifferentiated STS (1), and 3 were classified as FSA. Dog 38 had CSA diagnosed on preoperative incisional biopsy, but the operative specimen was lost. Of 34 dogs that had histologic margin evaluation, 28 (82.4%) had complete surgical margins and 6 (17.6%) had incomplete surgical margins (dogs 3, 8, 17, 24, and 33).

Oncologic Outcome

Local tumor recurrence was reported in 2 dogs and suspected in 1 dog. Dog 28 had FSA and complete margins, and for dog 38, the preoperative biopsy was consistent with CSA, but there was no final histopathology report with margin assessment. In dog 8, there was suspected local recurrence at 4 months. This dog developed lameness and a painful mass was found on palpation of the previous surgical site. Partial scapulectomy was used to remove a fibroblastic OSA initially; however, the margins were incomplete. Revision of a previous maxillectomy for an incompletely excised oral FSA was also performed at the time of partial scapulectomy. Postoperative CT scan of the affected site was performed at 4 and 5 months. The 4 month CT scan had lysis of the scapula, 0.5 cm from to the scapulectomy osteotomy site. One month later, there was more periosteal proliferation of the remaining scapula without bone lysis and an open incisional biopsy revealed regenerative hematopoiesis. Further diagnostic work up of this lesion was not performed. This dog was lost to follow up 313 days after scapulectomy.

Follow-up thoracic radiographs were available at various times for 30 (71.4%) dogs. Pulmonary metastasis was diagnosed radiographically in 20 (66.6%); 16 had OSA, 2 CSA (dogs 35 and 38), 1 FSA (dog 30), and 1 grade II STS (dog 32). In 3 of 20 dogs with lung metastasis (dogs 20, 22 with OSA, and dog 30 with FSA), bone metastasis was also found as an incidental radiographic finding (dogs 20 and 30) and on whole body nuclear scintigraphy (dog 22; Table S1). Dog 25 with lung and bone metastasis noted on chest radiographs and total body scintigraphy, had abdominal ultrasonography and splenic and hepatic masses consistent with metastatic OSA confirmed by ultrasound guided fine needle aspiration and cytology. In 3 of these 4 dogs (dogs 20, 22, and 25) a whole body scan was performed preoperatively. In 1 dog, (dog 33, with FSA) a neoplastic pleural effusion on cytology and a mediastinal mass were

found. Several biopsies were taken from the mass thoracoscopically and they were compatible with the primary tumor. In dog 41 with HS of the scapula, cytologically confirmed metastasis developed in both the skin and spleen. Dog 14 with OSA developed bone metastasis involving the spinous process of C5 radiographically (Table S1).

Overall DFI was 204 days (range, 107-245 days) and MST was 246 days (range, 177-394 days). Nineteen dogs died from tumor related causes. Twenty-three dogs were censored for survival analysis; 11 dogs were lost to follow up, 3 dogs were still alive at time of writing; 4 dogs died for unknown reasons; and 5 from unrelated causes. One of these dogs (dog 4) had hemoabdomen but necropsy was not performed and dog 2 was euthanized because of hypertrophic cardiomyopathy and caval thrombus.

In univariate analysis, age, sex, weight, presenting complaint, lameness duration before surgery, limb involved (right and left), % scapula removed, ALP concentration, histopathologic margins and diagnosis were not significantly associated with DFI or median ST. ST was significantly positively associated with administration of chemotherapy ($P = .0003$, HR = 5.45; 95%CI: 2.2, 13.5) with a median ST of 269 days (range, 232-919 days) in dogs that were administered chemotherapy compared with 107 days (range, 49-122 days) for those that did not. DFI was also significantly and favorably associated with administration of adjunctive chemotherapy ($P = .0011$, HR = 38.2; 95%CI: 4.2, 339.6) with dogs that had chemotherapy having median DFI of 211 days (range, 139-366 days) compared with 52 days (range, 39-107 days) in dogs that did not.

DFI and median ST in dogs diagnosed with scapula OSA were 210 days (range, 118-245 days) and 246 days (range, 177-651 days), respectively. When dogs with OSA were evaluated as a group, administration of chemotherapy did not have a statistically significant positive effect on DFI or median ST. A positive effect on survival with chemotherapy administration was suggested, as this comparison approached significance. ($P = .056$, HR = 16.183). In dogs with STS, DFI was 366 days (range, 107-366 days) and ST was 412.5 days (range, 107-2342). Dogs with CSA had a DFI of 54.5 days (range, 46-63 days) and the median ST was not reached but the mean ST time was 108 days (Table 2).

DISCUSSION

We found that the signalment of dogs was consistent with previous reports of dogs with primary bone tumors. Affected dogs were middle-aged to older, large breed dogs of various breeds. The most common presenting complaints were lameness (86%), swelling in the scapular region (33%) or both lameness and swelling. Based on this finding, we recommend that every orthopedic examination should include careful palpation of the scapula to ensure that this relatively rare diagnosis is not missed. In most (81%) dogs, >50% of the scapula was removed, suggesting that a relatively large amount of the scapula is affected before diagnosis. With the tumor types in our dogs, 3 cm margins are advisable to achieve complete margins of excision, so even a small lesion can result in removal of half of the scapula or more, depending on the size of the dog. The % scapula removed was not associated with limb use postoperatively or at 1 month after surgery. Further, the % scapula removed was not associated with DFI or ST. Five dogs had a total scapulectomy and 1 of these involved en bloc resection of the humeral head. All of these dogs had a fair limb use within 2 weeks, improving to good use within 2 months in 3 dogs (dogs 3, 4, and 28), suggesting that even with radical resection, this technique can result in a functional limb.

Adjunctive chemotherapy was positively prognostic for both DFI and ST. Dogs treated with adjunctive chemotherapy had a median ST of 269 (range, 232-919) days, compared with 107 (range, 49-122) days in dogs that did not ($P = .0003$; HR=5.4; 95%CI: 2.2, 13.5). Addition of chemotherapy to the treatment protocol was also significantly associated with an increased DFI (211 days) compared with 52 days for dogs that did not ($P = .00011$ HR = 38.2; 95%CI: 4.2, 339.7). Although there may be some selection bias involved because owners willing to treat with chemotherapy may promote a longer treatment course before euthanasia, the significant survival advantage

afforded by chemotherapy has been documented previously in canine appendicular OSA, and our findings confirm this. For scapular OSA, and other scapular tumors with metastatic potential, adjunctive treatment with chemotherapy appears to be an appropriate recommendation. When OSA dogs alone were evaluated, this positive effect on prognosis approached, but did not reach statistical significance ($P = .056$); however, given this trend and current recommendations for treatment of OSA, adjunctive chemotherapy is recommended for treatment of dogs with scapular OSA.

In dogs monitored for metastasis, 67% developed pulmonary metastasis, reflecting the high proportion of OSA in these dogs. It appears from these findings that scapular OSA has similar behavior to appendicular OSA at other sites. Regular monitoring of these dogs with thoracic radiographs is recommended. A dog with CSA had lungs metastasis at the time of diagnosis and this dog had a long ST after surgery and chemotherapy. Overall DFI in our study was 204 days and overall ST was 246 days. Again, the OSA cases had a major effect on our results, as the DFI and median ST of dogs with OSA in was 210 days (range, 118-245 days) and 246 days (range, 77-651 days), respectively. This is similar to the DFI and MST that would be expected after chemotherapy of appendicular OSA at other locations. ¹

Preoperative incisional biopsy performed in 27 dogs had high diagnostic yield (26 dogs) and results from incisional biopsy were consistent with eventual diagnosis when the entire mass was submitted. In dog 29, the preoperative open incisional biopsy was not diagnostic. As most primary bone tumors require a wide resection for curative intent treatment, regardless of histologic diagnosis, the decision to biopsy is somewhat clinician dependent. Care must be taken during biopsy to ensure that the biopsy tract can be entirely removed with the definitive resection.

Preoperative cytologic examination of fine needle aspirates was performed in 11 dogs (26%) with high yield; results were consistent with the ultimate diagnosis in all cases. Cytology has been shown to be a good test for evaluating appendicular bone lesions using fine needle aspiration, with a reported diagnostic accuracy of 71% overall and 92% when a neoplastic process was identified.¹⁸ Ultrasound-guided fine needle aspirate for bone lesions has also been reported to allow recognition of a break in the bone cortex for sampling, with a diagnostic sample obtained in 32/36 cases in 1 study.¹⁹ Fine needle aspirate for cytology could be considered as a first diagnostic step for scapular tumors, because it may abrogate the need for incisional biopsy, thus contributing to lower patient morbidity, decreased cost, and faster time for results.

Distribution of histologic diagnoses (63.3% OSA, 16.7% STS, 9.5% CSA, and 9.5% other tumors) was consistent with previous reports. OSA is the most common primary tumor in dogs, so this finding is not surprising because we focused on primary tumors of the scapula. It was interesting to note that STS (7 dogs), and not CSA (4 dogs) was the 2nd most common primary tumor of bone in our dogs; however, given the low numbers of dogs in each group, both should be considered as differential diagnoses for non-OSA scapular tumors of dogs. The STS group can be further divided into subtypes: 3 FSA, 2 grade II STS, 1 grade I STS, and 1 undifferentiated sarcoma. It is uncertain if these were primary STSs of bone, or if they were STSs that arose adjacent to the scapula with bone invasion; however, STS should be considered as a differential diagnosis in dogs with scapular tumors.

Histologic margins were considered complete in 82.4% of dogs. This outcome is good overall, but because of the high association between complete margins and a positive outcome for DFI and ST reported in other studies for OSA, STS and CSA, a higher rate of complete histologic margins should be strived for. In evaluating rib tumors treated with chest wall resection in dogs, both Liptak et al.²⁰ and Pirkey-Ehrhart et al. ²¹ reported that the margins of excision had a significant effect on patient survival. We did not find this effect, but this may be from type II error because of small cases number and low statistical power. Use of advanced imaging for preoperative surgical planning may improve the chances of achieving complete margins, as well as adhering strictly to the principles of surgical oncology and wide excision. In our study, 18 dogs had preoperative 3D imaging with either CT or MRI. This relatively low rate may reflect the 15-year period of case accrual. We evaluated the effect of advanced imaging

on the ability to achieve complete margins of excision and did not find a significant effect. Although not statistically significant, we nevertheless recommend use of advanced imaging for preoperative planning to define tumor margins and improve the likelihood of obtaining complete surgical margins at initial surgery.

The complication rate after scapulectomy was low. Acute complications included seroma (7 dogs) and an incisional breakdown at the level of the serratus ventralis. Scapulectomy will cause instability and increased motion of the proximal aspect of the limb because of removal of the superficial muscles (omotraversarius, trapezius, deltoideus, supraspinatus, infraspinatus) and the deeper muscles (rhomboides, serratus ventralis, subscapularis) that are disrupted in the resection. This surgical site should be reconstructed thoroughly, suturing cut edges of the serratus ventralis and rhomboides to the proximal edge of the subscapularis muscle and suturing the dorsal borders of the remaining infraspinatus and supraspinatus muscles to the insertion of the trapezius muscle. The omotraversarius and deltoideus muscles should be apposed when possible.² Careful soft tissue reconstruction will decrease both dead space and motion and may help decrease seroma formation. Cold compressive therapy, strict rest, and bandaging of the surgical site may help prevent acute complications. ²

Chronic complications included seroma (2 dogs), local recurrence (2 confirmed, 1 suspected), and pneumothorax in 1 dog that had a rib removed. The seromas were considered minor complications. Pneumothorax was likely associated with the en bloc resection of the rib and not the scapulectomy procedure per se. Local recurrence is a serious chronic complication. Overall, the complication rate was low, with seroma being the most common acute and chronic complication reported.

Local recurrence was documented in 2 dogs and suspected in 1 dog. In cases of confirmed recurrence, 1 dog had histologically complete margins after removal of a STS (FSA). The other dog had CSA on incisional biopsy, but final histopathology was not available. It is not clear from the record, but it appears that the scapula was submitted for histopathology postoperatively but the sample was lost. This case highlights the need to submit the entire sample after definitive resection, even when a preoperative histologic diagnosis has been obtained. Histology on the entire surgical specimen provides the definitive diagnosis, tumor grade, and an assessment of the surgical margins. The 3rd dog had OSA and incomplete histologic margins. This dog had lameness and swelling at the scapulectomy site. Repeat CT scan was consistent with recurrence, but the biopsy failed to confirm recurrent disease. A repeat biopsy would have been indicated, but was not performed.

Early postoperative (within 2 weeks) limb function was variable, but typically poor to fair immediately after surgery, with improvement to fair or good by 1 month. For dogs with longer term assessment, further improvement occurred in half of the dogs with poor limb use at 1 month and 10/17 of the dogs with fair limb use at 1 month. Inconsistent follow up information and the subjectivity of limb use evaluation are acknowledged as study limitations. A prospective study to evaluate limb use after scapulectomy with a longer follow up period and objective, standardized evaluation of limb use, such as force plate analysis, would help to determine limb use more accurately.

It is likely that after postoperative pain and swelling has decreased, these dogs require time to improve their strength and coordination. Physiotherapy may play a role in improving limb function after scapulectomy. Although only 8 dogs had physiotherapy, we found that the dogs that had physiotherapy had overall good limb function (3 fair, 3 good, and 2 excellent limb use). When limb use postoperatively and 1 month after surgery was assessed, there was a significant association of decreased limb use with increasing weight, which confirms our clinical impression that larger dogs will have a longer recovery after scapulectomy. It is likely, however, that as dogs increase in weight, they will be less tolerant of amputation, so this finding should not deter clinicians from recommending scapulectomy in large dogs.

Many (74%) dogs were administered adjunctive chemo-therapy, likely reflecting the high proportion of dogs with OSA (24/27). Of the 4 dogs with CSA, 1 received chemotherapy. Although earlier reports have suggested that CSA

has a low metastatic rate, a recent VSSO retrospective study evaluating canine appendicular CSA showed that 28% of dogs had metastatic disease and that histologic grade was predictive of metastasis and survival. 14A 50% metastasis rate was reported for grade III CSA.¹⁴ In people, grading CSA is one of the most important prognostic factors, with a reported metastasis rate of 71% for grade III CSA.²⁴ A grading scale adapted from a previous human CSA grading scale, used by Farese et al., was taken in consideration in only 1 CSA case, which was diagnosed as grade III CSA. This dog (dog 35) developed pulmonary metastasis. Because of the small number of our dogs with CSA, it is possible that this is not representative of the behavior of scapular CSA

Our study has several limitations inherent to retrospective studies. Inconsistencies in follow up and treatment protocols existed. These limitations include: a nonstandardized chemo-therapeutic protocol, lack of randomization of the dogs into treatment group, and inconsistencies with case work-up and staging and the number of non-OSA cases. Ideally, all the histopathologic samples would have been reviewed by a single pathologist and necropsy would have been performed on all dogs. It is possible that with a single pathologist review, some of the CSA cases would have been reclassified as OSA and vice versa. We did not evaluate or report the surgical technique performed in each dog for stabilizing the remaining part of the scapula musculature and chest wall, as this was considered beyond the scope of our study.

We concluded that scapulectomy is a safe, well-tolerated limb sparing procedure with a low complication rate. Limb use was fair to excellent for most dogs and, although long-term follow up of limb use was not available in all dogs, it appears that limb use improves over time. Increasing body weight is correlated with decreased limb use in the early postoperative period. The most common scapular tumor was OSA, followed by STS, and CSA. Primarily large breed dogs were affected, which is consistent with other locations for appendicular OSA and CSA. As is expected with OSA at other sites, the addition of adjunctive chemotherapy significantly improved the DFI and MST.

SUPPORTING INFORMATION

Additional supporting information may be found in the online version of this article at the publisher's web-site.

ACKNOWLEDGMENTS

We thank Veterinary Society of Surgical Oncology (VSSO) members support for this study and especially Drs. Julius Liptak, Maura O'Brien, Noel Fitzpatrick, Sarah Girling and Caleb Hudson and Nicholas Woo for case submission. We thank Gabrielle Monteith for her assistance with statistical analysis. We would also like to thank Dr. Stephen Withrow for his gentle encouragement of VSSO members for case accrual.

DISCLOSURE

The authors report no financial or other conflicts related to this report.

REFERENCES

1. Norton C, Drenen CM, Emms SG: Subtotal scapulectomy as the treatment for scapular tumour in the dog: a report of six cases. *Aust Vet J* 2006;84:364-366.
2. Trout NJ, Pavletic MM, Kraus KH: Partial scapulectomy for management of sarcomas in three dogs and two cats. *J Am Vet Med Assoc* 1995;207:585-587.
3. Kirpensteijn J, Straw RC, Pardo AD, et al: Partial and total scapulectomy in the dog. *J Am Anim Hosp Assoc* 1994;30:313-319.
4. Syme J: *Excision of the scapula*. Edinburgh, Scotland, Edmonston & Douglas, 1864, pp 11-35.
5. Villalobos CE, Hayden BL, Silverman A, et al: Limb-sparing resection of the scapula and reconstruction with constrained total scapula prosthesis: a case of multicentric epithelioid hemangioendothelioma involving the scapula and surrounding soft tissues. *Ann Surg Oncol* 2009;16:2321-2322.
6. Enneking WF: *Musculoskeletal tumor surgery*. Vol. 1. New York, NY, Churchill Livingstone, 1983, pp 355-410.
7. Creighton JJ Jr, Peimer CA, Mindell ER, et al: Primary malignant tumors of the upper extremity: retrospective analysis of 126 cases. *J Hand Surg Am* 1985;10:805-814.
8. Gibbons CLMH, Bell RS, Wundt JS, et al: Function after subtotal scapulectomy for neoplasm of bone and soft tissue. *J Bone Joint Surg Br* 1998;80:38-42.
9. Erdem V, Pead MJ: Haemangio sarcoma of the scapula in three dogs. *J Small Anim Pract* 2000;41:461-464.
10. Dernell WS, Ehrhart NP, Straw RC, et al: Tumors of the skeletal system. in: Withrow SJ, Vail DM (eds): *Withrow & MacEwen's small animal clinical oncology*. (ed4). St Louis, MO, Saunders, 2007, pp 540-582.
11. Hammer AS, Weeren FR, Weisbrode SE, et al: Prognostic factors in dogs with osteosarcoma of the flat and irregular bones. *J Am Animal Hospital Assoc* 1995;31:321-326.
12. Brodey RS, Misdorp W, Riser WH, et al: Canine skeletal chondrosarcoma a clinical pathology study of 35 cases. *J Am Vet Medical Assoc* 1974;165:68-78.
13. Waltman SS, Seguin B, Cooper B J, et al: Clinical outcome of non- nasal chondrosarcoma in dogs: 31 cases (1986-2003). *Vet Surg* 2007;36:266-271.
13. Farese JP, Kirpensteijn J, Kik M, et al: Biologic behavior and clinical outcome of 25 dogs with canine appendicular chondrosarcoma treated by amputation: a Veterinary Society of Surgical Oncology Retrospective Study. *Vet Surg* 2009;38:914-919.
14. Fox SM, Bray JC, Guerin SR, et al: Antebrachial deformities in the dog: treatment with external fixation. *J Small Anim Pract* 1995;36:315-320.
15. Bacon NJ, Ehrhart NP, Dernell WS, et al: Use of alternating administration of carboplatin and doxorubicin in dogs with microscopic metastases after amputation for appendicular osteosarcoma: 50 cases (1999-2006). *J Am Vet Med Assoc* 2008;232:1504-1510.
16. Kent MS, Strom A, London CA, et al: Alternating carboplatin and doxorubicin as adjunctive chemotherapy to amputation or limb-sparing surgery in the treatment of appendicular osteosarcoma in dogs. *J Vet Intern Med* 2004;18:540-544.
17. Berzina I, Sharkey LC, Matise I, et al: Correlation between cytologic and histopathologic diagnoses of bone lesions in dogs: a study of the diagnostic accuracy of bone cytology. *Vet Clin Pathol* 2008;37:332-338.
18. Britt T, Clifford C, Barger A, et al: Diagnosing appendicular osteosarcoma with ultrasound-guided fine-needle aspiration: 36 cases. *J Small Anim Pract* 2007;48:145-150.
19. Liptak JM, Kamstock DA, Dernell WS, et al: Oncologic outcome after curative-intent treatment in 39 dogs with primary chest wall tumors (1992-2005). *Vet Surg* 2008;37:488-496.
20. Pirkey-Ehrhart N, Withrow SJ, Straw RC et al: Primary ribs tumors in 54 dogs. *J Am Anim Hosp Assoc* 1995;31:65-69.
21. Drygas KA, McClure SR, Goring RL, et al: Effect of cold compression therapy on postoperative pain, swelling, range of motion, and lameness after tibial plateau leveling osteotomy in dogs. *J Am Vet Medical Assoc* 2011;238:1284-1291.
22. Rexing J, Dunning D, Siegel AM, et al: Effects of cold compression, bandaging, and microcurrent electrical therapy after cranial cruciate ligament repair in dogs. *Vet Surg* 2010;39:54-58.
23. Evans HL, Ayala AG, Romsdahl MM: Prognostic factors in chondrosarcoma of bone: a clinical pathological analysis with emphasis on histologic grading. *Cancer* 1977;40:818-831.

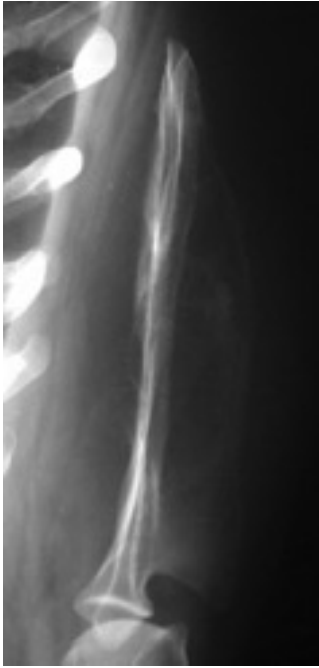

Figure 1 Caudocranial projection of the left scapula from case 41 ; note an osteolytic expansile lesion with amorphous periosteal reaction involving the medial surface and the scapular spine with soft tissue swelling around. A subtotal scapulectomy was performed.

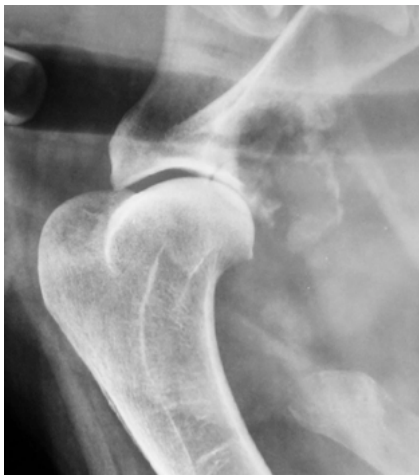

Figure 2 Lateral radiographic projection of the scapulohumeral joint from dog 28 with scapular fibrosarcoma. Note lytic changes extending from the distal caudal aspect of the scapula to the glenoid cavity. Total scapulectomy with partial humeral head resection performed.

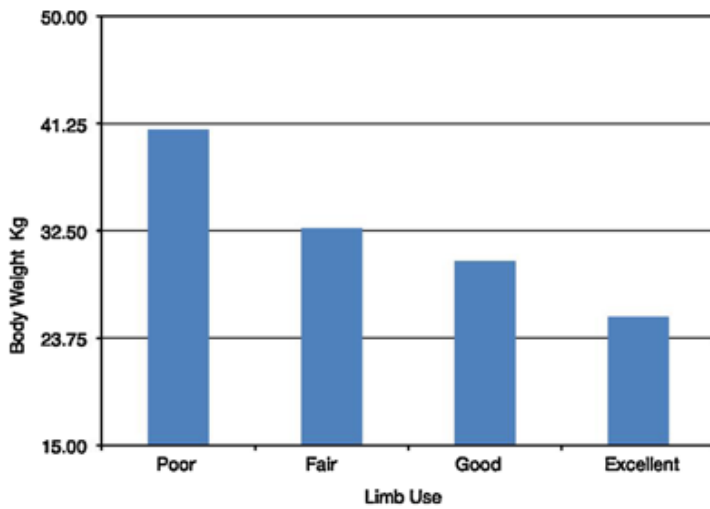


Figure 3 Postoperative limb use at 2 weeks compared to body weight.

Table 1 Summary of Postoperative Limb Use for 42 Dogs With Scapular Tumors after Scapulectomy

Limb Use	Postoperative Time				
	<2 Weeks	<1 Month	<2 Months	<3 Months	>3 Months
Poor	15 (37%)	8 (20%)	1 (7%)		
Fair	17 (41%)	17 (41%)	3 (21%)		
Good	7 (17%)	12 (29%)	4 (29%)	4 (67%)	1 (11%)
Excellent	2 (5%)	4 (10%)	6 (43%)	2 (33%)	8 (89%)
Dogs evaluated	41	41	14	6	9

Table 2 Overall Disease Free Interval (DFI; Days) and Median Survival Time (MST; Days) for the More Representative Scapular Tumor Types in 42 Dogs With Scapular Tumors Treated by Scapulectomy

	Overall	OSA	STS	CSA
Number of dogs	42	27	7	4
DFI	204 (107–245)	210 (118–245)	366 (107–366)	54.5 (46–63)
MST	246 (177–394)	246 (177–651)	412.5 (107–2342)	Not reached

OSA, osteosarcoma; STS, soft tissue sarcoma; CSA, chondrosarcoma.