Eruptive Dermal Clear Cell Desmoplastic Mesenchymal Tumors with Myofibroblastic Differentiation in a Young Boy.

J Cutan Pathol 2014; 41: 123–133. 2013

Published by John Wiley & Sons Ltd

Title

Eruptive dermal clear cell desmoplastic mesenchymal tumors with perivascular myoid differentiation in a young boy. A clinical, histopathologic, immunohistochemical and electron microscopy study of 17 lesions

Tomasini C, Metze D, Osella-Abate S, Novelli M, Kutzner H.

Carlo Tomasini[1],
Dieter Metze[2],
Simona Osella-Abate[3],
Mauro Novelli[3] and
Heinz Kutzner[4]

[1]Dermatopathology Section, Azienda Ospedaliera Citt`a della Salute e della Scienza, Turin, Italy,
[2]Department of Dermatology, University Hospital M¨unster, M¨unster, Germany,
[3]Dermatologic Clinic, Department of Medical Science, University of Turin, Turin, Italy, and
[4]Dermatopathologische Gemeinschaftspraxis, Friedrichshafen, Germany
Carlo Tomasini, MD
Dermatopathology Section, Azienda Ospedaliera
Citt`a della Salute e della Scienza, Via Cherasco
23, 10126 Turin, Italy
Tel: +39 0116336180
Fax: +39 011674034
e-mail: ctomasini@cittadellasalute.to.it

Accepted for publication September 17, 2013

Abstract

Clear cell tumors of the skin are observed in a wide variety of benign and malignant conditions with different histogenesis, sharing the presence of cells with abundant clear cytoplasm. Herein, we report the clinicopathologic features of a healthy young patient affected by asymptomatic, eruptive and disseminated, benign clear cell dermal tumors since early infancy. Neither family history nor genetic testing and counseling provided further useful information. The lesions were mostly confined to the face and lower left extremity with pink teleangiectatic papules and small nodules. Over a 4-year period, a total of 16 different cutaneous lesions were biopsied and histopathologic and immunohistochemical studies carried out; an additional lesion was also removed for electron microscopy examination. Histopathology evidenced multiple perivascular growths of spindle to oval and round cells intermingled with clear/granular cells throughout the dermis, with prominent desmoplasia and numerous capillary-like vessels with focal hemangiopericytoma-like features. Immunohistochemical neoplastic cells were uniformly positive for h-caldesmon and focally smooth muscle α-actin and CD13 indicating myoid differentiation whereas the consistent diffuse cytoplasmic staining for lysosome antigen, such as CD68PG-M1 and NKI/C3 along with the ultrastructural findings supported the view of a lysosome-mediated apoptotic process. The differential diagnosis with other clear cell cutaneous neoplasms is discussed.

***Keywords**:* clear cell tumors, electron microscopy, immunohistochemistry, mesenchymal tumors, perivascular myoid cells

Clear cell tumors of the skin are present in a broad variety of benign and malignant conditions with different histogenesis that share a common denominator of cells with abundant clear cytoplasm.[1–3] There are several types of cells designated as 'clear'. Indeed some are filled with mucin, or glycogen, or lipids that are completely resolved during processing, whereas others are filled with lysosomes which impart a granular appearance to the cytoplasm. At times, the cytoplasmic clearing and/or granularity may affect only part of the tumor, allowing for differentiation by conventionalmorphological criteria. However, diagnosis may be challenging and necessitate ancillary techniques, such as histochemistry, immunohistochemistry or electron microscopy, when extensive granular and/or clear cell changes are overwhelmingly predominant as they obscure the underlying differentiation. Histogenetically, clear cell skin tumors may be epithelial, mesenchymal, neural or melanocytic. Although most clear cell skin tumors are well-defined entities, easily recognizable by histopathologic and immunohistochemical features, rare clear cell cutaneous neoplasms of uncertain histogenesis have recently been described.[1,4–9]

Our experience with a young, healthy patient who presented with a history of eruptive, disseminated cutaneous clear cell dermal tumors, present since early infancy, is reported. A diagnosis of benign clear cell mesenchymal neoplasms was made on the basis of the clinicopathologic, immunohistochemical and ultrastructural data from 17 consecutive cutaneous lesions that evidenced myoid cells with extensive clear/granular cell changes.

Materials and methods

A total of 16 biopsies, excised from different cutaneous tumors in the same patient over a 4-year period, were included in the study. All the specimens were fixed in 4% buffered formalin, routinely processed and embedded in paraffin; 4-⌠m thick sections were stained with hematoxylin and eosin and others were stained immunohistochemically by the Flex Envision Technique, using DAKO autostainer and commercially available antibodies (see Table 1). Appropriate positive and negative controls were used in each case. A single representative papule from the face was removed and fixed in Karnovsky's fixative material, followed by postfixation, carried out with 1% osmium tetroxide. The papule was then dehydrated and embedded in Epon (ElectronMicroscopy Sciences, Hatfield, PA, USA). Ultrathin sections were stained with uranyl acetate and lead citrate and examined by a Philips EM10 electron microscope.

Results

Case report

An 11-year-old healthy boy with a 10-year history of multiple asymptomatic facial lesions was referred to us for dermatologic evaluation. The lesions had first appeared around his nostril openings and later developed also on other facial sites. The boy reported that some lesions had regressed spontaneously over the years. At first evaluation, there were numerous 2–10mm skin-colored to pinkish-yellow teleangiectatic papules and small nodules located mainly on the nose – particularly around the nostrils, cheeks, ears and forehead (Fig. 1A). Although they were mostly dome-shaped, some were pedunculated and some of the papules coalesced to form multilobated pink-yellowish nodules (Fig. 1B). Clinical differential diagnoses included fibrous papule, fibrofolliculoma/ trichodiscoma, molluscum contagiosum, trichoepithelioma, pilomatricoma, sebaceous tumor or xanthoma. There were also numerous flesh-colored, firm papules and nodules on his back and left lower extremity, with a large, brownish, ill-defined, firm, cutaneous plaque on the back of his left leg (Fig. 1C,D). Even if the patient had never noted the plaque on the back of his leg, it is most likely to have been present at birth. His mucous membranes were unaffected. There was no family history of hereditary diseases or similar conditions. Neither the patient nor his relatives had Stigmata of Von Recklinghausen's disease, tuberous sclerosis, Birt-Hogg-Dub´e syndrome or Cowden's disease. Following genetic counseling, analyses for germline mutations in the fumarate hydratase (FH) gene (hereditary disseminated leiomyomatosis), FLCN gene (Birt-Hogge-Dub´e syndrome), and TSC1 and TSC2 genes (Tuberous sclerosis complex) were carried out with negative results. The boy's medical history was unremarkable, with the exception ofmigraine at the age of 8, when a full neurologic work-up, includingmultiple magnetic resonance imaging studies (MRI) and electron encephalogram (EEG) evidenced no abnormalities. Chest X-ray, echotomography of thyroid gland, the abdomen including kidneys, lipidogram, ophthalmologic examination, full endocrine and repeated neurologic work-ups were also unremarkable.

After the initial clinical evaluation, 13 differentsized facial lesions were excised and three punch biopsies taken, one from a nodule on the left thigh, one from the firm plaque on the back of his left leg and one from a small plaque in the lumbar region. A total of 16 biopsies from different skin sites were available for

histopathologic examination which was carried out with a wide panel of immunohistochemical markers (Table 1). A facial papule was also removed and submitted for electron microscopy study. At the 4-year follow-up, although the patient is well, he continues to develop new lesions on his face (Fig. 2) and the dorsum of both hands.

Histopathological features

Microscopically, all the tumors had a similar characteristic appearance which varied little from lesion to lesion. The facial lesions were exophytic, well-circumscribed dermal nodules with clear cell aggregates arranged around vascular structures with slit-like or dilated lumen embedded in a sclerotic stroma (Fig. 2A). Neoplastic cells were monomorphous with central or peripheral small, round nuclei; some nuclei were pyknotic with condensed chromatin, while atypia was either scant or absent. Although the cytoplasm was mostly clear and vacuolated, it was focally finely granular and basophilic, mimicking signet ring cells, xanthoma cells or lipoblasts (Fig. 2B). Plump spindle-shaped cells, some with partly vacuolated cytoplasm, were closely admixed with the clear cells. An intimate relationship between the neoplastic cells and slit-like endotheliumlined, irregularly branching vascular channels was a constant feature in all lesions (Fig. 3). Focally, vessels showed a staghorn appearance resembling 'hemangiopericytoma'. The proportion between clear/vacuolated cells and plump myofibroblast-like non-vacuolated cells varied within different areas of the same specimen and among different tumors (Fig. 4A,B). Aggregates of clear cells were diffusely distributed throughout the full thickness of the dermis with focal involvement of the superficial fat tissue, in biopsies obtained from cutaneous lesions from his back and lower left extremity. One biopsy had a marked reduction in the number of clear cell dermal aggregates which were intermingled with prominent fibrosis (Fig. 4C,D). The dermis was almost completely replaced by fibrosis with a few remnants of clear cells in the biopsy from the long-standing, ill-defined firm popliteal plaque.

Special stains and immunohistochemical features

Mucicarmine and periodic acid-Schiff (PAS) stains were negative on clear cells in all specimens. Immunohistochemical analysis showed that all the tumor cells tested were stained diffusely positively for vimentin, h-caldesmon, CD68PG-M1, NKI/C3 and focally for smooth muscle α-actin (Fig. 5), whereas desmin was consistently negative. There was a constant negative result for CD163, a recently characterized antigen, expressed exclusively on monocytes and macrophages. Bcl-2 was mainly expressed by non-vacuolated oval myoid cells, whereas clear cells were almost consistently negative.

A focal weak positivity for CD13 was also observed in some spindle and clear cells. Vascular markers (CD31, CD34, factor VIII-related antigen) were absent, except in the endothelial lining of the vascular spaces. Interstitial CD34+ dendritic cells were scarce. All the other immunohistochemical stains, including neural, melanocytic, epithelial and sebaceous markers, were negative.

Electron microscopy features

Examination of a single representative papule by electron microscopy revealed characteristics of immature mesenchymal cells with features of myoid cells (Fig. 6). The cytoplasm wasmarkedly vacuolated with faint Golgi apparatus, rich in rough endoplasmic reticulum and lysosomes. Membranous, amorphous material and worm-like structures were detected focally. Electron lucent, round, empty spaces varying in size were observed, pushing nuclei focally at the periphery and some of the nuclei were folded. Thin parallel actin fibers with focal dense body formation were observed attached to the cell membranes in the cell periphery and formed adherens plaques in some areas. There was no evidence of desmosomal structures, melanosomes or basementmembranes (Fig. 7).

Discussion

We describe a series of cutaneous dermal neoplasms with striking clear/granular cell features developing in an eruptive fashion in a young male without evidence of an underlying genodermatosis. Their benign nature was supported by the lack of atypia, the monomorphous appearance of the cells, clinical history of long-standing lesions, tendency to spontaneous regression and absence of recurrences. Clinically, the tumors ranged from skin-colored to slightly erythematous, teleangiectatic asymptomatic papules and protruding small nodules on his face (particularly nose and nostrils), pinnae, trunk and extremities. A long-standing, previously unobserved, large, brownish, large, flat plaque was present on the back of his left leg.

The possibility of a hereditary syndrome was raised and further investigated, due to the early onset and the eruptive character of the tumors. The occurrence of multiple facial (and/or extrafacial) cutaneous lesions is

frequently encountered in many familial multiple skin tumor syndromes associated with internal abnormalities and malignancies, including tuberous sclerosis, multiple endocrine neoplasia type I, type-II neurofibromatosis, Cowden disease or Birt-Hogg-Dub´e syndrome.[10] Genetic counseling excluded these conditions on the basis of personal/family histories, physical examination and laboratory investigation. Genetic testing did not reveal any germline mutations in the *FLCN* gene (associated with the Birt-Hogg-Dub´e syndrome), the FH gene (associated with leiomyomatosis/Reed syndrome) and *TSC-1* and *TSC-2* (tuberous sclerosis complex) genes.

The histopathologic features of all lesions reported herein were characterized by an intimate relationship of ovoid, plump spindle and clear cells which seem to emanate from the vessel walls. The vascular lesions contained a varying proportion of clear (vacuolated) and spindle (non-vacuolated) cells. Immunohistochemical analysis showed consistent diffuse vimentin, and h-caldesmon expression as well as focal expression of smooth muscle α-actin and CD13, thereby suggesting perivascular myoid cell differentiation, whereas immunostaining with appropriate markers ruled out the possibility of neural, melanocytic or epithelial lineage. The clear cells were also strongly and diffusely positive for CD68PG-M1 and NKI/C3 in all lesions tested, in keeping with the granular and clear cytoplasmic changes, as a result of lysosome storage and vacuolization. The negative expression of CD163 was of diagnostic value in our study so as to exclude a monocyte/macrophage lineage of neoplastic cells. This recently characterized antigen is considered to be more specific than CD68PG-M1 in identifying cells of monocytic/macrophage lineage under both normal and pathologic conditions.[11] Ultrastructurally, the myoid cell differentiation of the clear cells supported the presence of abundant rough endoplasmic reticulum and actin fibers with adherens junctions at the periphery, along with highly lobulated nuclei, numerous lysosomes and membranous amorphous material, as well as indicating an active process of phagocytosis. As all the neoplasms described herein had a histopathological characterization of predominant clear/granular cell changes, extensive differential diagnosis with other cutaneous clear cell tumors was taken into consideration. Clear cell adnexal tumors, xanthomas, balloon cell melanocytic lesions and clear cell metastatic carcinomas were a matter of major concern amongst the fairly circumscribed dermal neoplasms with clear cells.[1–3,12,13] Moreover, another source of concern was the differentiation of the clear cell tumors described herein from a series of recently described clear cell mesenchymal skin tumors with uncertain histogenesis, including clear cell fibrous papule,[4] perivascular epithelioid cell tumors (PEComas),[5,6] the so-called distinctive clear cell mesenchymal tumor,[7] clear cell and balloon cell dermatofibroma,[8] clear cell granular cell tumors,[14] neurofibroma with clear cell changes,[15] dermal non-neural granular cell tumour,[16] desmoplastic cellular neurothekeoma,[17] metastatic chordoma and epithelioid angioleiomyoma.[18,19] Although the main immunohistochemical features distinguishing these entities and the clear cell tumors described herein are summarized in Table 2, further discussion is appropriate with respect to the differential diagnosis of clear cell fibrous papule, PEComa and the so-called distinctive clear cell mesenchymal tumor. Clear cell fibrous papule is an exceedingly rare cutaneous lesion originally described by Soyer et al. and purported to represent a histopathologic variant of angiofibroma.[4] Twenty-two cases of clear cell fibrous papule have been reported to date (including the granular cell variant).[4,20 – 23] Like the common angiofibroma, clear cell fibrous papule appears as a dome-shaped skincolored to slightly erythematosus solitary papule, which appears most commonly on the nose of adults. Histopathologic examination shows that the unique feature of this entity is the presence of numerous mesenchymal cells displaying copious pale, clear or focally granular cytoplasm embedded in a collagenous stroma with increased capillaries. Interestingly, 5 of 6 cases in Lee's series[20] were positive for CD68 and NKI/C3, indicating that these Lsions have a macrophagic phenotype. Although we did initially consider a diagnosis of clear cell fibrous papule for some of our patient's facial papules, the onset in early infancy, the presence of large protruding nodules with a teleangiectatic surface, the eruptive nature, the involvement of extrafacial sites, the perivascular arrangement of spindle to plump oval and clear cells that consistently expressed hcaldesmon and (focal) smooth muscle α-actin, did not support this interpretation.

Perivascular epithelioid cell tumors (PEComas) are a group of ubiquitous mesenchymal tumors with histopathologically and immunohistochemically distinctive perivascular epithelioid cells (PEC).[5,6] These cells, which have no known normal cellular counterpart, show spindle to epithelioid clear to granular cytoplasm and display a distinctive myomelanocytic immunophenotype, expressing both smooth muscle and melanocytic markers, without diffuse expression of the S100 protein. In the skin, PEComas present mostly on the lower extremities of adult women as asymptomatic solitary dermal nodules characterized by nests and sheets of epithelioid cells with clear or finely granular cytoplasm, separated by delicately arborizing capillaries. Although the clear cell morphology of PEComas is very similar to that observed in our cases, the different immunohistochemical profile led us to rule out this entity. Under the descriptive term 'distinctive

clear cell dermal mesenchymal tumor', Lazar and Fletcher[7] described a series of five neoplasms with clear cell changes of uncertain histogenesis located on the lower extremities of adults, that share some features similar to our cases, namely dermal collections and sheets of oval to polygonal cells with abundant clear to slightly granular PAS-negative cytoplasm with uniform positivity for NKI/C3 and some positivity for CD68 and vimentin, whereas myoid and melanocytic markers were consistently negative. Focal nuclear pleomorphism and elevated mitotic rate were observed in one tumor (Case 5) in this series and all the lesions behaved in a benign fashion. Distinctive clear cell dermal mesenchymal tumors are enigmatic cutaneous lesions that, although share many histopathologic and immunohistochemical similarities with our patient's tumors, do differ, mainly for the presence of striking desmoplasia, an intimate relationship with vessels and hemangiopericytoma-like features. Furthermore, no transition between non-vacuolated oval cells and crescentically granular/clear cells was noted in Lazar and Fletcher's series. All the dermal clear cell tumors described in our case study were characterized by spindle, plump to oval and/or round and clear cells with an intimate relationship with the outer cells of the vascular structures that showed immunohistochemical and electron microscopy features of myoid cells. These findings prompted us to speculate on the histogenesis of the tumors from pericytic cells or other perivascular mesenchymal cells.

Pericytes, also known as Rouget cells, periendothelial cells or mural cells, were first described in 1923 by Zimmermann, as specialized cells normally present around amphibian and vertebrate capillaries.[24] However, pericytes are still under debate as they are difficult to define, constitute a heterogeneous population of cells and their ontogeny is still to be clarified. Basically, they are adventitial cells located within the basement membrane of capillaries and postcapillary venules and are considered to be contractile cells that stabilize vessel walls, participate in the regulation of the blood flow in the microcirculation and have the ability to differentiate into other mesenchymal cells, including fibroblasts, smooth muscle cells and osteoblasts.[25] Microscopic study has showed that the periendothelial location of pericytes may easily be confused with the periendothelial location of vascular smooth muscle cells, fibroblasts, macrophages and even epithelial cells. Several markers have been used in immunohistochemistry to identify pericytes, including smooth muscle α-actin, non-muscle myosin, desmin, highmolecular weight melanoma-associated antigen (NG2), platelet-derived growth factor receptor (PDGFR)-β, aminopeptidase A, aminopeptidase N (CD13) and h-caldesmon.[26] However, none of these markers is absolutely specific for pericytes or are they able to distinguish them from vascular smooth muscle cells and other mesenchymal cells.

The concept of tumors made up of perivascular myoid cells or pericytes was introduced by Stout and Murray in 1942, who coined the term hemangiopericytoma to describe a spectrum of neoplasms which shared certain morphologic characteristics: a monotonous appearance at scanning magnification, moderate to high cellularity and the presence of numerous, variably thick-walled, branching 'staghorn' vessels.[27] However, over the years, it became evident that this vascular pattern, although rather characteristic, was non-specific, as it is shared by a wide variety of benign and malignant mesenchymal entities with a different lineage of differentiation.[28,29] Currently, entities that might represent true 'hemangiopericytomas', i.e. tumors made up of vessels and pericytes, include hemangiopericytoma of the sinusonal tract with myoid differentiation,myofibroma/myofibromatosis and the so-called infantile hemangiopericytoma with myoid differentiation, glomangiopericytoma, myopericytoma and perivascular myoma.[30]

Although no definite conclusion can be drawn as to the histogenesis of our patient's clear cell tumors, the diffuse expression of h-caldesmon and, focally, smoothmuscle α-actin and CD13, may be in keeping with the hypothesis of a histogenetic relationship of neoplastic oval and clear cells with perivascular poorly differentiated myoid cells. Interestingly, there was a spectrum of pathologic changes in the proportion of clear (vacuolated) and spindle (non-vacuolated) cells, from lesions showing a mixture of spindle to oval non-vacuolated cells and clear cells to lesions almost completely replaced by fibrosis with only few scattered clear cell nests. As the most diffuse fibrotic changes were observed in biopsy specimens from long-standing lesions on the lower extremity, these changes may well reflect the evolution of the lesions, in line with their tendency to spontaneous regression.

The pathogenesis of the cytoplasmic clearing or granularity of the perivascular myoid cells in our patient is also intriguing. The consistent diffuse cytoplasmic staining for lysosome antigens, such as CD68PG-M1 and NKI/C3, in most of the clear and granular cells and the ultrastructural findings support the interpretation that these changes may be due to a lysosome-mediated apoptotic process. Under physiological conditions, lysosomes participate in the organelle and macromolecule turnover through the release of hydrolases, a process called 'autophagy' that, depending on the particular context and intensity, is able to protect cells against cell death or mediate the so-called autophagic cell death.[31,32] In conclusion, we describe a series of eruptive, disseminated cutaneous clear cell neoplasms with perivascular myoid cell differentiation in a young

boy. The fact that the lesions began to appear when the boy was only 1 year old could imply a genetically determined condition, even if the genetic studies we carried out and the family histories we took did not demonstrate it. At present, our patient is under constant oncologic surveillance. It is hoped that future genetic advances will help solve this conundrum.

Acknowledgements

The authors thank Dr Rosa Maria Alfano and Dr Laura Moneghini Division of Pathology, San Paolo Hospital, Milan for the TSC genetic testing and h-caldesmon immunohistochemistry.

References

1. Civatte J. Clear cell tumors of the skin. J Cutan Pathol 1984; 11: 165.
2. Suster S. Clear cell tumors of the skin. Semin Diagn Pathol 1996; 13: 40.
3. Biswas A, Mahalingam M. Cutaneous clear cell neoplasms: a histopathological reappraisal. Am J Dermatopathol 2012; 34: 237.
4. Soyer HP, Kutzner H, Metze D, Cerroni L, Kerl H, Ackerman AB. Fibrous papule with clear fibrocytes. Dermatopathol Pract Concep 1997; 3: 110.
5. Mentzel T, Reisshauer S, R¨utten A, Hantschke M, Soares de Almeida LM, Kutzner H. Cutaneous clear cell myomelanocytic tumour: a new member of the growing family of perivascular epithelioid cell tumors (PEComas). Clinicopathologic and immunohistochemical analysis of seven cases. Histopathology 2005; 46: 498.
6. Liegl B, Hornick J, Fletcher C. Primary cutaneous PEComa: distinctive clear cell lesions of skin. Am J Surg Pathol 2008; 32: 608.
7. Lazar AJ, Fletcher CD. Distinctive dermal clear cell mesenchymal neoplasm: clinicopathologic analysis of five cases. Am J Dermatopathol 2004; 26: 273.
8. Zelger BW, Steiner H, Kutzner H. Clear cell dermatofibroma. Case report of an unusual fibrohistiocytic lesion. Am J Surg Pathol 1996; 20: 483.
9. Chaudhry IH, Calonje E. Dermal nonneural granular cell tumor (so-called primitive polypoid granular cell tumor): a distinctive entity further delineated in a clinicopathologic study of 11 cases. Histopathology 2005; 47:179.
10. LeeDA, Schneiderman P, Celebi JT. Genetics of skin appendage neoplasms and related syndromes. J Med Genet 2005; 42: 811.
11. Lau SK, Chu PG, Weiss LM. CD163. A specific marker of macrophages in paraffinembedded tissue samples. Am J Clin Pathol 2004; 122: 794.
12. Ostler DA, Prieto VG, Reed JA, Deavers MT, Lazar AJ, Ivan D. Adipophillin expression in sebaceous tumors and other cutaneous lesions with clear cell histology: an mmunohistochemical study of 117 cases. Mod Pathol 2010; 23: 567.
13. Opper B, Elsner P, Ziemer M. Cutaneous metastasis of renal cell carcinoma. Am J Clin Dermatol 2006; 7: 271.
14. Zedek DC, Murphy BA, Shea CR, Hitchcock MG, Reutter JC, WhiteWL. Cutaneous clearcell granular cell tumors: the histopathologic description of an unusual variant. J Cutan Pathol 2007; 34: 397.
15. Puri PK, Tyler WB, Ferringer TC. Neurofibroma with clear cell change. Am J Dermatopathol 2009; 31: 53.
16. Chaudhry IH, Calonje E. Dermal nonneural granular cell tumor (so-called primitive polypoid granular cell tumor): a distinctive entity further delineated in a clinicopathologic study of 11 cases. Histopathology 2005; 47:179.
17. García-Guti´errez M, Toussaint-Caire S, Gonz´alez-S´anchez P, Ortiz-Hidalgo C. Multiple desmoplastic cellular neurothekeomas localized to the face of a 16-year-old boy. Am J Dermatopathol 2010; 32: 841.
18. Su WP, Louback JB, Gagne EJ, Scheithauer BW. Chordoma cutis: a report of nineteen patients with cutaneous involvement of chordoma. J Am Acad Dermatol 1993; 29:63.
19. Liu JY, Liao SL, Zheng J. Cutaneous epithelioid angioleiomyoma with clear cell change. Am J Dermatopathol 2007; 29: 190.
20. Lee AN, Stein SL, Cohen LM. Clear cell ibrous papule with NKI/C3 expression. Am J Dermatopathol 2005; 27: 296.
21. Park HS, Cho S, Kim KH, Won CH. Fibrous papule of the face, clear cell type: a case report. J Eur Acad Dermatol Venereol 2007; 21: 1267.
22. Jacyk WK, Rutten A, Requena L. Fibrous papule of the face with granular cells.Dermatology 2008; 216: 56.
23. Chiang YY, Tsai HH, Lee WR, Wang KH. Clear cell fibrous papule: report of a case mimicking balloon cell nevus. J Cutan Pathol 2009; 36: 381.
24. Zimmermann KW. Der feinere Bau der Blutcapillares. Zeit Anat Entwicklungsgesch 1923; 68: 29.
25. Díaz-Flores L, Guti´errez R, Varela H, Rancel N, Valladares F. Microvascular pericytes: a review of their morphological and functional characteristics. Histol Histopathol 1991; 6: 269.
26. Armulik A, Genov`e G, Betsholtz C. Pericytes: developmental, physiological, and pathological perspectives, problems, and promises. Dev Cell 2011; 16: 193.
27. StoutAP, MurrayMR. Hemangiopericytoma. A vascular tumor featuring Zimmermann's pericytes. Ann Surg. 1942; 116: 26.
28. Fletcher CDM. Haemangiopericytoma – a dying breed? Reappraisal of an ''entity'' and its variants: a hypothesis. Curr Diagn Pathol 1994; 1: 19.
29. Nappi O, Ritter JH, Pettinato G, Wick MR. Hemangiopericytoma: histopathological. pattern or clinicopathologic entity? Semin Diagn Pathol 1995; 12: 221.
30. Gengler C, Guillou L. Solitary fibrous tumour and haemangiopericytoma: evolution of a concept. Histopathology 2006; 48: 63.
31. Kroemer G, Jaattela M. Lysosomes and autophagy in cell death control. Nature 2005; 5: 888.
32. Gonzalez-Polo RA, Boya P, Pauleau AL, et al. The apoptosis/autophagy paradox: autophagic vacuolization before apoptoticdeath. J Cell Sci 2005; 118: 3091.

Table 1. Antibodies (immunoreagents) utilized

Antibody	Clone	Source	Company	Dilution	Antigen retrieval
Adipophilin	AP125	Mouse	Acris	1 : 100	pH 9.0
BerEP4*	Ber-EP4	Mouse	DAKO	1 : 200	pH 6.0
h-Caldesmon	E89	Mouse	Ventana	1 : 100	–
Calponin	CALP	Mouse	Thermo Scientific	1 : 5000	pH 6.0
CD1a	010	Mouse	DAKO	1 : 200	pH 6.0
CD13	38C12	Mouse	Novocastra	1 : 80	PH 6.0
CD34*	My10	Mouse	BD Biosciences	1 : 100	pH 6.0
CD31*	JC70A	Mouse	DAKO	1 : 100	pH 6.0
CD68*	PG-M1	Mouse	DAKO	1 : 200	pH 6.0
CD163	10D6	Mouse	Leyca Macrosystem	1 : 1000	pH 6.0
Cytokeratin AE1/AE3*	AE1/AE3	Mouse	DAKO	1 : 50	pH 6.0
Cytokeratin 7*	OV-TL	Mouse	DAKO	1 : 50	pH 6.0
Cytokeratin 14*	LL002	Mouse	BioGenex	1 : 100	pH 6.0
Cytokeratin MNF116*	MNF116	Mouse	DAKO	1 : 500	pH 9.0
EMA	Mc5	Mouse	BioGenex	1 : 400	pH 6.0
Factor XIIIa	AC-1A1	Mouse	Thermo Fisher Scientific	1 : 1000	–
HMB45	HMB45	Mouse	DAKO	1 : 300	pH 6.0
Langerin	12D6	Mouse	Menarini	1 : 200	pH 9.0
Melan-A	A 103	Mouse	DAKO	1 : 1000	pH 9.0
NKI/C3	NKI/C3	Mouse	BioGenex	1 : 200	–
PGP 9.5	Polyclonal	Rabbit	Dako Cytomation	1 : 18000	pH 6.0
PHLDA1 = TDAG51	RN-6E2	Mouse	Santa Cruz Biotechnology	1 : 300	pH 6.0
Vimentin*	Vim 3B4	Mouse	DAKO	1 : 150	pH 6.0
S100*	Polyclonal	Rabbit	DAKO	1 : 2000	–
Smooth muscle actin	1A4	Mouse	DAKO	1 : 500	pH 9.0

*Predigestion proteinase.

Table 2. Differential diagnosis of dermal clear cell tumors

Entity	Lineage	Primary immunoreactivity
Clear cell adnexal tumors	Epithelial	Cytokeratins, EMA, adipophilin
Xanthoma	Macrophage	CD68, adipophilin
Clear cell melanocytic nevus and melanoma	Melanocytic	S100, Melan-A, HMB-45
Clear cell metastatic carcinoma	Epithelial	Cytokeratins, EMA, vimentin, CD10
Distinctive clear cell mesenchymal tumors	Mesenchymal, unspecified	NKI/C3, CD68 and vimentin (focal)
Clear cell/balloon cell dermatofibroma	Uncertain (presumed fibrohistiocytic)	Factor XIIIa
Perivascular epithelioid cell tumors (PEComas)	Uncertain	Smooth muscle and melanocytic markers
Clear cell fibrous papule	Uncertain (presumed fibrohistiocytic)	Factor XIIIa, vimentin, CD68, NKI/C3
Epithelioid angioleiomyoma	Smooth muscle	Actin, desmin
Clear cell granular cell tumor	Uncertain	S100, NSE, p75,CD68, NKI/C3
Neurofibroma with clear cell change	Neural	S100, CD68 (focal), p75
Non-neural granular cell tumor	Uncertain	NKI/C3, CD68 (focal)
Desmoplastic cellular neurothekeoma	Uncertain	NKI/C3,PGP9.5, S100A6, calponin, MITF
Chordoma	Neuroectodermal (physaliferous cell)	S100, vimentin, cytokeratin, and EMA
Present case	Myofibroblast (presumed pericyte)	Vimentin, h-caldesmon, CD13 (focal), smooth muscle α-actin (focal), CD68, NKI/C3, bcl-2

EMA, epithelial membrane antigen; MITF, microphthalmia-associated transcription factor; NSE, neuron specific enolase.

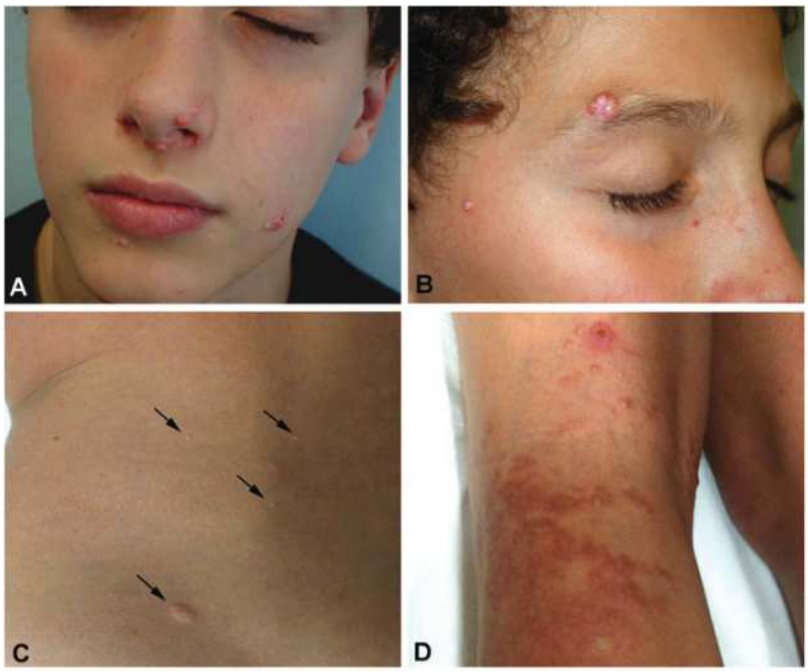

Fig. 1. (A and B) Pale facial papules with a teleangiectatic surface and grouped multilobated lesions. C) Scattered lesions on the trunk (arrows). D) Erythematous papulonodular lesions and hairless, hyperpigmented, cobblestone-like, ill-defined plaque on the posterior aspect of the extremity.

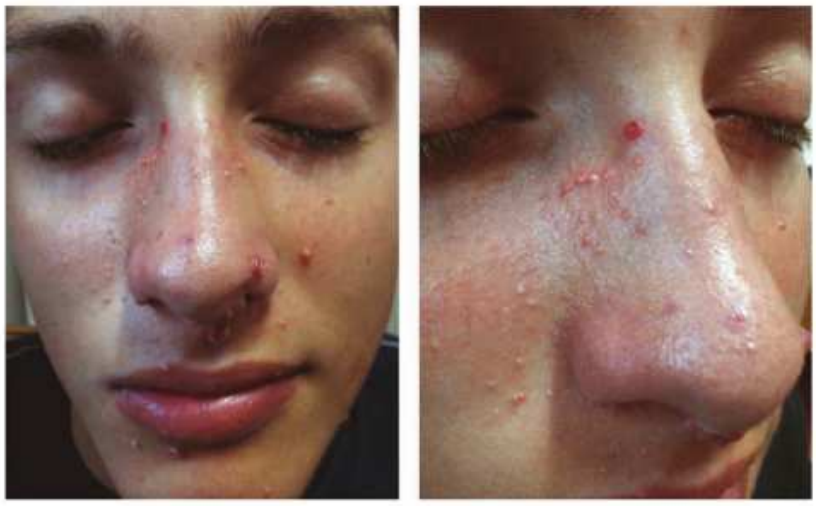

Fig. 2. Eruptive tumors on the face at the 4-year follow-up.

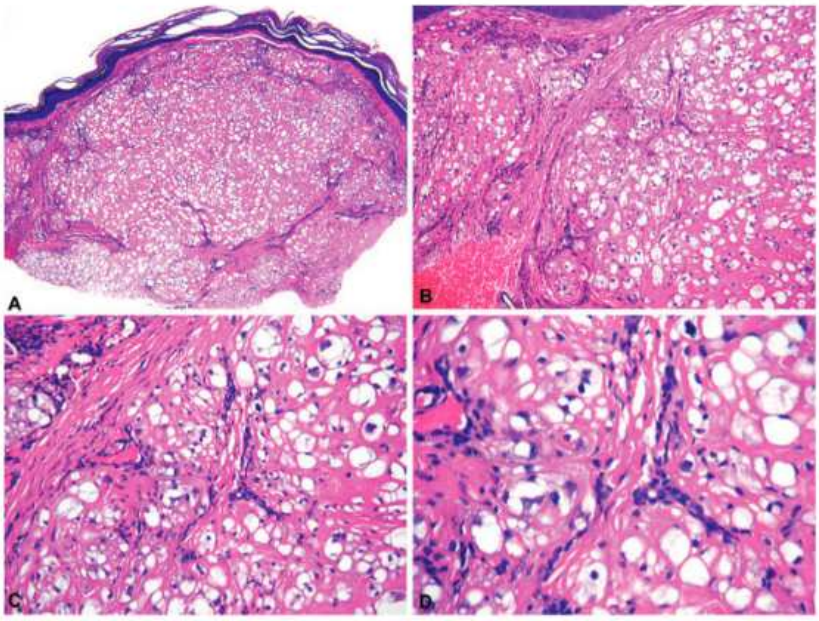

Fig. 3. A) A richly vascularized clear cell tumour with prominent stromal hyalinization. B) Clusters of round clear/granular cells are arranged in perivascular whorls. C) Note the intimate relationship between the clear cells and the vessel walls. D) The cytoplasm of neoplastic cells ranges from finely granular to clear and vacuolated.

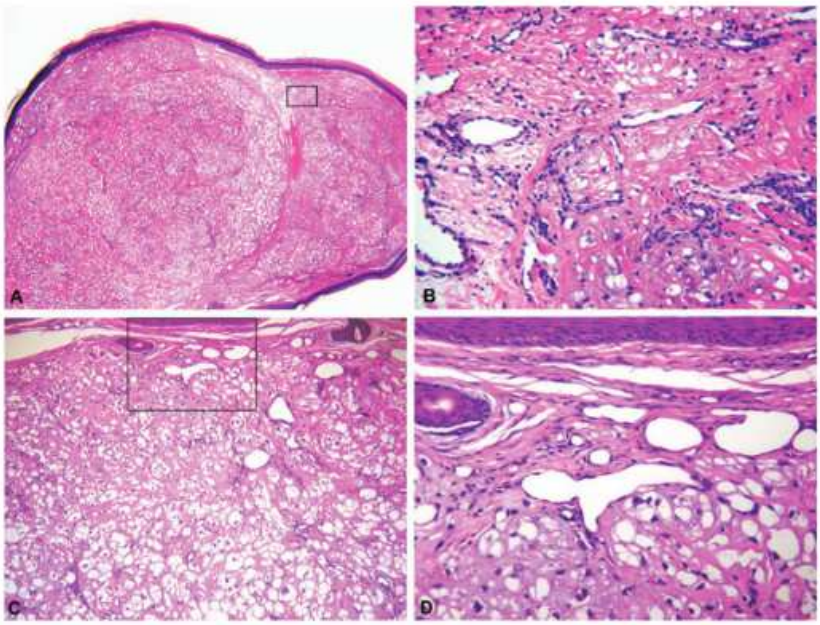

Fig. 4. A) Exophytic sessile clear cell tumour with superficial teleangiectasia. B) Ill-defined whorls of clear cells surrounding thin-walled 'staghorn' branching vessels. C) Perivascular growths of spindle to oval and clear cells in a focally prominent hemangiopericytoma-like pattern. D) Particular.

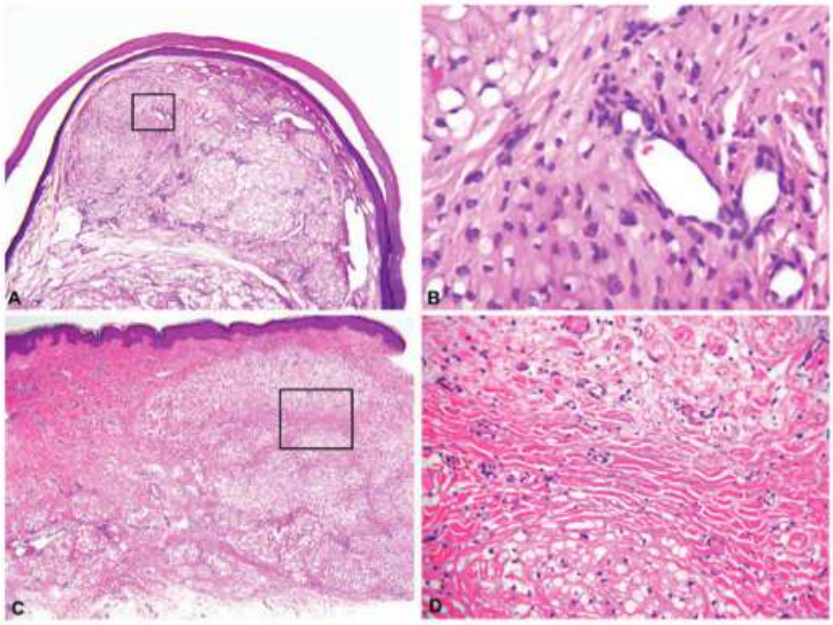

Fig. 5. (A and B) Early onset facial lesion showing mixed non-vacuolated and clear cellular patterns. B) Perivascular myoid cells intermingled with clear cells. (C and D) Biopsy of the long-standing plaque on the lower extremity showing prominent fibrotic changes and remnants of clear cell nodules.

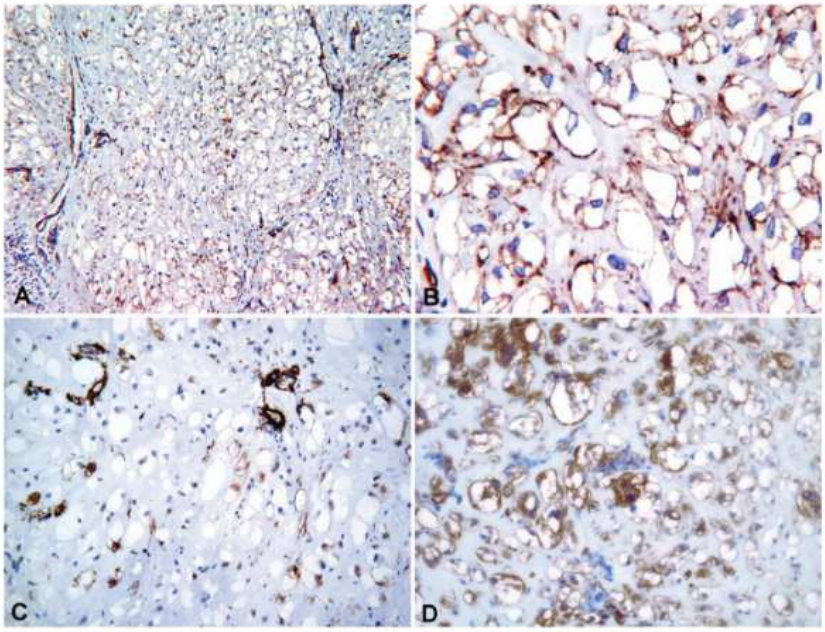

Fig. 6. Immunohistochemical characteristics of neoplastic cells. A) h-Caldesmon. Diffuse positivity of perivascular clear cells. Note the stronger expression of this marker on the outer cell lining of the vessels. B) Immunostaining for h-caldesmon is confined to the cell periphery. C) Smooth muscle a-actin. The clear cells show a focal expression of this marker. D) NKI/C3. A strong diffuse cytoplasmic expression is shown.

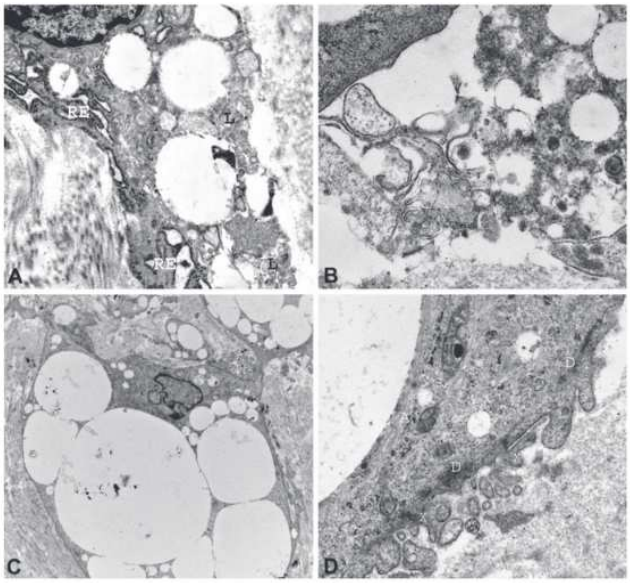

Fig. 7. Electron microscopy. A) The cytoplasm of the clear cells is markedly vacuolated and rich in rough endoplasmic reticulum and lysosomes (L) (original magnification ×20,000). B) Focally, membranous, amorphous material and worm-like structures are apparent (original magnification ×30,000). C) Electron lucent round empty spaces of different sizes (original magnification ×2,000). D) The periphery of the cells expressed thin parallel actin fibers (A) with focal dense body formation (D), which in some areas were attached to the cell membranes forming adherens plaques (X) (original magnification ×15,000).