

AperTO - Archivio Istituzionale Open Access dell'Università di Torino

Long-term outcomes of implants placed after vertical alveolar ridge augmentation in partially edentulous patients: A 10-year prospective clinical study

This is the author's manuscript

Original Citation:

Availability:

This version is available <http://hdl.handle.net/2318/1597832> since 2018-09-18T12:21:16Z

Published version:

DOI:10.1111/clr.12941

Terms of use:

Open Access

Anyone can freely access the full text of works made available as "Open Access". Works made available under a Creative Commons license can be used according to the terms and conditions of said license. Use of all other works requires consent of the right holder (author or publisher) if not exempted from copyright protection by the applicable law.

(Article begins on next page)

Long-term outcomes of implants placed after vertical alveolar ridge augmentation in partially edentulous patients: a 10-year prospective clinical study

Mario ROCCUZZO¹⁻², Matteo SAVOINI¹, Paola DALMASSO³, Guglielmo RAMIERI¹

1 Division of Maxillofacial Surgery, University of Torino, Italy

2 Private practice, Torino, Italy;

3 University of Torino, Department of Public Health and Paediatrics.

Correspondence to:

Dr. Mario Roccuazzo

Corso Tassoni, 14

10143 Torino,

Italy

Tel & Fax: +39.011.771 47 32

e-mail: mroccuzzo@icloud.com

Key words: bone implant interactions, bone regeneration, clinical assessment, clinical research, clinical trials, diagnosis, guided bone regeneration, periodontology, soft tissue-implant interactions, surgical techniques

ABSTRACT

Aim: The aim of this study was to evaluate the long-term clinical results around non-submerged implants placed after vertical alveolar ridge augmentation.

Material and methods: The original population consisted of two groups of partially edentulous patients (Clinical Oral Implants Research, 15, 2004, 73; Clinical Oral Implants Research, 18, 2007, 286), receiving a total of 82 implants, after a vertical bone augmentation of at least 4 mm. Following cementation of the fixed dental prostheses, patients were asked to follow an individualized supportive periodontal therapy (SPT) program for an appropriate clinical and radiographic follow-up.

Results: At the 10-year examination, seven of the 41 patients were lost to follow-up. During SPT, additional antibiotic and/or surgical therapy was necessary in 18 implants, and four of these implants were removed for biological complications. The overall implant survival rate was 94.1%. The mean interproximal bone loss (BL) was 0.58 ± 0.57 mm.

Conclusions: The results of this study confirmed that implants, placed after vertical augmentation and followed by an adequate SPT, offer predictable long-term results. Nevertheless, patients whose bone atrophy was consequence of a previous history of periodontitis presented a statistically significant greater BL.

INTRODUCTION

Ideal implant positioning requires sufficient bone, and augmentation is often a necessary option in compromised sites, due to trauma, atrophy, periodontal disease, and/or infection. Vertical regeneration of resorbed alveolar ridges is still the most challenging surgical procedure, especially in case of extensive atrophy. Even though there is a lack of controlled clinical trials evaluating the efficacy of the various surgical techniques, several reviews have been published, during the last years, to assess the real possibility of rehabilitation after bone augmentation (Aghaloo & Moy 2007; Tonetti & Hammerle 2008; Esposito et al. 2009; Ricci et al. 2013; Milinkovic & Cordaro 2014; Carini et al. 2014; Rasia dal Polo et al. 2014; Aloy-Prósper et al. 2015; Lutz et al. 2015).

Aghaloo & Moy (2007), for the Academy of Osseointegration Consensus Conference, found that alveolar ridge augmentation techniques did not have detailed documentation or long-term follow-up studies and did not allow for survival analysis under functional loading.

The Consensus Report of the 6th European Workshops on Periodontology (Tonetti & Hammerle 2008) emphasized the need to answer questions on the long-term performance of dental implants placed after vertical ridge augmentation. It was also highlighted that augmentation procedures have significant adverse events and can fail to produce adequate bone volumes to allow dental implant positioning. Moreover, available indications suggest that implants placed in augmented areas do not necessarily have the high long-term survival rates of dental implants placed in pristine sites.

In the following year, Esposito et al. (2009) published a systematic review based on few RCTs including few patients, sometimes having short follow-up, and often being judged to be at high risk of bias. He found out that various techniques can augment bone, but complications, especially for vertical augmentation, are common.

Ricci et al. (2013) presented a systematic review based on six papers, with no clear indication on the length of follow-up. Survival and success rates of implants placed in the areas treated with titanium grids were comparable to those of implants placed in native, non-regenerated bone and of implants placed in bone regenerated with resorbable and non-resorbable membranes.

Rasia dal Polo et al. (2014) devoted their systematic review on the alveolar ridge reconstruction with titanium meshes, only. An advantage in favor of the titanium mesh was found in terms of bone loss after exposure, as implant placement was not jeopardized in almost all of the cases. It could be deduced that titanium meshes represented a reliable solution for alveolar ridge reconstruction, in both lateral and vertical bone regeneration.

According to Milinkovic & Cordaro (2014), vertical defects can be treated with simultaneous and staged GBR, bone block grafts, and distraction osteogenesis. Further studies on bone augmentation procedures should report precise preoperative and post-operative measurements to enable a more exact

analysis, as well as to provide the clinician with the rationale for choosing the most indicated surgical approach.

Carini et al. (2014) concentrated on the use of autologous vs. autologous and bone substitutes under TiMesh and found out that the use of autologous bone is associated with a height and width gain of bone, which are greater compared to other techniques.

Aloy-Prósper et al. (2015) found that survival and success rates of implants placed in horizontally and vertically resorbed edentulous ridges reconstructed with block bone grafts are similar to those of implants placed in native bone, in distracted sites or with guided bone regeneration. Lutz et al. (2015) showed that different hard-tissue augmentation procedures seem to show stable peri-implant tissues, although due to high heterogeneity, the performance of meta-analysis was impossible and no correlation between soft tissue and bone stability could be presented.

Even though several distinguished scientific authorities (Tonetti & Hammerle 2008) had already stated that implants should be evaluated with cumulative success rates over a period of at least 10 years, most studies report only short-term results and/or retrospective data.

Two previous articles on the placement of non-submerged tissue level implants placed after vertical alveolar ridge augmentation in partially edentulous patients (Roccuzzo et al. 2004, 2007) concluded that more years of observation were necessary to verify the stability of augmentation over a long period of time and to compare the rate of resorption of peri-implant bone with that obtained by means of similar or other techniques.

The aim of this prospective study was to present the 10-year clinical parameters around implants placed after vertical bone augmentation and to provide information about the stability of the peri-implant regenerated bone. The results regarding implant loss, bone loss, soft tissue recession, pus, pocket depth, plaque, bleeding on probing, and additional treatment in the patients are described in this article.

MATERIAL AND METHODS

Study population

The study investigated the 10-year clinical and radiographic outcomes of two previously published groups of patients. Details have been already reported (Roccuzzo et al. 2004, 2007). Forty-one (13 male and 28 female, mean age 48.5 ± 10.6) subjects providing 82 implants were originally included. All patients were selected from those seeking implant rehabilitation and presenting, at preliminary visit with an orthopantomography, an insufficient coronal apical height of at least a portion of the alveolar process. The edentulous area in the maxilla or in the mandible, to be replaced with fixed partial

denture or single crown, corresponded to a Cawood and Howell's Class IV, V, or VI (Cawood & Howell 1988). The need for vertical augmentation of at least 4 mm was considered the condition required to be part of this study. The first 18 patients were treated with an autogenous bone graft, harvested from either the mandibular ramus or the mental symphysis and secured by means of titanium screws. Particulate bone was added, and a titanium micro-mesh (Ti-Mesh) was used to stabilize and protect the graft. If indicated, a titanium plate was also used for a maximum stability. The dimension of the block and the volume of the bone chips were selected to allow removal of the screws, at second surgery.

In the second group of 23 patients, a controlled clinical trial was conducted and identical surgery performed, by the same operator, at 12 test (bone graft + Ti-Mesh) and 12 control (bone graft alone) sites.

All patients were healthy, with no systemic contraindication to intraoral surgery and implant placement. Following selection, they received proper oral hygiene instructions and, when necessary, scaling and root planing. At the end of the initial therapy, before entering the surgical procedures, all patients demonstrated an adequate plaque control.

Patients were informed that their data would be used for statistical analysis and gave their informed consent to the treatment. No ethical committee approval was sought to start this study, as it was not required by national law or by ordinance of the local inspective authority. The prospective study was performed in accordance with the principles stated in the Declaration of Helsinki and the Good Clinical Practice Guidelines.

Surgical and prosthetic procedures

All procedures were performed, under local anesthesia, by the same operator (MR) expert in periodontal and implant surgery. During the first surgery, bone blocks were secured by means of screws and additional bone was harvested from and around the donor sites to increase the volume until the desired height and to create a regular morphology. After 4–6 months, a second surgery was performed to place solid-screw SLA implants, according to the manufacturer's instructions (Institut Straumann AG, Waldenburg, Switzerland) in a non-submerged fashion. Implants were placed with the border of the rough surface approximating the alveolar bone crest leaving the machined neck portion in the transmucosal area with a close adaptation of the wound margins to the implant shoulder. Whenever necessary, a connective tissue graft, harvested from the palate, was sutured onto the area to obtain thicker and wider marginal tissues around the implants, with no muscular tensions around their necks.

Abutment connection was carried out at 35 Ncm 6–10 weeks post-surgery to provide patients with

cemented implant-supported fixed restorations. Therefore, each test implant supported either a single crown or a portion of a small bridge. All restorations were fabricated to facilitate both the oral hygiene procedures and the probing along their circumference. Baseline probing measurements and radiographic data were collected, after prosthesis installation, to establish a baseline reference for the following controls. (Figs 1–5).

Data on patients, implant sites, and principal outcomes at 10-year are reported in Table 1.

Follow-up

Patients were placed on an individually tailored maintenance care program for supporting periodontal therapy (SPT), including continuous evaluation of their ability to perform proper plaque control, according to their previous periodontal history. Two different types of patients were considered separately: periodontally healthy patients (PHP) and periodontally compromised patients (PCP). Motivation, re-instruction, instrumentation, and treatment of sites with inflammation were performed as needed. When a patient either expressed the desire not to attend follow-up examinations or was not able to attend the requested visits, he/she was classified as “dropout.”

The diagnosis and treatment of peri-implant biological complications were performed according to cumulative interceptive supportive therapy (CIST) (Mombelli & Lang 1998), which consists in a series of treatment procedures that have to be cumulative adopted, depending on the health conditions of the peri-implant tissues: the number of sites treated according to therapy modalities C (systemic antibiotic therapy or treatment with local delivery device) and D (surgical therapy) during the 10 years was also registered.

Clinical measurements

The following parameters were examined during the clinical examination:

- Presence/absence of plaque at 4 sites of each implant (PI);
- Probing pocket depths (PD) at 4 sites of each implant and rounded off to the nearest millimeter.
- Bleeding on probing at 4 sites around each implant (BOP);
- Width of the keratinized tissue (KT) measured at the buccal aspect of the implant;
- Marginal soft tissue recession (REC) measured from the top of the crown to the soft tissue margin.

Final clinical examination

After 10 years, an examiner (S.G.), with more than a dozen years of experience as hygienist, blinded to the initial classification of the patients, recorded, for each test implant, probing depth (PD) measured at four sites (mesial, buccal, distal, and lingual) by means of a periodontal probe (XP23/UNC 15, Hu- Friedy, Chicago, USA) and rounded off to the nearest millimeter.

Soft tissue recession (REC) was measured from the implant shoulder to the coronal margin of the mucosa, by means of a Castroviejo Caliper Short (Salvin Dental Specialties, Inc., Charlotte, NC, USA) and rounded off to the nearest $\frac{1}{2}$ mm.

The distance between the base of the implant shoulder and the most coronal visible bone-to-implant contact, measured in millimeters, both at the mesial and at the distal aspect of each implant, was calculated using standardized periapical intraoral films with a long cone technique (Bornstein et al. 2005) and compared with the baseline values according to the technique described previously by Rocuzzo et al. (2008) (Figs 6 and 8).

Furthermore, the following parameters were collected:

- implant loss;
- plaque score (presence/absence): total score for both teeth and implants (FMPS) and for the implant alone (PI), measured at four sites per implant and expressed as a percentage of examined sites;
- bleeding on probing score (presence/absence): total score for both teeth and implants (FMBS) and for the implant alone (BOP), measured at four sites per implant and expressed as a percentage of examined sites;
- number of sites which required, during the SPT, additional treatment with modalities C and D according to the Cumulative Interceptive Supportive Therapy (CIST);

STATISTICAL ANALYSIS

Data were expressed as mean (\pm SD) and median (25–75 percentile) or counts and percentages.

Between-group differences were assessed by generalized linear model (GLM), using gaussian or gamma parameterization, as appropriate, for quantitative parameters, and logit link and binomial variance function to analyze categorical variables.

As patients received more than one implant, standard errors were all estimated taking account of the correlation of observations. All the tests were two tailed, and statistical significant level was set at 0.05.

RESULTS

Of the initial 41 patients enrolled in the study, seven patients (14 implants) were lost to follow-up: two died, one was not able to attend the final examination because he moved, and three refused the follow-up visit (Table 2). The final analysis was performed on 34 subjects.

Overall, PD around implants remained stable 3.12 ± 0.69 mm to 3.26 ± 0.91 mm ($p = 0.58$), while there was a small, but significant, reduction in KT width from 2.34 ± 1 mm to 1.89 ± 1.11 mm ($p < 0.001$).

Plaque around the implants was found to be $14.1 \pm 14\%$ at baseline and $21.9 \pm 25.8\%$ at the 10-year examination ($p = 0.13$), while BOP was $19.1 \pm 14.6\%$, $25.7 \pm 23.9\%$ ($p = 0.09$), respectively (Table 3).

Total mean bone loss was 0.58 ± 0.57 mm with a significant difference between PHP and PCP, that is, 0.43 ± 0.50 mm vs. 0.78 ± 0.59 mm ($p = 0.04$) (Table 4).

At the end of the 10-year period, pus was never detected in both groups.

During the entire 10-year observation time, 12 of the 30 implants (40%) in PCP needed antibiotic or surgical therapy for the treatment of biological complications. The corresponding values for healthy patients was seven of 38 (18.4%), even though the difference between the two groups did not reach a statistically significant difference ($p = 0.07$).

Three implants in the PCP group were lost, while only one in PHP.

DISCUSSION

This study provides evidence that non-submerged implant placement, after vertical ridge augmentation in partially edentulous patients, offers successful long-term results. This is, to the best of our knowledge, the first 10-year prospective study that presents data on the long-term implant outcomes, after vertical bone augmentation in the maxilla and mandible using autogenous grafts alone or associated with a titanium mesh (Ti-Mesh). Nevertheless, the difference between the use and not of the Ti-mesh was limited to the healing period. This is the reason why the 2 groups were pooled, in order to have a larger group of patients to evaluate the stability of the regenerated bone.

Tonetti & Hammerle (2008), for the consensus report of the 6th European workshop on periodontology, noted that the evidence base, for vertical ridge augmentation procedures to allow implant placement in clinical practice, was circumscribed to a limited number of studies performed by few investigators.

With four losses of 68 implants that reached the 10-year follow-up, the overall survival rate is equal to 94.1%. These results are comparable with another long-term retrospective study that reported a cumulative 10-year survival rate of 94.48% in patients treated with maxillary sinus augmentation and/or onlay bone grafting (Schmitt et al. 2014). However, these authors report a much greater

vertical bone loss (27.51%), probably due to the nature of bone harvested from the iliac crest. Similar outcomes are referred in implants placed simultaneously with GBR procedures, using resorbable and non-resorbable membranes, after 12–14 years follow-up in 58 patients, corresponding to 80.5% of the original study population (Jung et al. 2013). The average change in bone level over time was 0.081 mm/year, with a 95% confidence interval of 0.072–0.09 mm/year. In a study on 41 patients (50 sites), Miyamoto et al. (2012) presented a cumulative survival rate of 92.8% for implants placed in alveolar ridge reconstruction with titanium mesh and autogenous particulated bone graft after up to 96 months (mean follow-up 47.5 months). On the other hand, it is important to note that all the patients in our study reached the 10-year follow-up analysis. Nevertheless, even with these preliminary data, given the confined number of investigators using these techniques and the low number of patient treatments reported in the literature, the generalizability of this approach is still limited at this time in accordance with Tonetti & Hammerle (2008).

Corinaldesi et al. (2009) presented retrospective data on 24 patients treated by means of a Ti-mesh filled with intraoral autogenous bone and implant placement in both one- and 2-stage procedure. The mean peri-implant bone loss was 1.58 ± 0.48 mm, after 3–8 years, which is almost the double of the one reported in the present study. The reason for this is that 20 of the 56 implants were placed simultaneously with bone augmentation.

The total interproximal bone loss at 10 years post-loading was 0.58 ± 0.57 mm, and it appears to be consistent also with the ones reported for similar implants placed in native, non-reconstructed bone, and similar follow-up (Buser et al. 2012; Rocuzzo et al. 2014; van Velzen et al. 2015). In another study (Buser et al. 2013), a mean value of 0.44 mm was reported for the distance of implant shoulder to the first bone-to-implant contact (DIB), indicating minimal crestal bone loss over 6 years. Chiapasco et al. (2012) presented data on 18 patients treated by bone blocks of various origin and detected a BL of 0.52 ± 0.45 mm, after a mean time of 19 months.

De Stavola & Tunkel (2013) presented the results of the management of alveolar crest vertical defects using the tunnel technique approach associated with autogenous bone blocks prior to implant placement in 10 partially dentate. Data illustrated a 0.55 ± 0.49 mm mean bone remodeling. The limit in this paper is the short follow-up period 8 months.

Poli et al. (2014) presented the data of 13 patients selected for alveolar ridge reconstruction by means of a Ti-mesh filled with intraoral autogenous bone mixed with deproteinized an organic bovine bone in a 1:1 ratio. The mean peri-implant bone loss was 1.74 ± 0.56 mm on the mesial side and 1.91 ± 0.71 mm on the distal side, from the top of the implant head to the first visible bone–implant contact, at a mean follow-up of 88 months.

Clinical parameters were also recorded to demonstrate soft tissue stability over a 10- year observation

time. A good seal of peri-implant soft tissue is an important factor influencing the peri-implant bone stability, thus dental implants prognosis. Nevertheless, it must be noted that a small significant soft tissue recession was found, at the end of the observation period, as it can be depicted in Fig. 6. This was probably due to the fact that tissue-level implants, with a 4.8 mm collar diameter, were used. Nowadays implants with a platform switching and/or a reduced diameter would be most likely preferred (Buser et al. 2013; Filippi et al. 2013).

Horizontal augmentation was also achieved whenever clinically necessary, but it was not calculated to simplify clinical measurements. A precise assessment of the amount of bone augmentation obtained remains demanding task due to the evident difficulties in measuring. A CT scan performed after surgery, as suggested by Sbordone et al. (2012), could make the measurement of the bone gain more reliable. It was, however, considered unnecessary and therefore in contrast with the ethical recommendation of the directive of the council of the European Communities about the responsible use of ionizing radiation in medicine (Fig. 7).

This study may be considered a preliminary paper to give an answer to the AO Consensus report (Aghaloo & Moy 2007), which emphasized the need to evaluate “the effectiveness of ridge augmentation techniques in the compromised patient.” Nevertheless, it cannot provide a definitive answer to the question of the ITI Consensus report (Chiapasco et al. 2009) if “surgical procedures, for example, reconstruction of atrophic edentulous mandibles with onlay autogenous bone grafts, improve long-term implant survival.”

In regard to patients' compliance, it is important to note that oral hygiene conditions were carefully evaluated before and after surgeries and probably account for the low levels of complications regarding possible infections, even in cases of PCPs.

The positive results of this study are in sharp contrast with the ones presented by Sbordone et al. (2012), who evaluated, by computerized tomography, the volume resorption of autogenous corticocancellous grafted bone, harvested from the ileum and used in alveolar horizontal and vertical augmentation procedures, followed by dental implants. The authors found a progressive and unavoidable bone resorption of almost all the grafted bone in the maxilla and mandible, although the reported survival rate at 6 years was 100%.

The results of this clinical investigation, indeed, suggest that vertical ridge augmentation, with intraoral autogenous bone, is predictable and does not go through major resorption. Implants, placed grafted sites, presented at 10-year minimal pocket depths, minimal signs of inflammation, and minimal bone loss, in most of the cases.

These considerations along with the results from this study favor the use of a delayed approach when using autogenous bone grafts and titanium implants for reconstruction of the severely atrophied

maxilla, in accordance with Cordaro et al. (2002), Chiapasco et al. 2012), Urban et al. (2015), Restoy-Lozano et al. (2015).

Even though the 4th EAO Consensus Conference (Sanz et al. 2015) stated that the placement of implants in vertically augmented bone rendered comparable outcomes with those of short implants in the treatment of the posterior mandible, but short implants resulted in fewer complications, the possible incidence of peri-implantitis may have important clinical implications, mainly in the short implant group.

Moreover, one of the greatest clinical challenges is the treatment of vertical defects in the esthetic area where short implants cannot be used, and the comparison between the two alternative techniques is not possible.

Moreover, according to the above-mentioned consensus (Sanz et al. 2015) the lack of attached and keratinized mucosa, especially in the posterior mandible, may pose a higher risk for the maintenance of healthy peri-implant tissues and crestal bone levels. In this group of patients, no implant was placed in the complete absence of keratinized mucosa and if necessary was added resulting in a relative stability of the tissues, from ± 1 mm to 1.9 ± 1.1 mm after 10 years.

Indeed, this procedure cannot be followed by every dentist on every patient. Several authors have investigated possible alternatives for less invasive procedures. However, according to Chiapasco et al. (2015), for example, fresh frozen bone does not represent a reliable alternative to autogenous bone blocks because of the higher rate of bone exposure and partial loss of the grafts, the lower implant survival, and the higher peri-implant bone resorption in FFB patients.

In conclusion, this technique can be represented as an important reference forward in the definition of ideal augmentation protocols, especially in clinical situations with reduced vertical bone on adjacent teeth.

References

Aghaloo, T.L. & Moy, P.K. (2007) Which hard tissue augmentation techniques are the most successful in furnishing bony support for implant placement? *The International Journal of Oral & Maxillofacial Implants* 22: 49–70.

Aloy-Prosper, A., Penarrocha-Oltra, D., Penarrocha-Diago, M.A. & Penarrocha-Diago, M. (2015) The outcome of intraoral onlay block bone grafts on alveolar ridge augmentations: a systematic review. *Medicina Oral Patologia Oral y Cirugia Bucal* 2: 251–258.

Bornstein, M.M., Schmid, B., Belser, U.C., Lussi, & Buser, D. (2005) Early loading of non-submerged titanium implants with a sandblasted and acid-etched surface. 5-year results of a prospective study in partially edentulous patients. *Clinical Oral Implants Research* 16: 631–638.

- Buser, D., Chappuis, V., Kuchler, U., Bornstein, M.M., Wittneben, J.G., Buser, R., Cavusoglu, Y. & Belser, U.C. (2013) Long-term stability of early implant placement with contour augmentation. *Journal of Dental Research* 92: 176–182.
- Buser, D., Janner, S.F.M., Wittneben, J.G., Bragger, U., Ramseier, C.A. & Salvi, G.E. (2012) 10-year survival and success rates of 511 titanium implants with a sandblasted and acid-etched surface: a retrospective study in 303 partially edentulous patients. *Clinical Implant Dentistry and Related Research* 14: 839–851.
- Carini, F., Longoni, S., Amosso, E., Paleari, J., Carini, S. & Porcaro, G. (2014) Bone augmentation with Timesh. Autologous bone versus autologous bone and bone substitutes. A systematic review. *Annali di Stomatologia Supplement* 2: 27–36.
- Cawood, J.I. & Howell, R.A. (1988) A classification of the edentulous jaws. *International Journal of Oral and Maxillofacial Surgery* 17: 232–236.
- Chiapasco, M., Casentini, P. & Zaniboni, M. (2009) Bone augmentation procedures in implant dentistry. *The International Journal of Oral & Maxillofacial Implants* 24: 237–259.
- Chiapasco, M., Casentini, P., Zaniboni, M. & Corsi, E. (2012) Evaluation of peri-implant bone resorption around Straumann Bone Level implants placed in areas reconstructed with autogenous vertical onlay bone grafts. *Clinical Oral Implants Research* 23: 1012–1021.
- Chiapasco, M., Di Martino, G., Anello, T., Zaniboni, M. & Romeo, E. (2015) Fresh frozen versus autogenous iliac bone for the rehabilitation of the extremely atrophic maxilla with onlay grafts and endosseous implants: preliminary results of a prospective comparative study. *Clinical Implant Dentistry and Related Research* 17(Supplement 1): e251–66.
- Cordaro, L., Sarzi Amade, D. & Cordaro, M. (2002) Clinical results of alveolar ridge augmentation with mandibular block bone grafts in partially edentulous patients prior to implant placement. *Clinical Oral Implants Research* 13: 103–111.
- Corinaldesi, G., Pieri, F., Sapigni, L. & Marchetti, C. (2009) Evaluation of survival and success rates of dental implants placed at the time of or after alveolar ridge augmentation with an autogenous mandibular bone graft and titanium mesh: a 3-to 8-year retrospective study. *International Journal of Oral and Maxillofacial Implants* 24: 1119–1128.
- De Stavola, L. & Tunkel, J. (2013) Results of vertical bone augmentation with autogenous bone block grafts and the tunnel technique: a clinical prospective study of 10 consecutively treated patients. *International Journal of Periodontics and Restorative Dentistry* 33: 651–659.
- Esposito, M., Grusovin, M.G., Felice, P., Karatzopoulos, G., Worthington, H.V. & Coulthard, P. (2009) Interventions for replacing missing teeth: horizontal and vertical bone augmentation techniques for dental implant treatment. *Cochrane Database Systematic Review* CD003607.

- Filippi, A., Higginbottom, F.L., Lambrecht, T., Levin, B.P., Meier, J.L., Rosen, P.S., Wallkamm, B., Will, C. & Rocuzzo, M. (2013) A prospective non interventional study to document implant success and survival of the Straumann Bone Level SLActive dental implant in daily dental practice. *Quintessence International Journal* 44: 499–512.
- Jung, R.E., Fenner, N., Hammerle, C.H.F. & Zitzmann, N.U. (2013) Long-term outcome of implants placed with guided bone regeneration (GBR) using resorbable and non-resorbable membranes after 12–14 years. *Clinical Oral Implants Research* 24: 1065–1073.
- Lutz, R., Neukam, F.W., Simion, M. & Schmitt, M.C. (2015) Long-term outcomes of bone augmentation on soft and hard-tissue stability: a systematic review. *Clinical Oral Implants Research* 26: 103–122.
- Milinkovic, I. & Cordaro, L. (2014) Are there specific indications for the different alveolar bone augmentation procedure for implant placement? A systemic review. *International Journal of Oral and Maxillofacial Surgery* 43: 606–625.
- Miyamoto, I., Funaki, K., Yamauchi, K., Kodama, T. & Takahashi, T. (2012) Alveolar ridge reconstruction with titanium mesh and autogenous particulate bone graft: computed tomography-based evaluations of augmented bone quality and quantity. *Clinical Implant Dentistry and Related Research* 2: 304–311.
- Mombelli, A. & Lang, N. (1998) The diagnosis and treatment of peri-implantitis. *Periodontology* 2000 17: 63–76.
- Poli, P.P., Beretta, M., Cicciu', M. & Maiorana, C. (2014) Alveolar ridge augmentation with titanium mesh. A retrospective clinical study. *The Open Dentistry Journal* 8: 148–158.
- Rasia dal Polo, M., Poli, P.P., Rancitelli, D., Beretta, M. & Carlo Maiorana, C. (2014) Alveolar ridge reconstruction with titanium meshes: a systematic review of the literature. *Medicina Oral Patologia Oral y Cirugia Bucal* 6: 639–646.
- Restoy-Lozano, A., Dominguez-Mompell, J.L., Infante-Cossio, P., Lara-Chao, J., Espin-Galvez, F. & Lopez-Pizarro, V. (2015) Reconstruction of mandibular vertical defects for dental implants with autogenous bone block grafts using a tunnel approach: clinical study of 50 cases. *International Journal of Oral and Maxillofacial Surgery*. 44: 1416–1422.
- Ricci, L., Perrotti, V., Ravera, L., Scarano, A., Piattelli, A. & Iezzi, G. (2013) Rehabilitation of deficient alveolar ridges using titanium grids before and simultaneously with implant placement: a systematic review. *Journal of Periodontology* 84: 1234–1242.
- Rocuzzo, M., Aglietta, M., Bunino, M. & Bonino, L. (2008) Early loading of sandblasted and acid-etched implants: a randomized controlled double-blind split-mouth study. Five-year results. *Clinical Oral Implants Research* 19: 148–152.

- Roccuzzo, M., Gaudio, L., Bunino, M. & Dalmaso, P. (2014) Long-term stability of soft tissues following alveolar ridge preservation: 10-year results of a prospective study around non submerged implants. *International Journal of Periodontics & Restorative Dentistry* 34: 795–804.
- Roccuzzo, M., Ramieri, G., Bunino, M. & Berrone, S. (2007) Autogenous bone graft alone or associated with titanium mesh for vertical alveolar ridge augmentation: a controlled clinical trial. *Clinical Oral Implants Research* 18: 286–294.
- Roccuzzo, M., Ramieri, G., Spada, M.C., Bianchi, S.D. & Berrone, S. (2004) Vertical alveolar ridge augmentation by means of a titanium mesh and autogenous bone grafts. *Clinical Oral Implants Research* 15: 73–81.
- Sanz, M., Donos, N., Alcoforado, G., Balmer, M., Gurzawska, K., Mardas, N., Milinkovic, I., Nisand, D., Rocchietta, I., Stavropoulos, A., Thoma, D.S. & Torsello, F. (2015) Therapeutic concepts and methods for improving dental implant outcomes. Summary and consensus statements. The 4th EAO Consensus Conference 2015. *Clinical Oral Implants Research* 26: 202–206.
- Sbordone, C., Toti, P., Guidetti, F., Califano, L., Santoro, A. & Sbordone, L. (2012) Volume changes of iliac crest autogenous bone grafts after vertical and horizontal alveolar ridge augmentation of atrophic maxillas and mandibles: a 6-year computerized tomographic follow-up. *Journal of Oral and Maxillofacial Surgery* 70: 2559–2565.
- Schmitt, C., Karasholi, T., Lutz, R., Wiltfang, J., Neukam, F.W. & Schlegel, K.A. (2014) Long term changes in graft height after maxillary sinus augmentation, onlay bone grafting, and combination of both techniques: a long-term retrospective cohort study. *Clinical Oral Implants Research* 25: 38–46.
- Tonetti, M.S. & Hammerle, C.H.F. (2008) Advances in bone augmentation to enable dental implant placement: consensus report of the sixth European workshop on periodontology. *Journal of Clinical Periodontology* 35: 168–172.
- Urban, I.A., Monje, A. & Wang, H.L. (2015) Vertical ridge augmentation and soft tissue reconstruction of the anterior atrophic maxillae: a case series. *International Journal of Periodontics and Restorative Dentistry* 35: 613–623.
- van Velzen, F.J.J., Ofec, R., Schulten, E.A.J.M. & ten Bruggenkate, C.M. (2015) 10-year survival rate and the incidence of peri-implant disease of 374 titanium dental implants with a SLA surface: a prospective cohort study in 177 fully and partially edentulous patients. *Clinical Oral Implant Research* 26: 1121–1128.

Table 1. Data on patients at baseline, treatment, implant sites, and 10-year outcomes

Patient	Age	Gender	PCP	Ti-mesh	Implant sites	Implant	Implant	Drop-out
1.	45	F	Yes	Yes	4.5 4.6	November	1	
2.	56	F		Yes	1.6 1.7	October 2001		
3.	60	F		Yes	3.4 3.5 3.6	March 2002		1
4.	52	F	Yes	Yes	4.4 4.5 4.6	September	1	
5.	50	F		Yes	4.4 4.5	May 2000		
6.	53	F	Yes	Yes	2.2 2.3	April 2001		
7.	50	M	Yes	Yes	4.6 4.7	April 2002		1
8.	41	M	Yes	Yes	4.5 4.6	September	1	
9.	21	M		Yes	1.2 1.3	June 2001		
10.	73	M		Yes	2.7	March 2000		1
11.	58	F		Yes	1.4 1.5	June 2001		1
12.	46	F		Yes	4.5 4.6 4.7	March 2002		
13.	39	F		Yes	4.6 4.7	January 2002		
14.	33	M		Yes	2.2	September		
15.	54	F	Yes	Yes	1.1 1.2	January 2002		
16.	48	M		Yes	1.6	October 2001		
17.	40	F		Yes	1.5 1.6 1.7	January 2002		
18.	51	F		Yes	4.5 4.6	February 2002		
19.	55	F		No	4.5 4.6	March 2004		
20.	60	F		No	3.4 3.5 3.6	March 2002		1
21.	68	F		Yes	1.4 1.5 1.6	October 2003		
22.	55	F	Yes	Yes	4.5 4.6 4.7	September		
23.	50	M	Yes	No	4.5 4.6	May 2004		
24.	40	F	Yes	Yes	4.5 4.6	February 2003		
25.	34	M		Yes	1.3	July 2004		1
26.	43	F		No	4.5 4.6	April 2005		
27.	55	M	Yes	Yes	2.4 2.5 2.6	September		
28.	51	F		Yes	4.5 4.6 4.7	March 2004		
29.	46	F	Yes	Yes	1.1 1.2	April 2004		
30.	55	M	Yes	No	1.3	June 2004		
31.	42	F	Yes	No	1.2 2.2	February 2003		
32.	50	F		Yes	4.6 4.7	February 2003		
§				No	3.5 3.6	February 2003		
33.	40	F		No	3.5	March 2004		
34.	37	M		Yes	1.4 1.5	September		

Table 2. Number of patients and implants lost to the 10-year follow-up

Patients	Implants	Reason for dropout
2	4	Death
1	2	Moved
3	8	Refused to accept a visit

Table 2. Number of patients and implants lost to the 10-year follow-up

	Patients	Implants	Reasons for drop-out
	2	4	Death
	1	2	Moved
	3	8	Refused to accept a visit
Total	6	14	

Table 3. Clinical parameters around the loaded implants at baseline and at 10 years after placement

	Baseline	10-year follow-up	<i>p</i>
PI	14.07 ± 14.0% 25 (0–25)	21.9 ± 25.8% 25 (0–25)	0.13
BOP	19.14 ± 14.60% 25 (0–25)	25.78 ± 23.97% 25 (0–25)	0.09
PD	3.12 ± 0.69 mm 3.00 (2.50–3.50) mm	3.26 ± 0.91 mm 3.00 (2.75–3.63) mm	0.58
KT	2.34 ± 1.00 mm 2 (2–3) mm	1.89 ± 1.11 mm 2 (1–3) mm	<0.001
BL		0.58 ± 0.57 mm 0.5 (0-1) mm	
REC		0.74 ± 0.68 mm 1 (0-1) mm	

Data are expressed both in mean ± SD and median (25–75 percentiles).

PI, Presence of dental plaque; BOP, Presence of bleeding on probing; PD, Mean probing depth; KT, Keratinized tissue width; BL, Interproximal bone Loss; REC, Soft-tissue recession

Table 4. Clinical parameters around the implants 10 years after treatment in both groups

	PHP (n = 18) (impl = 37)	PCP (n = 15) (impl = 27)	<i>p</i>
PI	39/148 (26.4%)	17/108 (15.7%)	0.22
BL (mm)	0.43 ± 0.50	0.78 ± 0.59	0.04
PD change (mm)	0.08 ± 0.51 1 (0–1)	0.21 ± 0.66 0 (0–1)	0.44
BOP	39/148 (26.4%)	27/108 (25.0%)	0.87
Implant loss	1/38 (2.6%)	3/30 (10.0%)	0.23

Data are expressed in mean ± SD and median (25–75 percentiles), or numbers (%).

PHP, Periodontally healthy patients; PCP, Periodontally compromised patients; n, number of patients; impl, number of implants; PI, Presence of dental plaque; BOP, Presence of bleeding on probing; PD, Mean probing depth; KT, Keratinized tissue width; BL, Interproximal bone Loss.

Fig. 1. Clinical view of vertical ridge defect, patient no. 29, as a consequence of periodontal disease.

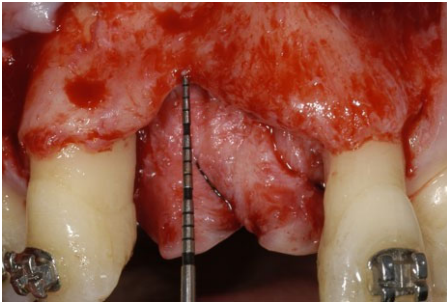


Fig. 2. Ti-mesh is fixed in order to contain and to protect the bone graft.

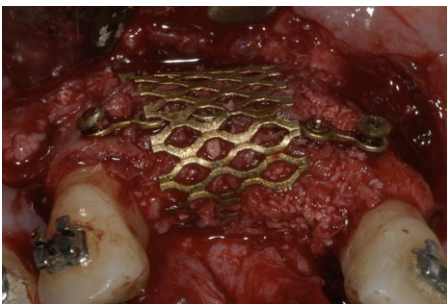


Fig. 3. Tension-free suture.

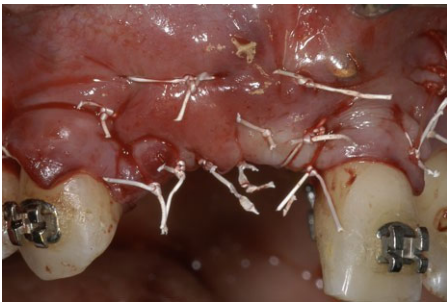

Fig. 4. Re-entry at 4 months after first surgery and non- submerged implants placement, significant vertical bone gain is evident.

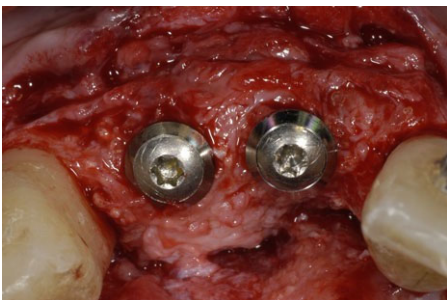


Fig. 5. Two porcelain-to-gold fused single crowns after cementation. This is considered the baseline

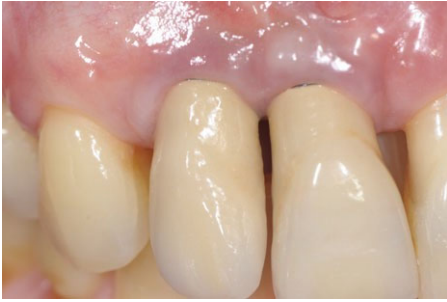

Fig. 6. Radiographic image at baseline.

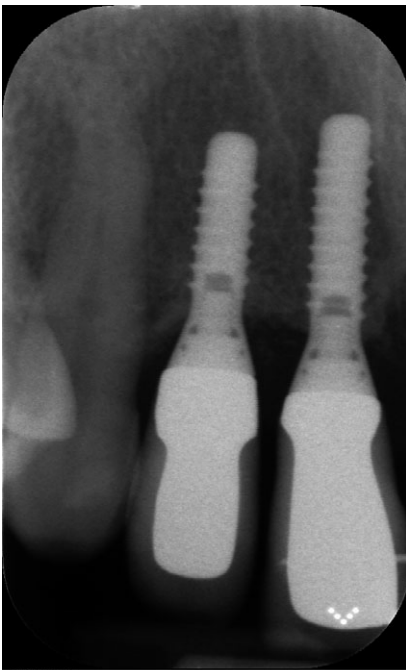


Fig. 7. 10-year follow-up clinical view, with minimal soft tissue recession.

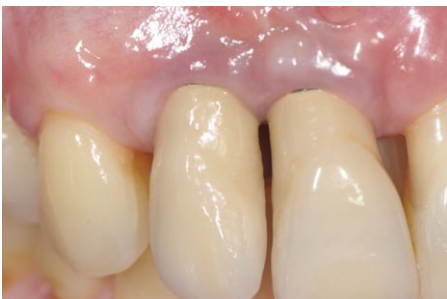

Fig. 8. Radiographic image at 10-year.

