Results of Cryoablation for Atrial Fibrillation Concomitant With Video-Assisted Minimally Invasive Mitral Valve Surgery

Results of cryoablation for atrial fibrillation concomitant with video-assisted minimally invasive mitral valve surgery

Giovanni Marchetto, Matteo Anselmino[*], Chiara Rovera[*], Samuel Mancuso, Davide Ricci, Marina Antolini*, Mara Morello*, Fiorenzo Gaita[*], Mauro Rinaldi.

Division of Cardiac Surgery, Department of Surgical Sciences, ñCittà della Salute e della Scienza di Torinoò Hospital, University of Turin, Italy

[*] Division of Cardiology, Department of Medical Sciences, ñCittà della Salute e della Scienza di Torinoò Hospital, University of Turin, Italy

Abstract word count: 241 words

No potential conflict of interest exist for all authors.

No funding was provided for this work.

Corresponding author:

Giovanni Marchetto, MD PhD

Email : giovanni.marchetto@libero.it

Department of Surgical Sciences, University of Turin

Division of Cardiac Surgery, Città della Salute e della Scienza Hospital,

Corso Bramante 88, 10126 Turin, Italy

Phone: +39-011-6335511 Fax: +39-011-6336130

GLOSSARY OF ABBREVIATIONS

- MIMVS: minimally invasive video-assisted mitral valve surgery
- AF: atrial fibrillation
- MV: mitral valve
- SR: sinus rhythm
- TOE: trans-oesophageal echocardiography
- PVs: pulmonary veins
- LA: left atrium
- PV: pulmonary vein
- ECG: electrocardiography
- SD: standard deviation
- PM: pace maker
- NYHA: New York Heart Association functional class
- OAC: oral anticoagulation
- SVC: superior vena cava
- LIPV: left inferior pulmonary vein
- LSPV: left superior pulmonary vein
- RIPV: right inferior pulmonary vein
- RSPV: right superior pulmonary vein

- IVC: inferior vena cava
- LV EF: left ventricular ejection fraction
- AP: antero-posterior
- SI: supero-inferior
- PAPs: systolic pulmonary artery pressure
- ACE-i: angiotensin-converting-enxyme inhibitor

Abstract

Objectives: Interest in minimally invasive video-assisted mitral valve surgery (MIMVS) is rapidly growing. Data on concomitant atrial fibrillation (AF) ablation to MIMVS are still lacking. The present study investigates the long-term results of AF cryoablation concomitant to MIMVS.

Methods: From October 2006 to September 2014, 68 patients with mitral valve (MV) disease (age 65.9±11.1 years, 34/68 males, Euroscore log 5.4±4.5) and drug resistant AF underwent MIMVS via right mini-thoracotomy and concomitant left sided AF endocardial cryoablation (Cryoflex Medtronic, Minneapolis, MN, USA). Patients were independently followed by cardiological outpatients visits and underwent electrophysiological study when indicated.

Results: Forty-four out of 68 patients (64.7%) underwent MV repair, 8/68 patients (11.8%) also received concomitant tricuspid valve surgery. One procedure was electively converted to full sternotomy (1.5%). Total clamp time was 97.6 ± 22.8 minutes. In March 2015, 60 patients were alive and completed the follow-up after a mean of 3.4±2.0 years following the procedure. Fourty eight patients (80%) presented sinus rhythm throughout the whole follow-up. Freedom from AF was respectively 96%, 87% and 72% at 1, 3 and 5 years. We recorded 2 pace-maker implants (3.3%). Three patients suffered symptomatic recurrences (2 atypical atrial flutter/1 atrial fibrillation) and underwent transcatheter ablation: all three patients remained in stable sinus rhythm for the remaining follow-up.

Conclusions: Given the favourable long term sinus rhythm maintenance rates of concomitant Cryoablation, MIMVS can also be offered to symptomatic AF patients. AF transcatheter ablation may easily avoid further symptomatic recurrences.

Key-words: atrial fibrillation, minimally invasive mitral, surgical ablation

Introduction

Interest in minimally invasive mitral valve (MV) surgery through a video-assisted mini-thoracotomy approach (MIMVS) is rapidly growing since when was first introduced in the mid-1990s [1]. A number of large studies have demonstrated the feasibility of performing MIMVS aiming to achieve similar safety and efficacy to conventional surgery with the added advantages of reduced trauma, improved cosmesis and shorter hospitalization [2,3].

Atrial fibrillation (AF) is the most common cardiac arrhythmia observed in clinical practice and confers an increased incidence of thromboembolic events and mortality [4]. A substantial increase in the incidence of AF has been reported in patients with indications for mitral valve surgery, and has also been demonstrated to be a profound risk factor for mortality [5]. The weight of this evidence has provided the impetus for the combination of surgical AF treatment and core cardiac surgical intervention, with the hope of synergistic improvements in both sinus rhythm (SR) maintenance and risk of morbidity and mortality [6, 7].

Concomitant surgical AF ablation and mitral valve surgery have proved to offer improved short- and mid-term SR maintenance compared to patients undergoing mitral valve surgery only. No differences were found between these two groups in terms of 30-day mortality, all-cause mortality, pacemaker implantation, stroke and thromboembolic events [8]. The advent of alternative energy sources has greatly simplified the original ñcut and sewò technique to create transmural lines transforming surgical ablation into an easier, safer and faster procedure to be associated to MIMVS [9, 10]. Recently published guidelines have called for long-term follow-up studies on this topic [11-14]. However data on follow-up after concomitant AF ablation to MIMVS are still missing. The present study investigates the long-term results of AF cryoablation concomitant to MIMVS.

Materials and methods

is. From October 2006 to September 2014,out of 781 MIMVS, the standard practice for MV disease in our Unit since October 2006, sixty-eight patients with concomitant drug resistant AF (13% paroxysmal, 87% persistent/long standing persistent) underwent video-assisted MIMVS via right mini-thoracotomy through the 4th intercostal space and concomitant left sided AF cryoablation (Cryoflex Medtronic, Minneapolis, MN, USA). Each patient in our study signed a written informed consent to undergo surgical or transcatheter procedures. Preoperative characteristics are summarized in Table 1. Patients that had already performed a cardiac surgical procedure or a previous transcatheter AF ablation were not included in this series. The analysis was conducted in an Academic medical center where patients accept to share their clinical data in an anonymous form. The study was observational and did not add treatment or modify conventional surgical procedure for the specific clinical indication. *Surgical procedure.* After a full preoperative work-up that included aorto-iliac angiography/CT scan, the most appropriate out of the following three MIMVS approaches was selected: direct aortic cannulation and endoaortic balloon occlusion (EndoDirect, Edwards Lifesciences, Irvine, CA); femoral arterial cannulation either with endoaortic ballon occlusion (EndoReturn, Edwards Lifesciences, Irvine, CA) or with transthoracic clamp (Chitwood Clamp, Scanlan International Inc, St Paul, MN). All patients underwent video-assisted right minithoracotomy through the 4th intercostal space (range 4-6 cm). Double lumen endotracheal ventilation, transoesophageal echo (TOE) and CO2 surgical field flooding were also used in all patients. Venous return was routinely obtained by double cannulation (jugular and femoral) and myocardial protection by cold crystalloid cardioplegia [15, 16].

Concomitant left sided AF cryoablation (Argon based Cryomaze, Cryoflex Medtronic, Minneapolis, MN, USA) consisted of isolation of the pulmonary veins (PVs) and of the posterior left atrial (LA) wall between the veins by a ñUò encircling cryolesion connected to the surgical paraseptal left atrial incision performed for mitral exposure, eventually creating the so-called ñbox lesionò (Figure 1). In

addition, a linear cryolesion (ñmitral lineò) was performed from the previously created ñbox lesionò to the mitral valve annulus to block conduction across the left atrial isthmus.

Electrophysiology study and transcatheter AF ablation. Under conscious sedation, and guided by a 3-dimensional electroanatomic mapping system (CARTO, Biosense Webster), the LA and PVs ostia were mapped measuring unipolar local voltage and detecting presence or not of PV isolation. In case of evidence of conduction gap between the PV and the atrium, antral pulmonary vein isolation was performed by radiofrequency ablation (Smartouch, Biosense Webster) aiming to complete PV isolation extending the surgical lesion set as demonstrated by circular mapping catheter (Lasso, Biosense Webster).

Clinical follow-up and event definition. After discharge patients were followed by cardiological outpatient visits as for lone AF transcatheter ablation protocol [11] including clinical examination and ECG at 3, 6, 12 months and then yearly. Holter monitoring was performed at least once in all patients. In case of symptom recurrence between follow up visits patients were reassessed by clinical examination, ECG and Holter monitoring. Electrophysiological study and transcatheter AF ablation were performed when indicated. Study period was closed in March 2015, all patients with at least 6 months follow up were included and reassessed with clinical examination, ECG and transthoracic Echocardiography.

Adverse events were classified according to the standardized definitions of the Society of Thoracic Surgeons/American Association of Thoracic Surgery/European Association of Cardiothoracic Surgery ñGuidelines for Reporting Morbidity and Mortality in Cardiac Valvular Operationsò and outcomes of AF cryoablation were reported following the HRS/EHRA/ECAS Expert Consensus Statement [11, 17]. A blanking period of three months was considered; following this interval any AF episode, persistent or paroxysmal, was registered as an event. All events were also classified as early (occurring within 30 days from the procedure) or late (>31 days after the procedure).

Statistical analysis. Categorical variables are reported as counts and percentages, while continuous variables as means and standard deviations (SD). Correlations between parameters and study groups were tested in cross tabulation tables by means of the Pearson Chi-Square or Fisherôs Exact Test and by one-way ANOVA respectively for categorical and continuous variables. McNemarôs test was used on paired categorical variables. Kaplan Meier curves were computed to describe AF free survival over time. A two sided p-value <0.05 was considered statistically significant; all analyses were performed with SPSS 20.0 (IBM Corp., Armonk, NY, USA)..

Results

Forty-four out of 68 patients (64.7%) underwent mitral valve repair. By pathology, repair rates were 32/37 (86.5%) degenerative, 11/15 (73.3%) functional, and 1/16 (0.6%) rheumatic. Eight patients (11.8%) received also concomitant tricuspid valve surgery (Table 2). One procedure was electively converted to full sternotomy (1.5%) due to unexpected severe pleural adhesions and had an uneventful postoperative course. Total clamp time was 97.6±22.8 minutes. There was no reopening for any cause. 23/68 patients (33.8%) suffered AF relapses during hospitalization, 62 patients were discharged from the Unit in SR (91.2%). One in-hospital minor stroke was recorded (1/68, 1.5%); no patients required PM implantation in the acute phase. Early mortality was 1/68 (1.5%, due to respiratory complications following cardiac arrest resuscitated in the Ward). In March 2015 60 patients completed the follow-up after a mean of 3.4±2.0 years following the procedure. Study flow chart following the procedure is depicted in Figure 2. In this time frame no patients required redo surgery; valve repair and replacement reported favourable results (no MR 43, 63.3%; <2+/4+ 25, 36.7%). Three patients suffered from minor stroke (4.4%), while 1 patient (who relapsed on the second day after surgery with permanent AF) had a stroke (1.5%). Two (3.3%) patients required PM implantation during follow-up. Figure 3a illustrates echocardiographic parameters and functional class at baseline and at end of follow-up. Notably mean pulmonary artery pressure (from

46.0 to 36.1, p=0.006), antero-posterior left atrial diameter (from 54.5 to 49.2, p=0.012) and NYHA functional class (from 2.6 to 1,2, p<0.001) significantly decreased. Medications at baseline or discharge and end of follow-up are shown in Figure 3b. At 1-year follow-up 50% of patients discontinued amiodarone. Compared to discharge, significantly less patients were prescribed amiodarone at follow-up (56,3% vs. 18,8%, p<0.001) while more patients assumed beta-blockers (9,4% vs 68,8%, p<0,001). Oral anticoagulants were discontinued in a significant proportion of patients (84,6% on OAC pre-surgery vs. 56,4% on OAC at follow-up, p<0.001); in particular, 13/60 (21.7%) patients discontinued OAC at 1-year follow-up. At 1-year follow-up freedom from AF recurrences was 94.8%. Forty-eight patients (80%) presented SR throughout the whole follow up. Out of the 12 patients (20%) suffering relapses, 7 patients (58.3%) suffered paroxysmal episodes while 5 (41.7%) presented persistent AF (Figure 2). Seven patients (58.3%) relapsed as atypical atrial flutter while 5 (41.7%) as atrial fibrillation. Overall, three patients suffered symptomatic recurrences (2 atypical atrial flutter, 1 atrial fibrillation) and an electrophysiological study was indicated and performed in these patients (Figure 4). In two cases arrhythmia was sustained outside the lesion set while in one case a conduction gap was recorded. Following transcatheter ablation all three patients resulted in sinus rhythm for the remaining follow up. Freedom from AF relapses, stratified by AF type, is reported in Figure 5. Table 1 also describes preoperative characteristics of the patients population completing follow-up stratified by AF relapses at univariate analysis, highlighting that AF characteristics before the surgical ablation (if paroxysmal or persistent/long-standing persistent) and NYHA class seem to significantly predict relapses.

Discussion

The main finding of the present study is that concomitant surgical video-assisted left sided AF cryoablation creating a box lesion plus a mitral line during MIMVS resulted in favourable long-term sinus rhythm maintenance rates. Out of all, only three patients suffered symptomatic

recurrences, with ECG documentation of atypical atrial flutter in two cases and AF in one. Following transcatheter ablation, patients resulted in sinus rhythm for the remaining follow-up. Based on the present experience, therefore, in the remote case of symptomatic arrhythmia relapses, AF transcatheter ablation completing the surgical lesion set seems to easily avoid further recurrences.

The cut-and-sew Cox-Maze III procedure has been the gold standard for surgical AF treatment and has proved to be effective at eliminating the arrhythmia [18]. In recent years the development of ablation technologies has dramatically changed the field of AF surgical ablation by the introduction of new techniques and energy sources [8,9,10], allowing the replacement of the surgical incisions with the linear ablation lines, transforming a technically complex procedure into an accessible and minimally invasive approach. Differently from paroxysmal AF, in which triggers from the pulmonary veins play an important role in the initiation of AF, in non-paroxysmal AF, atrial substrate modification is thought to be highly relevant [19]. This is especially true for patients with valvular heart disease, in which a dilated and remodeled atrium is present. In fact, previous studies have shown that mechanisms as the elongation and stretch of the atrial fibers and the presence of atrial fibrosis are crucial in the initiation and maintenance of AF in such a patients [20]. Therefore, procedures aiming to isolate the PVs and to permanently modify the atrial substrate with the creation of transmural linear lesions are indeed promising.

The principal shortcomings of the use of minimal access techniques is that, due to potential suboptimal exposure, they may lead to an excess of simplification in the lesion set and potentially increase the possibility of conduction gaps. In this context, electrophysiological validation may permit electrical evaluation of the surgical ablation and allows to perform additional transcatheter ablation when necessary [21-23]. In fact, new hybrid approaches, combining minimally invasive surgical and percutaneous ablation are emerging [24].

Cryoablation during concomitant cardiac surgical procedures in sternotomy has appeared to be safe and effective [25]. Recently Gaita et al. reported that on patients with long-standing persistent AF and valvular heart disease, an hybrid approach including surgical cryoablation in sternotomy patients, consisting of pulmonary veins isolation and left atrial linear lesions combined with consequent transcatheter radiofrequency ablation was highly effective in maintaining very long-term follow-up SR [24]. However, in this experience 21.2% of the patients needed transcatheter ablation touch-ups to eliminate conduction gaps and to complete atrial lines. In the present study safe and reproducible transmural lesions set in a bloodless surgical field, was achieved by an endocardial argon-based cooling cryoablation system with a flexible, easily adaptable to patientôs anatomy cryoprobe (ī 160°C for 120 seconds) without the need of consequent transcatheter touch-ups in the vast majority of the cases.

Another important issue regards the thromboembolic complications during follow up. Literature reports an annual stroke rate in surgically treated valvular patients varying from 0.8% to 3%. This thromboembolic risk is higher if AF is present [26,27]. In the present population, three patients experienced a minor stroke and one patient had a stroke during the follow-up, giving an overall annual rate of 1.7%. The maintenance of SR seems, therefore, to act as a protective factor against stroke, even in a population with surgical valvular heart disease in which the risk for thromboembolic events is inherently increased.

Eventually, although surely influenced also by the concomitant MV surgery, minimally invasive AF cryoablation resulted to impact favourably the natural history of patients with MV disease and drug resistant symptomatic AF as shown by a significant reduction of NYHA class, and discontinuation of amiodarone and oral anticoagulants at follow up.

Conclusions

Surgical cryoablation concomitant to MIMVS resulted to be highly effective in maintaining SR and reducing AF burden on long-term follow-up. Based on the present study population a minimally invasive approach can also be offered to symptomatic AF patients. In the remote case of symptomatic arrhythmia relapses, AF transcatheter ablation may easily avoid further recurrences.

Study limitations

The following limitations must be taken in account. First, this report is a observational study and may therefore be biased by patient selection by physician in charge. Second, the limited sample size may have influenced the statistical power of the analysis. Third the limited clinical events did not permit multivariate analysis to detect independent inference of the study parameters. Fourth, the follow-up of our study was mostly ECG-based. Being aware that a monitoring based on serial 24h ECG Holter tracings or, even better, implantable recorders would be more accurate, in a mostly persistent AF setting, consideration of any AF relapse, also those present only once during the follow up should limit event underestimation. Eventually, given that the surgical approach described is the standard and the only performed for this specific indication in our Center, no comparison group is available.

References

[1] Chitwood WR Jr, Wixon CL, Elbeery JR, et al. Video-assisted minimally invasive mitral valve surgery. J Thorac Cardiovasc Surg 1997;114:773-80.

[2] McClure RS, Athanasopoulos LV, McGurk S, et al. One thousand minimally invasive mitral valve operations: early outcomes, late outcomes, and echocardiographic follow-up. J Thorac Cardiovasc Surg 2013;145:1199-206.

[3] Sündermann SH, Sromicki J, Rodriguez Cetina Biefer H, Seifert B, Holubec T, Falk V, Jacobs S. Mitral valve surgery: right lateral minithoracotomy or sternotomy? A systematic review and

meta-analysis. J Thorac Cardiovasc Surg. 2014 Nov;148(5):1989-1995.e4. doi: 10.1016/j.jtcvs.2014.01.046. Epub 2014 Feb 5.

[4] Ehrlich JR, Hohnloser SH. Milestones in the management of atrial fibrillation. Heart Rhythm. 2009 Nov;6(11 Suppl):S62-7.

[5] Saxena A, Dinh D, Dimitriou J, et al. Preoperative atrial fibrillation is an independent risk factor for mid-term mortality after concomitant aortic valve replacement and coronary artery bypass graft surgery. Interact Cardiovasc Thorac Surg 2013;16:488-94.

[6] Kevin Phan1, Ashleigh Xie1, David H. Tian1, Kasra Shaikhrezai1,2, Tristan D. Yan1 Systematic review and meta-analysis of surgical ablation for atrial fibrillation during mitral valve surgery. ACS Vol 3, No 1 (January 2014).

[7] Stulak JM, Schaff HV. The cardiac surgeon as electrophysiologist. J Thorac Cardiovasc Surg. 2015 Sep 28. pii: S0022-5223(15)01807-3. doi: 10.1016/j.jtcvs.2015.09.098.

[8] Edgerton ZJ, Edgerton JR. A review of current surgical treatment of patients with atrial fibrillation. Proc (Bayl Univ Med Cent) 2012;25:218-23.

[9] Williams MR, Garrido M, Oz MC, et al. Alternative energy sources for surgical atrial ablation. J Card Surg 2004;19:201-6.

[10] Phan K, Xie A, La Meir M, Black D, Yan TD. Surgical ablation for treatment of atrial fibrillation in cardiac surgery: a cumulative meta-analysis of randomised controlled trials. Heart. 2014 May;100(9):722-30.

[11] Calkins, H., Kuck, K.H., Cappato, R. et al. 2012 HRS/EHRA/ECAS expert consensus statement on catheter and surgical ablation of atrial fibrillation: recommendations for patient selection, procedural techniques, patient management and follow-up, definitions, endpoints, and research trial design: a report of the Heart Rhythm Society (HRS) Task Force on Catheter and Surgical Ablation of Atrial Fibrillation. Heart Rhythm. 2012; 9: 632ï 696.

[12] Camm, A.J., Lip, G.Y., De Caterina, R. et al. 2012 focused update of the ESC Guidelines for the management of atrial fibrillation: an update of the 2010 ESC Guidelines for the management of atrial fibrillation. Eur Heart J. 2012; 33: 2719ï 2747.

[13] Craig T. January; L. Samuel Wann; Joseph S. Alpert; Hugh Calkins; Joseph C. Cleveland; Joaquin E. Cigarroa et al. 2014 AHA/ACC/HRS Guideline for the Management of Patients With Atrial Fibrillation. J Am Coll Cardiol. 2014; S0735-1097(14)01739-2.

[14] M. Anselmino, F. DôAscenzo, G. Amoroso, F. Ferraris, F. Gaita. History of transcatheter atrial fibrillation ablation. J Cardiovasc Med 2012; 13(1):1-8.

[15] Marchetto G, D'Armini AM, Rinaldi M, Viganò M. Portaclamp in video-assisted minimally invasive cardiac surgery: surgical technique and preliminary clinical experience. Eur J Cardiothorac Surg. 2005 Jun;27(6):1122-4. Epub 2005 Apr 9.

[16] Barbero C, Ricci D, El Qarra S, Marchetto G, Boffini M, Rinaldi M. Aortic cannulation system for minimally invasive mitral valve surgery. J Thorac Cardiovasc Surg. 2015 Jun;149(6):1669-72. doi: 10.1016/j.jtcvs.2015.02.040. Epub 2015 Feb 26.

[17] Cary W. Akins, D. Craig Miller, Marko I. Turina, Nicholas T. Kouchoukos, Eugene H. Blackstone, Gary L. Grunkemeier, Johanna J.M. Takkenberg, Tirone E. David, Eric G. Butchart,David H. Adams, David M. Shahian, Siegfried Hagl, John E. Mayer and Bruce W. Lytle. Guidelines for reporting mortality and morbidity after cardiac valve interventions. Eur J Cardiothorac Surg (2008) 33 (4): 523-528.

[18] Cox, J.L., Schuessler, R.B., D'Agostino, H.J. Jr. et al. The surgical treatment of atrial fibrillation. III. Development of a definitive surgical procedure. J Thorac Cardiovasc Surg. 1991; 101: 569ï 583.

[19] Gaita, F., Caponi, D., Scaglione, M. et al. Long-term clinical results of 2 different ablation strategies in patients with paroxysmal and persistent atrial fibrillation. Circ Arrhythm Electrophysiol. 2008; 1: 269ï 275.

[20] Nattel, S., Burstein, B., and Dobrev, D. Atrial remodeling and atrial fibrillation: mechanisms and implications. Circ Arrhythm Electrophysiol. 2008; 1: 62ï 73.

[21] Gaita, F., Riccardi, R., Caponi, D. et al. Linear cryoablation of the left atrium versus pulmonary vein cryoisolation in patients with permanent atrial fibrillation and valvular heart disease: correlation of electroanatomic mapping and long-term clinical results. Circulation. 2005; 111: 136ï 142.

[22] F. D'Ascenzo, A. Corleto, G. Biondi-Zoccai, M. Anselmino, MD, L. Di Biase, A. Natale, R.J. Hunter, J. Schilling, S. Miyazaki, H. Tada, K. Aonuma, L. Yenn-Jiang, H. Tao, C. Ma, D. Packer, S. Hammill, F. Gaita, MD. Which are the most reliable predictors of recurrence of Atrial Fibrillation after transcatheter ablation? A meta-analysis. Int J Cardiol 2013; 167(5):1984-9.

[23] Gehi, A.K., Paul Mounsey, J., Pursell, I. et al. Hybrid epicardial-endocardial ablation using a pericardioscopic technique for the treatment of atrial fibrillation. Heart Rhythm. 2013; 10: 22ï 28.

[24] Fiorenzo Gaita, MDemail, Elisa Ebrille, MD, Marco Scaglione, MD, Domenico Caponi, MD, Lucia Garberoglio, MD, Laura Vivalda, MD, Alessandro Barbone, MD, PhD, Roberto Gallotti, MD. Very Long-Term Results of Surgical and Transcatheter Ablation of Long-Standing Persistent Atrial Fibrillation The Annals of Thoracic Surgery Volume 96, Issue 4, Pages 1273ï 1278.

[25] Mack, C.A., Milla, F., Ko, W. et al. Surgical treatment of atrial fibrillation using argon-based cryoablation during concomitant cardiac procedures. Circulation. 2005; 112: I1ï I6.

[26] Bando, K., Kobayashi, J., Hirata, M. et al. Early and late stroke after mitral valve replacement with a mechanical prosthesis: risk factor analysis of a 24-year experience. J Thorac Cardiovasc Surg. 2003; 126: 358ï 364.

[27] Medi, C., Hankey, G.J., and Freedman, S.B. Stroke risk and antithrombotic strategies in atrial fibrillation. Stroke. 2010; 41: 2705ï 2713.

Figure Legends

Central Picture (same as Fig. 2): Study flow chart. AF: atrial fibrillation; EP: electrophysiological.

Figure 1. Anatomy of the left atrium following a para-septal atriotomy for exposure of the mitral valve using a left atrial lift system. Cryoablation lesion set performed in the study population connected to the left atriotomy thus creating a ñbox lesionò, plus the mitral cryoline. SVC, superior vena cava; LIPV, left inferior pulmonary vein; LSPV, left superior pulmonary vein; RSPV, right superior pulmonary vein; RIPV, right inferior pulmonary vein; IVC, inferior vena cava. (Modified from Illustrated techniques for performing the Cox-Maze IV procedure through a right mini-thoracotomy, RJ Damiano Jr et al, ACS Vol 3, No 1)

Figure 2. Study flow chart. AF: atrial fibrillation; EP: electrophysiological.

Figure 3. (A) Echocardiographic parameters and functional class at baseline and end of follow-up within patients completing the 3.4 ±2.0 year follow-up. P value by Pearson Chi-Square/Fisherôs Exact Test or ANOVA. LV EF, left ventricular ejection fraction; AP, antero-posterior; SI, supero-inferior; PAPs, systolic pulmonary artery pressure; NYHA, New York Heart Association functional class. **(B)** Medications at discharge and end of follow-up in patients completing the 3.4 ±2.0 year follow-up. P value by McNemarôs test. ACE-i, angiotensin-converting-enzyme inhibitor; OAC, oral anticoagulation. * indicates comparison between pre-surgery and follow-up.

Figure 4. 3D electroanatomic reconstruction views: **(A)** Anteroposterior and leftlateral 3-D electroanatomic reconstruction view of the left atrium and pulmonary veins showing site of radiofrequency ablation (red dots) from the anterior portion of right superior pulmonary vein and the septal mitral isthmus and from the left inferior pulmonary vein and the lateral mitral isthmus. **(B)** Posteroanterior and right oblique (30°) 3-D electroanatomic reconstruction view of the left atrium and pulmonary veins showing absence of electrical activity on all the posterior wall (effect of surgical ñbox lesionò; upper part) and site of radiofrequency ablation (white dots) at the anterior

portion of the right superior pulmonary vein (site of conduction gap; lower part). **(C)** Anteroposterior and leftlateral 3-D electroanatomic reconstruction view of the left atrium and pulmonary veins showing the electrophysiological substrate and the site of radiofrequency ablation (red dots).

Figure 5. Kaplan Meier curves for survival free from AF (persistent AF; persistent and/or paroxysmal A)

Figure 1.

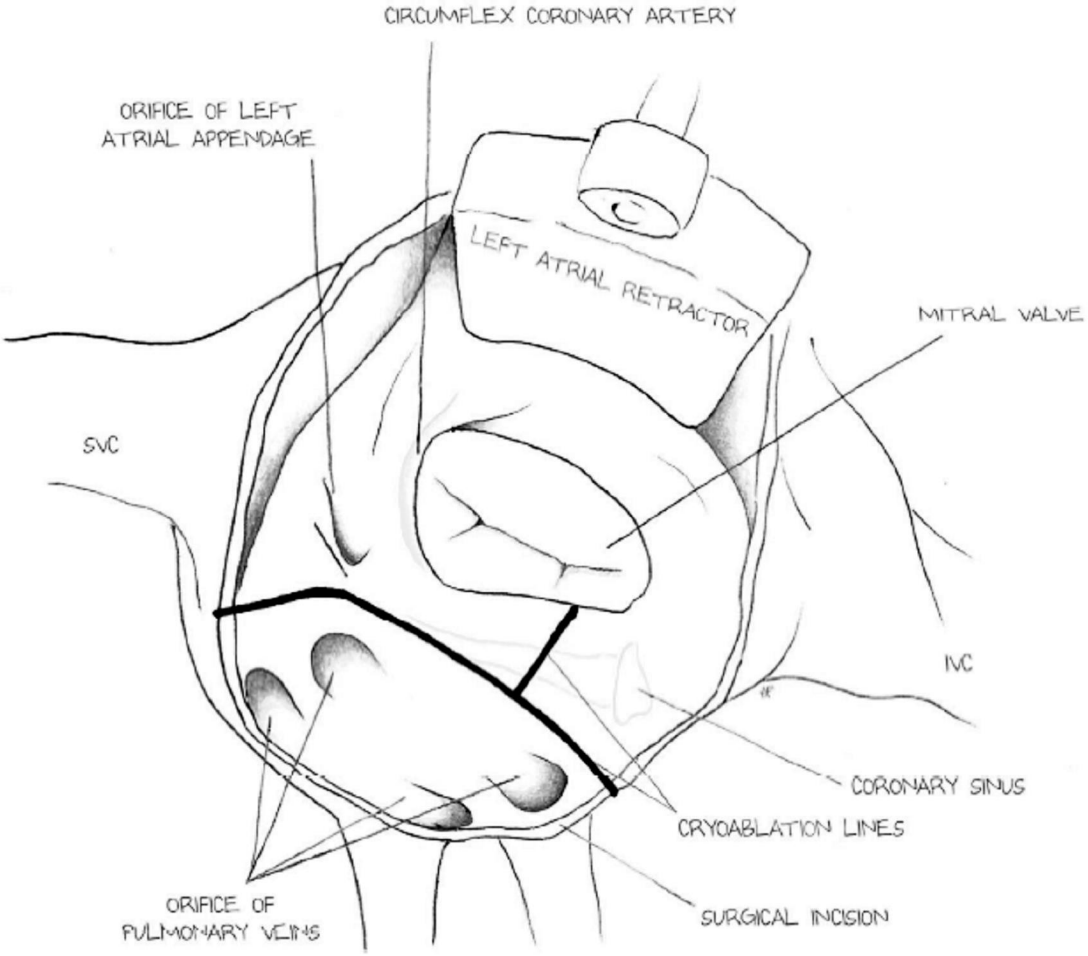
CIRCUMFLEX CORONARY ARTERY
ORIFICE OF LEFT ATRIAL APPENDAGE
LEFT ATRIAL RETRACTOR
MITRAL VALVE
SVC
IVC
CORONARY SINUS
CRYOABLATION LINES
SURGICAL INCISION
ORIFICE OF PULMONARY VEINS

Figure 2.

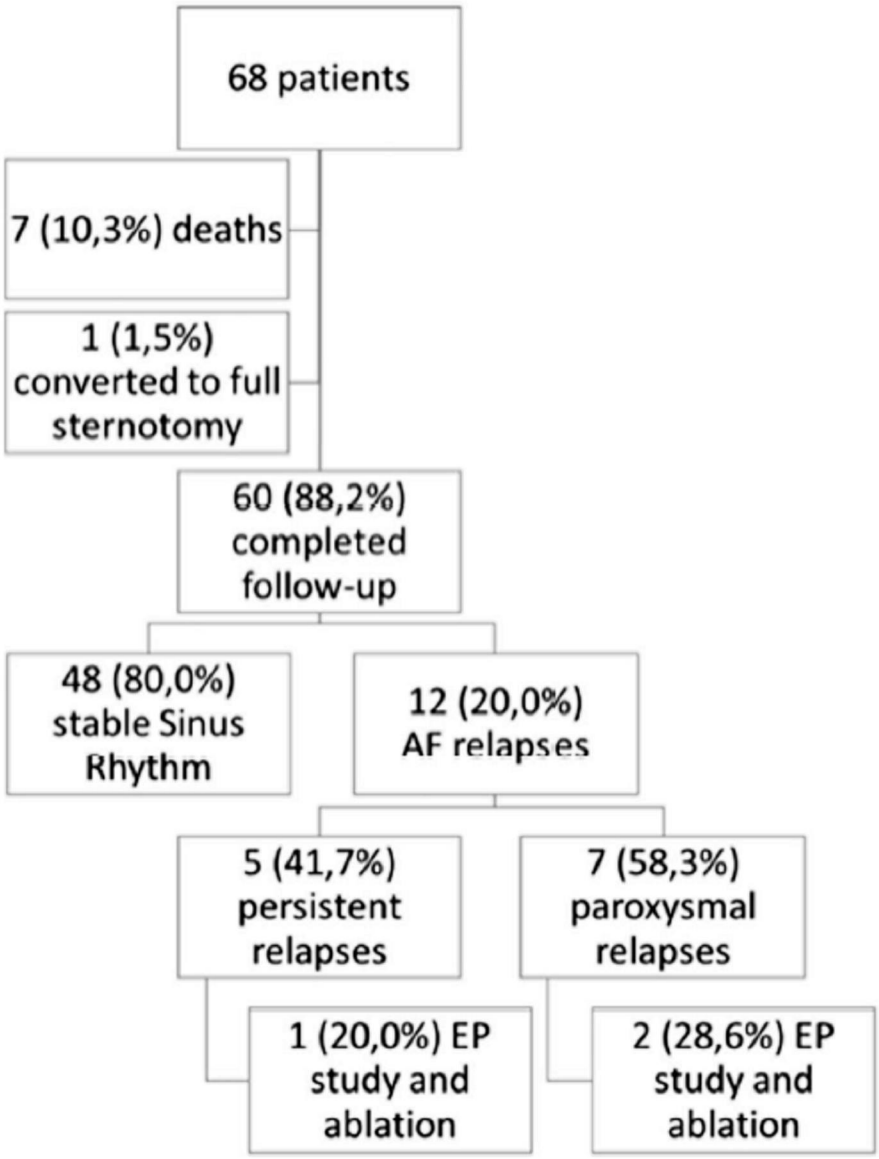
68 patients
7 (10,3%) deaths
1 (1,5%) converted to full sternotomy
60 (88,2%) completed follow-up
48 (80,0%) stable Sinus Rhythm
12 (20,0%) AF relapses
5 (41,7%) persistent relapses
7 (58,3%) paroxysmal relapses
1 (20,0%) EP study and ablation
2 (28,6%) EP study and ablation

Figure 3.

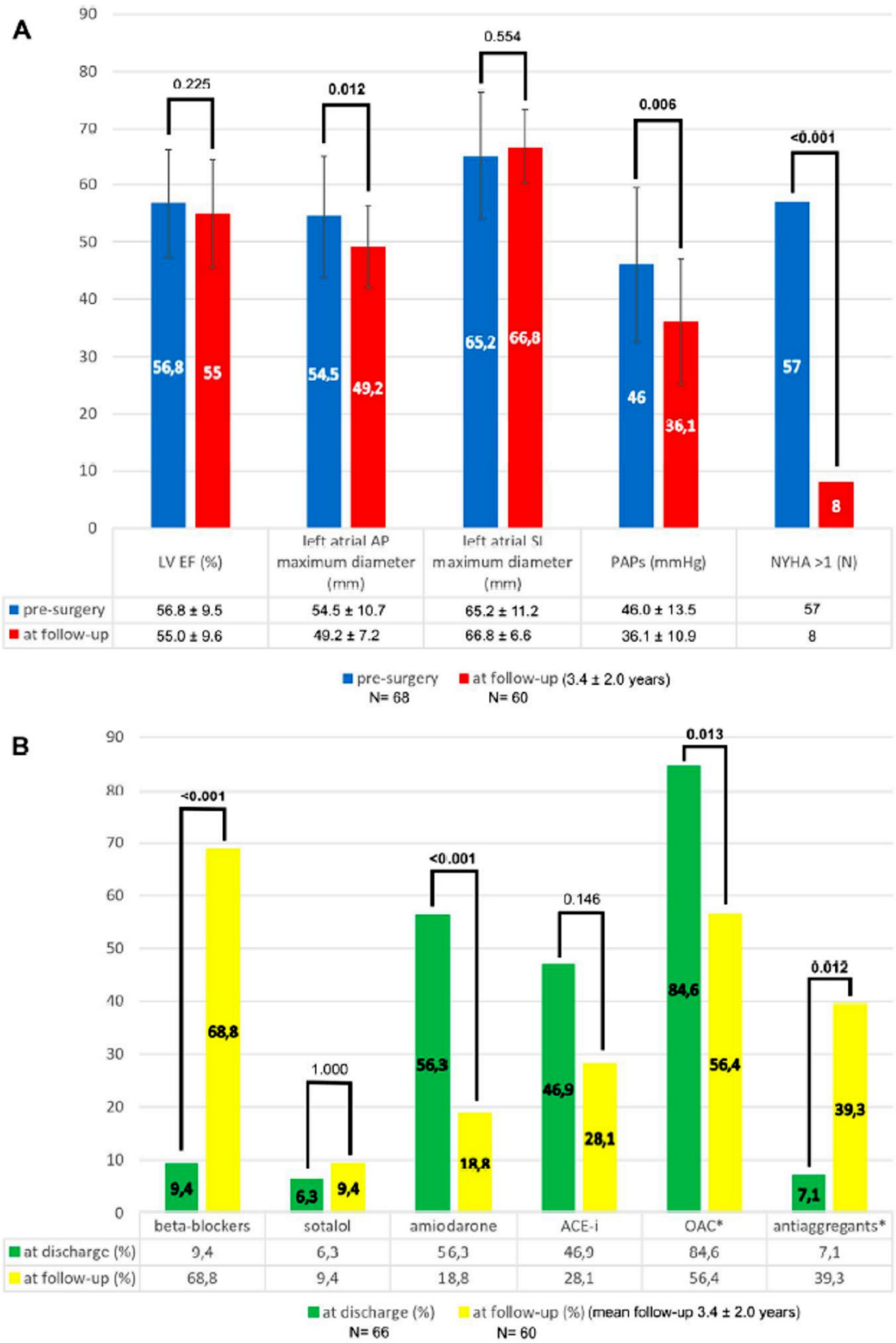
A
90
80
70
60
50
40
30
20
10
0
0.225
0.012
0.554
0.006
<0.001
56,8
55
54,5
49,2
65,2
66,8
46
36,1
57
8
LV EF (%)
left atrial AP maximum diameter (mm)
left atrial SI maximum diameter (mm)
PAPs (mmHg)
NYHA >1 (N)
pre-surgery 56.8 ± 9.5 54.5 ± 10.7 65.2 ± 11.2 46.0 ± 13.5 57
at follow-up 55.0 ± 9.6 49.2 ± 7.2 66.8 ± 6.6 36.1 ± 10.9 8
pre-surgery N= 68
at follow-up (3.4 ± 2.0 years) N= 60
B
90
80
70
60
50
40
30
20
10
0
<0.001
1.000
<0.001
0.146
0.013
0.012
9,4
68,8
6,3
9,4
56,3
18,8
46,9
28,1
84,6
56,4
7,1
39,3
beta-blockers
sotalol
amiodarone
ACE-i
OAC*
antiaggregants*
at discharge (%) 9,4 6,3 56,3 46,9 84,6 7,1
at follow-up (%) 68,8 9,4 18,8 28,1 56,4 39,3
at discharge (%) N= 66
at follow-up (%) (mean follow-up 3.4 ± 2.0 years) N= 60

Figure 4.

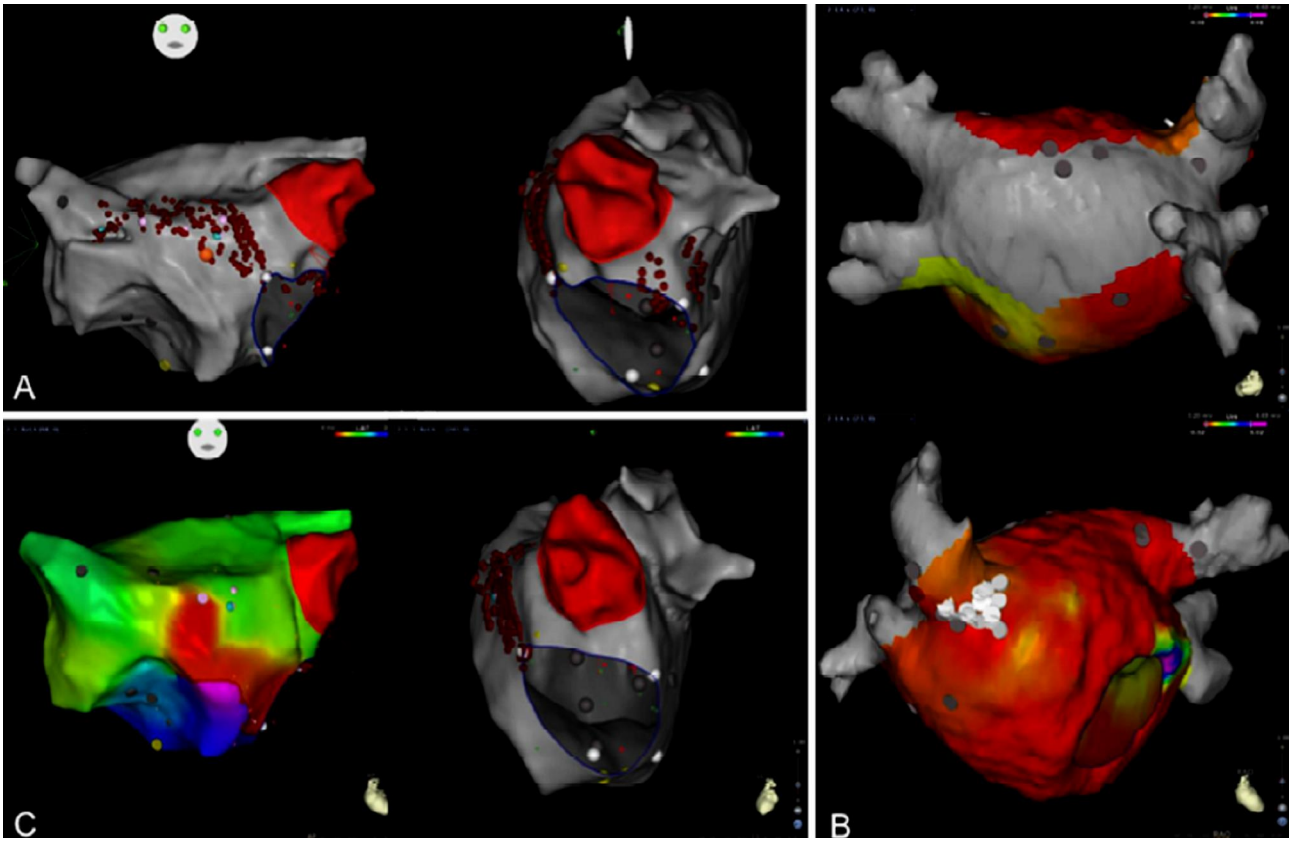

Figure 5.

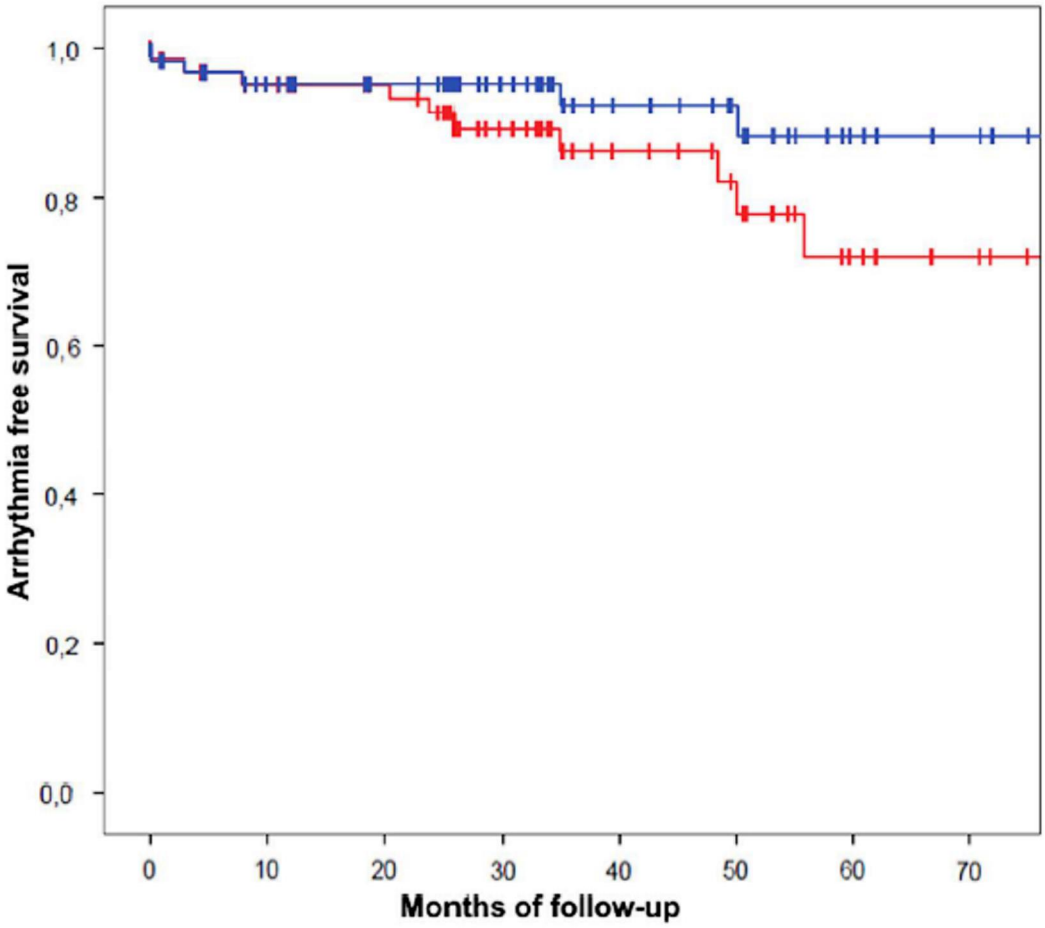

Patients at risk								
Persistent AF relapse	68	58	52	40	29	23	13	10
AF relapse	68	57	51	36	25	19	10	7