

AperTO - Archivio Istituzionale Open Access dell'Università di Torino

Favorable short-term outcome of hepatitis C virus-positive liver graft with bridging fibrosis: A plea for very early viral eradication

This is a pre print version of the following article:

Original Citation:

Availability:

This version is available <http://hdl.handle.net/2318/1627479> since 2017-06-08T00:14:10Z

Published version:

DOI:10.1002/hep.28978

Terms of use:

Open Access

Anyone can freely access the full text of works made available as "Open Access". Works made available under a Creative Commons license can be used according to the terms and conditions of said license. Use of all other works requires consent of the right holder (author or publisher) if not exempted from copyright protection by the applicable law.

(Article begins on next page)

Favorable short-term outcome of HCV-positive liver graft with bridging fibrosis: a plea for very early viral eradication

Journal:	<i>Hepatology</i>
Manuscript ID	HEP-16-1786.R1
Wiley - Manuscript type:	Clinical Observations in Hepatology
Date Submitted by the Author:	24-Oct-2016
Complete List of Authors:	<p>Martini, Silvia; AOU Città della Salute e della Scienza di Torino, University of Torino, Gastrohepatology Unit</p> <p>Salizzoni, Mauro; AOU Città della Salute e della Scienza di Torino, University of Torino, Liver Transplantation Center and General Surgery 2U</p> <p>David, Ezio; AOU Città della Salute e della Scienza di Torino, University of Torino, Pathology Unit</p> <p>Tandoi, Francesco; AOU Città della Salute e della Scienza di Torino, University of Torino, Liver Transplantation Center and General Surgery 2U</p> <p>Fonio, Paolo; AOU Città della Salute e della Scienza di Torino, University of Torino, Radiology Unit</p> <p>Delsedime, Luisa; AOU Città della Salute e della Scienza di Torino, University of Torino, Pathology Unit</p> <p>Strona, Silvia; AOU Città della Salute e della Scienza di Torino, University of Torino, Gastrohepatology Unit</p> <p>Dell'Olio, Dominic; AOU Città della Salute e della Scienza di Torino, Regional Transplantation Center, Piedmont</p> <p>Saracco, Giorgio; AOU Città della Salute e della Scienza di Torino, University of Torino, Gastrohepatology Unit</p> <p>Romagnoli, Renato; AOU Città della Salute e della Scienza di Torino, University of Torino, Liver Transplantation Center and General Surgery 2U</p>
Keywords:	Organ shortage, Liver fibrosis, Direct-acting antiviral agents, HCV-positive donor liver

1
2
3 **Favorable short-term outcome of HCV-positive liver graft with bridging fibrosis: a**
4
5 **plea for very early viral eradication**
6
7

8
9 Silvia Martini¹, Mauro Salizzoni², Ezio David³, Francesco Tandoi²,
10
11 Paolo Fonio⁴, Luisa Delsedime³, Silvia Strona¹, Dominic Dell Olio⁵,
12
13
14 Giorgio Maria Saracco¹, Renato Romagnoli²
15

16
17
18 ¹Gastrohepatology Unit
19

20
21 ²Liver Transplantation Center and General Surgery 2U
22

23 ³Pathology Unit
24

25 ⁴Radiology Unit
26

27
28 ⁵Regional Transplantation Center, Piedmont
29

30
31
32 AOU Città della Salute e della Scienza di Torino, University of Torino, Italy
33
34

35
36 **Authors' e-mail**
37

38 Silvia Martini: smartini@cittadellasalute.to.it
39

40 Mauro Salizzoni: mauro.salizzoni@unito.it
41

42 Ezio David: ezio.david@unito.it
43

44 Francesco Tandoi: francesco.tandoi@gmail.com
45

46 Paolo Fonio: paolo.fonio@unito.it
47

48 Luisa Delsedime: ldelsedime@cittadellasalute.to.it
49

50 Silvia Strona: silvia.strona@gmail.com
51

52 Dominic Dell Olio: dellolio@hotmail.com
53

54 Giorgio Maria Saracco: giorgiomaria.saracco@unito.it
55

56 Renato Romagnoli: renato.romagnoli@unito.it
57
58
59
60

Keywords

Organ shortage; HCV-positive donor liver; liver fibrosis; direct-acting antiviral agents.

Contact Information

Silvia MARTINI, MD

Gastrohepatology Unit, AOU Città della Salute e della Scienza di Torino

Corso Bramante 88, 10126 Turin, Italy

Phone: +39 011 6335928; Fax: +39 011 6334014

E-mail: smartini@cittadellasalute.to.it

List of Abbreviations

LT, liver transplantation; HCV, hepatitis C virus; MELD, Model for End-stage Liver Disease; CIT, cold ischemia time; DAA, direct-acting antiviral agents; US, ultrasound; GGT, gamma-glutamyltransferase; HBV, hepatitis B virus; SVR12, sustained virological response at week 12 after end of therapy; kPa, kilopascal.

Financial Support

The authors did not receive any grant or financial support for this work.

Summary

We report the first case of an HCV-positive recipient who was transplanted with an HCV-positive graft with portal-portal bridging fibrosis. Curbing HCV infection immediately after liver transplant with direct-acting antivirals, resulted in an excellent 9-month outcome.

For Peer Review

1
2
3
4
5
6
7
8
9
10
11
12
13
14
15
16
17
18
19
20
21
22
23
24
25
26
27
28
29
30
31
32
33
34
35
36
37
38
39
40
41
42
43
44
45
46
47
48
49
50
51
52
53
54
55
56
57
58
59
60

1
2
3
4
5 Persistent organ shortage in liver transplantation (LT) forces transplant centers to use
6 extended criteria donors. In this setting, hepatitis C virus (HCV)-positive livers represent a
7 precious resource, but their use has been so far restricted to those with fibrosis stage ≤ 2
8 according to Ishak (i.e. absence of bridging fibrosis), pending studies on fibrosis
9 progression in grafts at more advanced stage (1). The same indication accrued from our
10 own experience(2). In 1998 we used a 45-year-old HCV-positive graft having bridging
11 fibrosis (staging 3/6, Ishak) in an HCV-positive recipient, Model for End-stage Liver
12 Disease (MELD) 19 at LT; cold ischemia time (CIT) was 689 minutes and the patient
13 experienced delayed non-function (prolonged ascites with progressive cholestasis),
14 requiring re-LT on day 75.

15
16 However, the recent advent of direct-acting antivirals (DAA) has revolutionized HCV
17 therapy (3) and changes in the outcome of HCV-positive grafts can be expected.

18
19 On December 10th, 2015, the 2771th LT was performed in Turin, Italy. The donor was a 46-
20 year-old male, deceased of anoxic brain injury. He was HCV positive, genotype 3a,
21 inexperienced to antiviral therapy. Abdomen ultrasound (US) showed normal liver and
22 spleen echogenicity and size. Platelet count was $229 \times 10^9/L$, total bilirubin 0.7 mg/dL, INR
23 1.1, AST/ALT 98/171 IU/L, gamma-glutamyltransferase (GGT) 297 IU/L, HCV-RNA
24 1,210,101 IU/mL, hepatitis B virus (HBV) core antibody positive. On retrieval, the liver was
25 soft despite a grainy capsule (Fig.1A); biopsy showed fibrous expansion of most portal
26 areas with evidence of portal-portal bridging (grading 4/18, staging 3/6, Ishak) (Fig.1B-C).

27
28 The recipient, who signed an informed consent, was a 60-year old male, affected by
29 HBV/HCV-related cirrhosis (HCV genotype 1b, non-responder to peginterferon/ribavirin),
30 portal hypertension (large esophageal varices, spleen diameter 20 cm) and multinodular
31 hepatocellular carcinoma beyond San Francisco criteria, successfully downstaged to Milan
32 criteria. At LT, his MELD score was 8, creatinine clearance 98 mL/min, HCV-RNA 150,656
33
34
35
36
37
38
39
40
41
42
43
44
45
46
47
48
49
50
51
52
53
54
55
56
57
58
59
60

1
2
3 IU/mL; HBV-DNA undetectable without treatment. CIT was 373 minutes; end-to-end biliary
4
5 anastomosis with T-tube was performed; post-reperfusion biopsy showed moderate
6
7 ischemia-reperfusion injury. Immediate graft function was satisfactory, with no ascites and
8
9 no evidence of early/delayed dysfunction. Post-LT course was complicated by pneumonia
10
11 ~~due to a multi-sensitive *Klebsiella pneumoniae*~~, and he was discharged on day 26.
12
13
14 Immunosuppression included tacrolimus, mycophenolate mofetil and steroids, the last
15
16 weaned within 6 months. He underwent anti-HBV prophylaxis with lamivudine and
17
18 hepatitis B immunoglobulin. Anti-HCV therapy with daily sofosbuvir (400 mg), daclatasvir
19
20 (60 mg) and ribavirin at escalating dose (from 400 to 1000 mg) was started on the day of
21
22 transplant for 24 weeks (according to Italian guidelines), with good tolerance. After LT,
23
24 HCV-RNA was 4,407 IU/mL (HCV genotype 3a) at week 1; <15 IU/mL at week 2 and
25
26 persistently undetectable since week 3. He achieved a sustained virological response at
27
28 week 12 after end of therapy (SVR12). Transaminases and total bilirubin were persistently
29
30 normal from week 4 after LT; GGT and alkaline phosphatase normalized from week 8.
31
32
33 Liver stiffness, evaluated by transient elastography was 10.5 kilopascal (kPa) at week 12
34
35 of therapy and it fell to 8.5 kPa at SVR12.
36
37

38
39 On May 2nd, 2016, a T-tube cholangiography showed a mild biliary anastomotic stricture,
40
41 which was managed by endoscopic stenting for 1 month.
42

43
44 At SVR12, Doppler-US showed regular liver perfusion and reduction in spleen size (16.5
45
46 cm), whilst upper endoscopy confirmed disappearance of the esophageal varices;
47
48 magnetic resonance cholangiopancreatography evidenced a patent biliary anastomosis
49
50 with normal intrahepatic bile ducts (Fig.2A); liver biopsy showed persistent fibrous
51
52 expansion of most portal areas with occasional portal-portal bridging (grading 3/18, staging
53
54 3/6, Ishak; Fig.2B-C).
55

56
57 In conclusion, recourse to well-tolerated, ~~pan-genotypic~~ pan-genotypic DAAs immediately
58
59 after LT, allowed to cure the donor's chronic hepatitis C into the recipient, thus affording a
60

1
2
3 favorable short-term outcome, at variance with our previous unsuccessful case occurring
4
5 in the interferon-era. The present report is a proof-of-concept that curbing HCV infection
6
7 very early after LT, in association with CIT minimization and careful recipient selection,
8
9 may result in excellent survival of HCV-positive grafts with portal-portal bridging, pending
10
11 long-term fibrosis evaluation. This observation should encourage transplant teams to a
12
13 more extensive use of HCV-positive donors, hopefully within the scope of an internationally
14
15 agreed multicenter protocol.
16
17
18
19

20 21 References

- 22
23 1. Coilly A, Samuel D. Pros and cons: usage of organs from donors infected with
24
25 hepatitis C virus **HCV**. Revision in the direct-acting antiviral era. J Hepatol
26
27 2016;64:226-231.
28
29
30 ~~2. Ricchiuti A, Brunati A, Mirabella S, Pierini A, Franchello A, Salizzoni M. Use of~~
31
32 ~~hepatitis C virus positive grafts in liver transplantation: a single centre experience.~~
33
34 ~~Transplant Proc. 2005;37:2569-2570.~~
35
36 ~~3. **2** Hepatitis C guidance: AASLD-IDSA recommendations for testing, managing, and~~
37
38 ~~treating adults infected with hepatitis C virus **HCV**. Hepatology 2015;62:932-954.~~
39
40
41
42
43
44
45
46
47
48
49
50
51
52
53
54
55
56
57
58
59
60

FIGURE LEGENDS

Figure 1. Macroscopic and microscopic features of HCV-positive donor liver on retrieval. (A) Macroscopic appearance of the liver on retrieval: despite a grainy Glisson capsule, the parenchymal texture was soft on palpation, and no signs of portal hypertension were visible **and spleen size was normal.** (B) Portal inflammation with lymphocytic aggregate (empty arrow) and periportal hepatitis (arrows); grading 4/18 according to Ishak score (Sirius Red staining; x 200 magnification). (C) Portal fibrosis (empty arrow) with portal-portal bridging (arrows) (staging 3/6 according to Ishak score) and diffuse mild macrovesicular and microvesicular steatosis (Masson's Trichrome staining, **which was performed as an urgent procedure using rapid technique;** x 100 magnification).

Figure 2. Biliary imaging and histology at 9-month follow-up after transplantation and subsequent very early viral eradication. (A) Magnetic resonance cholangiopancreatography showing normal intrahepatic bile ducts, patent biliary anastomosis (arrow) and mild dilatation of the extrahepatic bile duct. (B) Mild portal inflammation (arrow), focal periportal hepatitis (arrowhead) and focal lobular inflammation (empty arrow); grading 3/18 according to Ishak score (hematoxylin–eosin staining; x 100 magnification). (C) Portal fibrosis (arrow) and thin portal-portal bridging (empty arrow); staging 3/6 according to Ishak score (Sirius Red staining; x 100 magnification).

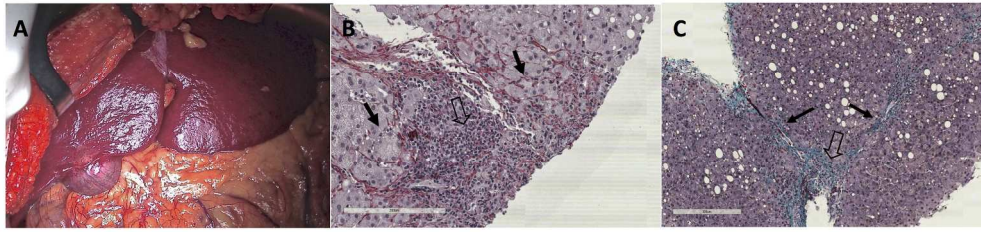


Figure 1. Macroscopic and microscopic features of HCV-positive donor liver on retrieval. (A) Macroscopic appearance of the liver on retrieval: despite a grainy Glisson capsule, the parenchymal texture was soft on palpation, no signs of portal hypertension were visible and spleen size was normal. (B) Portal inflammation with lymphocytic aggregate (empty arrow) and periportal hepatitis (arrows); grading 4/18 according to Ishak score (Sirius Red staining; x 200 magnification). (C) Portal fibrosis (empty arrow) with portal-portal bridging (arrows) (staging 3/6 according to Ishak score) and diffuse mild macrovesicular and microvesicular steatosis (Masson's Trichrome staining, which was performed as an urgent procedure using rapid technique; x 100 magnification).

253x67mm (300 x 300 DPI)

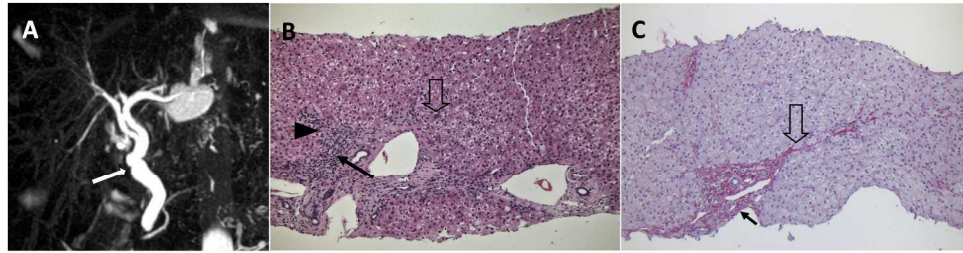


Figure 2. Biliary imaging and histology at 9-month follow-up after transplantation and subsequent very early viral eradication. (A) Magnetic resonance cholangiopancreatography showing normal intrahepatic bile ducts, patent biliary anastomosis (arrow) and mild dilatation of the extrahepatic bile duct. (B) Mild portal inflammation (arrow), focal periportal hepatitis (arrowhead) and focal lobular inflammation (empty arrow); grading 3/18 according to Ishak score (hematoxylin–eosin staining; x 100 magnification). (C) Portal fibrosis (arrow) and thin portal-portal bridging (empty arrow); staging 3/6 according to Ishak score (Sirius Red staining; x 100 magnification).

238x68mm (300 x 300 DPI)