Age associated changes in peripheral airway smooth muscle mass of healthy horses

Short Communication

Age-associated change in peripheral airway smooth muscle mass of healthy horses

Michela Bullone, Morgane Pouyet, Jean-Pierre Lavoie *

Department of Clinical Sciences, Université de Montréal, 3200 rue Sicotte, St-Hyacinthe, J2S 2M2, Quebec, Canada

*Corresponding author: Tel: +1 450 7738521.
E-mail address: jean-pierre.lavoie@umontreal.ca (J.-P. Lavoie).

Abstract

Peripheral airway smooth muscle (ASM) mass is increased in severe equine asthma, but no information exists on the timing of such a structural alteration during the development of the disease. In order to elucidate the mechanisms driving ASM remodeling during disease, anatomical ASM development has to be evaluated first. This study investigated the morphometric alterations sustained by peripheral ASM during aging in healthy horses. The thickness of the peripheral ASM layer was found to be constant in horses of all ages, but it occupies a greater proportion of the inner wall area in younger than in older horses. This finding suggests that equine airways physiologically experience a decrease in the relative abundance of ASM with age. Failure to do so may play a role in equine asthma development.

Keywords: Airway smooth muscle; Development; Foal; Lung; Peripheral airways.

Severe equine asthma, also known as recurrent airway obstruction (RAO) or heaves, is a chronic obstructive disease affecting adult horses exposed to environmental antigens as found in hay and straw dust. Following exposure, affected horses develop pulmonary inflammation associated with a severe bronchoconstrictive response caused by exaggerated airway smooth muscle (ASM) contraction (Leclere et al., 2011b). Several studies have shown that the ASM mass is increased in severely asthmatic horses, particularly in the peripheral airways, thereby contributing to airflow obstruction (Herszberg et al., 2006; Leclere et al., 2011a; Bullone et al., 2015).

Despite the central role of the increased ASM in severe equine asthma, no information is available concerning the timing of these structural alterations during disease development. Moreover, it remains unclear whether this remodeling results from an abnormal growth or from a failure of involution/regression mechanisms normally occurring during airway development in healthy subjects. To clarify these issues, an accurate description of the postnatal ontogenesis of ASM in healthy horses is required. The present study aims to investigate the anatomical alterations sustained by the peripheral ASM with ageing in a cohort of healthy horses.

Peripheral lung tissues harvested post-mortem from healthy horses were obtained from the Equine Respiratory Tissue Bank[1] or from the histological archives of the authors' institution. Horses were defined as healthy based on history (absence of respiratory signs), blood work results (when available), and histopathological findings. Histological sections of 5 µm thickness were stained with hematoxylin-eosin-phloxyn-saffron (HEPS). Five airways per horse with a major to minor axis ratio <1.5, with an intact epithelium, and with smooth muscle surrounding ≥70% of their circumference were studied. The ASM area, the outer border of ASM, and the internal perimeter length (Pi) were measured in cross-sectionally cut peripheral airways using Image J (NIH). ASM mass was expressed as ASM/Pi (corrected by the internal perimeter to account for variation in airway size) and as ASM% (percentage of the inner airway wall occupied by ASM, where the inner

[1] See: www.ertb.ca (accessed 04/05/2017).

airway wall area was calculated as the difference between the area enclosed by the external border of ASM and the airway lumen area enclosed by Pi; Fig. 1). Measurements were performed by one investigator blinded to the subject identity. For statistical analysis, horses were divided in six age groups (0-6 months, 6-12 months, 1-4 years, 5-10 years, 11-20 years, and >20 years). Further methodological details are provided online (see Appendix A: Supplementary material).

Tissues harvested from 51 healthy horses ranging from 1 day to 32 years of age were studied. Table 1 details their age, sex distribution, and average airway size. ASM/Pi, an indirect measure of ASM thickness, did not change with age in the horses studied (P=0.3; Fig. 2A). However, ASM/Pi significantly increased with increasing airway size when airways of all groups were analysed together (r^2=0.11, P<0.0001; Fig. 2B). ASM%, which represents the percentage of the inner bronchial area occupied by ASM bundles, decreased significantly with ageing (P=0.02; Fig. 3A). There was no significant difference in the mean ASM% of foals in the different age groups (see Appendix A: Supplementary material). With the exception of horses aged 11-20 years, in which ASM% decreased with increasing airway size (P=0.04), ASM% was not affected by airway size (P>0.1; Fig. 3B).

The increased ASM mass observed in the peripheral airways of severely asthmatic horses plays a central role in disease development and clinical presentation, as shown by a recent study in which a significant association was found between the degree of peripheral ASM remodeling and disease severity expressed in terms of lung function (Bullone, 2016). As both genetic and environmental factors contribute to severe equine asthma development (Leclere et al., 2011b), the structural alterations of peripheral airways contributing to airflow obstruction could precede the appearance of clinical signs and occur earlier in a horse's life. Interestingly, the mild form of equine asthma known as inflammatory airway disease (IAD), which is common among young athletic horses and is considered a risk factor for the development of the severe form of the disease

(Bosshard and Gerber, 2014), is characterised by airway hyperreactivity, i.e. an exaggerated bronchoconstrictive response. To elucidate the mechanisms driving ASM remodeling in equine asthma, normal smooth muscle development needs to be evaluated first. Our study provides the first data on peripheral ASM postnatal ontogenesis in the equine species. These results show that peripheral airways of similar size have an ASM layer characterised by a constant thickness. However, a higher proportion of the inner bronchial area is occupied by ASM in the fast-growing foals compared to what is observed in adult horses. Such age-related decrease of ASM% can be caused by an increased epithelial or lamina propria area, or both. Previous studies have reported an unchanged peripheral ASM thickness in children vs. men (Hislop and Haworth, 1989), which is in agreement with our results. An age-related decrease in peripheral ASM bundle size (corrected by airway dimensions) was reported in rhesus monkeys which, if occurring in man as well, might explain the increased airway hyperreactivity observed during childhood (Tran et al., 2004). In fact, in airways of similar size, the ability of the ASM to contract and induce bronchospasm is proportional to its mass. Increased ASM% has also been reported in young vs. old rabbits (Ramchandani et al., 2000), while the same was not observed in swine (Murphy et al., 1991). However, the latter study was limited to the large conducting airways. As a limitation of the current study, our data are limited to small peripheral airways, and therefore, the observed effects of airway size may not reflect what occurs when the entire bronchial tree is considered.

In conclusion, our study provides fundamental information on the anatomical development of ASM mass in healthy horses and paves the way for detecting asthma-related alterations in this process. The increased ASM% observed in young horses deserves attention as it could be associated with increased hyperresponsiveness and may be implicated in the pathogenesis of mild forms of equine asthma.

Acknowledgements:

The authors would like to thank Amandine Vargas for helping with case selection, Guy Beauchamp for statistical advice, and Dr. Pierre Hélie for kindly providing access to the histology archives of the Department of Pathology and Microbiology of the Université de Montréal. This study was financed by the Canadian Institutes of Health Research (MOP-102751) and by the Quebec Respiratory Health Network.

Appendix A: Supplementary material

Supplementary data associated with this article can be found, in the online version, at doi: ...

Conflict of interest statement:

None of the authors of this paper has a financial or personal relationship with other people or organisations that could inappropriately influence or bias the content of the paper.

References

Bosshard, S., Gerber, V., 2014. Evaluation of coughing and nasal discharge as early indicators for an increased risk to develop equine recurrent airway obstruction (RAO). Journal of Veterinary Internal Medicine 28, 618-623.

Bullone, M. 2016. Reversibility of airway remodeling in equine asthma: contribution of anti-inflammatory and bronchodilator therapies. PhD Thesis, Université de Montréal. Available at https://papyrus.bib.umontreal.ca/xmlui/handle/1866/18381 (accessed 04/05/2017).

Bullone, M., Beauchamp, G., Godbout, M., Martin, J.G., Lavoie, J.P., 2015. Endobronchial ultrasound reliably quantifies airway smooth muscle remodeling in an equine asthma model. PLoS One 10, e0136284.

Herszberg, B., Ramos-Barbon, D., Tamaoka, M., Martin, J.G., Lavoie, J.P., 2006. Heaves, an asthma-like equine disease, involves airway smooth muscle remodeling. Journal of Allergy and Clinical Immunology 118, 382-388.

Hislop, A.A., Haworth, S.G., 1989. Airway size and structure in the normal fetal and infant lung and the effect of premature delivery and artificial ventilation. American Review of Respiratory Diseases 140, 1717-1726.

Leclere, M., Lavoie-Lamoureux, A., Gelinas-Lymburner, E., David, F., Martin, J.G., Lavoie, J.P., 2011a. Effect of antigenic exposure on airway smooth muscle remodeling in an equine model of chronic asthma. American Journal of Respiratory Cellular and Molecular Biology 45, 181-187.

Leclere, M., Lavoie-Lamoureux, A., Lavoie, J.P., 2011b. Heaves, an asthma-like disease of horses. Respirology 16, 1027-1046.

Murphy, T.M., Mitchell, R.W., Halayko, A., Roach, J., Roy, L., Kelly, E.A., Munoz, N.M., Stephens, N.L., Leff, A.R., 1991. Effect of maturational changes in myosin content and morphometry on airway smooth muscle contraction. American Journal of Physiology 260, L471-480.

Ramchandani, R., Shen, X., Elmsley, C.L., Ambrosius, W.T., Gunst, S.J., Tepper, R.S., 2000. Differences in airway structure in immature and mature rabbits. Journal of Applied Physiology 89, 1310-1316.

Tran, M.U., Weir, A.J., Fanucchi, M.V., Murphy, A.E., Van Winkle, L.S., Evans, M.J., Smiley-Jewell, S.M., Miller, L., Schelegle, E.S., Gershwin, L.J., et al., 2004. Smooth muscle development during postnatal growth of distal bronchioles in infant rhesus monkeys. Journal of Applied Physiology 97, 2364-2371.

Table 1.

Details of the horses in the different age groups.

	0-6 months	6-12 months	1-4 years	5-10 years	11-20 years	>20 years
n	11	7	9	8	9	7
Age [a]	0.5 ± 1 months	8 ± 2 months	2 ± 1 years	8 ± 2 years	16 ± 3 years	25 ± 3 years
Sex [b]	4:7	3:4	5:3	3:4	6:3	3:4
Pi [µm] [a]	876 ± 232	817 ± 318	851 ± 343	1022 ± 578	934 ± 685	1026 ± 407

[a] Expressed as mean ± standard deviation.

[b] Expressed as female:male ratio.

Pi: internal perimeter.

Figures

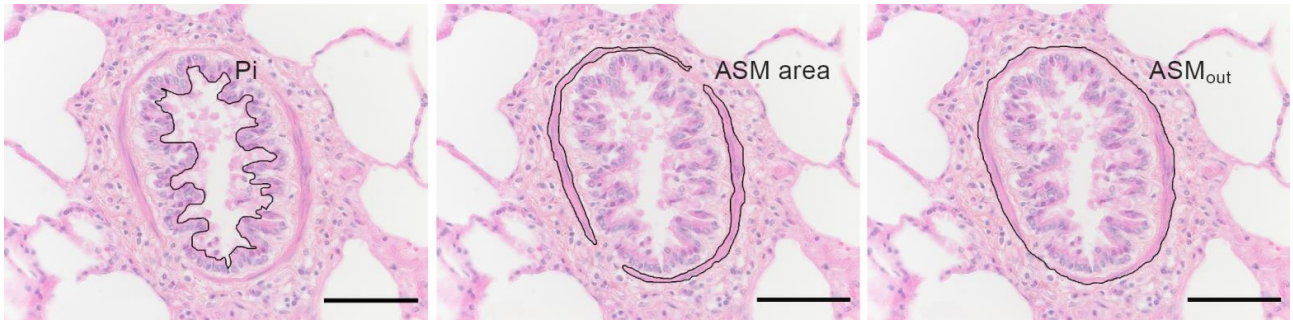

Fig. 1. Histomorphometric parameters assessed on peripheral airways. ASM% was calculated as (ASM area/[ASM$_{out}$ – airway lumen area])*100. Airway lumen area is the area enclosed by Pi. Scale bar: 50 µm. ASM: airway smooth muscle; ASM$_{out}$: area enclosed by the outer border of the airway smooth muscle layer; Pi: internal perimeter.

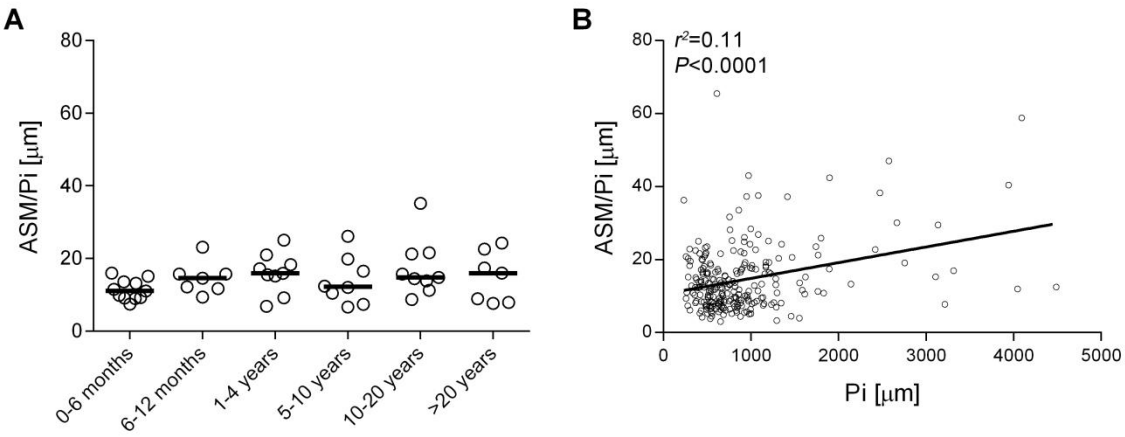

Fig. 2. Effect of age (A) and airway size (B) on peripheral ASM thickness. Up to 10-fold variations were observed for ASM/Pi values measured in airways of similar size in the same subject. ASM/Pi: thickness of the peripheral airway smooth muscle layer. ASM: airway smooth muscle. Pi: internal perimeter.

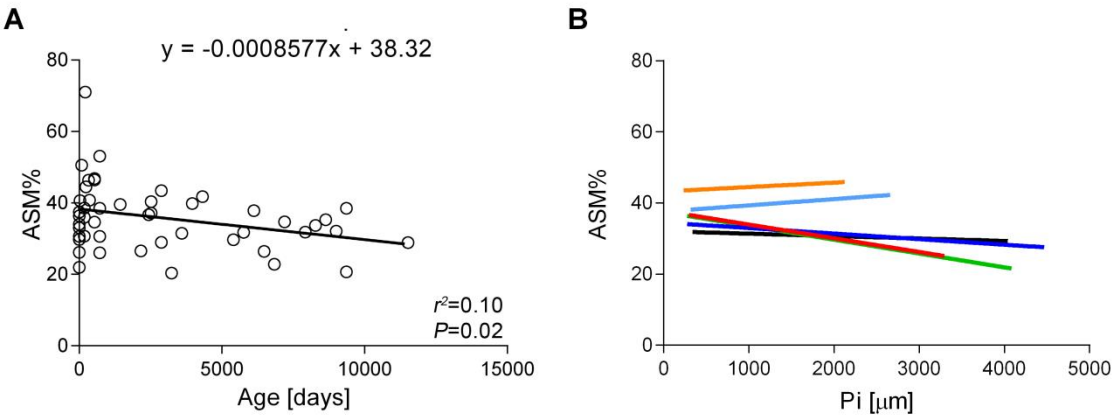

Fig. 3. Effect of age (A) and airway size (B) on the percentage of peripheral inner airways occupied by ASM bundles. (B) Red line: horses 0-6 month old. Orange line: horses 6-12 month old. Light blue line: horses 1-4 year old. Blue line: horses 5-10 year old. Green line: horses 11-20 year old. Black line: horses >20 year old. ASM: airway smooth muscle. ASM%: percentage of peripheral inner airways occupied by ASM bundles. Pi: internal perimeter.