

AperTO - Archivio Istituzionale Open Access dell'Università di Torino

### Thymus atrophy and regeneration following dexamethasone administration to beef cattle

**This is the author's manuscript**

*Original Citation:*

Thymus atrophy and regeneration following dexamethasone administration to beef cattle / Cannizzo F.T.; Spada F.; Benevelli R.; Nebbia C.; Giorgi P.; Brina N.; Bollo E.; Biolatti B.. - In: VETERINARY RECORD. - ISSN 0042-4900. - 167:9(2010), pp. 338-343.

*Availability:*

This version is available <http://hdl.handle.net/2318/98931> since

*Terms of use:*

Open Access

Anyone can freely access the full text of works made available as "Open Access". Works made available under a Creative Commons license can be used according to the terms and conditions of said license. Use of all other works requires consent of the right holder (author or publisher) if not exempted from copyright protection by the applicable law.

(Article begins on next page)



# UNIVERSITÀ DEGLI STUDI DI TORINO

***This is an author version of the contribution published on:***

*Questa è la versione dell'autore dell'opera:*

*Vet Rec. 167(9):338-43. 2010, doi: 10.1136/vr.c3303.*

***The definitive version is available at:***

*La versione definitiva è disponibile alla URL:*

*<http://veterinaryrecord.bmj.com/content/167/9/338.long>*

# **Thymus atrophy and regeneration following dexamethasone administration to beef cattle**

F. T. Cannizzo, F. Spada, R. Benevelli, C. Nebbia, P. Giorgi, N. Brina, E. Bollo, B. Biolatti

Thymus atrophy and regeneration were studied in 13- to 22-month-old beef calves treated with dexamethasone (DMT), using anabolic dosages and implementing different withdrawal times. Two trials were conducted. In trial 1, group A (n=6) received 0.7 mg/day DMT orally for 40 days, group B (n=6) received 1.4 mg/day orally for 40 days and group C (n=6) was the control. In trial 2, group D (n=6) received 0.7 mg/day DMT orally for 40 days, group E (n=6) received 1.4 mg/day orally for 40 days and group K (n=6) was the control. DMT withdrawal times before slaughter were six days (groups A and B) and 26 days (groups D and E). At slaughter, thymus atrophy was severe and progressive in animals from groups A and B. In contrast, thymus weight and volume of the animals from groups D and E were almost normal. Slight atrophy was also detected in the calves in these groups. Histological changes and Ki67 immunostaining revealed a large number of positive lymphoid cells, mostly in the cortical area, associated with higher expression of apoptosis in the medulla compared with controls. This demonstrated that the thymus of beef cattle is still able to regenerate following DMT administration.

CORTICOSTEROIDS are used illegally in several countries as growth promoters in veal calves and beef production, in order to enhance carcass and meat quality traits (Renaville and others 1994, Gottardo and others 2008). These drugs are usually used in association with sex steroids and  $\beta$ -agonists to obtain a higher proportion of lean meat (Meyer 2001). They can be administered either parenterally or orally in milk replacers or top-dressed on silage (Courtheyn and others 1993, Brambilla and others 1998). The national residue monitoring plan of EU member states, as required by Council Directive 96/23/EC and Council Regulation (EEC) Number 2377/90, checks for the absence of specific residues of corticosteroids. Unfortunately, the targeted gas chromatography/mass spectrometry (GC/MS) and liquid chromatography tandem mass spectrometry (LC/MS/MS) methods used give unsatisfactory results. This is partly because people who use corticosteroids illegally administer low dosages, which are readily cleared by the organism and therefore cannot be detected by these techniques, and partly because they often use new molecules that are structurally different from those the analytical techniques are designed to identify. The rapid metabolism and excretion of metabolites further limit the detection of residues. Therefore, the study of lasting and indirect biomarkers still evident at the abattoir may be of help in the detection of treated animals (Groot and others 1996, Brambilla and others 1998). In this respect, thymus atrophy may be considered an indirect biomarker of corticosteroid administration in cattle. Experimental corticosteroid administration studies have been conducted in six-month-old veal calves (Groot and others 1998, Biolatti and others 2005, Cannizzo and others 2008). Results showed that the thymus underwent severe atrophy that was reversible, returning to complete normality between 25 and 32 days after withdrawal, while the lesion was still detectable after two weeks (Biolatti and others 2005, Cannizzo and others 2008). Starting in 2009, histological examination of the thymus has been introduced by the Ministry of Health in Italy as a screening test to control the illegal use of corticosteroids in veal calves (Piano Nazionale Residui 2009 - Ministero del Lavoro, della Salute e delle Politiche Sociali -Dipartimento per la Sanità Pubblica Veterinaria, la Nutrizione e la Sicurezza Alimentare).

Dexamethasone (DMT) and other corticosteroids are now the most popular growth promoters in beef cattle production. They are administered at low dosages in order to obtain better performances, as seen in veal calves (Istasse and others 1989, Corah and others 1995, Courtheyn and others 2002, Capolongo and others 2007, Gottardo and others 2008). Unfortunately, existing scientific data on the physiological effects of corticosteroids on the thymus of one-and-a-half-year-old beef cattle are insufficient to apply them to the histological screening of this gland. According to Wise and Klindt (1995), the thymus weight of beef cattle starts to decrease at around 14 months of age, but no clear data are available on the normal histological pattern of the thymus at this age. Moreover, little is known about the behaviour of the thymus in beef cattle following corticosteroid administration, and thymus atrophy could also be a consequence of infectious diseases, intoxication and stress (Gruver and Sempowski 2008). In these cases, however, the affected animals should show typical clinical signs and lesions (Inui and others 1978, Heilmann and others 1982, Durham and others 1985, Hughes and others 1985, Peters and others 1987, Durchfeld 1988, Durchfeld and others 1989, Uno and others 1990). While various studies have been performed to assess the effects of the non-therapeutic use of DMT on beef cattle growth and slaughter performance (Brethour 1972, Dicke and others 1974, Gottardo and others 2008), none has been done with regard to the pathological effects on the thymus. The regenerative process of lymphoid tissue can be evaluated by estimating cell proliferation activity with the immunohistochemical detection of the Ki67 antigen (Krüger and Müller 1995) as well as apoptosis. Tissue regrowth is not only the result of cell proliferation but also of enhanced cell survival (inhibition of apoptosis) or a combination of both mechanisms (Hannun 1997).

The aim of this work was to study the pathological changes (atrophy and regeneration) of the thymus in 13- to 22-month-old beef cattle, together with Ki67 antigen expression and apoptosis following DMT administration, with different growth-promoting protocols and the application of different withdrawal times before slaughter. Two different breeds were used in the study to detect possible variation in response to corticosteroid treatment.

## Materials and methods

### Animals and experimental design

In trial 1 an anabolic treatment regimen was instituted to establish the pathological changes in the thymus after DMT administration with a short withdrawal time. Eighteen male Charolais beef cattle, 17 to 22 months old, were randomly divided into three groups: cattle in group A (n=6) were given 0.7 mg/day dexamethasone-21-sodium-phosphate (Desashock; Fort Dodge Animal Health) orally for 40 days; cattle in group B (n=6) were given 1.4 mg/day of the same compound orally for 40 days; and cattle in group C (n=6) served as the control group. Animals were slaughtered after a six-day withdrawal period.

Trial 2 was designed to assess the ability of the thymus of beef cattle to restore its weight and structure following atrophy induced by DMT and to verify whether lesions are still present and detectable after a protracted withdrawal time. Eighteen crossbred male Friesian beef cattle, 13 to 17 months old, were randomly divided into three experimental groups: cattle in group D (n=6) were given 0.7 mg/day of dexamethasone-21-sodium-phosphate orally for 40 days; cattle in group E (n=6) were given 1.4 mg/day of the same compound orally for 40 days; and cattle in group K (n=5) served as the control group. Animals in groups D and E were slaughtered after a 26-day withdrawal period, together with control group K.

All groups of experimental animals were kept in separate boxes, 10 x 15 m, and fed with a diet consisting of corn silage, corn, hay and a commercial protein supplement; water was supplied ad libitum. The experiment was authorised by the Italian Ministry of Health and the Ethics Committee of the University of Turin. Carcasses of treated animals were destroyed. All animals treated orally, before the distribution of the feed each morning, were tied to the feeding trough, where two trained technicians gave one capsule containing the compound per application, using a drenching gun. Control animals were treated with a placebo.

#### Processing of thymic tissue

Both cervical and thoracic portions of the thymus of each animal were collected soon after slaughter and weighed. The thymus:bodyweight ratio was calculated according to the following formula: weight of organ (g)/bodyweight of beef cattle (kg) x 100. Tissue samples were fixed in 10 per cent neutral buffered formalin and paraffin embedded according to routine histological procedures. Representative sections of each sample were stained with haematoxylin and eosin for histological examination.

#### Detection and quantification of apoptosis

Representative 4 pin thick sections of thymus from cattle in groups D, E and K were stained by a terminal uridine deoxynucleotidyl transferase dUTP nick-end labelling (TUNEL) assay using an ApopTag In Situ Apoptosis Detection Kit (Intergen) for the identification of apoptotic nuclei (Mori and others 1994), according to the manufacturer's instructions. The reaction was revealed immunohistochemically by means of a peroxidase conjugated anti-digoxigenin antibody. The reaction was developed in a solution of diaminobenzidine and hydrogen peroxide for five minutes, counterstained with 0.5 per cent (w:v) methyl green for 10 minutes and destained in n-butanol. A negative control was obtained by omitting the terminal deoxynucleotidyl transferase in the reaction mixture during the labelling steps.

#### Immunohistochemistry

Sections of thymus of groups D, E and K were immunohistochemically stained with monoclonal Ki67 antibodies (Dako) as follows: sections (3 µm) were deparaffinised and rehydrated. Endogenous peroxidase activity was blocked by incubating sections in 3 per cent hydrogen peroxide for 15 minutes. After repeated rinsing with phosphate buffered saline solution (PBS), sections were immersed in citrate buffer (0.005M, pH 6.0) and heated in a water bath at 98°C for 45 minutes. They were then incubated with a primary antibody for 60 minutes (1:50 dilution). The sections were washed in PBS, and a streptavidin-biotin multilink method (StrAvidin Multilink kit; Biogenex) was used for the detection of reactivity. Diaminobenzidine-hydrogen peroxide solution (Dako) was used as chromogen and applied for five minutes. The slides were then rinsed in distilled water to stop the reaction. After washing, the slides were counterstained with haematoxylin, dehydrated and mounted with a coverslip.

#### Image analysis

Digital images were obtained with a Nikon DS-Fi1 colour digital camera (Nikon Instruments). The apoptotic and Ki67-positive cells were identified by examination at 400 x magnification by light microscopy. For each section, 10 randomly selected fields were examined using Image-Pro-Plus software (Media Cybernetics). In each field, the total areas of apoptotic or Ki67-positive cells and negative nuclei were evaluated. The incidence of positive cells was expressed as the percentage of the positive nuclear area (mean [sd]).

#### Statistical analyses

Statistical analyses were carried out using GraphPad Software, version 3.05. To compare the data, the Kruskal-Wallis test (non-parametric analysis of variance) and the Dunn's multiple comparison post test were used. Differences between the groups were considered significant at  $P < 0.05$ .

## Results

#### Gross and microscopic findings in the thymus

In trial 1 thymus weight and volume of treated animals (groups A and B) were significantly reduced compared with controls (group C), which had a mean weight of 408 g (Table 1, Fig 1). Animals in group A showed an intermediate reduction of weight and volume with a mean weight of 217 g and the thymus parenchyma was replaced by fat tissue. Both cervical and thoracic portions of the thymuses of group B

were notably reduced in weight and volume and were replaced by fat (mean weight 131 g). The cervical portion was the most severely affected in all subjects and in two animals it could not be detected. Histologically, group A showed severe thymic cortical atrophy, while the medullary framework was still present though reduced, showing a pronounced rarefaction of lymphocytes (Fig 2a). The thymic cortex was almost completely replaced by fat tissue leaving only scattered remnants localised close to the medulla. All treated animals in group B showed remarkable histological findings, characterised by complete replacement of lymphoid tissue by fat; even the medulla had disappeared, making the histological structure of the thymus unrecognisable. Remnants of the parenchyma were represented only by small, disseminated islets of lymphocyte aggregates, especially around the vessels immersed in the fat tissue (Fig 2b). Control animals showed a variable pattern, from the normal appearance of the thymus of young animals to slight physiological atrophy in the oldest (Fig 2c), and varying from a moderate fat infiltration at the periphery of lobules to a moderate reduction of the cortex.

In trial 2, the thymus weights and volumes in the control and treated animals were not significantly different (Table 1). Macroscopically, superficial and interstitial fat deposits were more abundant and lobules appeared slightly atrophic in the thymuses of treated animals (Fig 3). The histological appearance of the thymuses of all treated animals in groups D and E showed a considerable interstitial fat infiltration associated with thinning of the cortex and lymphocyte depletion, both in the cortex and the medulla (Figs 4a, b). Lesions were most severe in the thymuses of animals in group E (Fig 4b). The histology of the thymus of the control beef cattle (group K) was similar to that of young calves. The parenchyma had normal features characterised by a cortex filled with proliferating T cells with a smaller proportion of associated epithelial cells. More mature T cells were found in the medulla, where epithelial cells, dendritic cells and macrophages were more abundant (Fig 4c). Almost none, or very few, adipose cells were observed in the peripheral layers of the cortex.

#### Apoptosis of the thymus (TUNEL assay)

Apoptotic cells were detected in the thymuses of treated and control animals in trial 2, scattered in the medulla and more densely distributed throughout the cortex. The apoptotic signal was localised in the nucleus of thymocytes with variable morphology, according to the different stages of apoptosis. In some cells the nuclear staining was homogeneous, while in others it was more intense at the periphery. In a few cases, clusters of apoptotic fragments were observed in the cytoplasm of macrophages. In the cortical area the positivity accounted for 0.60 per cent, 0.14 per cent and 0.38 per cent, respectively, in groups D, E and K. A significant statistical difference was observed between groups D and E ( $P < 0.05$ ). In addition, a significant increase of apoptotic cells was detected in the medulla in all groups ( $P < 0.05$ ). In particular, a significant trend was observed between groups in the thymic medulla ( $P < 0.05$ ), where the percentage of the apoptotic-positive area was 4 per cent, 3.4 per cent and 2.4 per cent, respectively, in groups D, E and K ( $P < 0.05$ ) (Fig 5).

#### Immunohistochemical expression of Ki67 in the thymus

Table 2 shows the results for Ki67 expression in trial 2. This antigen was detected in the thymus of all examined animals ( $n = 17$ ). In all cases, Ki67 immunostaining revealed a high number of lymphoid cells showing nuclear staining of heterogeneous intensity. The mean percentage areas for Ki67 in the cortex were 60.8 per cent, 62.5 per cent and 59.2 per cent, respectively, in groups D, E and K. In the medulla, the mean percentage areas were 40.6 per cent, 33.0 per cent and 22.9 per cent in the same experimental groups. Statistically significant differences ( $P < 0.01$ ) were detected between groups D and K for the medulla (Fig 6), and between the cortex and medulla in each group ( $P < 0.01$  for group D, and  $P < 0.001$  for groups E and K), as expected (Fig 7).

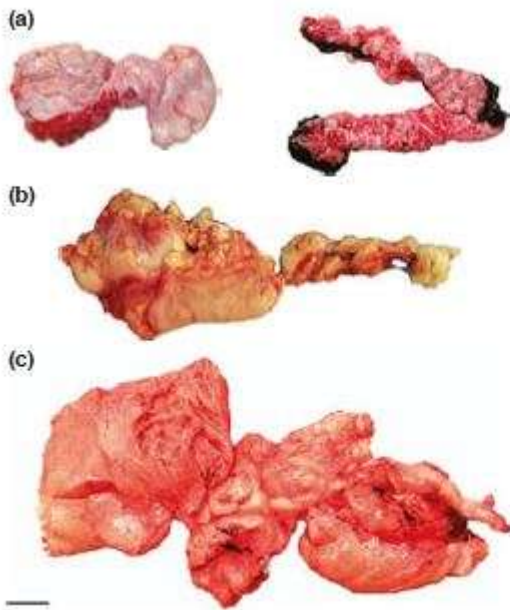


FIG 1: Gross appearance of the thymuses of beef cattle from groups (a) A, (b) B and (c) C. Thymus of group A shows a reduction of volume and fat infiltration, while severe atrophy of the cervical and thoracic portions is evident in cattle of group B. Bar = 2 cm

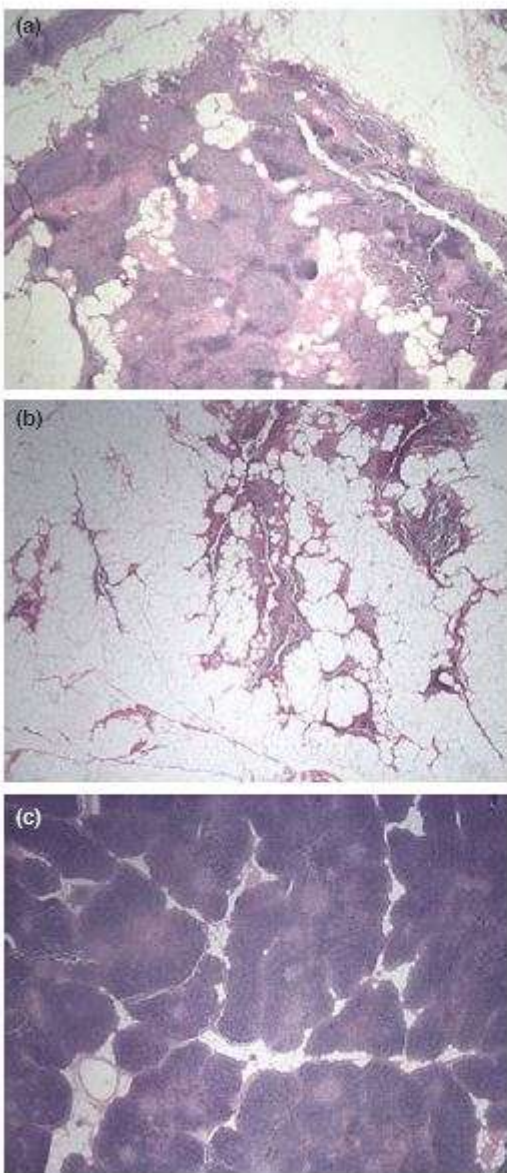


FIG 2: Histological appearance of the thymuses of beef cattle from groups (a) A, (b) B and (c) C. Group A shows severe atrophy of the cortex that has almost disappeared, while the medulla is still present. In group B, lymphoid tissue is completely replaced by fat tissue and the histological structure of the thymus is not recognisable. Haematoxylin and eosin. x20



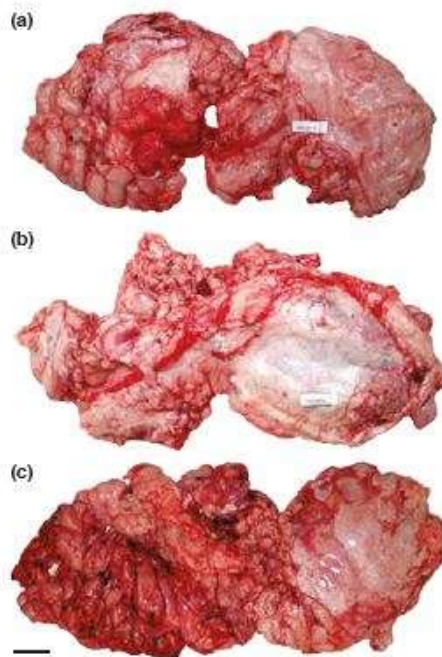


FIG 3: Gross appearance of the thymuses of beef cattle from groups (a) D, (b) E and (c) K. Fat deposits infiltrate the lymphoid tissue of both treated groups D and E. The lobules appear slightly atrophic compared with controls. Bar=2 cm

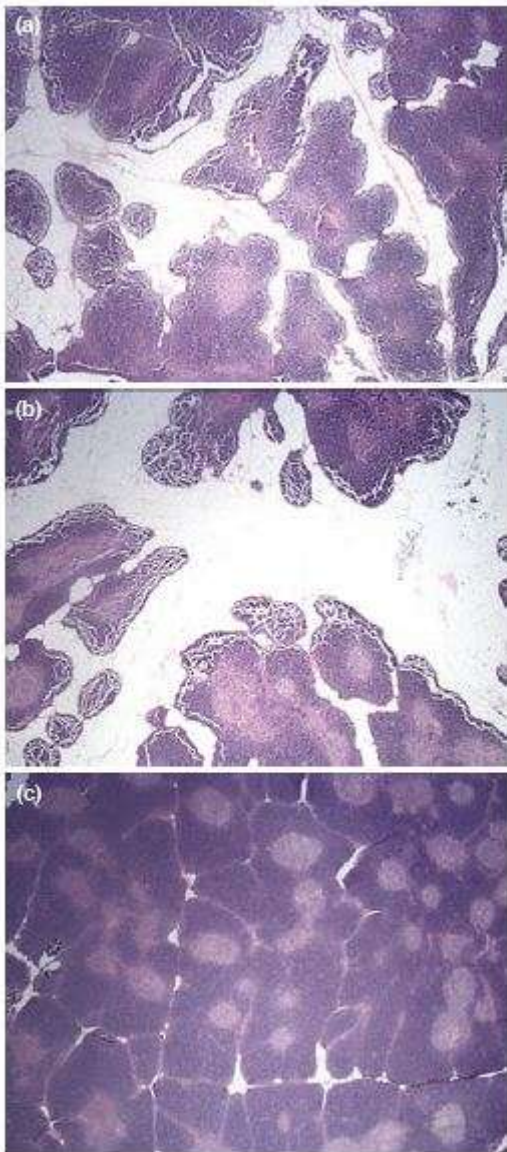


FIG 4: Histological appearance of the thymuses of beef cattle from groups (a) D, (b) E and (c) K. Partial atrophy of the cortex is evident in both groups D and E, and is most severe in group E. Haematoxylin and eosin. x20

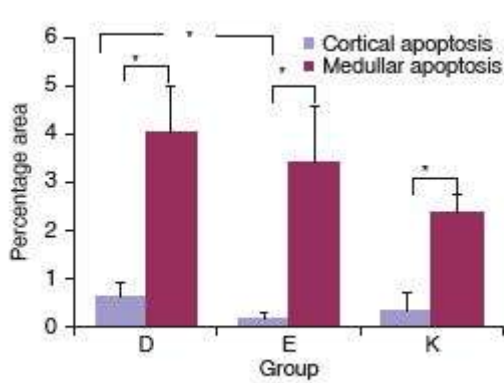


FIG 5: Apoptosis revealed by TUNEL (terminal deoxynucleotidyl transferase-mediated dUTP nick end labelling) assay. Cortical and medullar positivity area in the thymus of groups D, E and K. Data are expressed as mean (sd). \*P<0.05

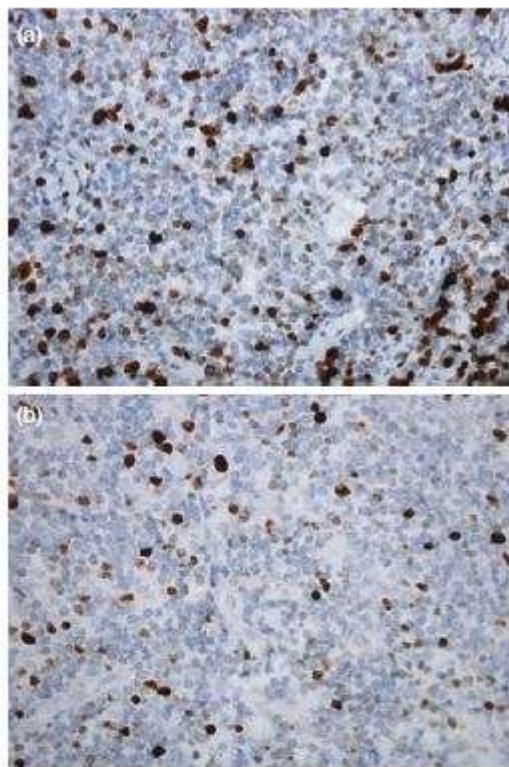


FIG 6: Ki67 expression in the thymic medulla of (a) group D and (b) group K. x400

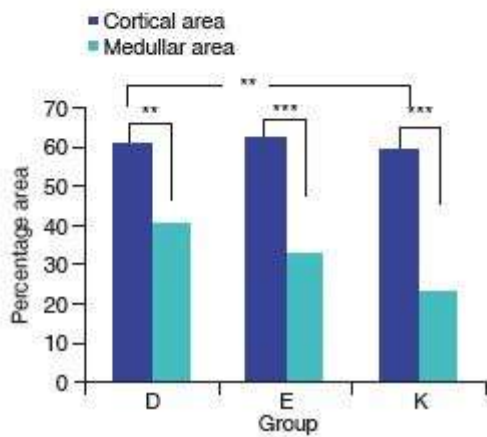


FIG 7: Ki67 immunohistochemistry. Treated animals show increased expression of Ki67 in the thymic medulla that is accentuated in group D. Data are expressed as means for each group. \*\*P<0.01 \*\*\*P<0.001

**TABLE 1: Carcase and thymus weights of treated and control animals**

Animal ID	Group	Carcase weight (kg)	Thymus weight (g)	Mean (sd) thymus weight (g)
1	A	471	387	217 (94)
2		501	247	
3		486	157	
4		518	194	
5		511	115	
6	B	424	202	131 (50)
7		462	162	
8		451	206	
9		506	125	
10		483	134	
11	C	497	101	408 (70)
12		456	59	
13		412	393	
14		408	337	
15		406	505	
16	D	422	427	1133 (220)
17		478	457	
18		400	326	
19		255	870	
20		299	970	
21	E	278	1200	1028 (56)
22		269	1350	
23		272	1000	
24		255	1410	
25		286	1020	
26	K	287	1030	950 (149)
27		289	1030	
28		291	1130	
29		326	960	
30		291	1000	
31		373	1160	
32		331	974	
33		323	876	
34		342	985	
35		336	756	

**TABLE 2: Expression of Ki67 antigen in thymus of trial 2 animals**

ID	Group	Cortical positivity (%)	Medullar positivity (%)
19	D	60.4	41.7
20	D	58.2	29.5
21	D	64.1	42.4
22	D	60.0	53.0
23	D	61.3	36.7
24	D	60.4	41.0
25	E	68.0	20.2
26	E	67.1	25.1
27	E	57.9	33.7
28	E	57.0	42.8
29	E	68.1	38.3
30	E	60.0	37.8
31	K	58.5	26.6
32	K	59.1	17.0
33	K	66.3	28.3
34	K	52.3	19.7
35	K	59.6	22.0

## Discussion

Prolonged administration of low doses of DMT induced a dose-dependent thymus atrophy in beef cattle of different breeds (trial 1) and, when allowed a longer withdrawal time, thymus parenchyma regenerated almost to normality (trial 2).

Trial 1 showed that in beef cattle, as in veal calves (Biolatti and others 2005, Cannizzo and others 2008), administration of low doses of DMT for 40 days up to six days before slaughter (group A) induced thymus atrophy of intermediate severity; this was characterised mostly by the disappearance of the cortex and almost complete loss of lymphoid tissue, which was replaced by fat tissue with the higher dose treatment (group B). In trial 2, low doses of DMT administered for a long period to beef cattle did not significantly affect the weight of the thymus when examined approximately one month after the end of treatment; however, this experimental protocol was responsible for increased fat deposits on the surface and interstitium of the thymus, and for typical histological changes represented by partial cortex atrophy and replacement of lymphocytes with fat. For the control thymuses, the mean weight was less in group C (17- to 22-month-old Charolais cattle) (trial 1) than in group K (13- to 17-month-old crossbred male Friesian cattle) (trial 2); histologically, physiological involution was more pronounced in the animals in group C than in group K, although changes were much less severe than the atrophic lesions detected in the thymuses of animals from the treated groups (A, B, D and E). The weight and morphology of the thymuses of the control animals from group K were more similar to those of young calves except for a slight to moderate fat deposition along the interstitial septa at the periphery of the cortex (Cannizzo and others 2008). These small physiological differences may be ascribed to both the older age of the animals employed in trial 1 compared with those of trial 2, and to the different breed of animals in the two groups, suggesting that the thymus of Friesian cattle is physiologically heavier than that of the Charolais breed. The same considerations apply to the treated animals.

Comparing the results of this experiment (trials 1 and 2) with those described in six-month-old veal calves treated with DMT (Biolatti and others 2005, Cannizzo and others 2008), it appears that the length of the withdrawal time of DMT significantly influences the patterns of DMT-induced lesions. Cannizzo and others (2008) reported pronounced thymus atrophy in veal calves from seven to 12 days after the end of DMT treatment, which is consistent with the results of trial 1 in beef cattle in the present study. Partial recovery of thymus weight and structure after 25 days followed by complete recovery after 32 days was also observed in veal calves, and similar results have been observed in trial 2 (groups D and E) where thymuses were examined 26 days after the end of treatment. It must be emphasised that in beef cattle atrophic changes in the thymus were more severe and regeneration incomplete when compared with veal calves treated similarly (Biolatti and others 2005, Cannizzo and others 2008); this may be ascribed to the different physiological condition of beef cattle, where thymus involution may already have started and regeneration, although still present, may be slower. Thus, it is conceivable that the thymus preserves an intrinsic ability to regenerate; however, the mechanism controlling regeneration is not well known. This study demonstrated that lymphoid proliferation, after DMT treatment, starts in the cortical regions and proceeds toward the medulla in all of the examined animals. In the control group the percentage of Ki67-positive cells in the medulla is clearly lower compared with treated animals, as already observed in the human thymus (Salakou and others 2001). On the other hand, apoptosis is more intense in the medulla where mature cells are concentrated (Chen 2004), as in the normal cell turnover. In the current study, however, there was a significant increase in the occurrence of this phenomenon in treated animals compared with controls, as already observed in veal calves, due to the toxic effect of DMT (Zavitsanou and others 2007, Cannizzo and others 2008). This is further evidence that the thymus of beef cattle maintains its regenerative potential, as supported by the intense lymphoid proliferation activity still present 26 days after withdrawal of the drug.

In conclusion, the results of this study show that DMT induces thymus atrophy in beef cattle and that this atrophy is clearly detectable at the slaughterhouse after a withdrawal time of six days, both macroscopically and histologically. The severity of this alteration correlates with the administered DMT dosages. Thymus regeneration was demonstrated in trial 2 after a prolonged withdrawal time, as already described in veal calves (Cannizzo and others 2008). Since the administration of corticosteroids to beef cattle must be continued until very close to the time of slaughter in order to obtain the anabolic effects (Tarantola and others 2004), it can be concluded that gross and histological examination of the thymus should be included as a screening test at the slaughterhouse to detect corticosteroid treatment of beef cattle.

### Acknowledgements

The authors are grateful to the Centro di Referenza di Patologia Comparata 'Bruno Maria Zaini', Tony Wilsmore and the technical staff of the Department of Animal Pathology for their skilful assistance.

This work was partially supported by Regione Piemonte CIPE -Progetti di Ricerca Scientifica Applicata 2004: 'Individuazione di biomarcatori dei trattamenti illeciti nei bovini da carne con indagini di proteomica e genomica' and by Ministero delle Politiche Agricole Alimentari e Forestali, project SAFORISK.

### References

- BIOLATTI, B., BOLLO, E., CANNIZZO, F. T., ZANCANARO, G., TARANTOLA, M., DACASTO, M., CANTIELLO, M., CARLETTI, M., BIOLATTI, P. G. & BARBARINO, G. (2005) Effects of low-dose dexamethasone on thymus morphology and immunological parameters in veal calves. *Journal of Veterinary Medicine. A* **52**, 202-208
- BRAMBILLA, G., FIORI, M., PIERDOMINICI, E., ANTONUCCI, G., GIORGI, P., RAMAZZA, V. & ZUCCHI, M. (1998) A possible correlation between the blood leukocyte formula and the use of glucocorticoids as growth promoters in beef cattle. *Veterinary Research Communications* **22**, 457-465
- BRETHOUR, J. R. (1972) Effects of acute injections of dexamethasone on selective deposition of bovine intramuscular fat. *Journal of Animal Science* **35**, 351-356
- CANNIZZO, F. T., MINISCALCO, B., RIONDATO, F., BOLLO, E., BARBARINO, G., GIORGI, P., MAZZINI, C. & BIOLATTI, B. (2008) Effects of anabolic and therapeutic doses of dexamethasone on thymus morphology and apoptosis in veal calves. *Veterinary Record* **163**, 448-452
- CAPOLONGO, F., TAPPARO, M., MERLANTI, R., RAVAROTTO, L., TEALDO, E., GALLINA, G., MONTESISSA, C. & DACASTO, M. (2007) Illicit treatments in cattle and urinary 6beta-hydroxycortisol/cortisol ratio. *Analytica Chimica Acta* **586**, 228-232
- CHEN, W. (2004) The late stage of T cell development within mouse thymus. *Cellular and Molecular Immunology* **1**, 3-11
- CORAH, T. J., TATUM, J. D., MORGAN, J. B., MORTIMER, R. G. & SMITH, G. C. (1995) Effects of a dexamethasone implant on deposition of intramuscular fat in genetically identical cattle. *Journal of Animal Science* **73**, 3310-3316
- COURTHEYN, D., LE BIZEC, B., BRAMBILLA, G., DE BRABANDER, H. F., COBBAERT, E., VAN DE WIELE, M., VERCAMMEN, J. & DE WASCH, K. (2002) Recent developments in the use and abuse of growth promoters. *Analytica Chimica Acta* **473**, 71-82
- COURTHEYN, D., VERHEYE, N., BACKEROT, V., DAL, V., SCHILT, R., HOOIJERINK, H., VAN BEENEKOM, E. O., HAASNOT, W., STOUTEN, P. & HUF, E. A. (1993) Detection of corticosteroids in animal feed and premixes: a new category of growth promoters. Proceedings of the Euroresidue II Conference. Veldhoven. May 3 to 5, 1993. pp 251-256
- DICKE, B. D., FARLIN, S. D. & ARTHAUD, V. H. (1974) Effect of dexamethasone on intramuscular fat content. *Journal of Animal Science* **39**, 168
- DURCHFELD, B. (1988) Pathologisch-anatomische und pathologisch-histologische Untersuchung der akzidentellen Thymusatrophie bei Kälbern. VetMed thesis. Justus-Liebig Universität. pp 61
- DURCHFELD, B., KÄUFER-WEISS, I. & WEISS, E. (1989) Accidental thymus involution in calves. *Berliner Und Münchener Tierärztliche Wochenschrift* **102**, 400-405 (In German)
- DURHAM, P. J., LAX, A. & JOHNSON, R. H. (1985) Pathological and virological studies of experimental parvoviral enteritis in calves. *Research in Veterinary Science* **38**, 209-219
- GOTTARDO, F., BRSCIC, M., POZZA, G., OSSENSI, C., COSTIERO, B., MARIN A. & COZZI, G. (2008) Administration of dexamethasone per os in finishing bulls. I. Effects on productive traits, meat quality and cattle behaviour as indicator of welfare. *Animal* **2**, 1073-1079
- GROOT, M., SCHILT, R., HAASNOT, W., BERENDE, P. L. M., RAMAZZA, V., COURTHEYN, D., VERCAMMEN, J. & LOGGHE, M. (1996) Veal calves treated with a low dosage of prednisolone, histological and analytical data. In Proceedings of the Euroresidue III Conference. Veldhoven. May 3 to 5, 1993. pp 440-445

- GROOT, M. J., SCHILT, R., OSSENKOPPELE, J. S., BERENDE, P. L. & HAASNOOT, W. (1998) Combinations of growth promoters in veal calves: consequences for screening and confirmation methods. *Zentralblatt Für Veterinärmedizin. Reihe A* 45, 425-440
- GRUVER, A. L. & SEMPOWSKI, G. D. (2008) Cytokines, leptin, and stress-induced thymic atrophy. *Journal of Leukocyte Biology* 84, 915-923
- HANNUN, Y. A. (1997) Apoptosis and the dilemma of cancer chemotherapy. *Blood* 89, 1845-1853
- HEILMANN, P., STEINBACH, G. & SCHULZE, E (1982) Pathoanatomical and pathohistological studies of cyclophosphamide-induced organ changes in calves with special reference to lymphatic organs. *Archiv Für Experimentelle Veterinärmedizin* 36, 623-633 (In German)
- HUGHES, B. J., FORSELL, J. H., SLEIGHT, S. D., KUO, C. & SHULL, L. R. (1985) Assessment of pentachlorophenol toxicity in newborn calves: clinicopathology and tissue residues. *Journal of Animal Science* 61, 1587-1603
- INUI, S., NARITA, M. & KUMAGAI, T. (1978) Bovine virus diarrhea-mucosal disease. I. Pathological changes in natural and experimental cases. *National Institute of Animal Health Quarterly* 18, 109-117
- ISTASSE, L., DE HAAN, V., VAN EENAEME, C., BUTS, B., BALDWIN, P., GIELEN, M., DEMEYER, D. & BIENFAIT, J. M. (1989) Effects of dexamethasone injections on performances in a pair of monozygotic cattle twins. *Journal of Animal Physiology and Animal Nutrition* 62, 150-158
- KRÜGER, S. & MÜLLER, H. (1995) Correlation of morphometry, nucleolar organizer regions, proliferating cell nuclear antigen and Ki67 antigen expression with grading and staging in urinary bladder carcinomas. *British Journal of Urology* 75, 480-484
- MEYER, H. H. (2001) Biochemistry and physiology of anabolic hormones used for improvement of meat production. *apmis: Acta Pathologica, Microbiologica, Et Immunologica Scandinavica* 109, 1-8
- MORI, C., NAKAMURA, N., OKAMOTO, Y., OSAWA, M. & SHIOTA, K. (1994) Cytochemical identification of programmed cell death in the fusing fetal mouse palate by specific labelling of DNA fragmentation. *Anatomy and Embryology* 190, 21-28
- PETERS, W., LIESS, B., FREY, H. R. & TRAUTWEIN, G. (1987) Incidence and impact of persistent infections with BVD virus in the field. In *Agriculture. Pestivirus Infections of Ruminants*. Ed J. W. Harkness. Office for the Official Publications of the European Communities. pp 133-145
- RENAVILLE, R., MASSART, S., LOGNAY, G., DEVOLDER, A., SNEYERS, M., MARLIER, M., SEVERING, M., BURNY, A. & PORTETELLE, D. (1994) Influence of a hormonal preparation containing glucocorticoids (dexamethasone esters), progestagen (chlormadinone acetate) and oestrogen (ethinyl oestradiol) on testosterone, insulin-like growth factor-1 (IGF-1), IGF-binding proteins and spermatogenic cells in finishing bulls. *Animal Production* 59, 189-196
- SALAKOU, S., TSAMANDAS, A. C., BONIKOS, D. S., PAPAPETROPOULOS, T. & DOUGENIS, D. (2001) The potential role of bcl-2, bax, and Ki67 expression in thymus of patients with myasthenia gravis, and their correlation with clinicopathologic parameters. *European Journal of Cardio-Thoracic Surgery* 20, 712-721
- TARANTOLA M., SCHIAVONE A., PREZIUSO G., RUSSO C., BIOLATTI, B. & BERGERO D. (2004) Effects of low doses of dexamethasone on productive traits and meat quality of veal calves. *Animal Science* 79, 93-98
- UNO, K., TAKESUE, K., NAKANISI, K., NAKAGAWA, K., MURAKAMI, K. & HOMMA, S. (1990) Thymuses atrophy in calves associated with infectious diseases. *Journal of the Japanese Veterinary Medical Association* 43, 655-660
- WISE, T. & KLINDT, J. (1995) Thymic weight changes and endocrine relationships during maturation in cattle: effects of age, sex, and castration. *Growth, Development, and Aging* 59, 139-148
- ZAVITSANOU, K., NGUYEN, V., GREGURIC, I., CHAPMAN, J., BALLANTYNE, P. & KATSIFIS, A. (2007) Detection of apoptotic cell death in the thymus of dexamethasone treated rats using [123I]annexin V and in situ oligonucleotide ligation. *Journal of Molecular Histology* 38, 313-319